Accepted Manuscript



Skeletal and Dentoalveolar Changes in the Transverse Dimension using Microimplant-Assisted Rapid Palatal Expansion (MARPE) Appliances

Chen Zong MDS , Bojun Tang MDS , Fang Hua MDS, PhD , Hong He DDS, MDS, PhD Professor , Peter Ngan DMD

PII: S1073-8746(19)30006-4
DOI: https://doi.org/10.1053/j.sodo.2019.02.006
Reference: YSODO 564

To appear in: *Seminars in Orthodontics*

Please cite this article as: Chen Zong MDS , Bojun Tang MDS , Fang Hua MDS, PhD , Hong He DDS, MDS, PhD Professor , Peter Ngan DMD , Skeletal and Dentoalveolar Changes in the Transverse Dimension using Microimplant-Assisted Rapid Palatal Expansion (MARPE) Appliances , *Seminars in Orthodontics* (2019), doi: https://doi.org/10.1053/j.sodo.2019.02.006

This is a PDF file of an unedited manuscript that has been accepted for publication. As a service to our customers we are providing this early version of the manuscript. The manuscript will undergo copyediting, typesetting, and review of the resulting proof before it is published in its final form. Please note that during the production process errors may be discovered which could affect the content, and all legal disclaimers that apply to the journal pertain.

ACCEPTED MANUSCRIPT

Skeletal and Dentoalveolar Changes in the Transverse Dimension using Microimplant-Assisted Rapid Palatal Expansion (MARPE) Appliances

Chen Zong, MDS
Department of Orthodontics, Hubei-MOST KLOS & KLOBM, School & Hospital of Stomatology, Wuhan University, Wuhan, CHINA

Bojun Tang, MDS
Department of Orthodontics, Hubei-MOST KLOS & KLOBM, School & Hospital of Stomatology, Wuhan University, Wuhan, CHINA

Fang Hua, MDS, PhD
Department of Orthodontics, Hubei-MOST KLOS & KLOBM, School & Hospital of Stomatology, Wuhan University, Wuhan, CHINA; Division of Dentistry, School of Medical Sciences, The University of Manchester, Manchester, UK.

Hong He, DDS, MDS, PhD
Professor, Department of Orthodontics, Hubei-MOST KLOS & KLOBM, School & Hospital of Stomatology, Wuhan University, Wuhan, CHINA

Peter Ngan, DMD
Professor and Chair, Department of Orthodontics
West Virginia University School of Dentistry

Please send all correspondence to:
Dr. Hong He
Professor, Department of Orthodontics, Hubei-MOST KLOS & KLOBM, School & Hospital of Stomatology, Wuhan University, Wuhan, CHINA

Email address: drhehong@hotmail.com

ACCEPTED MANUSCRIPT

ACCEPTED MANUSCRIPT

Abstract

Background: Conventional rapid palatal expansion (RPE) has been proven to be a reliable treatment for correcting transverse maxillary deficiency in young patients. However, side effects including dental tipping and risk of periodontal problem limited its application to young patients after the pubertal growth spurt. Surgically assisted rapid palatal expansion (SARPE), a supplement to RPE, could be applied in skeletally mature patients. However, SARPE was an invasive method, and the morbidity, risks and cost related to surgical treatment might discourage many adult patients. The use of Microimplant-Assisted Rapid Palatal Expansion (MARPE) appliance, which can potentially avoid surgical intervention, is gaining popularity in treatment of maxillary transverse deficiency (MTD) in young adolescent patients. However, the literature on the skeletal and dentoalveolar changes with this appliance is scarce. **Objective:** To evaluate the immediate skeletal and dentoalveolar changes in the transverse dimension with the maxillary skeletal expander (MSE), a MARPE appliance with hybrid anchorage, using cone-beam computed tomography (CBCT). **Materials and Methods:** Twenty-two patients (11 males and 11 females, mean age 14.97 ± 6.16 years) with transverse maxillary deficiency were treated using the MSE (Biomaterials Korea, Inc., Seoul, Korea). The appliance consisted of a central expansion screw that were welded to four tubes that served as guides for microimplant placement. The microimplants were 1.8mm in diameter and 11mm in length. The longer length of microimplants permitted bicortical engagement of the palatal and nasal floor, reducing the force transmitted to the anchored teeth during expansion. The appliance activation varied with age and skeletal maturity of the patient. The expansion was terminated when 2-3mm of overexpansion was achieved. CBCT scans were taken before treatment (T1) and immediately after expansion (T2). Measurements were taken to evaluate the amount of total expansion, skeletal expansion, and angular dental tipping at the first molar region. **Results: A total expansion of** 5.41 ± 2.18 mm **was achieved,** 59.23±17.75% **of which** was attributed to skeletal expansion (3.15±1.64 mm) with the first molars exhibiting buccal tipping of 2.56 ± 2.64°. **Conclusions:** The use of MARPE appliances such as MSE can be used to correct transverse maxillary deficiency in adolescent patients with minimal dentoalveolar side effects.

Keywords: Rapid Maxillary Expansion (RME), Microimplant Assisted Maxillary Expansion (MARPE), Maxillary Skeletal Expander (MSE), Cone Beam Computed Tomography (CBCT)

ACCEPTED MANUSCRIPT

Skeletal and Dentoalveolar Changes in the Transverse Dimension using Microimplant-Assisted Rapid Palatal Expansion (MARPE) Appliances

Introduction

The use of maxillary expansion appliance could be dated back to 1860s, when Angell came up with the concept "maxillary expansion", which opened the mid-palatal suture laterally by a palatal expansion appliance.[1] Haas introduced the Haas Expander to United States in 1956 and was the first to report on the increase in nasal width and arch perimeter with maxillary expansion.[2] This technique was soon accepted by clinicians in patients with growth potential. However, the use of RME was less predictable in patients over 15-years-old due to the fact that this was a tooth-borne anchorage device.[3,4] Expansion performed after the peak pubertal growth spurt will lead to more dental than skeletal changes with side effects of buccal dental tipping[5-11] and often a downward and backward rotation of the mandible.[12,13] Moreover, the skeletal effect was limited to around 4 mm due to the fact that transverse expansion would be inevitably compensated by dental tipping.[14] It was reported that skeletal expansion only accounts for about 38% of total expansion,[15] and the recurrence rate was 35%~50%.[16]

Brown introduced the concept of surgically assisted rapid palatal expansion (SARPE) in 1938[17] and then SARPE procedure gradually became the main treatment modality for adult patients with maxillary transverse discrepancy.[18,19] The advantages of treatment with SARPE were predictable skeletal and dental changes,[4,18] and a low rate of relapse (5%~25%).[4] However, many adult patients were discouraged from choosing this treatment due to the invasive nature, risks, complications and cost of the surgical procedure.[20]

The introduction of the Microimplant Assisted Rapid Palatal Expansion (MARPE) appliances provided a new alternative treatment modality for clinicians and adolescent patients with maxillary transverse deficiency. Three dimensional finite element analysis showed that these devices had greater skeletal and less dental side effects than traditional RME.[21,22] Lin et al.

ACCEPTED MANUSCRIPT

compared tooth-borne versus bone-borne rapid maxillary expanders and concluded that bone-borne expanders produced greater orthopedic effects in late adolescent patients.[23] Carlson et al. reported a 19-year-old male with severe constricted maxillary arch treated with the MARPE technique.[24] Cunha et al. reported success in treating a 24-year-old female with maxillary transverse deficiency and Class II malocclusion using the MARPE appliance therefore avoiding the need of a surgical procedure.[25] Choi et al. conducted a larger study using MARPE in 69 young adult patients and reported success in opening the mid-palatal sutures in 86.96% of the subjects.[26] Park et al. reported success in obtaining sutural expansion in 14 young adult patients treated with the MARPE appliance and found a decrease in buccal bone thickness and height of alveolar crest using CBCT.[27] These studies suggested that MARPE appliances can correct transverse maxillary deficiency in young adolescent patients but there was a lack of literature about the skeletal and dental effect of these appliances. The objective of this study was to evaluate the immediate skeletal and dentoalveolar changes in the transverse dimension with the maxillary skeletal expander (MSE), a MARPE appliance with hybrid anchorage, using CBCT.

Materials and Methods

Subjects

A total of 22 patients from the Department of Orthodontics, School of Dentistry, West Virginia University and the Department of Orthodontics, Hospital of Stomatology, Wuhan University (11 males and 11 females, average age 14.97 ± 6.16 yrs.) were included in the study. All patients initially presented in the clinic with transverse maxillary deficiency and had undergone maxillary expansion by MARPE between February 2016 and June 2018. CBCT images were taken before treatment (T1) and immediately after completion of maxillary expansion (T2). This study was approved by the Institutional Review Board of the Hospital of Stomatology, Wuhan University (Reference #: 2018-B01) and the West Virginia University (Reference #:1501557557).

The inclusion criteria consisted of young adolescent patients with transverse maxillary discrepancy of greater than 4mm and less than 10mm treated with the MSE appliance. Consent was obtained from all the subjects. CBCT images were taken before and after expansion with

ACCEPTED MANUSCRIPT

the MSE appliance. The exclusion criteria consisted of subjects diagnosed with congenital facial anomaly or dysmorphism; obvious facial asymmetry; waiving the MARPE therapy for any reasons; with incomplete pre- and post-treatment CBCT scans.

Appliance Design

The MSE appliance consisted of a central expansion jackscrew and four attached arms soldered to orthodontic bands on the anchor teeth to facilitate placement of the appliance. Four tubes were welded to the central expansion jack screw that served as guides for microimplant placement (Figure 1).[24] The microimplants were 1.8mm in diameter and 11 mm in length. The longer length of microimplants allowed bicortical engagement of the palatal and nasal floor, reducing the force transmitted to the anchored teeth during expansion. The palatal microimplants were placed as posterior as possible to maximize the orthopedic force to the pterygoid plates efficiently but never to exceed the palatine process (Figure 2).[14] The microimplants were placed parallel and symmetrical to the mid-palatal suture. The jackscrew was placed as close to the palatal vault as possible without pressing on the soft tissues.

Activation Protocol

Every subject began maxillary expansion 2 weeks after the placement of microimplants. The rate of activation depended on patient's chronological age (Table 1). Maxillary expansion should be suspended if patients complained of unbearable pain; if jackscrew was too tight to turn; if one or more microimplants were loose; and if microimplants or linkages were wrapped by soft tissue and there was obvious localized inflammation. Patients were instructed how to activate the expansion and how to flush the palatal region after meal to keep oral hygiene. The turns of expansion were recorded, regular dental visits were required, and every adverse event was reported. The expansion was terminated when 2-3mm of overexpansion was achieved.

CBCT analysis

ACCEPTED MANUSCRIPT

CBCT scans were taken before treatment (T1) and immediately after expansion with MSE appliance (T2) by the NewTom VGi 9 (Imola, Italy) at Wuhan University and the Carestream Kodak CBCT 9300 (Atlanta, Georgia, USA) at West Virginia University. The exposure time was 3.6s, scanning time was 18s, and scanning view was 20*25cm, with minimal layer thickness of 0.3mm. Patients were instructed to sit up keeping the Frankfort plane paralleled to the ground and clenching on intercuspal position during scanning. The Dicom files were extracted from the CBCT disks using NNT software. All documents were then introduced to the Dolphin 11.9 software.

CBCT data orientation

Three-dimensional model of CBCT was reconstructed in Dolphin software. Specific landmarks which formed the reference planes were determined in the model (Table 2). The three dimensional model was then adjusted based on these reference planes (Figure 3). Accurate orientation could enhance the reliability of superimposition.

Diagnosis

PAC (posterior-anterior cephalogram) was reconstructed after orientation. Transverse maxillary deficiency was diagnosed and measured using the method of Betts et al. (Figure 4).[28] The estimated maxillary transverse discrepancy was measured by comparing the distance of JR-JL and AG-GA. The proper size of MSE (8mm, 10mm, 12mm) was selected according to the diagnosis.

CBCT Superimposition

Pre- and post-treatment CBCT data were superimposed via Dolphin software by voxel. The anterior cranial base was regarded as the most reliable reference structure, thus in this study the voxel of anterior cranial base was used for superimposition (Table 3, Figure 5). Through superimposition, pre- and post-treatment CBCT data were shown in different colors (Figure 6).

CBCT measurements

ACCEPTED MANUSCRIPT

All measurements were performed by one of the investigators. Error measurements were performed by repeating the measurements 3 weeks later to test for its reliability. No significant differences were found between the first and second measurements using Intra-Class correlation (Table 4).

Distance of mesiolingual cusps of maxillary first molars

Landmarks were determined in the coronal slice where both the mesiolingual cusp and palatal root apex of the maxillary first molar could be firstly seen when the transverse section moves from the mesial to the distal (Figure 7). The pre- and post-treatment distance was compared. The differences in value was defined as the **"total expansion"** acquired at the maxillary first molar. Total expansion includes skeletal expansion (true extended distant of mid-palatal suture) and dental expansion (dental tipping and alveolar bending).

Buccal lingual inclination (torque) of maxillary first molars

The torque of maxillary first molar was defined as the intersection angle between mesiolingual cusp-palatal root apex line and horizontal plane (Frankfort plane). The torque was measured on the coronal slice when the cusp and apex were first seen when the transverse section moved from the mesial to the distal (Figure 8).

Extended distance of mid-palatal suture

In the axial cross-section plane, one horizontal slice was chosen for measurement when the mid-palatal suture was seen clearly. In this slice, extended distance was measured anteriorly and posteriorly connecting the left and right microimplants (Figure 9). The average value was regarded as the value for true skeletal horizontal expansion. For most subjects, there were no difference between the anterior and posterior extended distance. As a result, the expansion pattern of mid-palatal suture could be considered as parallel or slightly "V" shaped pattern (Figure 10).

ACCEPTED MANUSCRIPT

In the coronal view, vertical expansion of mid-palatal suture was measured at the nasal and palatal floor on a coronal cross-sectional slice through the center of maxillary first molar by connecting the right and left external edges of the suture according to the method of Ngan et al.[29] (Figure 11, 12). The suture external edges were verified in the axial cross-sectional slice for each tested position.

Statistical analysis

Statistical analyses were performed using SPSS software (version 22.0, Chicago), and 95% confidence intervals ($P < 0.05$) were obtained. The extended distance in mid-palatal suture was evaluated by one-sample t test. The anterior and posterior, nasal and palatal mid-palatal sutural expansion, maxillary width, total expansion and torque of maxillary first molars were evaluated by paired t test, and the relationship between the extended distance in mid-palatal suture and JR-JL were evaluated by Pearson correlation coefficient.

Result

A total of 30 patients with transverse maxillary deficiency were treated consecutively by the MARPE appliance at the two centers, but only twenty-two patients were included in this study. Three were excluded due to incomplete CBCT, three were excluded during MARPE treatment because the palatal soft tissue wrapped around the MSE, one patient was excluded because of peri-implantitis and one was diagnosed with cleft lip and palate.

Table 5 shows the mean transverse maxillary deficiency (5.27 ± 2.78 mm) and the width of the maxillary first molars for the 22 subjects in the study. **Table 6** shows the total expansion at the maxillary first molars. Significant differences were found before and after treatment with MSE appliance (5.41 ± 2.18 mm, $p < 0.001$). Significant increase in maxillary width (3.22 ± 1.63mm, $p < 0.001$) and increase in dental tipping (2.56 ± 2.65° $p < 0.001$) were also found after treatment with MSE appliance. **Tables 7** shows the average mid-palatal suture expansion (mm)

ACCEPTED MANUSCRIPT

measured at the nasal and palatal floor on the coronal CBCT slice. **Table 8** shows the average mid-palatal suture expansion (mm) measured at the anterior and posterior palatal regions on the axial section of CBCT slices. Significant greater increase in sutural expansion was found at the level of the palatal bone compared with the nasal floor (0.52±0.11mm, p<.001, **Table 9**). No significant differences were found comparing expansion at the anterior comparing to the posterior region on the axial section. **Table 10** shows significant change in total maxillary expansion and the contributions from skeletal expansion and contribution from dental expansion. The total expansion was 5.41 ± 2.18mm. The contribution by skeletal expansion or mid-palatal sutural expansion was 3.15±1.64 mm which was 59.23 % of the total expansion. The rest was contributed by dental expansion, 2.27 ± 1.25 mm which was 40.96% of the total expansion. Fifteen of the 22 patients had complete correction of the transverse maxillary deficiency and acquired excessive expansion of 1.75±1.47 mm. The overcorrection in expansion was designed to compensate for dental tipping during expansion. Five of the 22 patients had partial correction of the transverse maxillary deficiency. Although the transverse discrepancy still existed, the separation of mid-palatal suture could be observed clearly on the CBCT scan. Two of the 22 patients had less than adequate amount of expansion.

Discussion

The subjects in this study were limited to patients with transverse discrepancy of less than 10mm. This is based on the literature reporting that MARPE appliances cannot overcome such a large transverse discrepancy in adolescent patients. Secondly, although there are 3 sizes of jackscrews (8mm, 10mm, and 12mm) available for various required amount of expansion, the palatal vault of patient with more than 8mm of transverse discrepancy is often too narrow to place jack screws greater than 8mm. In situation where an MSE of greater than 8mm was needed, a second MSE might have to be used for further expansion. In the current study, there were 3 subjects with transverse discrepancy greater than 8mm, but they did not require placement of a second MSE appliance.

In most cases, patients with transverse discrepancy of less than 4mm were also excluded from the study. It has been reported that traditional RME could acquire maxillary

ACCEPTED MANUSCRIPT

expansion of 0~4mm[14] and skeletal anchorage is usually not necessary. However, patients who presented with severe crowding and obvious buccal inclination of maxillary posterior teeth were included in the study. The skeletal maxillary expansion gained with the MARPE appliance is beneficial for aligning and levelling, which may avoid extraction of premolars and the use of skeletal anchorage may reduce side effects such dental tipping[30] and alveolar bending associated with tooth borne expansion appliances.[31,32]

As for the activation protocol, the study initially followed the expansion rate referred by Carlson.[24] However, this rate turned out to be too conservative to achieve skeletal expansion. Consequently, we enhanced the expansion rate based on Carlson's method (Table 1) by shortening the follow-up interval to one week, recorded their true expansion rate every day and reported every adverse event for their safety and convenience. Using the rate shown in Table 1, all the subjects could tolerate the pain of expansion. A space between the maxillary incisors could be observed in 7 to 10 days after expansion. With the maxillary expansion, the mechanical stress generated in circummaxillary sutures increase.[33-35] Thus, the rate of expansion should be decreased after the opening of the diastema.

The use of posterior-anterior cephalogram (PAC) has been thought to be the most convenient and reliable way to diagnose transverse maxillary deficiency.[28] Vanarsdall proposed the use of PAC to diagnose skeletal transverse discrepancy.[36] However, two dimensional radiographs may not necessarily reflect the true hard tissues.[37,38] Due to the lack of a gold standard, orthodontists often diagnose transverse maxillary deficiency by clinical examination, model measurement combined with two dimensional radiographs. With the advent of CBCT, the measurements based on CBCT or reconstructed PA cephalogram were proved to be more reliable.[39,40] Besides, orthodontists could assess the situation comprehensively by observing various slices of CBCT.[41] Therefore, CBCT was used to analyze the pre- and post-treatment changes with MARPE treatment.

Before comparing the pre- and post-treatment changes, the skeletal and dental indices must first be orientated and superimposed. The pre- and post-treatment indices should be measured on the same slice. Thus, the procedure of superimposition was very important to the

ACCEPTED MANUSCRIPT

result. The most common way of superimposition was by landmarks, that is, to mark 3-7 reference points and superimpose Pre-MARPE and post -MARPE CBCT based on these points. However, recent evidence indicated that superimposition by voxel of anterior cranial base was more accurate than that by landmarks.[42] Thus, in this study, superimposition by voxel was used to decrease bias.

The skeletal indices were maxillary width and extended distance of mid-palatal suture. Reconstructed PAC showed that the average increase in maxillary width was 3.22±1.63 mm, while horizontal slice of CBCT showed the extended distance of mid-palatal suture was 3.14±1.64 mm. As mentioned previously, the value of maxillary width measured by the method of Vanarsdall would be inaccurate if the head positions of pre- and post-MARPE CBCT changed. Fortunately, the use of CBCT could avoid bias via orientation, superimposition and calibration. Consequently, the extended distance of mid-palatal suture, rather than maxillary width, was more recommended to assess the effect of skeletal expansion by MSE.

As for dental expansion, twenty of the 22 patients presented dental tipping of maxillary first molar after treatment with the MARPE appliance. The possible reasons could be that part of mechanical force generated from MSE was transmitted to the anchored teeth since MSE was a hybrid appliance. In addition, the mechanical force of MSE led not only to transverse expansion, but also to maxillary rotation. Considering that the center of rotation of the maxilla was much higher than the placement of the miniscrews, the MARPE appliance would inevitably generate torque in the two maxillae, resulting in alveolar bone bending. Even though the relative position of anchored teeth did not change in alveolar bone, “dental tipping” would still be observed because of alveolar bending. For children and adolescents whose pterygomaxillary and zygomaxillary sutures were less matured, the bone resistance of maxillary expansion was relatively less. For adult patients, the bone resistance was significantly greater, considerable part of orthopedic force would be exerted on anchored teeth, leading to both of dental tipping and alveolar bending. Due to the limited sample size, this hypothesis could not be proved in this study. Interestingly, two patients showed lingual tipping of the maxillary molars. Clinical examination showed buccinator hypertrophy, probably the buccinator muscle constricted the

ACCEPTED MANUSCRIPT

transverse expansion of maxillary first molar in MARPE treatment, leading to lingually dental tipping.

One interesting finding was that the expansion pattern of the 22 patients was not identical. In the palatal slice (horizontal plane paralleled to Frankfort plane), 15 subjects presented a parallel expansion pattern, 4 subjects presented the typical “V” expansion pattern, and 3 subjects presented a reverse “V” expansion pattern.

According to a study by Mohlhenrich et al., treatment with MARPE appliance with pterygoid plate separation often resulted in parallel expansion, while treatment with SARPE without pterygoid plate separation resulted in “V” expansion.[43] This study showed the structures resistant to maxillary expansion was not only at the zygomaxillary sutures, but also at the pterygomaxillary sutures. Thus, a typical “V” expansion pattern of mid-palatal suture might be the result of ineffective expansion near pterygomaxillary sutures, while reverse “V” expansion pattern might be the result of ineffective expansion near zygomaxillary and nasomaxillary sutures. The reason why this happens may be related to the anteroposterior position of miniscrews placement in the maxillae. Two of the patients with “V” expansion pattern presented with proclination of maxillary anterior teeth and severe crowding before MARPE treatment which may have caused a mesial movement of the molars. Since the placement of MARPE miniscrews was determined by the relative position of the molars in alveolar bone, the implanting position would be too mesial to exert orthopedic to the pterygoid maxillary efficiently. In these cases, the posterior expansion force would be less than the anterior, presenting with a typical “V” expansion pattern. On the other hand, reverse “V” expansion pattern may be a “pseudo appearance”. Due to the short time between pre-MARPE and post-MARPE CBCT, the stress generated from MSE might not have been completely expressed in the anterior region of the mid-palatal suture.

A few adverse events were reported with MARPE treatment. For the 22 patients treated with the MARPE appliance, transverse maxillary deficiency remained in 7 patients. In three young adult patients, the microimplants were inclined at an angle in the post-MARPE CBCT. There were three possible causes: the miniscrews were implanted unparalleled at the

ACCEPTED MANUSCRIPT

beginning; the relative position of miniscrews in maxillary bone changed due to the low density of maxillae; and the resistance from circummaxillary sutures of adult patients might be too high to be overcome by miniscrews, leading to the inclination of the miniscrews. In addition, more than half of the subjects reported mild to moderate pain after maxillary expansion. To avoid these adverse events, it is recommended that the region of palatal vault to be flushed with water as often as possible; strict sterilization before placement of microimplants; and parallel placement of microimplants. If MSE appliance was wrapped by soft tissue or microimplants were loose due to infection, MSE should be removed immediately, combined with application of hydrogen peroxide and saline. If patients reported moderate to severe pain, avoid continued turning of the jackscrew or slow down the rate of expansion.

Conclusions

The use of MARPE appliances such as MSE can be used to correct transverse maxillary deficiency in adolescent or young adult patients with minimal dentoalveolar side effects. A total expansion of 5.4mm can be achieved in which near 60% was contributed by skeletal expansion. More parallel expansion can be expected anteroposterioly and more expansion vertically at the palatal compared to the nasal floor.

ACCEPTED MANUSCRIPT

ACCEPTED MANUSCRIPT

References

1. Angell DH. Treatment of irregularity of the permanent or adult teeth. The Dental Cosmos, Vol 1; pg 599.

2. Haas, A.J. Rapid expansion of the maxillary dental arch and nasal cavity by opening the midpalatal suture. *Am J Orthod Dentofac Orthop.* 1961;31:73-90.

3. Braun S, Bottrel JA, Lee KG*, et al.* The biomechanics of rapid maxillary sutural expansion. *Am J Orthod Dentofac Orthop*. 2000;118:257-61.

4. Baccetti T, Franchi L, Cameron CG, Jr MNJA. Treatment timing for rapid maxillary expansion. *Angle Orthod*. 2001;71:343-50.

5. Suri L, Taneja P. Surgically assisted rapid palatal expansion: a literature review. *Am J Orthod Dentofacial Orthop*. 2008;133:290-302.

6. Ballanti F, Lione R, Fanucci E*, et al.* Immediate and post-retention effects of rapid maxillary expansion investigated by computed tomography in growing patients. *Angle Orthod*. 2009;79:24-9.

7. Kiliç N, Kiki A, Oktay H. A comparison of dentoalveolar inclination treated by two palatal expanders. *Eur J Orthod.* 2008;30:67-72.

8. Lione R, Ballanti F, Franchi L*, et al.* Treatment and posttreatment skeletal effects of rapid maxillary expansion studied with low-dose computed tomography in growing subjects. *Am J Orthod Dentofacial Orthop*. 2008;134:389-92.

9. Olmez H, Akin E, Karaçay S. Multitomographic evaluation of the dental effects of two different rapid palatal expansion appliances. *Eur J Orthod*. 2007;29:379-85.

10. Da SFO, Lara TS, Da SH, Bertoz FA. Post expansion evaluation of the midpalatal suture in children submitted to rapid palatal expansion: a CT study. *J Clin Pediatr Dent.* 2006;31:142.

11. Chung CH, Font B. Skeletal and dental changes in the sagittal, vertical, and transverse dimensions after rapid palatal expansion. *Am J Orthod Dentofacial Orthop.* 2004;126:569-75.

12. Lagravère MO, Carey J, Heo G*, et al.* Transverse, vertical, and anteroposterior changes from bone-anchored maxillary expansion vs traditional rapid maxillary expansion: a randomized clinical trial. *Am J Orthod Dentofacial Orthop.* 2010;137:304-5.

ACCEPTED MANUSCRIPT

13. Basciftci FA, Karaman AI. Effects of a modified acrylic bonded rapid maxillary expansion appliance and vertical chin cap on dentofacial structures. *Angle Orthodontist*. 2002;72:61.

14. Md R, Ad R, Abrã£O J. Skeletal alterations associated with the use of bonded rapid maxillary expansion appliance. *Braz Dent J.* 2011;22:334-9.

15. Suzuki H, Moon W, Previdente LH*, et al.* Miniscrew-assisted rapid palatal expander (MARPE): the quest for pure orthopedic movement. *Dental Press J Orthod.* 2016;21:17-23

16. Garrett B, Caruso J, K, Farrage J*, et al.* Skeletal effects to the maxilla after rapid maxillary expansion assessed with cone-beam computed tomography. *Am J Orthod Dentofacial Orthop.* 2008;134:8.

17. Kapila S. Cone beam computed tomography in orthodontics: Indications, insights, and innovations. *Am J Orthod Dentofacial Orthop.* 2016;149:583.

18. The Surgery of Oral and Facial Diseases and Malformations: Their Diagnosis and Treatment Including Plastic Surgical Reconstruction. *Journal of the American Medical Association.* 1939;112:2199.

19. Pogrel MA, Kaban LB, Vargervik K, Baumrind S. Surgically assisted rapid maxillary expansion in adults. *Int J Adult Orthodon Orthognath Surg.* 1992;7:37-41.

20. Asscherickx K, Govaerts E, Aerts J, Vande VB. Maxillary changes with bone-borne surgically assisted rapid palatal expansion: A prospective study. *Am J Orthod Dentofacial Orthop.* 2016;149:374-83.

21. Williams BJ, Currimbhoy S, Silva A, O'Ryan FS. Complications following surgically assisted rapid palatal expansion: a retrospective cohort study. *J Oral Maxillofac Surg.* 2012;70:2394-402.

22. Ludwig B, Baumgaertel S, Zorkun B*, et al.* Application of a new viscoelastic finite element method model and analysis of miniscrew-supported hybrid hyrax treatment. *Am J Orthod Dentofacial Orthop.* 2013;143:426-35.

23. Lin L, Ahn HW, Kim SJ*, et al.* Tooth-borne vs bone-borne rapid maxillary expanders in late adolescence. *Angle Orthod.* 2015;85:253-62.

24. Carlson C, Sung J, Mccomb RW*, et al.* Microimplant-assisted rapid palatal expansion appliance to orthopedically correct transverse maxillary deficiency in an adult. *Am J Orthod Dentofacial Orthop*. 2016;149:716-28.

ACCEPTED MANUSCRIPT

25. Cunha ACD, Lee H, Nojima LI*, et al.* Miniscrew-assisted rapid palatal expansion for managing arch perimeter in an adult patient. *Dental Press J Orthod*. 2017;22:97-108.

26. Choi SH, Shi KK, Cha JY*, et al.* Nonsurgical miniscrew-assisted rapid maxillary expansion results in acceptable stability in young adults. *Angle Orthod*. 2016;86:713-20.

27. Park JJ, Park YC, Lee KJ*, et al.* Skeletal and dentoalveolar changes after miniscrew-assisted rapid palatal expansion in young adults: A cone-beam computed tomography study. *Korean J Orthod*. 2017;47:77-86.

28. Betts NJ, Vanarsdall RL, Barber HD*, et al.* Diagnosis and treatment of transverse maxillary deficiency. *Int J Adult Orthodon Orthognath Surg.* 1995;10:75-96.

29. Ngan P, Nguyen U, Tremont T, Nguyen T, Martin CA. Skeletal, dentoalveolar and periodontal changes of skeletally matured patients with maxillary deficiency treated with microimplant assisted rapid palatal expansion appliance: A pilot study. *AOS Trends in Orthodontics*. 2018;8(2):71-85.

30. Park JH, Tai K, Owtad P. 3-Dimensional cone-beam computed tomography superimposition: a review. *Seminars in Orthodontics.* 2015;21:263-73.

31. McNamara JA Jr, Franchi L. The cervical vertebral maturation method: A user's guide. *Angle Orthodontist.* 2018;88:133.

32. Wertz RA. Skeletal and dental changes accompanying rapid midpalatal suture opening. *American Journal of Orthodontics.* 1970;58:41-66.

33. Haas AJ. Palatal expansion: just the beginning of dentofacial orthopedics. *Am J Orthod.* 1970;57:219-255.

34. Ciambotti C, Ngan P, Durkee M*, et al.* A comparison of dental and dentoalveolar changes between rapid palatal expansion and nickel-titanium palatal expansion appliances. *Am J Orthod Dentofacial Orthop*. 2001;119:11-20.

35. Carlson C, Sung J, McComb RW*, et al.* Microimplant-assisted rapid palatal expansion appliance to orthopedically correct transverse maxillary deficiency in an adult. *Am J Orthod Dentofacial Orthop*. 2016;149:716-28.

36. Provatidis C, Georgiopoulos B, Kotinas A, Macdonald JP. In vitro validated finite element method model for a human skull and related craniofacial effects during rapid maxillary expansion. *Proc Inst Mech Eng H.* 2006;220:897-907.

37. Provatidis C, Georgiopoulos B, Kotinas A, Mcdonald JP. On the FEM modeling of

ACCEPTED MANUSCRIPT

craniofacial changes during rapid maxillary expansion. *Medical Engineering & Physics.* 2007;29:566-79.

38. Jafari A, Shetty KS, Kumar M. Study of stress distribution and displacement of various craniofacial structures following application of transverse orthopedic forces--a three-dimensional FEM study. *Angle Orthod.* 2003;73:12-20.

39. Jr VR. Transverse dimension and long-term stability. *Semin Orthod.* 1999;5:171-80.

40. Malkoc S, Sari Z, Usumez S, Koyuturk AE. The effect of head rotation on cephalometric radiographs. *Eur J Orthod.* 2005;27:315-21.

41. Leonardi R, Annunziata A, Caltabiano M. Landmark identification error in posteroanterior cephalometric radiography. A systematic review. *Angle Orthod.* 2008;78:761-5.

42. Nur M, Kayipmaz S, Bayram M*, et al.* Conventional frontal radiographs compared with frontal radiographs obtained from cone beam computed tomography. *Angle Orthod.* 2012;82:579-84.

43. Mohlhenrich SC, Modabber A, Kamal M*, et al.* Three-dimensional effects of pterygomaxillary disconnection during surgically assisted rapid palatal expansion: a cadaveric study. *Oral Surg Oral Med Oral Pathol Oral Radiol.* 2016;121:602-8.

ACCEPTED MANUSCRIPT

ACCEPTED MANUSCRIPT

Figure 1: A The Microimplant Skeletal Expander (MSE) appliance; **B** The diameter of the microimplants were 1.8mm and the length varied from 8 to 12 mm depending on the thickness of the palatal and nasal floor; **C** A wrench was used for activation, expanding 0.4mm for every 3 turns

Figure 2: The jackscrew was placed as posteriorly as possible to maximize the orthopedic effects to the pterygoid plates but not to exceed the palatal process.

Figure 3: A Frankfort plane; **B** Coronal plane; **C** and **D**, mid-sagittal plane.

Figure 4: JR, intersection of contour of right maxillary tuberosity and right zygomaxillary
JL, intersection of contour of right maxillary tuberosity and right zygomaxillary
AG and GA are right and left mandibular angle notch respectively

Figure 5: The selection range used for superimposition by voxel

Figure 6: Pre-treatment CBCT: Grey and white; post-treatment CBCT: Cerulean

Figure 7: In the coronal slice: **A**, pre-MARPE distance between mesiolingual cusps of maxillary first molars; **B**, pre-MARPE distance between mesiolingual cusps of maxillary first molars.

Figure 8: In the coronal slice: A, pre-MARPE torque; B and C, pre-MARPE torque.

Figure 9: Anterior and posterior extended distance

Figure 10: A "V" pattern; **B** paralleled pattern; **C** reverse "V" pattern

Figure 11: Coronal cross-sectional slice through the center of Maxillary first molar

Figure 12: Horizontal expansion: nasal and palatal floor

ACCEPTED MANUSCRIPT

Table 1: Recommended expansion rate for patients of different ages

Age(year)	Rate(turn/day)	
	initial	after opening of the
13	2	2
13~15	2~3	2
16~17	3	2
≥18	3~4	2~3

ACCEPTED MANUSCRIPT

Table 2: Definition of landmarks and reference planes

Landmarks and reference planes	Definition
Nasion	anterior point on nasofrontal suture
Sella	central point in Sella turcica
Basion	anterior point of foramen magnum
Porion	superior point on external auditory canal
Orbit	The inferior point on orbit
ANS	Anterior nasal spine
PNS	Posterior nasal spine
Horizontal plane	Frankfort plane (FH plane) Or(left)-Po-Or(right)
Mid-Sagittal plane	Perpendicular to the FH plane, and pass the
Coronal plane	Perpendicular to the FH and sagittal plane

ACCEPTED MANUSCRIPT

ACCEPTED MANUSCRIPT

Table 3: The selection range of anterior cranial base

Selection boundary	
Superior(mid-sagittal)	Superior border of ethmoid sinus
Anterior(mid-sagittal)	Posterior border of frontal sinus
Exterior(horizontal)	Internal ethmoid sinus

ACCEPTED MANUSCRIPT

Table 4: Intra-Class correlation coefficient between first and second measurements.

Parameter	Intra-class correlation coefficient
Pre-treatment maxillary width	**0.987**
Post-treatment maxillary width	**0.983**
Pre-treatment maxillary molar width	**0.945**
Post-treatment maxillary molar width	**0.957**
Pre-treatment Torque of right maxillary first molar	**0.963**
Pre-treatment Torque of left maxillary first molar	**0.978**
Post-treatment Torque of right maxillary first molar	**0.976**
Post-treatment Torque of left maxillary first molar	**0.987**

ACCEPTED MANUSCRIPT

Table 5: Maxillary transverse discrepancy and width of maxillary molars for all subjects (n=22)

	Mean	**SD**
Age (yr)	14.97	6.16
Transverse discrepancy (mm)	5.27	2.78
Maxillary molar width (mm)	40.00	3.72

ACCEPTED MANUSCRIPT

Table 6: Skeletal and dental changes before and after treatment with the MSE appliance (N=22)

	Before			After		P value
	Mean	SD		Mean	SD	
Total expansion (mm)	66.35	6.29		70.65	8.14	0.00**
Maxillary molar width	40.00	3.72		45.40	4.25	0.00**
Torque of right	99.57	5.06		101.90	5.06	0.00**
Torque of left	100.01	5.79		102.64	7.71	0.00**

**P＜0.01. * P＜0.05.

ACCEPTED MANUSCRIPT

Table 7: Average mid-palatal suture expansion (mm) measured at the nasal and palatal floor on the coronal section of CBCT slices.

Position	T	N	Mean±SD	Maximum	Minimum
Nasal	**T1**	**22**	**0**	**0**	**0**
	T2	**22**	**2.82±1.54**	**5.90**	**0.40**
	T2-T1	**22**	**2.82±1.54**	**5.90**	**0.40**
Palatal	**T1**	**22**	**0**	**0**	**0**
	T2	**22**	**3.34±1.75**	**6.75**	**0.30**
	T2-T1	**22**	**3.34±1.75**	**6.75**	**0.30**

ACCEPTED MANUSCRIPT

Table 8: Average mid-palatal suture expansion (mm) measured at the anterior and posterior palatal regions on the axial section of CBCT slices.

Position	T	N	Mean±SD	Maximum	Minimum
Anterior	**T1**	**22**	**0**	**0**	**0**
	T2	**22**	**3.07±1.57**	**5.40**	**0.10**
	T2-T1	**22**	**3.07±1.57**	**5.40**	**0.10**
Posterior	**T1**	**22**	**0**	**0**	**0**
	T2	**22**	**3.28±1.68**	**6.30**	**0.10**
	T2-T1	**22**	**3.28±1.68**	**6.30**	**0.10**

ACCEPTED MANUSCRIPT

ACCEPTED MANUSCRIPT

Table 9: Matched-paired *t*-test comparing vertical expansion at the palatal and nasal floor and the horizontal sutural separation at the anterior and posterior regions.

		n	Mean±SD	Difference	P	Significance
Vertical	Nasal	22	2.82±1.54	-0.52±0.11	0.000	***
	Palatal	22	3.34±1.75			
Horizontal	Anterior	22	3.07±1.57	-0.21±0.11	0.075	NS
	Posterior	22	3.28±1.68			

ACCEPTED MANUSCRIPT

ACCEPTED MANUSCRIPT

Table 10: Skeletal and dental attribution to acquired total maxillary expansion

	Total (mm)			Skeletal (mm)			Dental (mm)	
	Mean	SD		Mean	SD		Mean	SD
Expansion	5.41	2.18		3.15	1.64		2.27	1.25
Percentage	100.00%	0.00%		59.23%	17.75%		40.96%	17.40%

ACCEPTED MANUSCRIPT

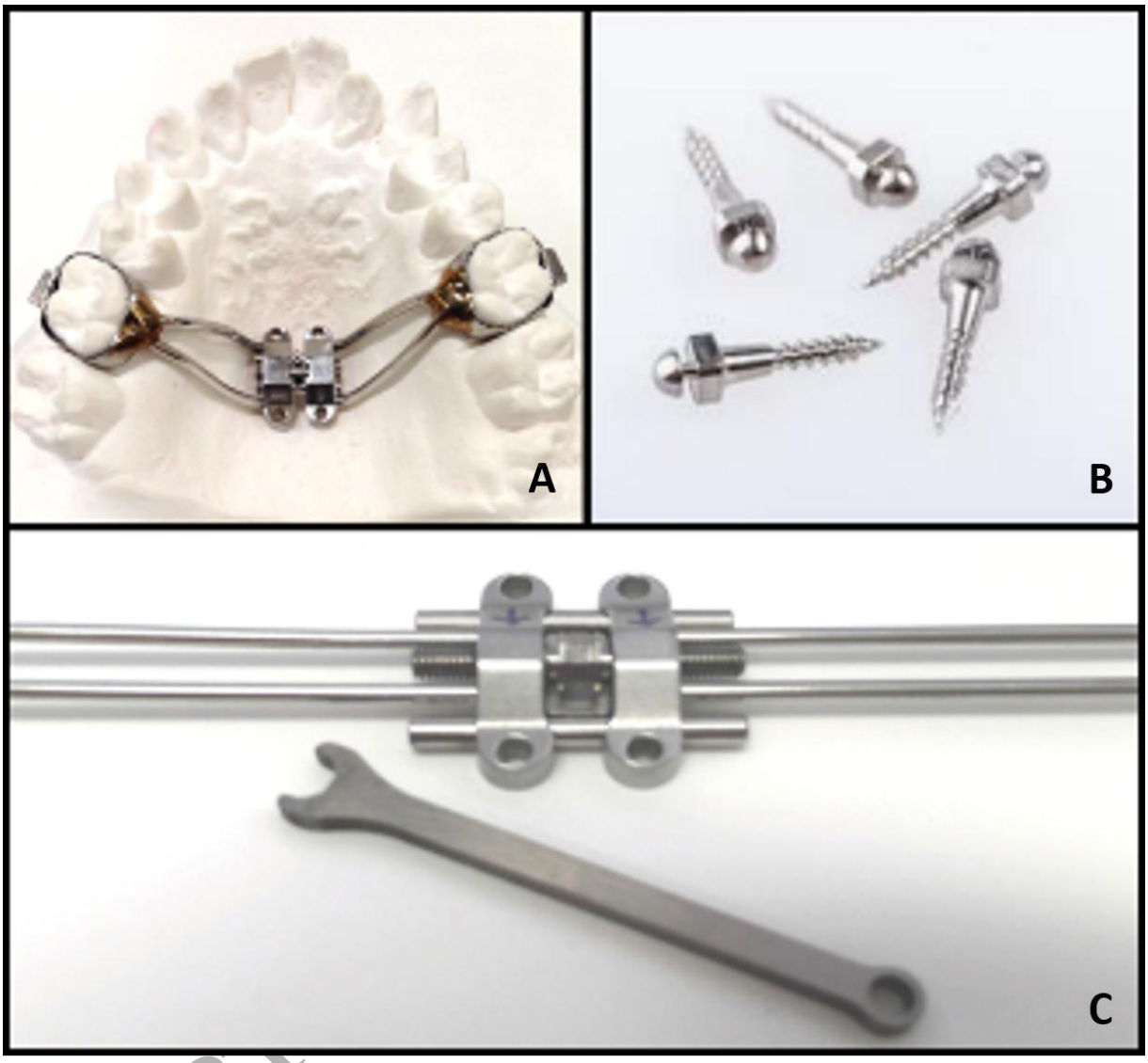

ACCEPTED MANUSCRIPT

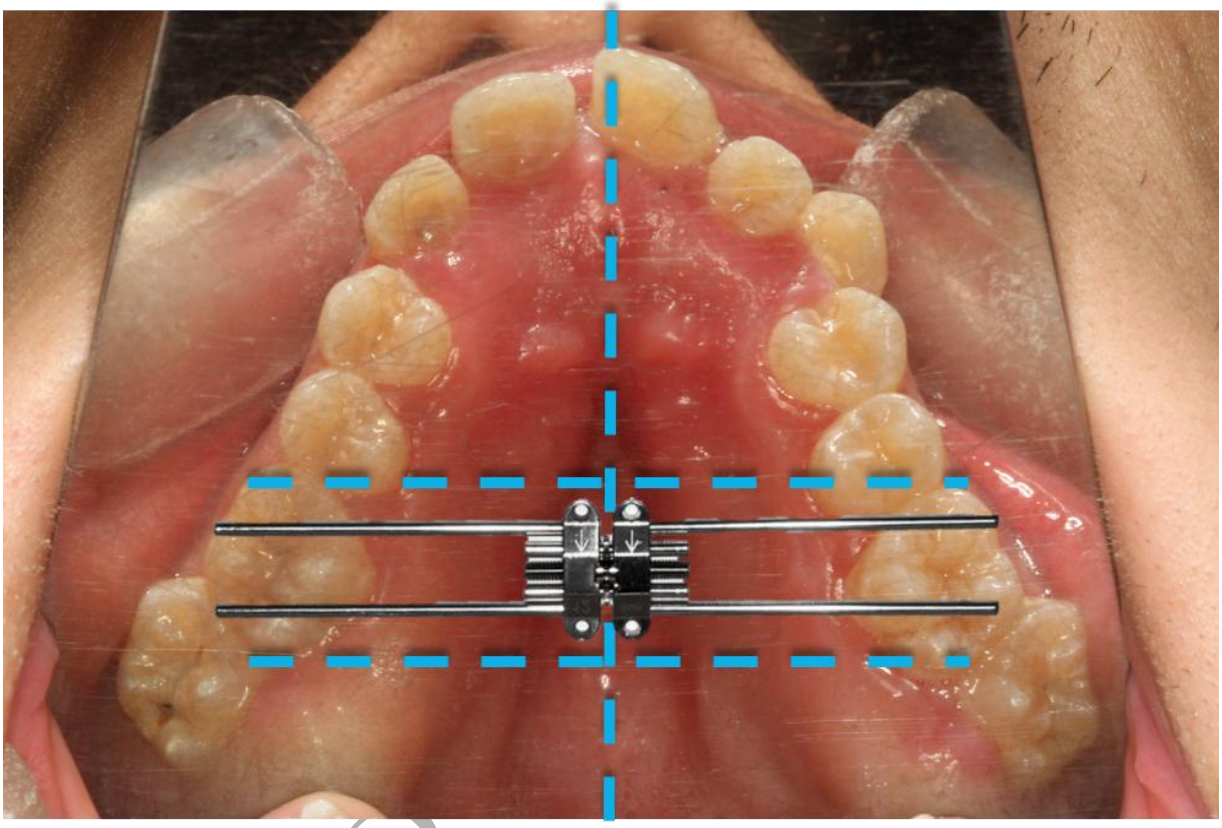

ACCEPTED

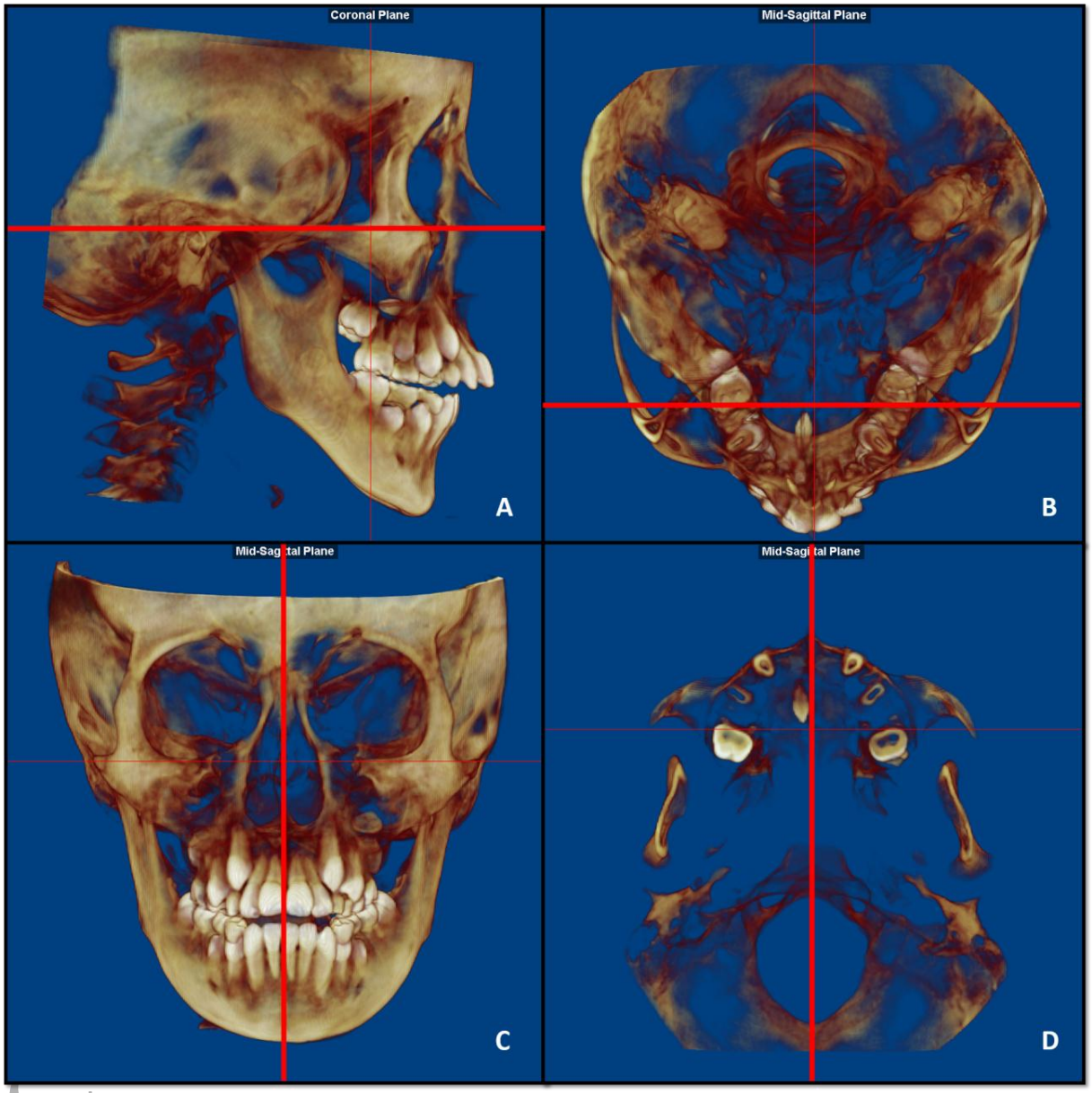
Coronal Plane
A
Mid-Sagittal Plane
B
Mid-Sagittal Plane
C
Mid-Sagittal Plane
D

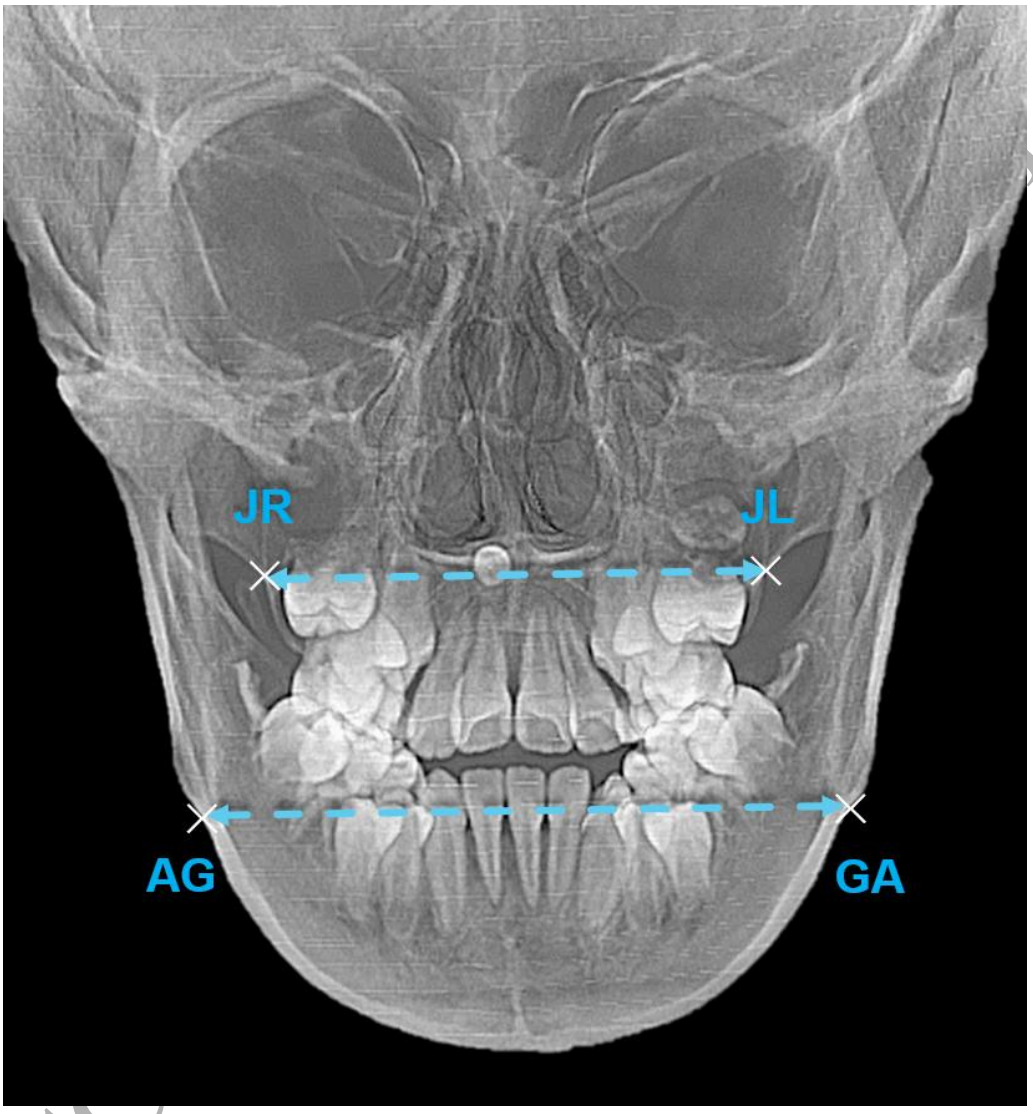
JR
JL
AG
GA

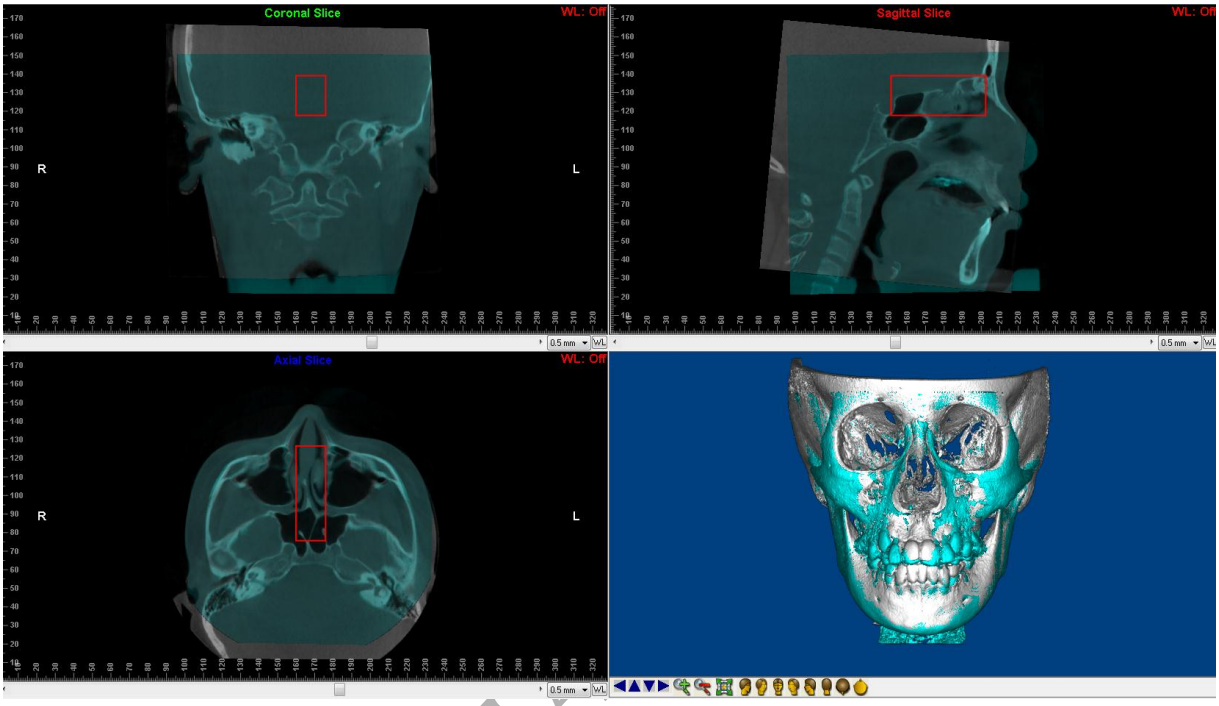

ACCEPTED MANUSCRIPT

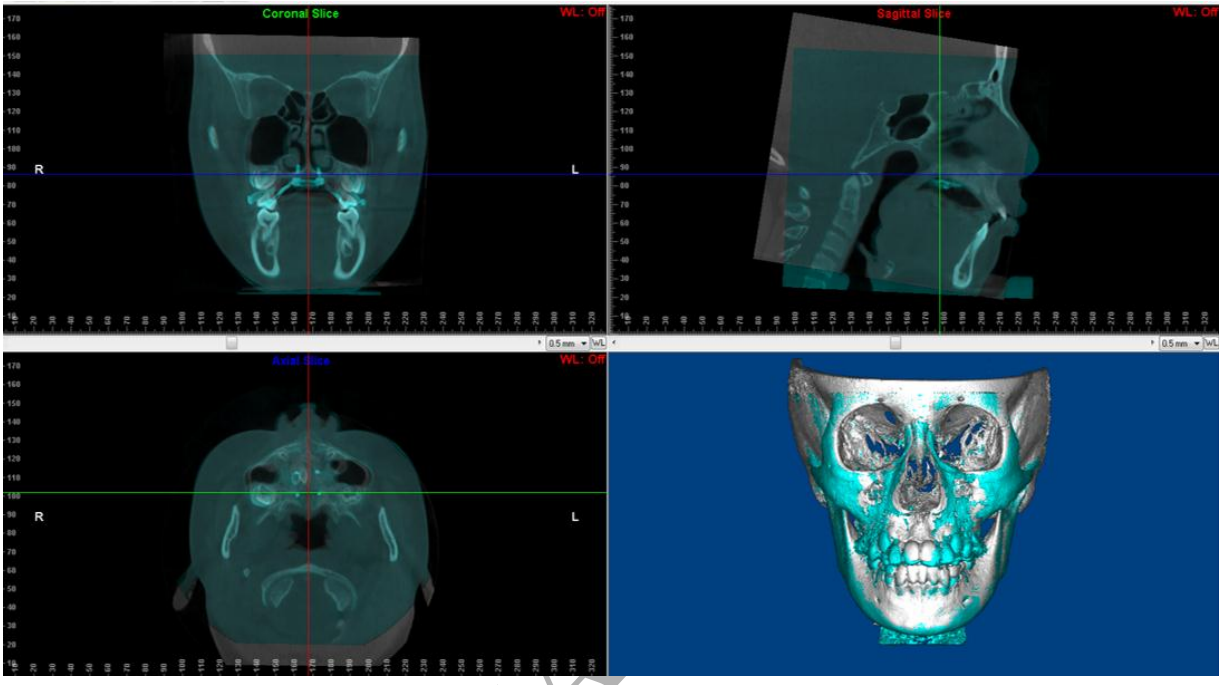

ACCEPTED MANUSCRIPT

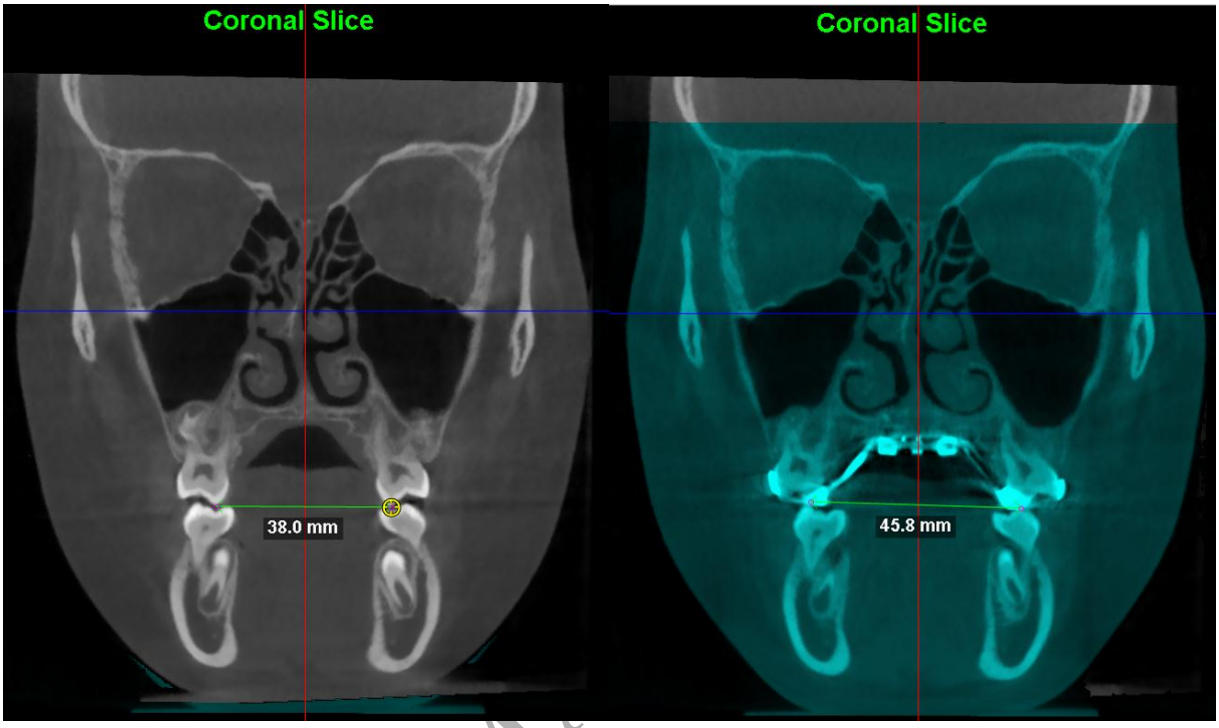

ACCEPTED MANUSCRIPT

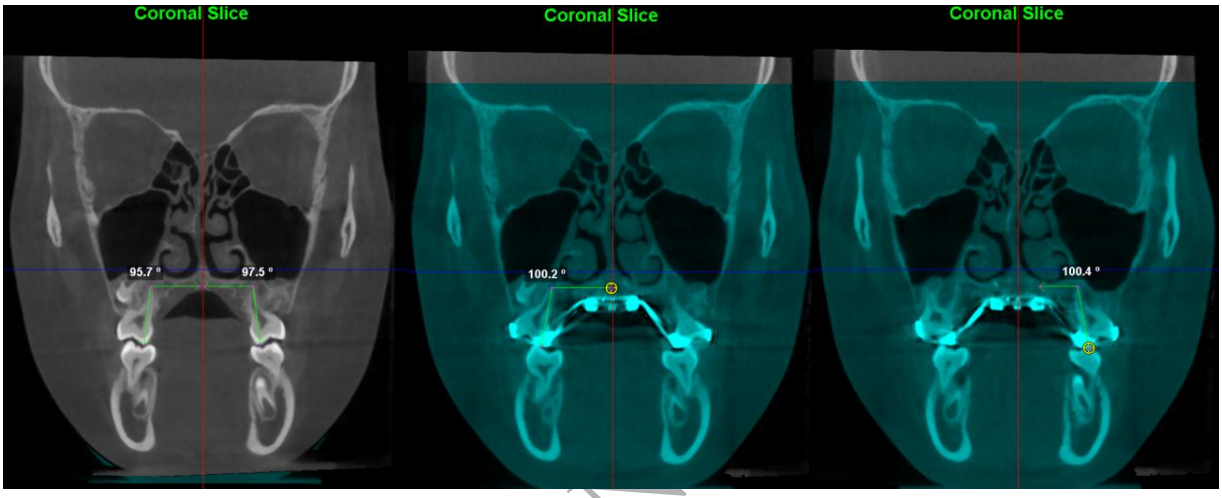

ACCEPTED MANUSCRIPT

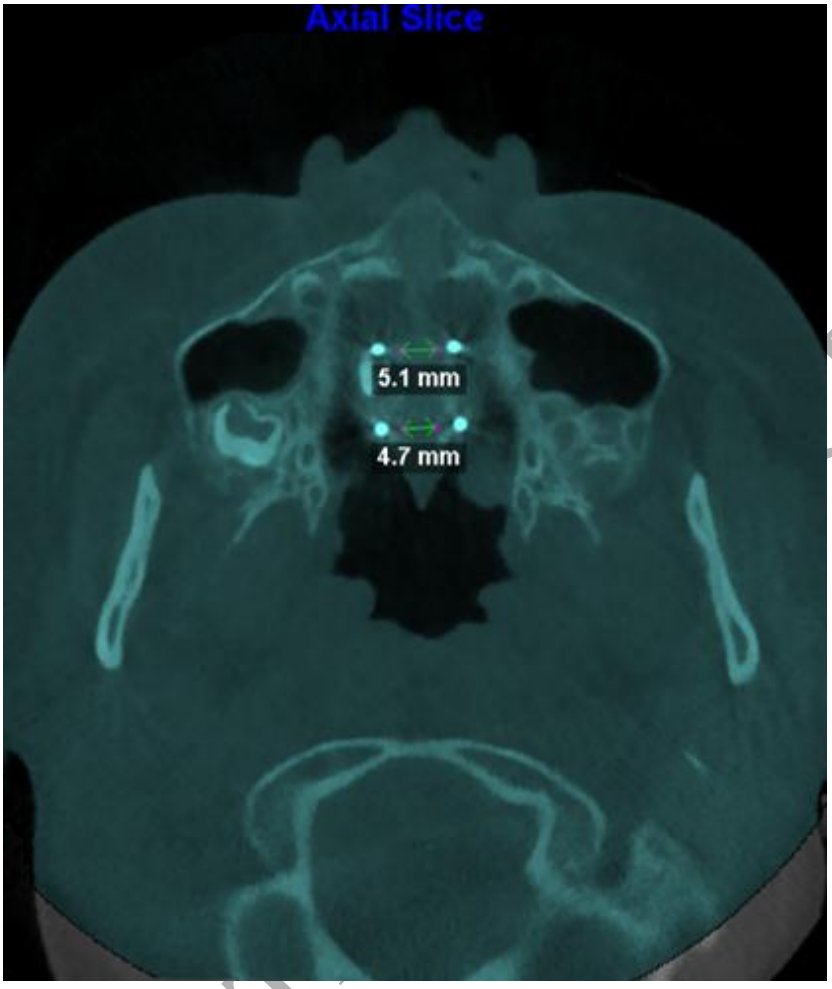

ACCEPTED MANUSCRIPT

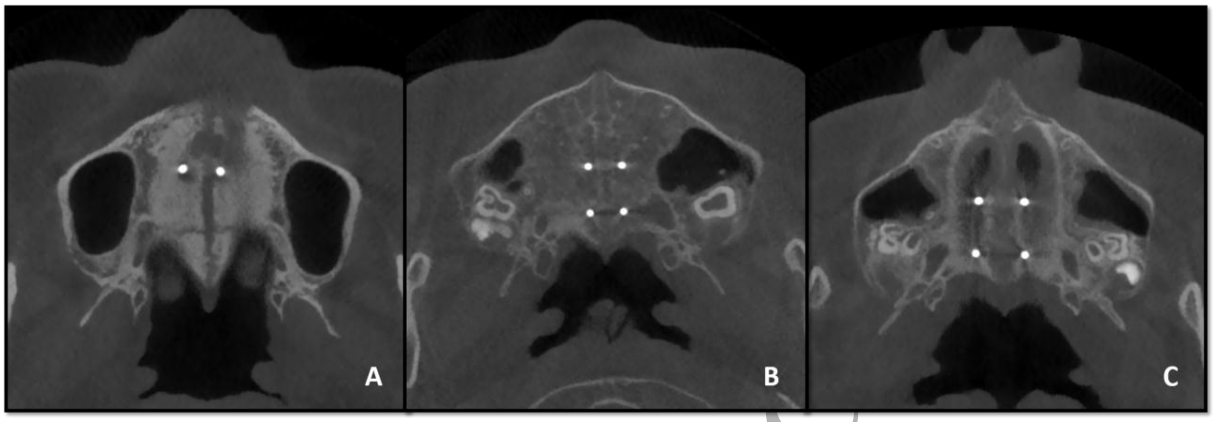

ACCEPTED MANUSCRIPT

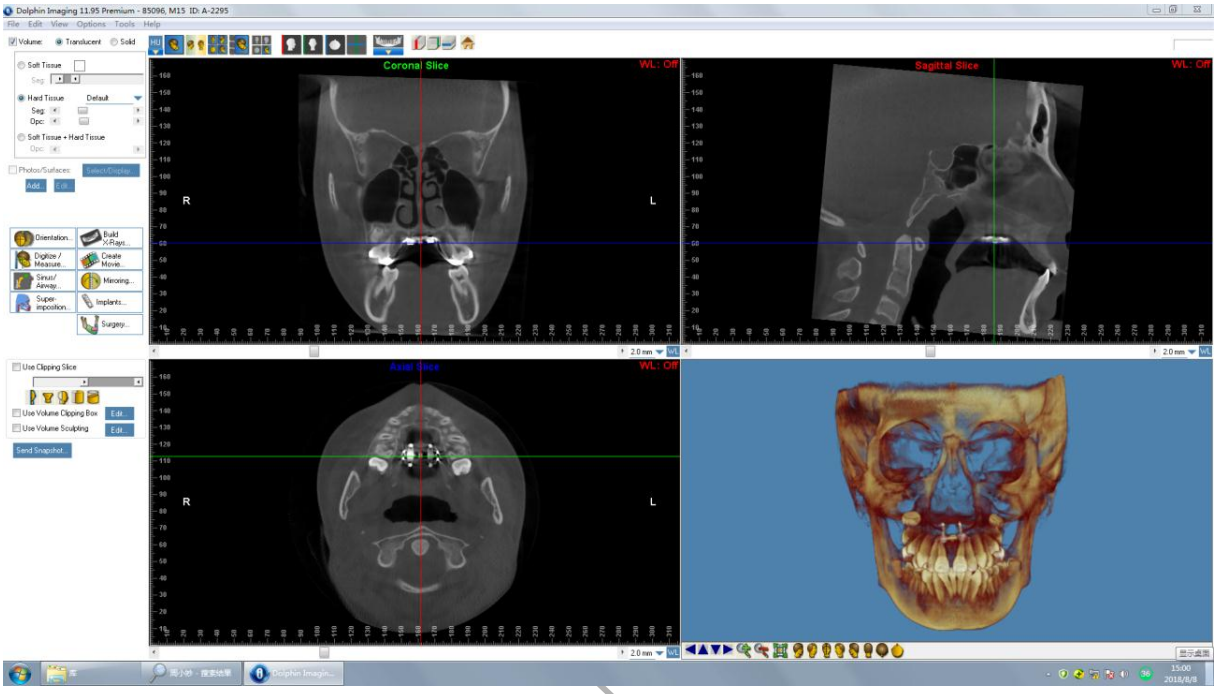

ACCEPTED MANUSCRIPT

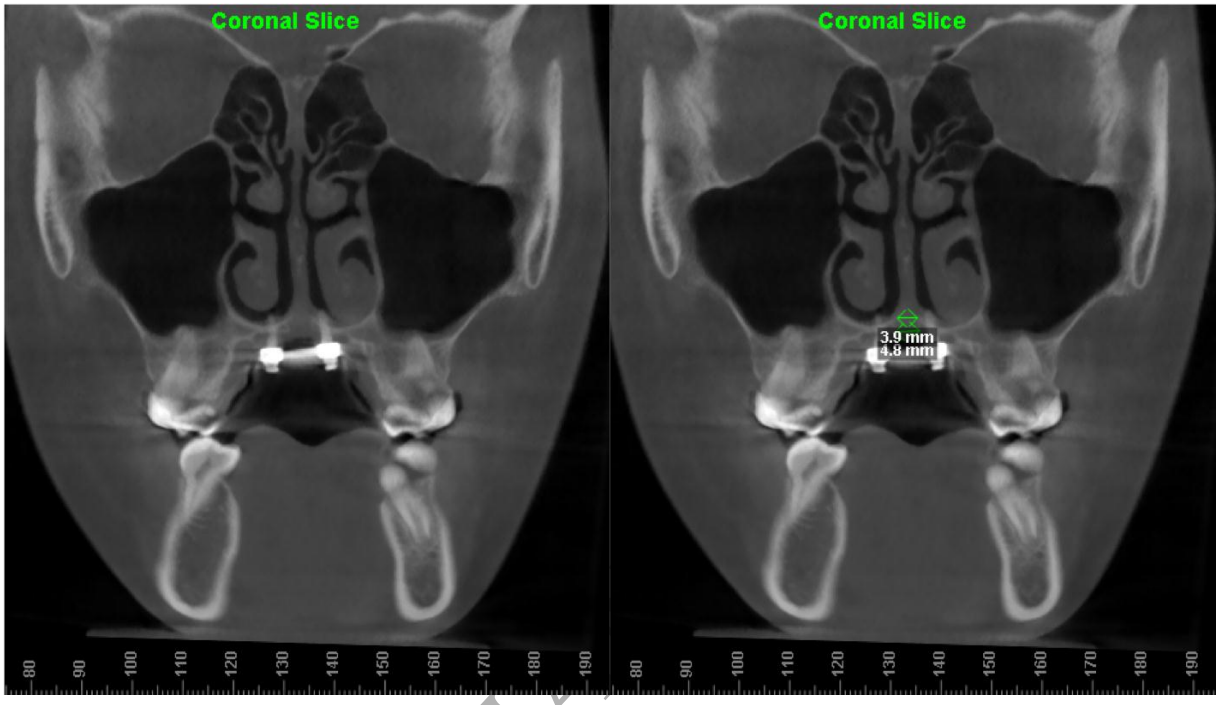

ACCEPTED MANUSCRIPT