KU Leuven
Groep Biomedische Wetenschappen
Faculteit Geneeskunde
Departement Cardiovasculaire Wetenschappen

KU LEUVEN

DOCTORAL SCHOOL
BIOMEDICAL SCIENCES

TIMING OF PULMONARY VALVE REPLACEMENT IN TETRALOGY OF FALLOT

Bjorn Cools

Jury:

Promotor:	Prof. Dr. M. Gewillig
Copromotor:	Prof. Dr. F. Rega
	Prof. Dr. P. Claus
Voorzitter	Prof. Dr. K. Freson
Juryleden:	Prof. Dr. L. Søndergaard
	Prof. Dr. S. Qureshi
	Prof. Dr. W. Budts
	Prof. Dr. B. Meyns

Proefschrift voorgedragen tot het behalen van de graad van Doctor in de Biomedische Wetenschappen

KU Leuven
Biomedical Sciences Group
Faculty of Medicine
Department of Cardiovascular Sciences

KU LEUVEN

DOCTORAL SCHOOL
BIOMEDICAL SCIENCES

TIMING OF PULMONARY VALVE REPLACEMENT IN TETRALOGY OF FALLOT

Bjorn Cools

Jury:

Promotor:	Prof. Dr. Gewillig
Co-promotor:	Prof. Dr. F. Rega
	Prof. Dr. P. Claus
Chair	Prof. Dr. K. Freson
Jury members	Prof. Dr. L. Søndergaard
	Prof. Dr. S. Qureshi
	Prof. Dr. W. Budts
	Prof. Dr. B. Meyns

Dissertation presented in partial fulfilment of the requirements for the degree of Doctor in Biomedical Sciences

TABLE OF CONTENTS

TABLE OF CONTENTS **1**

LIST OF ABBREVIATIONS **3**

INTRODUCTION AND AIMS **5**

INTRODUCTION **5**
1.1 Etiology 7
1.2 Pathophysiology 8
1.3 Overall survival 8
1.4 Treatment 9
1.5 Residual lesions and long-term risks 11
1.6 Underlying pathophysiology 14
1.7 Reintervention for residual lesions 16
1.8 Conclusion 19

AIMS **21**

RESEARCH WORK **25**
CHAPTER 1: Feasibility of percutaneous pulmonary valve implantation The durability of implanted valves and the morbidity and mortality of the technique. **27**
1.1 Abstract 29
1.2 Introduction 30
1.3 Patients and methods 30
1.4 Results 31
1.5 Discussion 36
1.6 Conclusion 40
1.7 Supplement 42

CHAPTER 2: Feasibility and safety of pre-stenting followed by percutaneous pulmonary valve implantation in patients with TOF with dilated RVOT and severe PR **43**
2.1 Abstract 45
2.2 Introduction 46
2.3 Patients and methods 46
2.4 Results 52
2.5 Discussion 55
2.6 Conclusion 57

CHAPTER 3: The resistance to deformation of stents and combination of stents and risk of corrosion **61**
3.1 Abstract 63
3.2 Introduction 64
3.3 Materials and methods 65
3.4 Results 68

3.5 Discussion 70
3.6 Conclusion 72
3.7 Supplement 75

CHAPTER 4: The creation of an animal model with pulmonary valve regurgitation and RV volume overload 77
4.1 Abstract 79
4.2 Introduction 80
4.3 Materials and Methods 81
4.4 Results 84
4.5 Discussion 85
4.6 Conclusion 87

CHAPTER 5: RV remodeling and reverse remodeling after PVR in an ovine TOF model 91
5.1 Abstract 93
5.2 Introduction 95
5.3 Materials and Methods 96
5.4 Results 101
5.5 Discussion 105
5.6 Conclusion 110

GENERAL DISCUSSION 117

Background 119

1. Feasibility of percutaneous pulmonary valve replacement
   The durability of implanted valves and the morbidity
   and mortality of the technique 119
2. Feasibility and safety of pre-stenting followed by PVR
   in patients with TOF with dilated RVOT and severe PR 120

3.1 Resistance of stents and combinations of stents to deformation 121
3.2 Risk of corrosion 121
4. The creation of an animal model with severe PR and RV volume overload 122
5. RV remodelling due to severe PR and reverse remodelling after PVR
   in an ovine TOF model 122

FUTURE PERSPECTIVES 125
REFERENCES 129
SUMMARY 141
ACKNOWLEDGEMENTS AND CONFLICTS OF INTEREST 147
DANKWOORD 151
CURRICULUM VITAE AND LIST OP PUBLICATIONS 157

LIST OF ABBREVIATIONS

α SMA	Alpha-smooth muscle cell actin
ACC	American College of Cardiology
AHA	American Heart Association
BIB	Balloon-in-balloon
BSA	Body surface area
BT	Blalock Taussig
CIED	Cardiac implantable electronic device
CMR	Cardiac magnetic resonance
CPR	Cardiopulmonary resuscitation
CP-stent	Cheatham-Platinum
Δ	Delta of change
ECG	Electrocardiogram
ECMO	Extracorporeal Membrane Oxygenation
ECV	Extracellular volume
ESC	European Society Cardiology
Fr	French
ICD	Implantable cardiac defibrillator
IE	Infective endocarditis
INDICATOR	International Multicenter Tetralogy of Fallot Registry
J	Joule
LGE	Late Gadolinium Enhancement
LV	Left ventricle
LVAD	Left ventricular assist device
MRI	Magnetic Resonance Imaging
NYHA	New York Heart Association
OCP	Open Circuit Corrosion Potential
PA	Pulmonary artery
PICP	Propeptide of procollagen type I
PPVI	Percutaneous Pulmonary Valve Intervention
PPVR	Percutaneous pulmonary valve Replacement
PR	Pulmonary regurgitation
PS	Pulmonary stenosis
PTFE	Polytetrafluoroethylene
PTP	Peak-to-Peak
PVR	Pulmonary Valve Replacement
RBBB	Right bundle branch block
ROS	Reactive oxygen species
RV	Right ventricle
RVEDV(i)	Right Ventricular End Diastolic Volume (i) indexed for body surface area
RVESV(i)	Right Ventricular End Systolic Volume (i) indexed for body surface area
RVOT	Right ventricular outflow tract
RVOTO	Right Ventricular outflow tract obstruction
SBE	Subacute Bacterial Endocarditis
SCD	Sudden Cardiac Death
T1	Magnetic resonance technique (timing of radiofrequency pulse sequence)
TAP	Transannular patch
TOF	Tetralogy of Fallot
TPV	Transcatheter Pulmonary Valve
TR	Tricuspid regurgitation

VF	Ventricular fibrillation
Vmax	Maximum flow velocity
VO2 max	Maximum rate of oxygen consumption
VSD	Ventricular septal defect
VT	Ventricular tachycardia
WGA	Wheat Germ Agglutinin

INTRODUCTION

1. INTRODUCTION

Tetralogy of Fallot (TOF) is a congenital cardiac disease named after the French physician Etienne-Louis Arthur Fallot. The condition was first described by Niels Stensen back in 1671. Etienne-Louis Arthur Fallot detailed the four cardinal characteristics of this cyanotic cardiac disease back in 1888: 1. the pulmonary stenosis, 2. the ventricular septal defect (VSD), 3. the aortic root overriding the VSD and 4. the hypertrophy of the right ventricle. This lesion occurs in 3/10.000 live births and accounts for 7-10% of all congenital cardiac malformations.(1)

1.1. Etiology

The cause of this congenital cardiac disease is multifactorial. Environmental and/or genetic factors play a role in the development.(2) TOF is a well-recognized feature in some chromosomal anomalies like trisomy 21, 18 and 13 as well as in the microdeletion syndrome 22q11.2. Mutations in the following genes have sporadically been identified: JAG1, NOTCH2, NKX2-5, ZFPM2, FOXC2 GDF1, GATA4, TBX5 and TBX1.(2) Besides the chromosomal defects there are reports were TOF is associated with untreated maternal diabetes, phenylketonuria and intake of retinoic acid.(1)

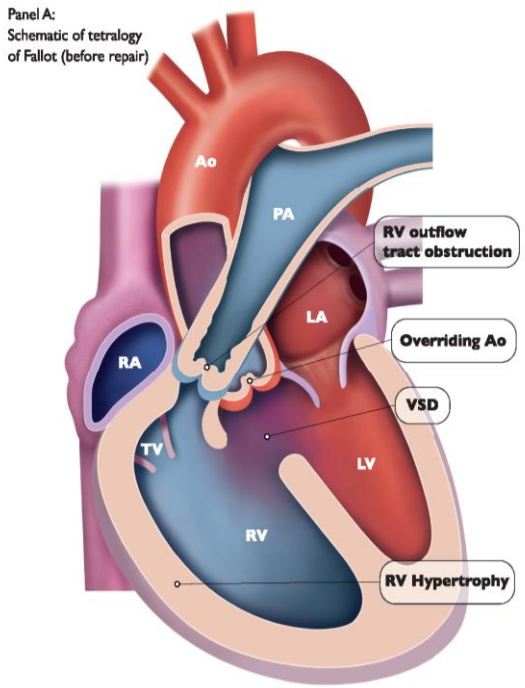

Fig. 1. Anatomical drawing showing the four cardinal features of tetralogy of Fallot. The ventricular septal defect, the override of the aortic root, the subpulmonary and pulmonary stenosis and the RV hypertrophy. VSD ventricular septal defect, Ao aorta, RV right ventricle. Baumgartner H. *et al*. Eur Heart J 2020 (3) Reprint with permission of Oxford University Press.

1.2. **Pathophysiology**

The embryological basis of the lesions in TOF is related to antero-cephalad deviation of the outlet ventricular septum. The deviation of the muscular outlet septum creates a malalignment VSD resulting in overriding of the aortic root. The deviation of the septum together with the septoparietal trabeculations that encircle the subpulmonary outflow tract create the stenosis of the right ventricular outflow tract (RVOT). The RVOT stenosis and large VSD results in systemic RV pressure leading to hypertrophy of the right ventricle.(4,5) The RVOT obstruction can occur at different levels. There is a variable dynamic sub-pulmonary stenosis due to the deviation of the infundibular septum and muscular bands. The pulmonary valve may be hypoplastic or atretic, and often the pulmonary trunk and arteries are also diminutive in variable degrees.

At birth the severity of cyanosis is related to the degree of obstruction of the blood flow to the lungs.(1) Some patients with TOF will develop hypercyanotic episodes (spells) characterized by a sudden decrease in oxygen saturation. The spells can start within weeks after birth. These can be precipitated by factors such as dehydration or agitation. These spells are attributable to acute subpulmonary obstruction and in severe cases collapse and even death can ensue. Without palliative surgery or repair, the majority of patients with TOF will not reach adulthood with an average life expectancy of approximately 12 years. Less than 3% of unoperated patients survive beyond the age of 40 years.(6)

1.3. **Overall Survival**

The overall survival following TOF repair improved significantly in the last decades. Before 1980, the surgical approach consisted of a 2-staged repair; a Blalock-Taussig (BT) or a Waterston shunt in the first year of life followed by surgical repair around the age of 4-5 years. The postoperative mortality reported in that era was 2.5% at the shunt stage and 3.6% for combined shunt and corrective surgery.(7) In the 80s' most centers changed their strategy to a single stage repair. The actual postoperative mortality for a complete repair ranges from 1.1 % to 3.7 %.(8–11)

Although the long-term survival of TOF patients has improved, it remains reduced.(12) Karamlou *et al* presented the long-term survival of different interventional era's. Of patients who were admitted around 1950, less than 50% survived the subsequent twenty years. With improved techniques in the era of 1980 survival at 20 years increased to 80%, and to over 90% from 1990 and onwards.(8) A recent report of long-term follow-up of 453 patients after transatrial-transpulmonary repair showed 93 % survival 30 years after surgery.(13) The overall survival of 645 patients with repaired TOF followed at our institution (University Hospitals Leuven) was 90.9% at the age of 40 years. The overall survival of TOF patients is lower compared to the survival of the general Belgian population (Fig 2).

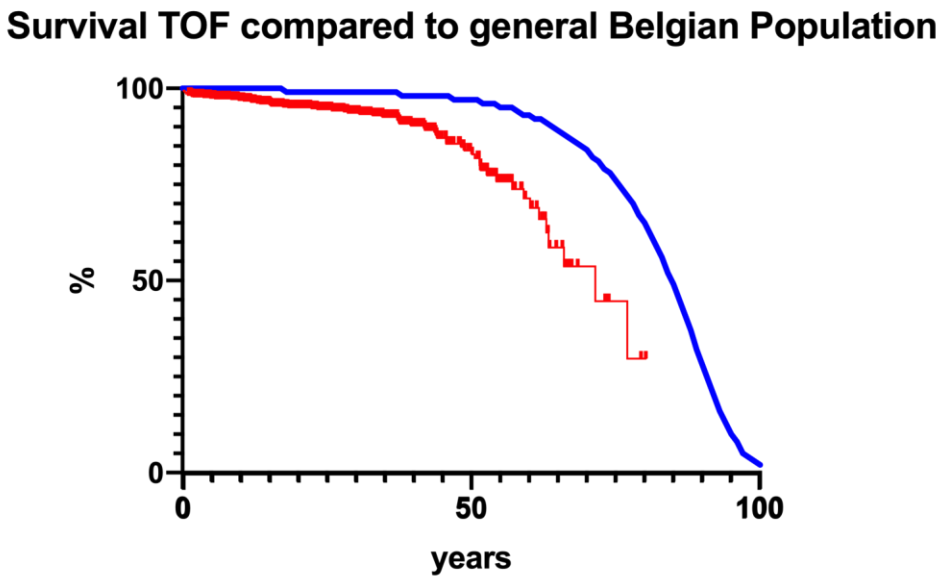

Figure 2 Kaplan-Meier showing the general survival of TOF patients who underwent TOF repair at the University Hospitals Leuven from 1960 until 2020 (color red) compared to the survival of the general Belgian population (color blue) (Data source of the survival of the general Belgian population is Statbel General Statistics Belgium 2019)

1.4. Treatment

The surgical treatment era of patients with tetralogy of Fallot started in 1944 with Alfred Blalock, Helen Taussig and Vivian Thomas at the John Hopkins institute in the United States (US). In 1939 Blalock and Levy reported experiments in dogs in which they anastomosed the left subclavian artery to the left pulmonary artery.(14,15) The first operation in patients with TOF was performed In 1944. This was followed with a detailed description of the operations on the first 3 children in 1945 by Blalock and Taussig. In one patient the subclavian artery and in the other 2 cases the innominate artery was used to create a systemic-to-pulmonary artery shunt.(16–21) Years later the shunt was modified using prosthetic material as polytetrafluoroethylene (PTFE) to create a systemic-to-pulmonary shunt. The 'modified' shunt with PTFE was anastomosed between the subclavian artery and the pulmonary artery.(21) (Fig.3)

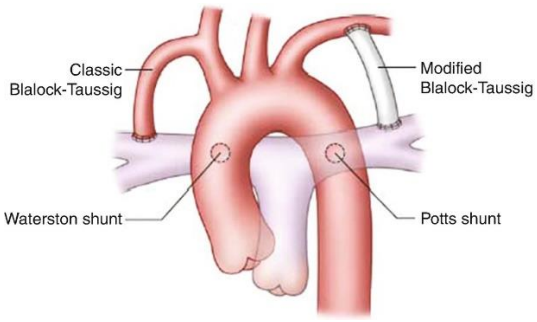

Figure 3 Schematic diagram showing the various locations of palliative systemic to pulmonary shunts. Kochav Adult Congenital Heart Disease in Clinical practice 2018 (22) Reprint with permission of Springer Nature.

Walton Lillehei performed the first intracardiac repair in 1954 in patients with TOF at the Boston Children's Hospital (US). Between March 1954 and may 1955 dr. Lillehei and his team operated 45 children with VSD, TOF and atrioventricular canal defects using parental cross-circulation.(23,24) By the end of the 1950s, mechanical cardiopulmonary bypass was available and the intracardiac repair of patients with tetralogy of Fallot became more feasible.(25–27)

From the 1950s to the 1980s, it was common to undertake a staged approach consisting of an initial palliative shunt followed by surgical repair around the age of 5 years.(7,8) In the initial surgical repair technique a large incision in the RVOT into the main pulmonary artery (PA) was used. The ventricular septal defect (VSD) was closed using a patch and the muscular tissue responsible for the subpulmonary stenosis resected. The outflow tract was closed using a patch, the so-called transannular patch. (Fig. 4) This technique disrupted the integrity of the pulmonary valve. In the beginning of 90's successful transatrial followed by transpulmonary repair was reported. This procedure is aimed at reducing the extent of the ventriculotomy.(28–30)

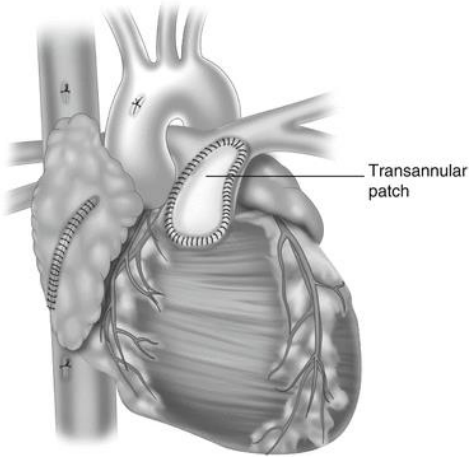

Figure 4 The appearance of a transannular patch used to enlarge a hypoplastic PV annulus and main pulmonary trunk. Hirsch and Bove (28) Reprint with permission of Springer Nature.

Surgical repair by means of a transannular patch provides excellent relief of right ventricular outflow tract obstruction (RVOTO) but at the expense of pulmonary valve regurgitation which leads to right ventricle (RV) dilatation over time. Eventually, the patient requires a pulmonary valve replacement. Therefore, surgeons established valve sparing techniques in the hope of preserving pulmonary valve competence and reducing RV long-term stress.(31–33)

In the current era some centers perform early complete repair in the neonatal period when oxygenation is compromised. This approach has a higher immediate postoperative mortality ranging between 4.6% and 6.4% and a 5 year survival of 92%. These results are worse compared to a staged repair.(10,34)

1.5. Residual lesions and long-term risks

In patients with repaired TOF there are often residual lesions such as RVOTO and more commonly, pulmonary valve regurgitation. Other long-term risks for patients with TOF after surgical repair include ventricular dysfunction and malignant arrhythmias that may lead to sudden cardiac death (SCD).(35,36)

Data from the International Multicenter TOF Registry (INDICATOR) demonstrated that residual RVOTO resulting in progressive RV hypertrophy is a long-term risk factor for ventricular tachycardia (VT).(37) In 1-7% of patients with residual RVOTO re-intervention will be required during long-term follow-up.(38)

Pulmonary valve regurgitation is more common during long-term follow-up and induces RV volume overload. The RV dilatation can lead to tricuspid regurgitation and RV dysfunction. Most patients with repaired TOF have a right bundle branch block (RBBB) with QRS prolongation. This block leads to delayed electrical activation of the RVOT and the infundibular region.(39) RBBB and RV dyssynchrony are contributing factors in progressive RV dysfunction.(40,41) In adults with repaired TOF and RBBB an increased intra-RV and intra-LV dyssynchrony was observed in the TOF group compared to healthy individuals. RV pacing failed to improve hemodynamics.(39)
In a study consisting of 16 adults with repaired TOF an epicardial electroanatomic map of the RV was created and single and dual-site RV pacing was applied. The commonest site of late activation was the RV free wall and the RVOT was subject to great variation in activation, which was latest in patients with a transannular patch. Targeted single (alternate) site RV pacing resulted in significant improvement of the cardiac output, superior when compared to RV apical or dual site RV pacing.(42)

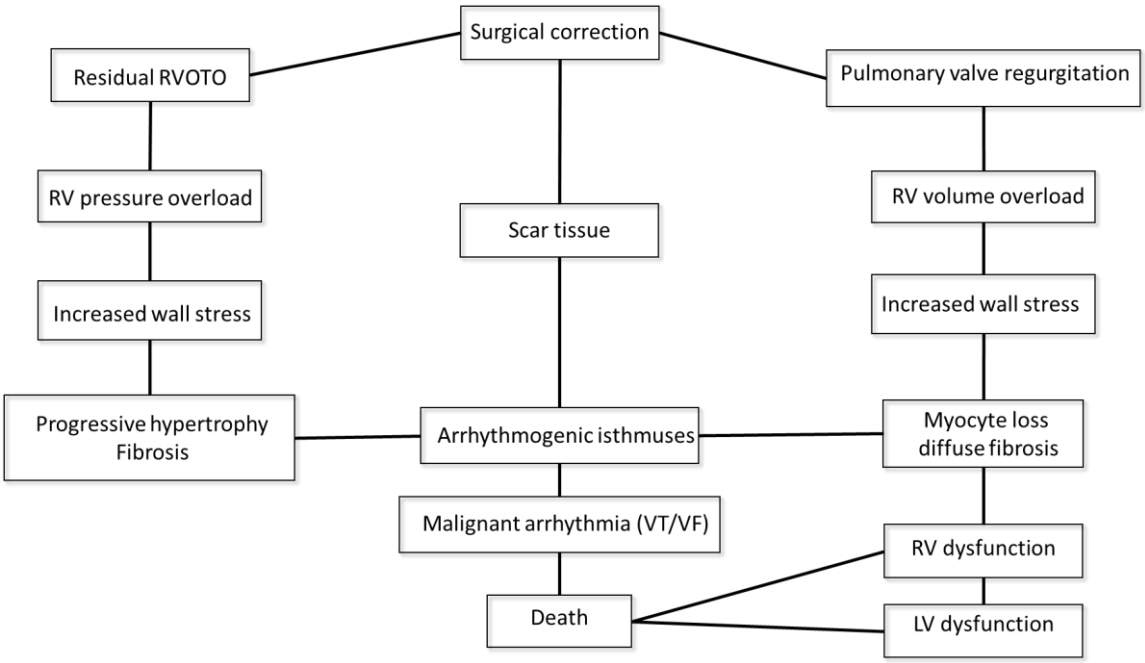

Figure 5 Pathophysiological diagram of the residual lesions at the level of the ventricles and long-term risks

The RV shows adaptation and remodeling to maintain a compensated state and, when these compensatory mechanisms fail, RV failure occurs.(43) The transition from an adaptive remodeling process to an adverse remodeling process is poorly understood.(38) The mechanism of progressive RV failure as suggested by Tal Geva is that following surgical repair, the RV mass-to-volume ratio decreases with an increase of the end systolic volumes and a decrease of RV ejection fraction.(40) Cardiac magnetic resonance (CMR) data in adults with repaired TOF demonstrated expansion of the extracellular volume (ECV) fraction which reflects the ratio of extracellular matrix volume to total myocardial volume. The increased ECV was observed in RV volume overload and was negatively related to RV mass-to-volume ratio which suggests myocyte loss and diffuse fibrosis.(44)

Due to the interventricular interdependence, the RV dysfunction can, in turn lead to left ventricular (LV) dysfunction.(40) Left ventricular dysfunction has been detected in 21-23% of adult patients with repaired TOF.(35,36)

Atrial as well as ventricular arrhythmias have been reported in 12% - 36% of patients after TOF repair.(8,45–47) There is a steep increase in the development of arrhythmias after the age of 45 years.(48) Estimated lifetime prevalence of atrial arrhythmias is 20%.(3) The most common atrial arrhythmia is an intra-atrial reentry-tachycardia. Ventricular arrhythmias consist of polymorphic ventricular tachycardias and fibrillation. Both polymorphic and monomorphic VT and VF can lead to sudden cardiac death (SCD). Gatzoulis *et al* and Redington *et al* estimated the annual risk of sudden death at 0.2%.(43,46) Murphy *et al* demonstrated a risk of SCD of 6% after TOF repair.(47) QRS

prolongation of > 180 milliseconds has been identified as a risk factor for SCD.(45,46) Other risk factors include severe pulmonary regurgitation (PR), severe RV dilation, left ventricular dysfunction and older age at complete repair.(49) Malignant arrhythmias may already be present at a young age.(12) A recent survey looking at the need for cardiac implantable electronic devices (CIED) in adults with repaired TOF showed a 4.3% overall implantation (792/18.353) of which 30.6% were pacemakers and the vast majority 69.4% were implantable cardiac defibrillators (ICDs). The mean age at implantation was 42.6+-13.9 years.(50) A risk score has been developed to identify patients who would benefit from an ICD.(51) The recommendations for the management of ventricular arrhythmias and prevention of sudden death in patients with congenital heart disease have been published by the European Society of Cardiology (ESC) and American College of Cardiology (AHA/ACC).(52,53)

Data from the International Multicenter TOF Registry (INDICATOR) identified risk factors for sustained VT and sudden cardiac death after pulmonary valve replacement in patients with TOF. The identified risk factors consisted of heart failure, older age at the time of pulmonary valve replacement (PVR), atrial arrhythmias prior to PVR and a higher end systolic RV volume index.(54,55) Arrhythmogenic anatomic isthmuses, which are the substrate for ventricular tachycardia in repaired TOF patients, have been identified by electro-anatomical mapping.(56) Four locations have been identified: 1/ between the tricuspid annulus and RVOT, 2/ between the RVOT and the pulmonary valve, 3/ between the pulmonary valve and the ventricular septal defect and 4/ between the ventricular septal defect and tricuspid valve.(56–58) Targeting these anatomical isthmuses by catheter ablation has been shown to be highly effective to control VT.(56)

Regression of RVOT dysfunction by replacing the pulmonary valve in a timely manner is considered to terminate the progressive adverse RV remodeling, but it will not interfere with the scar made by the surgeon. However, the key question is ideal timing of performing pulmonary valve replacement.

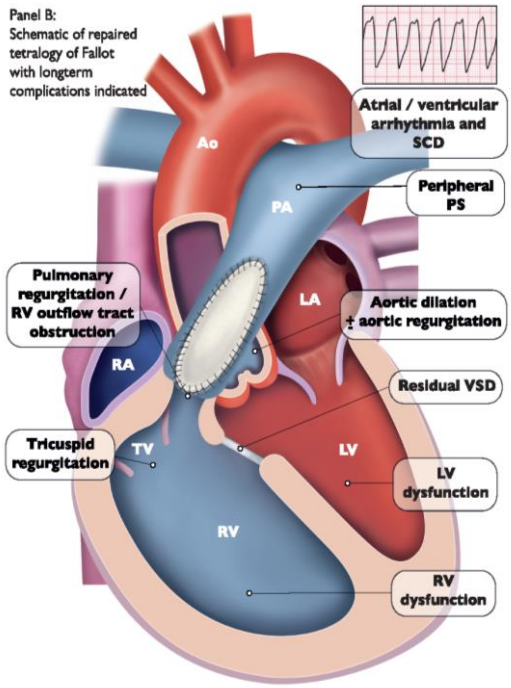

Figure 6 Anatomical drawing of repaired tetralogy of Fallot indicating the residual lesions and long-term complications to address during follow-up. RV right ventricle, SCD sudden cardiac death, PS pulmonary stenosis, VSD ventricular septal defect, LV left ventricle. Baumgartner H. *et al*. Eur Heart J 2020 (3) Reprint with permission of Oxford University Press.

1.6. Underlying pathophysiology

Pressure overload in the RV leads to increased wall stress and hypertrophy.(59) The pressure overload leads to activation and expansion of the fibroblasts. Activated fibroblasts (myofibroblasts) start secreting extracellular matrix proteins and collagen. These activated myofibroblasts express alpha-smooth muscle actin (α-SMA).(60) The cardiomyocytes can stimulate fibrosis under stress conditions and are a source of transforming growth factor (TGF)-β which is a crucial fibrogenic mediator. TGF-β promotes differentiation of fibroblasts to myofibroblasts and induces extracellular matrix protein synthesis.(61) Other mediators such as the vasoconstrictor Endothelin-1 with fibrogenic properties and reactive oxygen species (ROS) are involved in activation of fibroblasts.(59)

In a pressure overloaded RV the increased collagen deposition is associated with a disproportionate increase in collagen I secretion. Collagen I has reduced elasticity when compared to type III collagen. The change in collagen I to III ratio might be partially responsible for the increase in right ventricular stiffness following pressure overload.(59) An animal (rodent) model with pulmonary artery banding developed hypertrophy. The total collagen and soluble collagen was increased and was associated with RV diastolic dysfunction.(62)

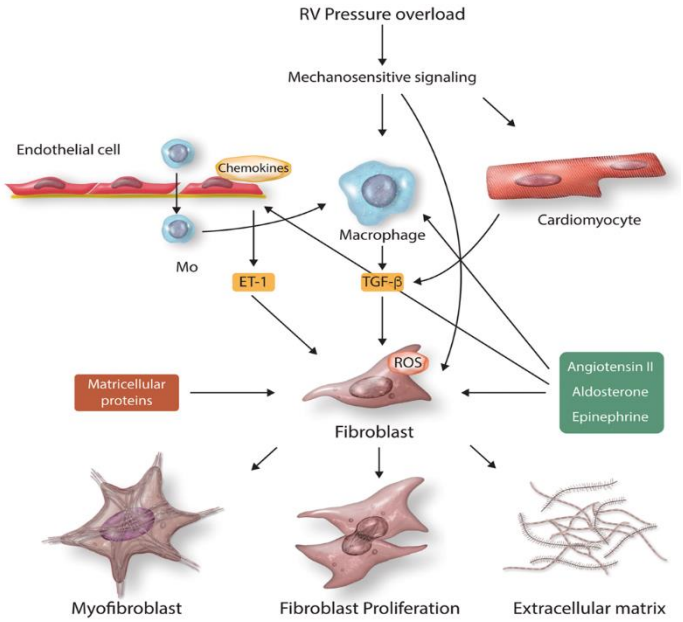

Figure 7 Cell biological effectors of fibrosis in the pressure-overloaded RV. Adapted from Frangogiannis NG. Fibroblasts and the extracellular matrix in right ventricular disease. Cardiovasc Res 2017(59) Reprint with permission of Oxford University Press.

Compared to data regarding changes in the extracellular matrix in RV pressure overload, data on RV volume overload are limited. In a mouse model RV volume overload was associated with subendocardial fibrosis in the RV wall.(63) In a piglet model with combined RV volume and pressure overload an increased accumulation of collagen in the interstitial spaces was found with significantly enlarged cardiac myocytes.(64)

Preoperative myocardial analysis in children undergoing primary TOF repair showed hypertrophy of the RV cardiomyocytes and increased interstitial collagen in both ventricles.(65) In cyanotic children the interstitial fibrosis and mitochondrial injury in the RV was more pronounced at the time of surgery. Histologic data on RV fibrosis in patients with repaired TOF are rare.(66)

Kido *et al* performed myocardial biopsy at the time of surgical PVR in 30 adult patients with repaired TOF (median age 29 yrs). A higher RV/LV pressure ratio (> 0.45) was a predisposing factor for RV myocardial fibrosis.(67)

Late gadolinium enhancement (LGE) measurement on cardiac magnetic resonance (CMR) imaging in 92 adults with repaired TOF suggested fibrosis at surgical sites: the outflow tract (99%), the VSD patch (98%), the trabeculated myocardium (24%) and the suture lines (79%) in TOF patients.(68) LGE was associated with arrhythmia.(68) Chen *et al* demonstrated in 9 patients with TOF a greater ECV using T1 measurements. The Increased ECV was associated with RV volume overload and arrhythmia. The ECV is the ratio of the extracellular matrix volume to total myocardial volume. An increased ECV can be explained by the extracellular matrix exceeding the cardiomyocyte hypertrophy or a loss of cardiomyocytes with proportionally larger extracellular matrix. The RV ECV was negatively related to

RV mass-to-volume ratio. Myocyte loss is a plausible mechanism of cellular remodeling. Chen *et al* speculated that in patients with repaired TOF with RV volume overload, the combination of decreasing RV mass-to-volume ratio and increasing RV ECV is consistent with a maladaptive process at cellular level characterized by cardiomyocyte loss and diffuse fibrosis.(44) This topic should be further investigated.

1.7. Reintervention for residual lesions

For residual pulmonary valve stenosis balloon dilation can be performed. Residual stenosis in the branch pulmonary arteries can be treated with percutaneous balloon dilation, stenting or surgical re-intervention.(69–71) Residual lesions as dilation of the aortic root, aortic regurgitation, residual VSD or severe tricuspid valve regurgitation should be addressed as needed.(3) Residual RVOTO and PR both can be treated with pulmonary valve replacement.
The most recent guidelines from the European Society of Cardiology (ESC) and American College of Cardiology (AHA/ACC) provide recommendations for PVR.(3,72)

- PVR (surgical or percutaneous) is recommended in symptomatic patients with severe PR and/or at least moderate RVOTO. (Class I)
- PVR (surgical or percutaneous) should be considered in asymptomatic patients with severe PR and/or RVOTO when one of the following criteria is present.(Class IIa)
    - Decrease in objective exercise capacity
    - Progressive RV dilation to RVESVi ≥80mL/m², and/or RVEDVi ≥160mL/m², and/or progression of tricuspid regurgitation to at least moderate
    - Progressive RV systolic dysfunction
    - RVOTO with right ventricular systolic pressure >80 mmHg

(**RVESVi**= right ventricular end-systolic volume indexed for body surface area, **RVEDVi** = right ventricular end-diastolic volume indexed for body surface area, Classes of recommendation: **Class I**=recommended; Evidence and/or general agreement that a given treatment or procedure is beneficial, useful, effective, **Class IIa**=should be considered; weight of evidence/opinion is in favour of usefulness/efficacy)

The guidelines are based on CMR studies in adult patients with repaired TOF.(40,73–80) In symptomatic patients insufficient reverse remodeling of the RV has been shown after PVR.(80,81) Therrien *et al* found that in patients with a pre-operative RVEDVi >170 ml/m² and the RVESVi >85 ml/m² the RV volumes did not normalized after PVR.(80) RV dysfunction was already observed in patients with a less dilated RV.(82,83) After PVR a trend towards normalization of the RV dimensions could be achieved if pre-interventional indexed RV end diastolic volumes (RVEDVi) were < 160 ml/m^2 and end systolic (RVESVi) < 80 ml/m^2.(83)

In 2006 Tal Geva formulated indications for PVR in patients with repaired TOF or similar physiology, and suggested PVR before the RV dimensions reached an RVEDVi ≥160 ml/m² and RVESVi ≥70 ml/m².(40)

Optimal timing of PVR remains uncertain. It is a difficult balance between performing PVR before irreversible RV dysfunction with late complications as ventricular failure or SCD occurs and the disadvantage of graft failure and need for (multiple) re-interventions due to earlier PVR.(40) A meta-analysis of 48 trials on PVR in repaired TOF demonstrated that PVR leads to improvement in RV and LV function and volume improved, shortened QRS and improvement of symptoms.(76) It has not been proven to date that PVR improves the life expectancy by altering the risk of SCD and RV failure.(55)

Age is not reflected in the guidelines in a direct manner; indirectly most of the symptomatic patients will be older compared to asymptomatic patients. Dr. Tal Geva stated in 2006 that there were no data to support PVR in young patients with mild-to-moderate RV volume overload with preserved ejection fraction and without any additional risk factor.(40) Studies on PVR in younger patients did show a greater improvement in RV function and exercise capacity. Early data from Dr. Benson's group of percutaneous PVR showed that PVR at young age (including patients < 16 yrs of age) was associated with improved RV function and increased VO2 max. This data may support performing PVR in repaired TOF patients at younger (adolescent) age. (84–87) There is a tendency towards performing PVR at younger age to prevent the detrimental complications of severe PR.(84,88,89) Disadvantages of PVR at younger age (< 20 years of age) consist of a 2-fold higher risk of graft failure and repeated PVR over a lifetime.(90–92)

Different types of conduits have been used for surgical valve replacement: homograft, Freestyle™ (Medtronic Inc, Minneapolis, US), Carpentier-Edwards porcine, Carpentier-Edwards pericardial, Ionescu-Shiley pericardial, mechanical and the Contegra-conduit.(92,93) Overall homografts appear to have a better longevity compared to other xenografts. There is weak evidence of a higher durability of porcine valves compared to bovine pericardial valves.(94) Freedom from valve dysfunction and re-intervention was 81.6% for homografts compared to 43.4% for bioprostheses at median 10 year follow-up.(95) In patients with TOF there was no difference in re-intervention rate of the homograft valves compared to the Freestyle™ (Medtronic Inc.) valve.(96) The reported durability of homografts in TOF patients varies substantially among different trials: freedom from valve dysfunction has been reported in the ranges of 47% to 74% at 10 years.(97–99) Homografts are preferably used in children with TOF. In children freedom from re-operation was 70% at 8 years and 39% at 8 years in children who had a homograft implanted before the age of 3 years.(100) Failure of the homografts was ascribed to somatic

growth in 8% and in 53% as a result of wall thickening leading to stenosis.(101) Age at first valve replacement varies among papers from 20.8 – 33.8 years.(96,99) Contegra-conduits (bovine jugular vein) were generally implanted at a younger age mean 10.9 years (range 0.2-46 years) and the freedom from re-intervention was 94% at 11.4 years.(93) Graft failure with need for re-intervention was 63.6% at 10 years for Contegra-conduits compared to 81.4% for homografts.(102) Current hospital mortality for surgical PVR overall is low, approximately 1.5%.(99)

Infective endocarditis (IE) is reported in porcine materials but also in the Contegra-conduit where IE was reported in up to 11.3% of the cases. (103,104) The IE risk of the Contegra-conduits has been shown to be higher compared to homografts.(105)

In the year 2000 Philippe Bonhoeffer mounted a valve from the bovine jugular vein in a Cheatam Platinum CP- stent™ and implanted it in lambs. This was the first transcatheter balloon expandable valved stent.(106–108) The first 58 human implants were reported in 2006.(109) In 2006 the valve gained CE approval and became available for clinical use as the Melody™ transpulmonary valve (TPV) (Medtronic Inc, Minneapolis, US). The valve can be used to address a stenotic, a regurgitant or a combined lesion of the RVOT. The initial data on the use of this stented valve showed high procedural success with low early morbidity and negligible degree of mortality.(110,111) The initial experience identified stent fractures and endocarditis as risk factors for graft failure.(105,111–115) McElhinney *et al* reports an annual incidence of TPV related endocarditis of 2.4% per patient-year.(116,117) Stent fracture and recompression may lead to hemodynamic compromise and is a major concern for long-term function after percutaneous pulmonary valve implantations (PPVI).(112,113,118–120) A valved stent is exposed to mechanical stress load resulting in recompression and strain which ultimately may result in metal fatigue and stent fractures. Data on metal fatigue and fracture rates of the different stents used in PPVI is not available, especially data on combinations of different types of stents as used during pre-stenting.

The outflow tract of patients with TOF can become dilated and therefore the valved stent with limited outer diameter might be less suitable.(121,122) The outer diameter of the Melody™ valve is 24.1 mm delivered on a 22 mm Ensemble™. Other manufactures developed valves with a larger outer diameter such as the Sapien XT valve (Edwards Lifescience) with sizes 23, 26 and 29mm.(123–127) To accommodate for large outflow tracts self-expanding valves have been developed and are currently investigated in clinical trials. The Harmony transcatheter pulmonary valve (Medtronic, Minneapolis, US) and The Venus P-valve™ (Medtech, Shanghai, China) are both examples of self-expanding valved stents with diameters ranging up to 34 mm diameter of the middle part.(128–130)

The most recent ESC and ACC guidelines also provide recommendations on the treatment of sustained VT and ICD implantation in patients with TOF.(3,72) In patients with sustained VT who are undergoing surgical or percutaneous PVR preoperative catheter mapping and transection of VT-related anatomical isthmuses should be considered (class IIa). In patients with risk factors for SCD as LV or RV dysfunction, VT, QRS ≥180 milliseconds, or extensive RV scarring on CMR electrophysiological evaluation (including programmed electrical stimulation) and ICD implantation should be considered (class IIa). Intraoperative cryoablation of the conducting myocardium between the pulmonary valve and the ventricular septal defect patch (isthmus 3) should be considered at PVR as the implanted conduit may cover the isthmus which makes ablation in later stage impossible.(131)

1.8. **Conclusion**

After the initial surgical repair of TOF, residual lesions as RVOTO and PR are common. The residual lesions contribute to the long-term risks such as malignant arrhythmia leading to SCD and ventricular failure. Residual RVOTO leading to progressive hypertrophy is a risk factor for VT and death. Over time PR leads to RV volume overload. The progressive RV dilatation with increasing tricuspid regurgitation and RV dyssynchrony eventually give rise to RV dysfunction. Replacement of the pulmonary valve can stop the adverse remodeling of the RV when performed in time. Recommendations for PVR have been established for symptomatic and asymptomatic patients with repaired TOF.

The ideal timing of PVR remains challenging. PVR should be performed before irreversible RV dysfunction occurs, but earlier PVR increases the re-intervention rate due to faster graft failure. It has not been proven that PVR changes the long-term risks. PVR can be performed with a surgical conduit with reasonable longevity and acceptable procedural morbidity and mortality. Transcatheter strategies are being developed to perform PVR in repaired TOF patients with dilated outflow tracts.

Our current understanding of the remodeling and reverse remodeling processes of the RV is limited. More knowledge of the adaptation mechanisms of the RV is required. One of the future aims should be to detect early changes which might predict the future decline in RV function or the risk for malignant arrhythmias.

AIMS

AIMS

This thesis addresses different issues related to pulmonary valve replacement in the course of the life a patient with Tetralogy of Fallot.

The feasibility of percutaneous pulmonary valve implantation and its applicability in patients with surgically repaired tetralogy of Fallot is evaluated.

The resistance of combinations of stents to deformation and risk of corrosion is evaluated.

An animal model with severe pulmonary regurgitation and right ventricular volume overload is created and RV remodeling and reversed remodeling after pulmonary valve replacement is studied.

The following research questions will be addressed:

In **Chapter 1** the aim is to study the feasibility of percutaneous pulmonary valve implantation. The aim is to evaluate the durability of implanted valves and to report on the morbidity and mortality of the technique.

In **Chapter 2** the aim is to evaluate feasibility and safety of pre-stenting followed by percutaneous pulmonary valve implantation in patients with TOF with dilated RVOT and severe PR.

In **Chapter 3** the aim is to evaluate the resistance of stents and combinations of stent to deformation. The aim is to assess the corrosion potential when different types of stent alloys come into contact with each other.

In **Chapter 4** the aim is to create an animal model with severe PR and RV volume overload to study RV remodeling and reverse remodeling after PVR at different time intervals.

In **Chapter 5** the aim is to evaluate RV remodeling and reverse remodeling after PVR at different time intervals in an ovine TOF model

RESEARCH WORK

CHAPTER 1

Feasibility of percutaneous pulmonary valve implantation. The durability of the implanted valves and the morbidity and mortality of the technique

Published as : Bjorn Cools, Steven Brown, Werner Budts, Ruth Heying, Els Troost, Derize Boshoff, Benedicte Eyskens, Marc Gewillig. Up to 11 years of experience with the Melody valved stent in the right ventricular outflow tract. EuroIntervention 2018; Oct 12;14(9):e988-e994

1.1 ABSTRACT

Aim To report up to 11 years follow up after Melody™ valve implantation in pulmonary position.

Methods and results Single institution non-randomized prospective observational study from all Melody valves in pulmonary position after discharge between 2006 - 2017 (n = 188). Mean age 19.4±13.2 y. Indication: stenosis (45%), regurgitation (33%) and mixed (22%). Pre-stenting was performed in all except the initial four patients. In stenotic lesions the peak gradient is 36±12 mmHg PIG after 11 years and in regurgitant lesions the maximal regurgitation is 2/4. Stent fractures were observed in 8.6%; only 1 grade III fracture required redo PPVI. Surgical removal was done in 7(3.7%), redo PPVI in 5(2.7%). Endocarditis was diagnosed in 19 (10.2%) patients a median of 2.3 years (0.7–8.8) after Melody implantation. Three were surgically removed early because persistent infection, 16 got sterilized; 6 required replacement (3 surgical, 3 redo PPVI). There are no valve or procedure related deaths.

Conclusions: The Melody valve shows a good preserved leaflet function up to 11 years after implantation. The main reason for graft failure is endocarditis, although in half of those patients no re-intervention was needed. After pre-stenting, stent fractures lead very exceptionally to re-intervention.

1.2 INTRODUCTION

Since the first human implantation performed in the year 2000, percutaneous pulmonary valve implantation (PPVI) has established itself as technically feasible with good short to mid-term outcomes over all age groups.(1–5) PPVI results in improvement in right ventricular (RV) function and dimensions, reduction of tricuspid regurgitation, improved electrical stability, exercise ability and a better quality of life.(6) Early adverse events included coronary compression, rupture of the right ventricular outflow tract (RVOT), aortic valve compression, aortic erosion, valve embolization and tricuspid valve damage. These mostly occurred during initial experiences and have largely been curtailed by better-quality assessment practices and technical improvements. Stent recompression, stent fracture and endocarditis have emerged as potential problems during long term follow up.(1,2)

The indications for PPVI have changed over time: initially the stented valve was developed to prolong conduit function in order to delay surgical valve replacement; it now can be offered for almost any dysfunctional RVOT even for those without a previous conduit.(7) Extensive medium and long term data on the performance of the Melody™ valved stent in the right ventricular outflow tract are not yet available. Follow-up data is required to compare PPVI with existing surgical techniques, and to determine its role when applied to symptomatic patients or even when applied for prognostic reasons.(8)

This aim of this study was to analyze up to 11 year follow up data of Melody™ valve (Medtronic Inc., Minneapolis, MN, USA) implantations in our center.

1.3 PATIENTS AND METHODS

This is a single institution non-randomized prospective observational study. All patients discharged with a Melody™ valve in pulmonary position were entered into a registry starting in 2006 with a specified protocol for clinical follow-up. For the purpose of this analysis, the database was closed 20 December 2017 and included 185 patients.

Standard techniques for implantation were used as previously described.(7,9) In short, procedures were performed under general anesthesia and standard prophylactic antibiotic regimens followed. After discharge, endocarditis prophylaxis was recommended to all, no anti platelet medication was prescribed except when indicated for other reasons.

1.3.1 Follow up

The protocol consisted of follow-up at 1,3, 6 and 12 months, followed by annual visits thereafter. This included radiography to assess for the presence of stent fractures as well as routine transthoracic echocardiographic examination. Stent fractures were classified as proposed by Nordmeyer *et al*.(10) Pulmonary regurgitation (PR) was classified according to a scale of 0 to 4 (none to severe) based mainly

on the magnitude of the regurgitation jet on color Doppler, early termination of diastolic flows as well as right heart dilation.

Endocarditis was diagnosed using the modified Dukes criteria. Imaging was done by transthoracic echocardiography and in case of inconclusive images, additionally transoesophageal or especially intravascular ultrasound (ICE) was performed.(11)

1.3.2 Ethics & statistics

Assent and informed consent were obtained from patients, their parents or legal guardians. Approval for the study was granted by the local ethics committee (S60373); for inclusions after 2010, adherence to the study protocol was imposed by Belgian medical insurance in order to obtain reimbursement. SPSS version 20 (IBM) was used for data analysis. Continuous data are expressed as mean and standard deviation or median and range. Paired data were analyzed by a paired t-test and Kruskal Wallis test. Kaplan Meier plots were used for survival analyses. A $p < 0.05$ indicated statistical significance.

1.4 RESULTS

One hundred and eighty eight (n = 188) Melody™ valves were implanted in 186 patients over this 11 year period. In 1 patient a Melody valve was explanted immediately after post-implant dilatation because of coronary compression; this implantation failure is not included in this study. This study therefore reports on follow-up of 188 valves in 185 patients discharged with a Melody valve. Age and weight at implantation can be viewed in Table 1. Two thirds of the patients were male (125 vs. 62 female) and the majority (119/185) were younger than 18 years at implantation. The youngest patient was 3.5 years and had a weight of 15 kg at the time of procedure. The patient underwent a Rastelli repair with a downsized homograft which became severely stenotic 2 years later. A 34 mm covered CP-stent™ and a Melody™ valve were implanted on a 18 mm Ensemble™.

The main indications for PPVI were a stenotic RVOT (45%) followed by dominant PR (33%) with the remainder mixed PS-PR (22%). Diagnosis of underlying conditions included tetralogy of Fallot (n = 101) 54.3%, post Ross operation (n = 33) 17.7%, post Rastelli repair (n = 17) 9.2%, pulmonary stenosis (n = 23) 12.4% and truncus arteriosus (n = 12) 6.5%. The stented valves were implanted in homografts (52.7%) and in 32.8% in native or patched right ventricular outflow tracts and in 14.5% in bioprosthesis (e.g. Contegra®, Hancock® etc.) (Table 1). Pre-stenting was not performed in the initial four patients (standard recommendations at that stage, early experience). Thereafter and with increasing understanding, RVOT pre-stenting was actively performed and evolved significantly. Stents were implanted to ensure a stable landing zone with no recoil nor distortion; care was taken to abolish all gradients prior to Melody™ valve implantation. Initially, the outflow tract was dilated up to the nominal value of the surgical conduit (standard recommendation at that stage). In the later years conduits were

expanded with covered stents up to 22-24 mm provided that the size of the RVOT and coronary anatomy were acceptable.

Table 1. Demographic data. indication and primary lesion

		mean	median	SD	min	max
Age (years)		19.4	15.2	13.2	3.5	81.6
Weight (kg)		51.5	50.0	23.2	15.0	119.0
Conduit diameter* (mm)		20.7	22.0	3.3	10.0	27.0
			N	%		
Sex	male		123	66.7		
	female		62	33.3		
indication	stenosis		83	45.2		
	regurgitation		61	32.8		
	mixed		41	22.0		
conduit type	native or patch		61	32.8		
	homograft		97	52.4		
	Contegra®		23	12.4		
	Hancock®		1.0	0.5		
	Freestyle®		3	1.6		

**conduit diameter prior to implant. SD : standard deviation*

A total of 226 pre-stents were implanted – one only in 147 patients, two in 26, three in 6 and four stents in 2 patients. Hybrid open cell bare metal stents were implanted in the conduit free outflow tracts as described in a previous publication.(1) Various types of stents were used for pre-stenting (CP Numed NY USA n=161, covered CP Numed NY USA n=31, Andrastent® (Andratech Gmbh Koblenz Germany) n=8, Max LD® (Covidien Minnesota USA) n=2, various n=3). Melody™ valves were delivered on 18 mm (n = 11), 20 mm (n = 34) and the vast majority on a 22mm (n = 145) Ensemble systems. Of the latter, one was over expanded to 24 mm inner diameter.

1.4.1 Follow-up

Patients have been followed up for a total of 836 patient years over this 11 year period. At closure of the database in December 2017, clinical and echocardiographic follow up was complete in all patients (thus with last annual visit later than December 2016 excepted when censored (death, explant, re-stent, redo PPVI).

1.4.2 Graft survival

The overall graft survival was 78% at 10 years follow-up. (Figure1) Thirteen patients (6.9%) had failure of the graft requiring replacement: in 7 patients the stent was surgically removed due to endocarditis (n=6: none acute, 3 early because ongoing infection, 3 elective after sterilization)) and subpulmonary stenosis (n=1). In 5 patients a redo PPVI was performed for stenosis after endocarditis (n=3), in one due to conduit stenosis 10.3 years after initial implantation and in one patient due to a type III stent fracture at 5.2 years after implantation. Redo PPVI was done in both with a new Melody™ valved stent.

1.4.3 Patient survival

There were three late deaths, none were related to the procedure or overall valve related : one patient died from kidney failure at the age 85 years, one due to status epilepticus at the age of 20 years and one sudden death during sleep at the age of 26 years (there was no autopsy performed).

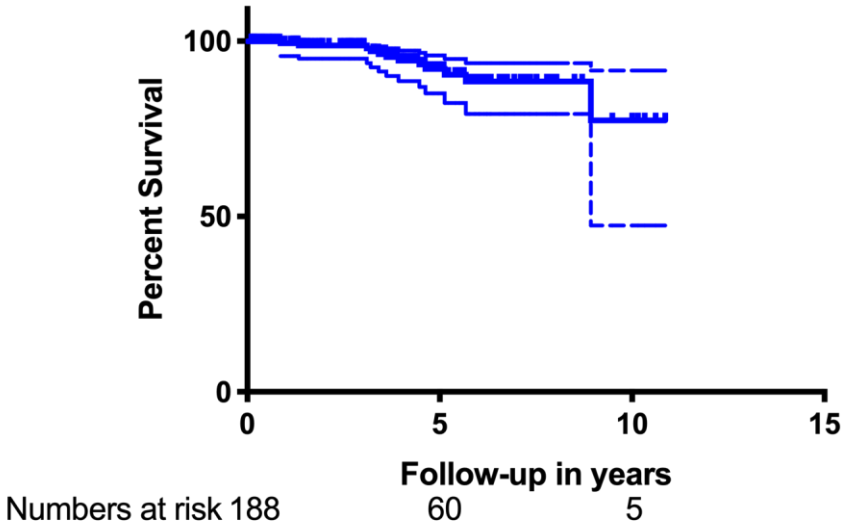

Figure 1. Kaplan-Meier plot overall graft survival in RVOT. Graft failure is defined by surgical removal of the Melody™ valve or redo PPVI with another valved stent. 95% Confidence Interval

1.4.4 Hemodynamic outcomes

When stenosis was the main indication for PPVI, we observed initially a sharp decline of the peak instantaneous Doppler gradient PIG to 23±11 mmHg, which remained fairly unchanged at 36 ± 12 mmHg over the RVOT during follow-up.(Figure 2) When PR was the dominant lesion, it followed a similar pattern and dropped from median 4/4 to median 0/4 after PPVI (range 0-2) and slightly increased to median 2/4 at 11 years.(Figure 3) Functional status remained constant after 11 years with the majority of the patients in NYHA functional class of I-II. One patient developed increased gradient across the valve without any sign of endocarditis: the wall of the valve was thickened on intravascular ultrasound and angiogram. We could not determine whether this was due to thickening of the conduit

wall or a hammock effect of the surrounding tissue. As balloon dilation was unsuccessful due to significant recoil, a bare metal stent was implanted to adequately relieve the gradient, followed 4 months later by repeat PPVI.

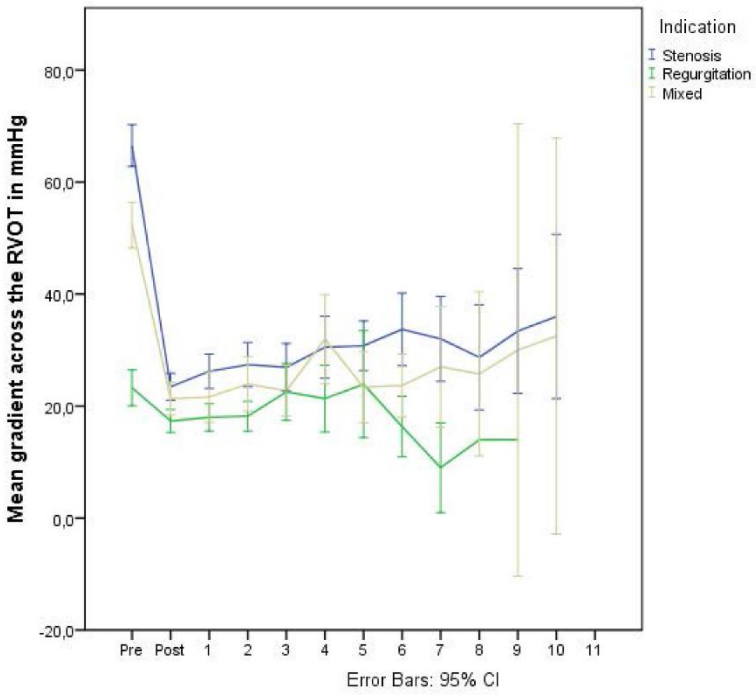

Figure 2. Graft function. Evolution of RVOT peak Doppler gradient = 4(Vmax)^2. Depicted are three groups with predominant stenosis (blue), predominant regurgitation (green) and mixed (orange).

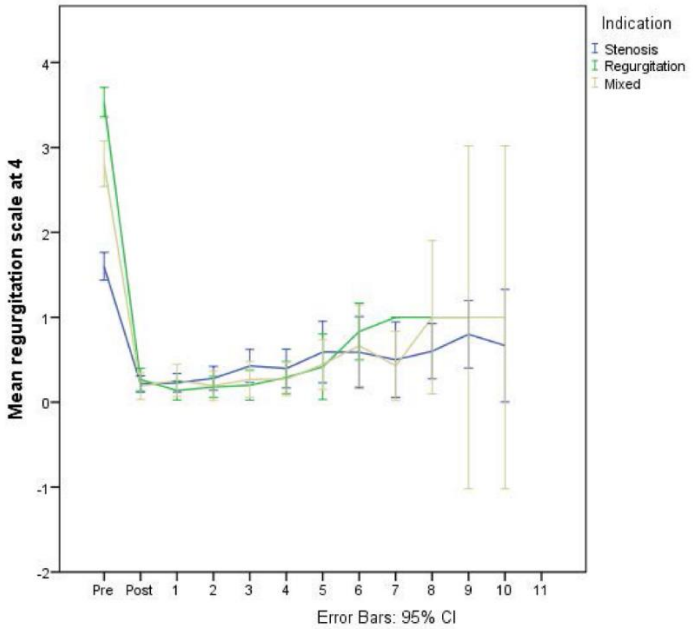

Figure 3. Graft function. Evolution of pulmonary regurgitation (PR). Depicted are three groups with predominant stenosis (blue), predominant regurgitation (green) and mixed (orange).

1.4.5 Stent fractures

Chest radiography was performed on regular base (once in a year) in 87% of patients and stent fractures were observed in 16 patients (8.6%). In 2 patients a type III fracture of a covered CP stent was observed 5 and 7 years after implantation; one patient of the latter required a redo stenting and redo PPVI because of moderate stenosis. When reviewing the implantation procedure in this case, the pre-stent still showed motion and should have been fortified with an additional stent prior to Melody implantation. In the remaining 14 patients only type I stent fractures were observed a mean of 4.2±2.6 years after implant. The relative incidence of stent fracture was 1/4 (25%) in the initial 4 patients who did not receive a pre-stent versus 13/182 (7.1%) in the pre-stented group. None of the minor fractures resulted in hemodynamic consequences. Freedom from stent fractures was 82% at 11 years.(Figure 4)

1.4.6 Reinterventions

In 21 (11.3 %) patients a re-intervention was performed during follow-up. Balloon angioplasty to accommodate for somatic growth was performed in 8 (4.3%) patients mean 3.4±1.9 years after implantation. Seven (4.3%) Melody™ valves were explanted, 6 for endocarditis and one electively as a result of progressive subvalvular pulmonary stenosis. Repeat PPVI was required in 3 patients after curing the endocarditis, in one patient following a type III fracture and in one after “wall thickening”.

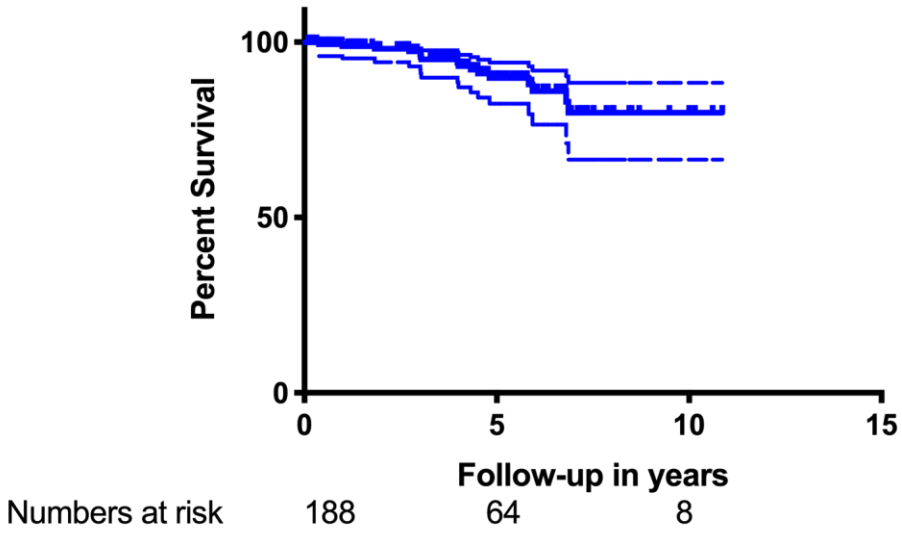

Figure 4. Kaplan-Meier analysis. Freedom from stent fractures (study period 2006-2017). 95% Confidence Interval

1.4.7 Endocarditis

Endocarditis was diagnosed in 19 (10.2%) patients at a median time of 2.3 years (range 0.7-8.9) after Melody™ implantation. The median age at the time of endocarditis was 16.2 years (range: 8.0 – 45.6) with a strong male preponderance (16/19, 84.2%). A total of 10/19 patients had definite endocarditis

according to the modified Duke criteria and the others as possible. Freedom from endocarditis was 84.9% and 76.2% after 5 and 10 years, respectively.(Figure 5) The original substrate in which the Melody™ valve was implanted in these cases were homografts (n = 10)(52.6%), native or patched RVOT's (n = 6)(31.6%) and Contegra® type valve (Medtronic Inc., Minneapolis, MN, US) grafts (n = 3)(15.8%). Peak instantaneous gradients over the RVOT in patients presenting with endocarditis had increased significantly - from a median of 23mm Hg (range: 10 - 42) to a median of 65mm Hg (range: 18 -110) (p = 0.001). Positive bacterial identification was obtained in 89.4% of the cases: Staphylococci species (n = 6), Streptococcus viridans (n = 5), HACEK group (n = 2) and other (n = 4). In two patients no organisms were cultured. A probable entry point could be determined in 15/19 patients (78.9%), predominantly dental and in some from the skin. Three were surgically removed early (4, 17 and 25 days) because persistent infection; 16 got sterilized after 4 to 6 weeks of antibiotics; 6 required eventually replacement because of obstruction (3 surgical, 3 redo PPVI with Sapien valve). In the latter patients we waited first minimal 6 weeks before pre-stenting, and again minimal 6 weeks prior to redo PPVI to ascertain eradication of the infection.

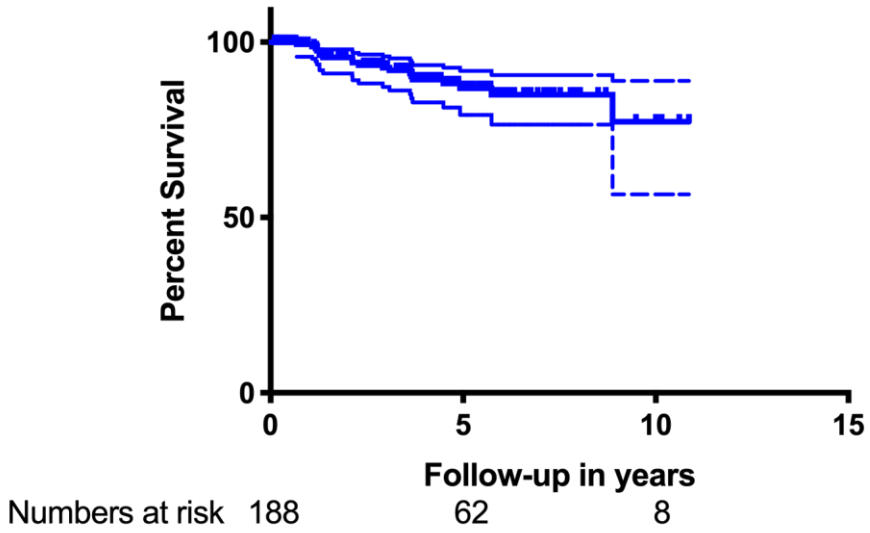

Figure 5. Kaplan-Meier analysis. Freedom from endocarditis (study period 2006-2017). 95% Confidence Interval

1.5 DISCUSSION

As time progresses and experience increases, PPVI is establishing itself as a very competitive option for the treatment of RVOT dysfunction. The most important finding of this interim analysis is that the Melody™ valve exhibited good graft survival with good function up to 11 years of follow-up for patients who remained free from endocarditis. Gradients across the RVOT did not change significantly and pulmonary regurgitation remained low. Stent fractures with hemodynamic consequences are exceptional after adequate pre-stenting, but endocarditis remains a challenge.

1.5.1 Melody™ valve function

Overall graft survival was 78% after 10 years of follow-up, the main reason for graft failure was valve dysfunction due to endocarditis 10/13 (77%). If patients remained free from endocarditis, there was little progression of obstruction and/or regurgitation. This can be attributed to a number of factors. The procedural protocol includes adequate pre-stenting the RVOT with the aim to ensure mechanical stability of the landing zone, underscored by the number of stents used during pre-stenting. The aim of this protocol is to ensure strength (resistance to deformity) of the scaffolding with redistribution of stresses over the coupled stent system resulting in improved stented valve function. Even though disadvantages such as fretting, leverage and galvanic corrosion may occur, the success of this approach is illustrated by the fact that none of our patients presented with acute collapse of the stented valve and only a few demonstrated signs of mild recompression.(12)

The minimal stenosis and regurgitation indicate preserved good function of the graft leaflets over the period of our analysis. As opposed to surgical conduits, where obstruction frequently occurs at the anastomosis of “normal” tissue to conduits, the joined stent scaffolding in the landing zone potentially prevents initial direct contact of the graft tissue with that of the patient at the proximal and distal end of the landing zone. Furthermore, disturbed patterns of flow are more likely with surgical implants not only due to limitations at implantation, but also due compression, kinking, shrinkage and fibrosis over time. Adequate pre-stenting aims to prevent external compression and streamlines flow as a result of straightening of distorted conduits and by achieving a nice circular shape – all of which are likely to further improve valve function. Pre-stenting is thus important for a number of reasons as the omission of pre-stenting during the initial London and US experiences revealed.(2) Similar to surgical experiences, where larger conduits provide better longevity of a valve, it would be logical to ensure an adequate diameter of the RVOT during pre-stenting. We currently aim for a 22 to 24 mm landing zone, if permitted by the anatomy and coronary proximity. In the majority of our patients (75.3%), valves were implanted using the largest (22mm) delivery system and expanded up to 22 mm inner diameter.

1.5.2 Reinterventions

Re-interventions were performed in 11.3% of patients. These findings are in agreement with the medium term results of the US trial where the freedom from re-intervention after 5 years was 91%.(13) The main reason for surgical explantation (6/7) of the graft or percutaneous redo PPVI (3/5) was endocarditis. One valve was over stented because of a grade III pre-stent fracture (see section stent fractures). One valve was electively explanted 3.5 years after implantation due to progressive subpulmonary obstruction; the Melody valve itself still had normal function and appearance, with an endothelial covering of the valve leaflets. In this patient, the initial residual infundibular gradient was mild, but continued to increase as the right ventricle size regressed as a result of reduced volume

loading after Melody implantation. Cognizance of this occurrence should be taken, since right ventricular remodeling after PPVI may amplify gradients proximal to the landing zone. Balloon angioplasty to accommodate for somatic growth is a decided advantage of a percutaneous valve and adds to the attraction of PPVI. We considered this as elective treatment and not as a forced re-intervention.

1.5.3 Stent fractures

Fractures of the stented RVOT (7.5%) in our series were lower than in most reports.(2,10,14) The use of multiple overlapping stents and the use of simple X-ray (F & P) may have precluded the detection of small fractures of the Melody stent; however Doppler echocardiography excluded a clinically relevant change of valve function, which is the final goal of this treatment. Fractures were mostly of class I with no hemodynamic compromise and we observed only 2 grade III fractures of a pre-stent. In one patient, a redo PPVI was performed because the clinician observed mild deformation of the conduit in the presence of a moderate Doppler gradient of 45 mmHg; prophylactically an additional outflow tract stent and Melody valve were placed. An explanation for the observed low frequency of stent fractures and extremely low occurrence of hemodynamically important fractures can possibly be found the rigid pre-stenting protocol: aggressive pre-stenting until no more motion of the “tube” is observed. We hypothesize that this strategy decreases strain amplitude and metal fatigue, thereby delaying or even avoiding fracture during a human lifetime. This is supported by previous analysis of mechanical stress bench testing of stents.(12)

1.5.4 Endocarditis

Endocarditis is an important threat for any bioprosthetic valve, including the Melody™ valve. Several series have reported incidence rates of endocarditis between 7,5 and 16% in bovine valves.(15) In our series endocarditis occurred in 10.2% of the implants. In 10/19 (52.6%) the endocarditis was cured with antibiotics only without significant change in valve function. No deaths occurred and no urgent surgery was required since all patients, caretakers and general practitioners were instructed to monitor for early signs of endocarditis; additionally there is a short and fast track for referral to the implant center in case of suspicion of endocarditis. Of note is that a “sudden” significantly increased gradient over the RVOT should alert the consulting cardiologist to the possible presence of endocarditis.

The study was not powered to identify specific factors, but there is a strong male preponderance and mostly young adolescents appear to be at higher risk. Youngster in pubertal age group are difficult to control on hygienic measures (dental/skin). In 15/19 patients a clear entry point for endocarditis could been identified. Following extensive education of patients, their parents and caretakers, not allowing overruling nor deviation from the ESC guidelines, we have observed a reduction of endocarditis from

a maximal annual incidence of 2.6% down to currently less than 1.0%. All patients were advised to follow a rigorous schedule of dental and skin hygiene and to take adequate prophylaxis prior to high risk procedures. Similar information was conveyed to their local practitioners and dentists. It should be noted that the 2015 ESC guidelines specify transcatheter heart valves to be at higher risk (IIA evidence) whilst the 2007 AHA guidelines only allude to prosthetic valves.(16,17) As a result, this had been confusing for practitioners and dentists and as far as our country concerns has led to a more liberal attitude concerning SBE prophylaxis. In view of the findings of this study and other reports, it seems prudent to promote that biological percutaneous valves should adhere to strict antibiotic prophylactic measures.

The current strategy in our center is not to give antiplatelet therapy. The use of antiplatelet therapy in preventing microthrombi and possible prevention of IE is being studied.(18–21) There is currently however no evidence that antiplatelet therapy with acetylsalicylic acid only reduces endocarditis in this situation. With our current strategy we have reduced the annual incidence of endocarditis below 1.0%/year, which is lower than similar cohorts with acetylsalicylic acid. The jury is still out on this question!

1.5.5 Comparison to surgery

A recent contemporary multicenter surgical trial of decellularized (n = 163) and standard allografts (n = 124) with similar numbers over a comparable period, showed that freedom from conduit dysfunction at 10 years was 83% for decellularized conduits and 58 % for standard allografts ($p < 0.001$).(22) In a review of best evidence by Abbas, freedom from re-intervention and graft failure varied from 47% - 72% after 10 years for various conduits.(23) Similar findings were reported for Contegra® conduits in children where freedom from re-operation was 75% at 5 years. Our results show that the Melody™ valve had a freedom from conduit dysfunction of 78% after 10 years indicating that it is highly competitive to current conduits, and might perform even better if endocarditis were contained. Furthermore, if adaptation for somatic growth is excluded (which is not an option for most surgical conduits), the Melody™ valve required in 7% of the cases a re-intervention within 11 years follow-up time. This is low in comparison to 10% risk of re-intervention for the decellularized conduits and even 27% for standard allografts.(22–25)

Possible reasons for better performance of the Melody™ valve as opposed to surgical conduits include absence of retraction or shrinkage, as is frequently observed at the muscular cuff of a homograft or at the distal anastomosis of a Contegra®. Furthermore, a stented conduit is more resistant to external compression typically exerted by the sternum and aorta or internal retraction due to fibrosis of the biological tissue.

1.6 Conclusion

The Melody™ valve shows good graft survival up to 11 years. Gradient relief can be attributed to pre-stenting, with a lasting result over the study period. Leaflet function remained good: no significant stenosis or regurgitation. Endocarditis remains an important issue, which might be reduced by stringent adherence to prophylactic measurements. PPVI with the Melody™ valved stent longevity compares favorably with surgical grafts.

References

1. Cools B., Budts W., Heying R., et al. Medium term follow-up after percutaneous pulmonary valve replacement with the Melody® valve. IJC Hear Vasc 2015;7. Doi: 10.1016/j.ijcha.2015.02.014.
2. Cheatham JP., Hellenbrand WE., Zahn EM., et al. Clinical and hemodynamic outcomes up to 7 years after transcatheter pulmonary valve replacement in the US melody valve investigational device exemption trial. Circulation 2015. Doi: 10.1161/CIRCULATIONAHA.114.013588.
3. Borik S., Crean A., Horlick E., et al. Percutaneous pulmonary valve implantation: 5 years of follow-up does age influence outcomes? Circ Cardiovasc Interv 2015. Doi: 10.1161/CIRCINTERVENTIONS.114.001745.
4. A. F., P. A., S. M-M., et al. Melody® transcatheter pulmonary valve implantation: Results from a French registry. Arch Cardiovasc Dis 2014. Doi: 10.1016/j.acvd.2014.10.001 LK - http://sfx.library.uu.nl/utrecht?sid=EMBASE&issn=18752128&id=doi:10.1016%2Fj.acvd.2014.10.001&atitle=Melody%C2%AE+transcatheter+pulmonary+valve+implantation%3A+Results+from+a+French+registry&stitle=Arch.+Cardiovasc.+Dis.&title=Archives+of+Cardiovascular+Diseases&volume=107&issue=11&spage=607&epage=614&aulast=Fraisse&aufirst=Alain&auinit=A.&aufull=Fraisse+A.&coden=&isbn=&pages=607-614&date=2014&auinit1=A&auinitm=.
5. K AA., T BD., K CA., et al. One-Year Follow-Up of the Melody Transcatheter Pulmonary Valve Multicenter Post-Approval Study. JACC-CARDIOVASCULAR Interv 2014.
6. Nguyen HH., Shahanavaz S., Van Hare GF., Balzer DT., Nicolas R., Silva JNA. Percutaneous pulmonary valve implantation alters electrophysiologic substrate. J Am Heart Assoc 2016. Doi: 10.1161/JAHA.116.004325.
7. Cools B., Brown SC., Heying R., et al. Percutaneous pulmonary valve implantation for free pulmonary regurgitation following conduit-free surgery of the right ventricular outflow tract. Int J Cardiol 2015;186. Doi: 10.1016/j.ijcard.2015.03.108.
8. Pagourelias ED., Daraban AM., Mada RO., et al. Right ventricular remodelling after transcatheter pulmonary valve implantation. Catheter Cardiovasc Interv 2017;90(3). Doi: 10.1002/ccd.26966.
9. Boshoff DE., Cools BLM., Heying R., et al. Off-label use of percutaneous pulmonary valved stents in the right ventricular outflow tract: Time to rewrite the label? Catheter Cardiovasc Interv 2013;81(6). Doi: 10.1002/ccd.24594.
10. J. N., S. K., L. C., et al. Risk stratification, systematic classification, and anticipatory management strategies for stent fracture after percutaneous pulmonary valve implantation. Circulation 2007.
11. Li JS., Sexton DJ., Mick N., et al. Proposed modifications to the Duke criteria for the diagnosis of infective endocarditis. Clin Infect Dis 2000. Doi: 10.1086/313753.
12. Cools B., Brown S., Wevers M., et al. Right ventricle outflow tract prestenting: In vitro testing of rigidity and corrosion properties. Catheter Cardiovasc Interv 2018;91(2). Doi: 10.1002/ccd.27320.
13. McElhinney DB., Hellenbrand WE., Zahn EM., et al. Short-and medium-term outcomes after

transcatheter pulmonary valve placement in the expanded multicenter US melody valve trial. Circulation 2010. Doi: 10.1161/CIRCULATIONAHA.109.921692.
14. J. N., L. C., P. L., et al. Percutaneous pulmonary valve-in-valve implantation: A successful treatment concept for early device failure. Eur Heart J 2008.
15. O'Donnell C., Holloway R., Tilton E., Stirling J., Finucane K., Wilson N. Infective endocarditis following Melody valve implantation: Comparison with a surgical cohort. Cardiol Young 2017. Doi: 10.1017/S1047951116000494.
16. Van Dijck I., Budts W., Cools B., et al. Infective endocarditis of a transcatheter pulmonary valve in comparison with surgical implants. Heart 2015. Doi: 10.1136/heartjnl-2014-306761.
17. Habib G., Lancellotti P., Antunes MJ., et al. 2015 ESC Guidelines for the management of infective endocarditis: The Task Force for the Management of Infective Endocarditis of the European Society of Cardiology (ESC). Eur Heart J 2015. Doi: 10.1093/eurheartj/ehv319.
18. Eisen A., Shapira Y., Sagie A., Kornowski R. Infective endocarditis in the transcatheter aortic valve replacement era: Comprehensive review of a rare complication. Clin Cardiol 2012. Doi: 10.1002/clc.22052.
19. Jung CJ., Yeh CY., Shun CT., et al. Platelets enhance biofilm formation and resistance of endocarditis-inducing streptococci on the injured heart valve. J Infect Dis 2012. Doi: 10.1093/infdis/jis021.
20. Hoen B. Platelets and platelet inhibitors in infective endocarditis. Curr Infect Dis Rep 2002. Doi: 10.1007/s11908-002-0021-3.
21. Malekzadeh-Milani S., Ladouceur M., Patel M., et al. Incidence and predictors of Melody® valve endocarditis: A prospective study. Arch Cardiovasc Dis 2015. Doi: 10.1016/j.acvd.2014.09.003.
22. Bibevski S., Ruzmetov M., Fortuna RS., Turrentine MW., Brown JW., Ohye RG. Performance of SynerGraft Decellularized Pulmonary Allografts Compared With Standard Cryopreserved Allografts: Results From Multiinstitutional Data. Ann Thorac Surg 2017. Doi: 10.1016/j.athoracsur.2016.07.068.
23. Abbas JR., Hoschtitzky JA. Which is the best tissue valve used in the pulmonary position, late after previous repair of tetralogy of Fallot? Interact Cardiovasc Thorac Surg 2013. Doi: 10.1093/icvts/ivt332.
24. Pardo González L., Ruiz Ortiz M., Delgado M., et al. Pulmonary homograft stenosis in the Ross procedure: Incidence, clinical impact and predictors in long-term follow-up. Arch Cardiovasc Dis 2017. Doi: 10.1016/j.acvd.2016.09.008.
25. Yong MS., Yim D., d'Udekem Y., et al. Medium-term outcomes of bovine jugular vein graft and homograft conduits in children. ANZ J Surg 2015. Doi: 10.1111/ans.13018.

1.7 SUPPLEMENT

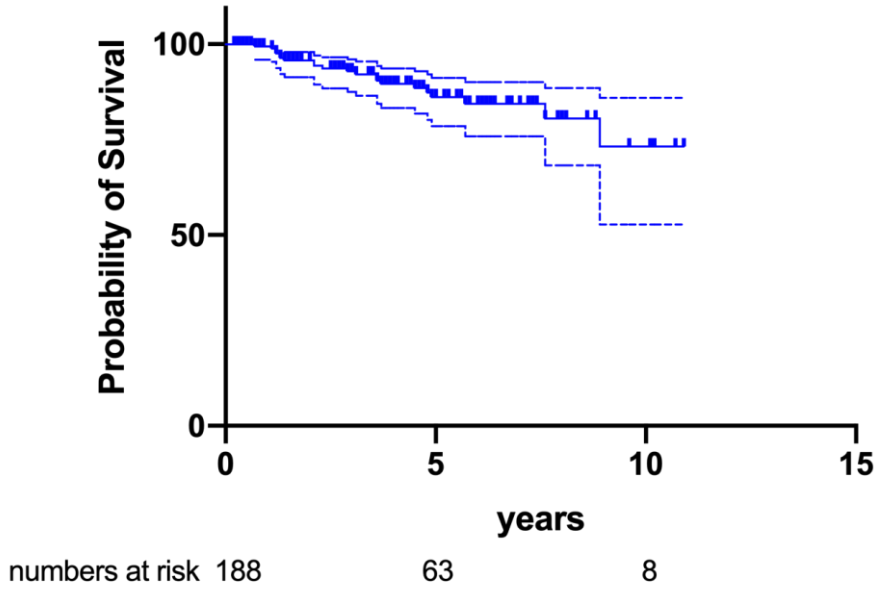

Figure S1 Kaplan-Meier plot of Valve Dysfunction. Valve dysfunction is defined as valve deterioration due to one of the following events: hemodynamic important fracture of the valved stent, endocarditis and valve thrombosis. 95% Confidence Interval

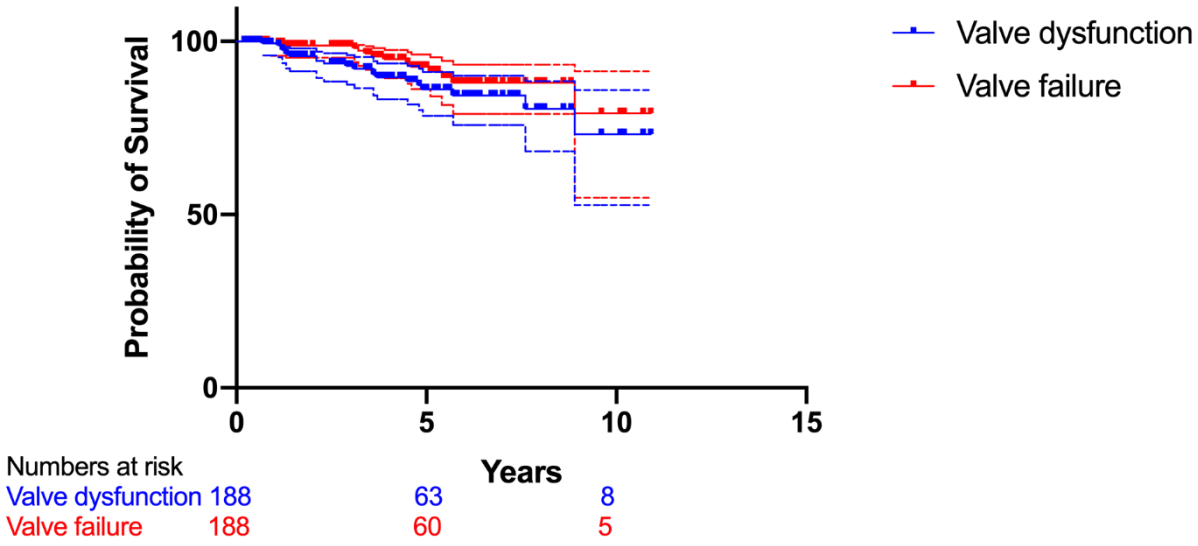

Figure S2 Kaplan-Meier plot of Valve Dysfunction (blue) and Valve Failure (red). Valve dysfunction is defined as valve deterioration due to one of the following events: hemodynamic important fracture of the valved stent, endocarditis or valve thrombosis. Valve failure is defined as re-intervention with replacement of the valve (surgically or percutaneously) or valve-related death. 95% Confidence Interval

CHAPTER 2

Feasibility and safety of pre-stenting followed by percutaneous pulmonary valve implantation in patients with tetralogy of Fallot with dilated RVOT and severe pulmonary valve regurgitation

Published as : Bjorn Cools, Stephen C. Brown, Ruth Heying, Katrijn Jansen, Derize E. Boshoff, Werner Budts, Marc Gewillig. Percutaneous pulmonary valve implantation for free pulmonary regurgitation following conduit-free surgery of the right ventricular outflow tract. Int J Card 186 (2015) 129-135

2.1 ABSTRACT

Introduction: Pulmonary regurgitation (PR) following surgery of the right ventricular outflow tract (RVOT) is not innocent and leads to significant right heart dysfunction over time. Recent studies have demonstrated that percutaneous valves can be implanted in conduit free outflow tracts with good outcomes.

Objectives: To evaluate in patients with severe PR – anticipated to require future pulmonary valve replacement - the feasibility and safety of pre-stenting dilated non-stenotic patched conduit-free right ventricular outflow tracts before excessive dilation occurs, followed by percutaneous pulmonary valve implantation (PPVI).

Patients and methods: Twenty seven patients were evaluated, but only 23 were deemed suitable based on the presence of an adequate retention zone ≤ 24mm defined by semi-compliant balloon interrogation of the RVOT. A 2 step procedure was performed: first the landing zone was prepared by deploying a bare stent, followed 2 months later by valve implantation.

Results: RVOT pre-stenting using an open cell bare metal stent (Andrastent® XXL range) was performed at a median age of 13.0 years (range: 6.0 – 44.9) with a median weight of 44.3 kg (range: 20.0 – 88.0). Ninety six percent (22/23) of patients proceeded to PPVI a median of 2.4 months (range: 1.4 – 3.4) after initial pre-stent placement. Twenty one Melody™ valves and one 26 mm Edwards SAPIEN™ valve were implanted. Complications consisted of embolization of pre-stent (n = 1), crumpling (n = 4) and mild stent dislocation (n = 2). During follow-up, no stent fractures were observed and right ventricular dimensions decreased significantly.

Conclusions: Post-surgical conduit-free non-stenotic RVOT with free pulmonary regurgitation can be treated percutaneously with a valved stent if anatomical (predominantly size) criteria are met. In experienced hands, the technique is safe with low morbidity.

2.2 INTRODUCTION

Pulmonary regurgitation (PR) after transannular patching or even limited infundibulotomy is associated with late adverse events such as aneurysmal dilation of the right ventricular outflow tract (RVOT), right ventricular dysfunction, progressive tricuspid valve regurgitation, dysrhythmias and premature sudden death.(1–3) Surgical pulmonary valve replacement (PVR) is an efficient technique to avoid these late problems.(4,5) However, this strategy is not free of either early or late complications, requiring repeated re-interventions of increasing complexity and risk. Proper timing is therefore essential not only to reduce the number of interventions, but also to limit cumulative risk and keep long term morbidity as low as possible. The ideal timing of re-intervention in order to allow a patient to experience a cardiac event-free existence as well as a normal life expectancy has yet to be determined and remains a hotly debated issue.(6) Current survival studies with long term follow-up of patient groups where current guidelines have been applied report on an ongoing excess mortality in every decade: this suggests that there is a margin for improvement and that current guidelines may require refinement.(3,7)

Percutaneous pulmonary valve implantation (PPVI) may be of benefit in these patients.(8,9) PPVI is recognized as an acceptable method for right ventricular outflow tract valve replacement in selected patients, typically with a surgical conduit. However, the majority of patients that will eventually require a pulmonary valve do not have a surgical conduit as landing zone.

In recent publications, it was shown that PPVI is effective and safe in patients with conduit-free RVOTs.(10–12) The aim of this study was to determine the safety and feasibility of RVOT stenting and subsequent PPVI in patients with non-stenotic dilating RVOTs. This included assessment of right ventricular (RV) changes and determination of the limitations and complications of this strategy and also, to start accumulating data to compare the different strategies.

2.3 METHODS

Patients were recruited from the outpatient clinics where they routinely present for annual evaluation. The main inclusion criterion for this ongoing, prospective study was severe pulmonary regurgitation (grade 3 or 4) in a conduit-free RVOT with progressive dilation of the right ventricle, where one would anticipate the need for a pulmonary valve in the near future. Such patients typically have no significant gradient across the RVOT. During the study period only the Melody™ valve (Medtronic, Minneapolis, MN, US) was considered because of re-imbursement issues. Due to the maximum indicated outer diameter of 24mm, RVOT diameter at the level of the pulmonary valve had to measure between 18 and 21mm on echocardiography to qualify for inclusion. The severity of PR was classified on color flow Doppler similar to our previous publication.(10) Patient records were used to obtain catheterization

and follow-up data. Digital measurements of catheterization data were performed using an IMPAX® viewer (Agfa Heartlab®, Mortsel, Belgium). Cardiovascular magnetic resonance imaging (MRI) was performed in some cases, but information was not used for patient selection. At the time of the study MRI could not be performed in all studied patients due to limited access to the MRI facility. The study was conducted in accordance with local Ethics Committee guidelines; fully informed consent after extensive discussion of all different strategies was obtained from the patient and parents.

2.3.1 Cardiac catheterization and PPVI: technical aspects

All procedures were performed under general anesthesia. The catheterization procedure and valve implantation were similar to that previously described.(9,10,13)

2.3.1.1 Interrogation of the RVOT

Angiography

Biplane angiography was performed in the RVOT by means of a Multi-Track™ angiographic catheter (NuMED, Inc., NY, USA) using the lateral projection for the pulmonary valve region and a frontal view with extreme cranial angulation to demonstrate the RVOT, main pulmonary artery and its bifurcation.

Guide wires

A stiff exchange length guide wire was securely positioned in a distal pulmonary artery branch (e.g. E-wire, JOTEC®, Germany; Amplatz Ultra-Stiff, COOK®, Bloomington, USA; Lunderquist™, COOK®, Bloomington, USA). It is helpful to put a curve on the wire matching the shape of the RVOT and pulmonary artery since this will facilitate balloon retrieval after stent placement by improving the inner curve.

Delineation of the RVOT anatomy (Fig. 1)

Balloon-interrogation during low-pressure sub-maximal inflation and deflation was performed using a semi-compliant, mildly oversized balloon, e.g. a 23 – 25mm Tyshak II® balloon (NuMED, Inc., Hopkinton NY, USA) (Table 1). At nominal pressure the balloon typically stretched open the outflow tract almost completely without a significant indentation (Fig. 1B); the balloon at this point has a predetermined size which facilitates interpretation of diameters. Also, absence of movement and mild indentation of the inflated interrogation balloons are important and comforting signs. If there was no or minimal indentation, simultaneous injection through the side-arm of a long Mullins sheath was carried out.

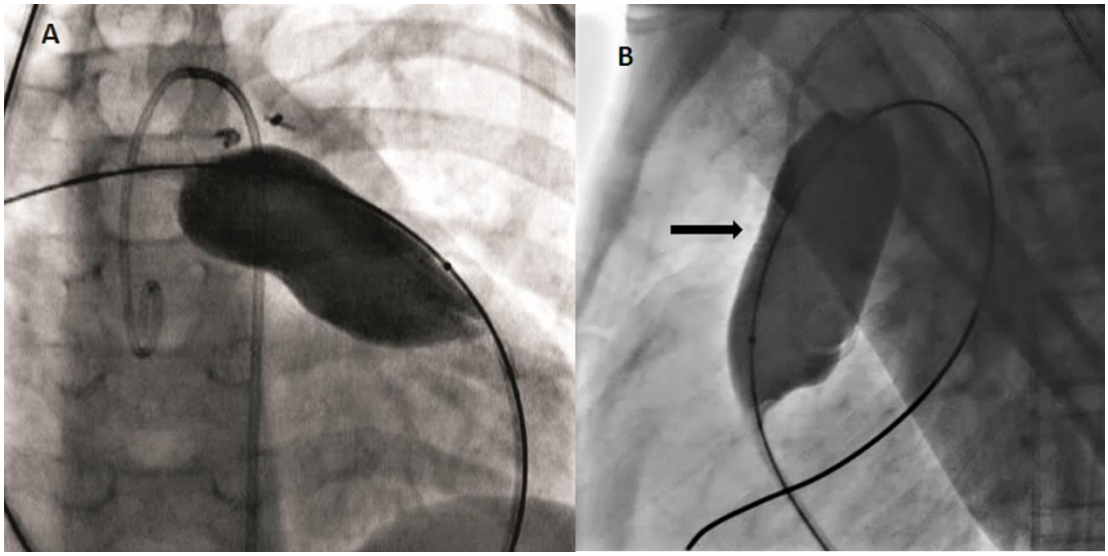

Figure 1. Balloon interrogation of RVOT A. Cranially tilted antero-posterior view of 23mm Tyshak II® balloon inflated in RVOT patient 12, with mild indentation. B. Lateral view of 25mm Tyshak II® balloon fully inflated in RVOT of patient 23. Note minimal indentation of future landing zone (arrow).

This assists in further outlining the RVOT, provides evidence that the inflated balloon is securely seated (confirms probable stent fixation) and to assess the (un)likelihood of a paravalvular leak post valve implantation. Simultaneous aortogram was performed during full inflation of the balloon to exclude coronary compression.

2.3.1.2 Pre-stenting the RVOT

Stent placement (Figs. 2 & 3)

Open cell design, bare metal stents (AndraStent® XXL series, Andramed, GmbH, Reutlingen Germany) were hand-crimped on balloon-in-balloon (BIB™) balloons (NuMED, Inc., Hopkinton NY, USA). More detail can be viewed in Table 1. The BIB™ balloons were selected to be 2 -4 mm larger than the retention zone or –most frequently- a BIB™ 24mm was used if only mild indentation of a 25 mm Tyshak II® was observed. Ideally the length of the balloon should be matched to the stent; if too long, these large balloons will push themselves back due to the distal shoulders locked in the bifurcation.

		RVOT pre-stent								PPVI		
No.	Surgical procedure	Age at prestent(y)	Weight(kg)	ECHO RVOT min diam	Angio RVOT min diam	Interrogation balloon diam	AndraStent® XXL length	BIB® Balloon (diam)	fluoroscopy time (min)	Ensemble™ Diam	time After pre-stent (mo)	Fluoroscopy time (min)
1	TA	7.2	21	15	15.7	20	39	22	14.0	22	2.4	15.0
2	TA	12.3	34	19	16.7	23	39	24	9.3	22	1.6	11.0
3	TA	6.0	20	18	18.5	20	39	22	8.1	22	2.3	11.0
4	TA	7.3	26	17	18.0	23	39	18	12.7	20	1.9	18.9
5	TA	16.5	88	21	23.1	25	43	25	22.7	24*	3.4	9.0
6	IP	8.6	26	22	19.0	25	30	24	10.0	NA	NA	10.0
7	TA	12.2	45	20	23.0	25	39	24	4.9	22	2.7	6.5
8	TA	9.7	38	19	18.0	25	39	24	14.4	22	2.3	12.0
9	TA	13.1	46	20	17.1	20	39	20	23.0	20	2.8	40.0
10	TA	11.9	38	17	14.0	23	48	22	15.4	22	2.2	22.1
11	IP	14.0	58	17	24.0	25	57	24	11.0	22	3.3	15.8
12	TA	9.2	36	18	22.0	23	43	24	8.0	22	1.9	12.3
13	TA	7.0	29	19	19.0	23	39	24	19.0	22	2.1	18.9
14	TA	8.3	21	19	22.0	23	39	22	14.4	22	3.0	20.4
15	IP	17.9	70	21	21.0	25	43	24	10.0	22	1.9	9.2
16	TA	44.9	80	20	19.0	23	48	24	35.0	22	1.4	8.8
17	TA	20.8	78	22	22.9	25	43	24	14.0	22	3.0	26.2
18	TA	6.5	24	20	20.0	25	39	24	11.0	22	3.0	17.0
19	IP	13.7	42	22	21.0	25	39	24	8.5	22	2.4	9.7
20	TA	10.3	40	21	21.1	25	39	22	12.2	22	2.5	10.8
21	TA	16.3	80	20	24.0	25	43	24	18.5	22	2.1	10.1
22	IP	10.7	36	20	18.0	25	43	24	11.6	22	2.1	13.5
23	TA	15.3	43	19	22.0	25	57	25	22.0	22	1.9	18.0

Table 1. Patient characteristics and procedural information. BIB®, balloon-in-balloon delivery balloon; IP, infundibular patch; TA, transannular patch. PPVI: percutaneous pulmonary valve implantation; RVOT right ventricular outflow tract; All diameters (diam) in mm. -, not available. * 26mm Edwards valve implanted. Patient 6 went for surgical valve replacement after stent migration.

The AndraStent® XXL shortens 5-15% at 20 – 24 mm distention (bench testing) and was chosen long enough to leave no redundant RVOT. Stents placed in a conduit free non-stenotic RVOT tend to move proximally during inflation; the stents were therefore mounted slightly more distally on the delivery balloon than the traditional central mounting position. During stent mounting the outer balloon was slightly inflated to create mild shoulders proximal and distal to the stent – the distal shoulder assists progress in the long sheath during difficult passage and the proximal shoulder prevents the stent from sliding-off. As we gained experience, we started deployment more distally in the main pulmonary artery in order to ensure that proximal movement is compensated for and that the stent is positioned across the intended retention zone. Once the stent was in the desired position and uncovered, BIB® balloons were sequentially inflated using hand insufflation as only low pressure is required to open and anchor the stent. This allows maximal control during deployment, with the balloon being inflated until the stent is anchored onto the wall or retention area: this is visually confirmed by either seeing an indentation in the stent, or seeing the cells splay open and hook into the walls or, rarely, by means of a control angiogram through the side-arm of the sheath to observe complete occlusion of the RVOT by the inflated balloon-stent unit. If required, the 24 mm BIB™ was slightly overinflated up to 25-26 mm (off-label). It is important to keep the tip of the long sheath close to the balloon since this will allow the operator to stabilize the system and limit the stent from being milked back.

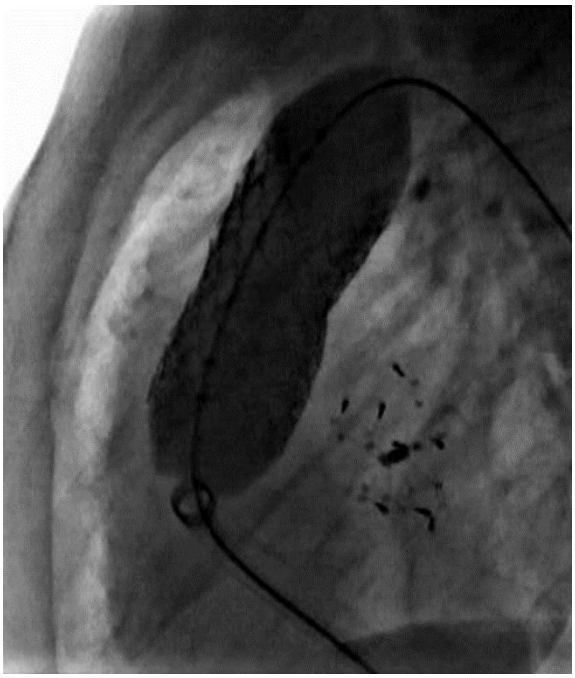

Figure 2. Implantation of prestent in RVOT. AndraStent® 39XXL mounted on 22mm BIB™ balloon with outer balloon inflated. Note nice indentation posteriorly which will assist in keeping stent secure (small arrow). Open cells act as anchors by hooking onto surrounding tissue (thick arrow).

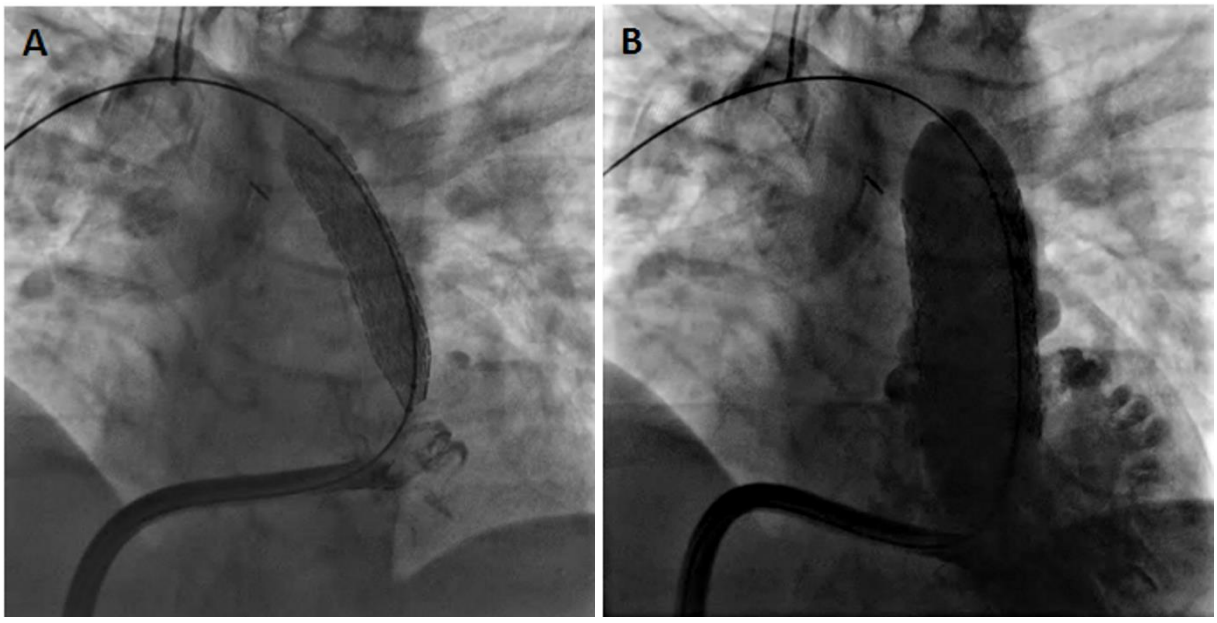

Figure 3. Prestent RVOT with AndraStent 57XXL in patient 23. A. Inner balloon of 24mm Balloon-in-balloon (Numed, USA) BIB™ inflated and in good position. B. Outer balloon insufflated. Stent pushed slightly back by BIB™ due to smaller diameter of the right pulmonary artery and encroachment on bifurcation. Also notice how close the long sheath is positioned to BIB™ balloon in order to allow the operator to stabilize or push system forwards during inflation. Angiography performed via long sheath illustrates good apposition of stent to RVOT walls.

2.3.1.3 Balloon retrieval after RVOT stent placement (Fig. 4)

The balloon should be carefully retrieved as it may cause displacement or embolization of the stent. If concerned (n = 2), we placed a second guide wire using a balloon tipped catheter through the stent, advanced another long sheath into the stent and removed the dilator - this enabled the operator to "push" with the second sheath stabilizing the stent and keeping it in place whilst withdrawing the original balloon. In general, we consider these newly implanted stents insufficiently stable to allow the manipulations typically required for pulmonary valve implantation at this point. Therefore, a period of 2 months was allowed for a tissue ingrowth to secure the stent.(14)

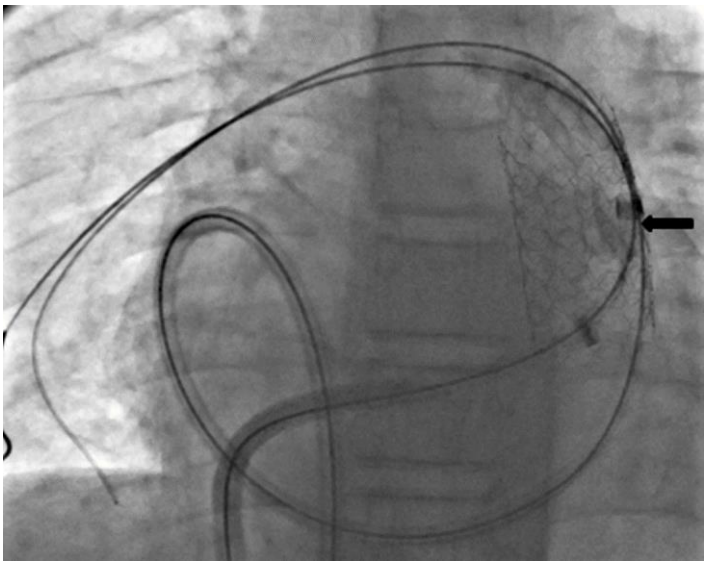

Fig. 4. Stabilizing RVOT stent for balloon retrieval in patient 23. Due to difficulty during retrieval stent was stabilized by exerting pressure with a second long sheath (arrow).

2.3.1.4 PPVI

At the second catheterization, we used a balloon-tipped catheter to re-enter the original RVOT stent to ensure that the guide wire remained free of the stent cells. Once again we recommend pre-bending the wire, but at a more acute angle with the intention to facilitate passage on the way in. If a stent protruded too much into the RVOT and passing of the Ensemble™ could potentially be difficult, the proximal end was flared open (n = 2). Alternatively, a covered (closed cell) stent can be placed to prevent hooking of the valved stent delivery system onto the open cells of the previously placed RVOT stent (n = 2); or, it may be used to decrease the internal diameter of the stented RVOT in order to ensure good fixation of the percutaneous pulmonary valve (n = 2). A jugular approach will allow the Ensemble™ to enter the RVOT stent more centrally with less friction on the lateral walls of the RVOT.

The valved stent should be fully expanded to ensure complete contact with the RVOT stent. If required, the 22mm Ensemble™ BIB may be slightly further expanded up to 24 mm by adding more volume (off-label use).

2.3.2 Follow-up

Patients were re-evaluated clinically, electrocardiographically and echocardiographically after 1, 3, 6 and 12 months, and annually thereafter. Magnetic resonance imaging (MRI) is performed after 3 months. Chest roentgenogram is performed after 6 and 12 months, and annually thereafter for 3 years, if indicated.

2.3.3 Statistical analysis

Data was analyzed using standard statistical software (SPSS for windows, SPSS Inc., IBM Company, Chicago, Illinois, US, version 18). A Student-t test was used to compare normally distributed data. Continuous data were expressed as medians with the minimum and maximum values. A p-value < 0.05 was considered significant.

2.4 RESULTS

During a three year period ranging from November 2010 to May 2013, 28 patients were interrogated for bare metal pre-stenting; 4 patients were deemed unsuitable because of lack of indentation (n = 2) or the presence of significant flow around an inflated 25 mm RVOT interrogation balloon (n = 2). No patient was excluded because of potential coronary artery compression. The remaining 23 patients (16 males and 7 females) form the basis of this report: these include 3 patients who were previously described.(10) All patients had undergone surgery for tetralogy of Fallot at a median age of 0.5 years (range: 0.2 – 12); 18/23 (80%) had received a limited transannular patch during initial repair and the remainder had an infundibular patch.

2.4.1 RVOT pre-stent

RVOT pre-stenting was performed at a median age of 13.0 years (range: 6.0 – 44.9) with a median weight of 44.3 kg (range: 20.0 – 88.0) and height of 143.7 cm (range: 100 – 192), respectively. Patient and procedural characteristics can be viewed in Table 1. There was no significant gradient across the RVOT before initial stent placement (median 9 mmHg; range: 0 – 23). Due to the distensability of the RVOT, and because the available valved stent could reach maximally 24 (to 25) mm, a 25 mm Tyshak II® balloon was typically used for interrogation. Only AndraStent® XXLs were used (30 – 57 mm) and, as operator experienced increased, larger outflow tracts treated (Table 1). Stents were mounted on 18 - 24mm BIB™ balloons and delivered through a 14F long Mullins sheath (COOK® Medical, Bloomington,

USA). In 2 patients (nos. 5 & 23) the BIB™ was over expanded to 25-26 mm. All stents were implanted via the femoral venous route, except in patient no. 5 where the right jugular vein was used since the femoral veins were inaccessible. Fluoroscopy lasted a median of 14.3 minutes (range: 4.9 – 35.0) and radiation dose a median of 7522.2 μGym^2 (range: 164.0 -19,015.0).

2.4.2 PPVI

Ninety six percent (22/23) of patients proceeded to PPVI a median of 2.4 months (range: 1.4 – 3.4) after initial stent placement. Twenty one Melody™ valves (Medtronic, Minneapolis, MN, US) were implanted: nineteen (n = 19) on a 22 mm and two (n = 2) on a 20 mm Ensemble™ system. In patient no. 5 a 26mm Edwards SAPIEN™ valve (Edwards Life Sciences Inc, Irvine, CA,US) was implanted due to concerns regarding the diameter of the RVOT. The most common route for valve insertion was via the femoral veins (n = 19), right jugular vein (n = 2) and subxyphoidal hybrid procedure (n = 1, patient no. 5). In patient no. 9, access was changed to the jugular venous route after difficulties with delivery were encountered with the transfemoral route. A covered 45mm 8 Zig Cheatham Platinum stent (CCP) mounted on a 24mm BIB™ balloon was placed before Melody™ valve implantation during the same session in patients 5 and 17 to reduce the diameter of the RVOT, since during implantation of the initial pre-stent, a 24mm BIB™ balloon was overinflated to ensure secure seating of the stent. Fluoroscopy lasted a median of 15.3 minutes (range: 6.5 – 40.0) and radiation dose a median of 3956.9 μGym^2 (range: 872.0 -12 972.0).

Pre-discharge echocardiography showed gradients less than 10 mmHg in all patients and none or trivial pulmonary regurgitation; 1 patient had a minimal paravalvular leak.

2.4.3 Follow-up

After 3 months M-mode right ventricular end diastolic dimension (RVEDD) decreased an average of 20% ($p < 0.005$) from a median z score of 3.9 (range: 1.8 - 5.2) before valve implantation to a median z score of 2.3 (range: -0.5 – 3.8) ($p < 0.001$). Left ventricular end diastolic dimension remained essentially unchanged. Paired magnetic resonance imaging before and after was available for 7 patients and showed that right ventricle end diastolic volumes decreased significantly from a median of 118.4 ml/m^2 (range: 88.4 – 156.1) to 104.1 ml/m^2 (range: 81.9 – 129.3) ($p = 0.05$) and left ventricular volumes improved from 77.0 ml/m^2 (range: 69.1-147) to 88.6 ml/m^2 (range: 79-157) ($p = 0.037$) (Fig. 5). Subjective exercise capabilities also improved: upon specific request all patients reported specific physical activities that could be performed easier or faster than before valve replacement.

No stent fractures of the Melody™ CP stent were observed on chest radiography at 6 months and yearly after implantation. Valve function remained very stable during the short follow-up of 14 - 42 months without a significant increase of gradient nor regurgitation (mean gradient 16 mmHg, range 5-30; median PR 0, range 0-1).

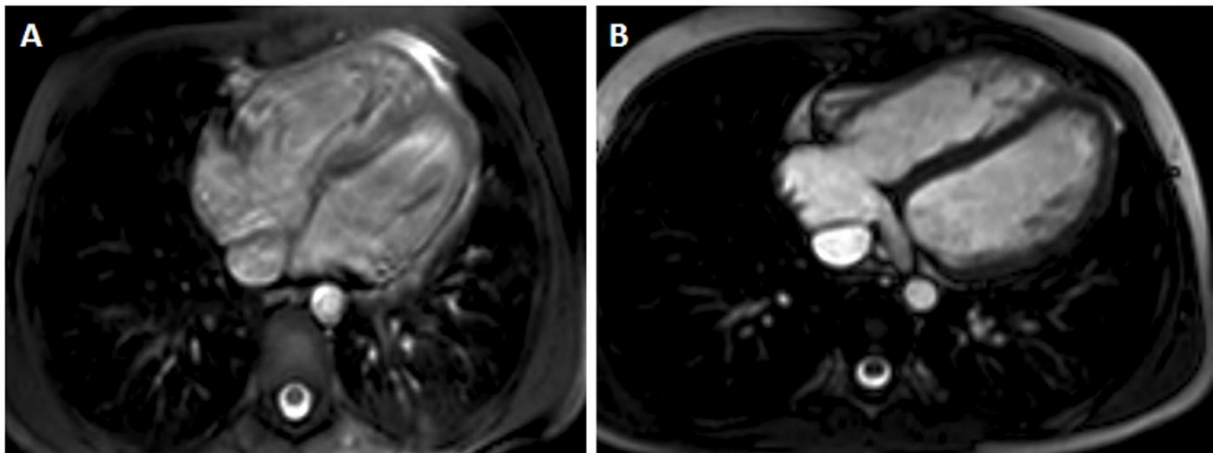

Figure. 5. Four chamber MRI imaging**.** MRI before (A) and following (B) valve replacement. Decrease in volume of right ventricle and increase in left ventricular volume.

2.4.4 Complications

All patients were hemodynamically stable throughout the procedures and there were no periprocedural deaths or coronary artery compromise. In one patient (no. 6), the RVOT stent migrated into the right ventricle after placement and the patient was sent for surgery. This occurred early in the series and in retrospect was avoidable. In 2 patients (nos. 17&23) the stent migrated proximally while withdrawing the BIB™; the AndraStent® remained in satisfactory position and both patients later proceeded to Melody™ valve implantation. Crumpling of the stent during valved stent insertion was observed in 4 patients (nos. 5, 9, 12 and 22) (Fig. 6).

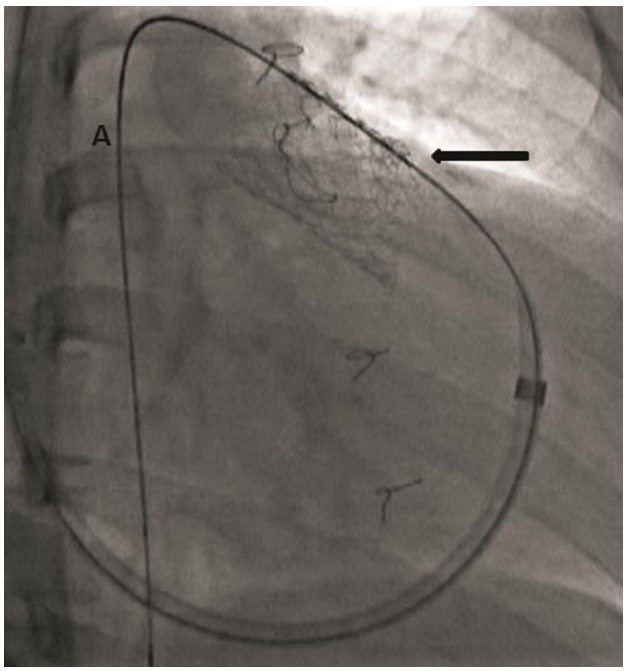

Figure 6. Frontal projection of crumpled stent. At reentry of the stent 2 months after initial deployment in patient 5, crumpling of prestent occurred (arrow).

In patient 5 (SAPIEN valve), the pre-stent was implanted with the BIB™ balloon overinflated to 25 mm; at that point in our experience we opted not to use a Melody™ valve because of recommended maximum size. We first tested passage with the Sapien delivery system - this resulted in crumpling the stent. Consequently, we decided on a hybrid approach from subxyphoidal 2 months later which allowed easy deployment after reopening the pre-stent with a covered CP-stent™. In the other 3 patients, crumpling occurred during advancement of the Ensemble™ delivery system, but this did not preclude optimal positioning for valve implantation. In patient 24 (pre-stenting up to 26 mm) the landing zone was first trimmed down to 24 mm by means of a covered CP stent™. The Melody™ valve was then deployed using a 22 mm Ensemble™. However, after withdrawal of the Ensemble™, the Melody™ migrated proximally (insufficient expansion) but remained within the original pre-stent. The Melody valve was subsequently further expanded using a 24mm BIB™ and safely secured.

2.5 DISCUSSION

Results of this study show that PPVI in young patients with dilating, conduit free non-stenotic RVOT's is feasible. Creation of an adequate landing zone by pre-stenting the RVOT makes the PPVI procedure safe and predictable.

Ninety six percent of stents were safely implanted in the conduit free RVOT's. This finding is in agreement with recent reports where it was also convincingly demonstrated that stents can be securely positioned in larger outflow tracts with a waist.(10,11) It should be emphasized that this study was carried out in younger patients using a different strategy - earlier stenting for a progressively dilating RVOT with the aim to prevent large aneurysmal dilation of the RV and RVOT with the intention to normalize "early" right ventricular volumes. Our results demonstrate that stents can be safely secured if a stretched retention zone of ≤ 24mm exists during semi compliant balloon interrogation of the RVOT.

A potential disadvantage of RVOT stent placement is that pulmonary regurgitation persists or may even be aggravated, but none of our patients became symptomatic; pulmonary regurgitation is known to be well tolerated for a limited period.(15) A stent in the RVOT will fix the size and prevent further dilation of that zone; this maneuver may delay the need for RVOT valve replacement for months or years, but this possibility was not explored in the current study.

2.5.1 Follow-up

During our short term follow up, right ventricular dimensions and volumes improved in all patients - a finding reported in other studies.(11) Furthermore, subjective parameters of exercise ability improved during short term follow-up. These and other outcomes will receive attention in the course of the ongoing phase of this study.

We observed no stent fractures or stent compressions; the rounded shape remained preserved in all patients. The absence of stent compression-fracture is important for the longevity and long-term function of the valves. This observation is quite different compared to Melody™ valves implanted in shrunken homografts and other conduits: in our group of patients the RVOT is large and dilated and the place for the stent-valve was already provided - we consider it unlikely that the heart or surrounding tissues would exert significant localized compressing forces on the stents.

2.5.2 Complications

Overall, complications could be managed. The stent which migrated could have been avoided and occurred during the early learning curve. Factors leading to the embolization included selection of a too short a stent as well as incorrect positioning.

2.5.3 Changes of management strategies

Early surgical repair of tetralogy of Fallot remains the treatment of choice.(1) In the 1960's, postoperative death was predominantly related to residual stenosis, while pulmonary regurgitation was considered well tolerated.(16,17) However, after an event free period of 2 to 3 decades, patients started presenting with episodes of ventricular tachycardia and sudden death.(1,3) It then became clear that pulmonary regurgitation (PR) was not indefinitely tolerated but caused a progressive deterioration in right ventricular function and electrical stability.(18) Patients were initially considered for pulmonary vale implantation only when they became symptomatic, but it soon became clear that this strategy yielded suboptimal results. Several studies showed that valve replacement at that stage allowed little if any recuperation of RV size and mechanical dysfunction with persistence of electrical instability.(19–23)

Pulmonary valve implantation at an earlier stage was clearly indicated. The perfect treatment should consist of valve replacement with a valved conduit of adult dimensions with no procedural risk and perfect long term function of the valve. However, this perfect solution in patients with tetralogy of Fallot was not available in the nineties: operative risk was low but not zero, and all valved conduits had a limited lifespan requiring several surgical replacements with a progressive difficulty-morbidity-risk.(24) Thus, avoiding a "too early" replacement and ideal timing became important in order to reach the ultimate end-point: reach old age without cardiac events and with adequate exercise performance. Assessing strategies with such distant end-points is difficult. The search for the best surrogate end-point or predictive marker for irreversible or late dysfunction started: RV size, RV systolic or diastolic function, regurgitant fraction, exercise capacity etc. Currently, the marker most commonly used is RV size measured with MRI volumetrics with a current end diastolic threshold of 160-170ml/m^2.(24) Pulmonary valve implantation just below this marker predicts some (but incomplete) diminishing of RV size; however, this threshold has not been shown to be predictive or associated with a good survival

free of cardiac events until old age. Several authors now advocate more restrictive volumes in the guidelines since it appears that the nearer to normal (average: 79±14 ml/m^2) right ventricular volumes return after PVR, the better the right ventricular substrate can remodel with lengthier electrical stability.(24–30) As clinicians, we should remain open-minded: we should not repeat the errors of the late 1980s when we presumed that any degree of PR would be well tolerated for a lifetime. Equally so, we must remain critical towards the current "guidelines" which have some logic background, but only consider upper limits of tolerance without knowledge of late outcome.

In the meantime, the therapeutic options have changed markedly: percutaneous valve replacement at low (and progressively decreasing) risk is possible with valves that, if implanted under ideal conditions, are very competitive with good longevity.(31) This brings us back to the initial ideal treatment strategy: instead of seeing how far one can allow the RV to be damaged before compromising life expectancy and ventricular function, aim for valve replacement when an adult sized valve can be implanted, provided this happens at near zero risk and with virtual perfect late outcomes. Such strategy allows to (hopefully) avoid going beyond the ill-defined point of irreversible damage to the RV. Conversely, earlier initial valve replacement will induce different nature and timing of re-interventions, which over a lifetime may or may not be beneficial. With the current imperfect solutions, different strategies need to be explored, keeping in mind that the answer pertaining to final outcome can only be expected in 3 to 4 decades.

2.6 Conclusions

Post-surgical conduit-free non-stenotic RVOT with free pulmonary regurgitation can be stented and percutaneous valve replacement can be performed if anatomical (predominantly size) criteria are met. In experienced hands, the technique is safe with acceptable morbidity. Early results on functional class and RV size are promising. However, the long term superiority of any treatment strategy will only be answered in the decades to come.

REFERENCES

1. Sarris GE., Comas J V., Tobota Z., Maruszewski B. Results of reparative surgery for tetralogy of Fallot: Data from the European Association for Cardio-Thoracic Surgery Congenital Database. Eur J Cardio-Thoracic Surg 2012. Doi: 10.1093/ejcts/ezs478.
2. D'Udekem Y., Ovaert C., Grandjean F., et al. Tetralogy of Fallot: Transannular and right ventricular patching equally affect late functional status. Circulation 2000. Doi: 10.1161/01.cir.102.suppl_3.iii-116.
3. Hickey EJ., Veldtman G., Bradley TJ., et al. Late risk of outcomes for adults with repaired tetralogy of Fallot from an inception cohort spanning four decades. Eur J Cardio-Thoracic Surg 2009. Doi: 10.1016/j.ejcts.2008.06.050.
4. Kim HW., Seo DM., Shin HJ., Park JJ., Yoon TJ. Long term results of right ventricular outflow tract reconstruction with homografts. Korean J Thorac Cardiovasc Surg 2011. Doi: 10.5090/kjtcs.2011.44.2.108.
5. Yuan SM., Mishaly D., Shinfeld A., Raanani E. Right ventricular outflow tract reconstruction: Valved conduit of choice and clinical outcomes. J Cardiovasc Med 2008. Doi:

10.2459/JCM.0b013e32821626ce.
6. Geva T. Indications for pulmonary valve replacement in repaired tetralogy of fallot: The quest continues. Circulation 2013. Doi: 10.1161/CIRCULATIONAHA.113.005878.
7. Cuypers JAAE., Menting ME., Konings EEM., et al. Unnatural history of tetralogy of fallot: Prospective follow-up of 40 years after surgical correction. Circulation 2014. Doi: 10.1161/CIRCULATIONAHA.114.009454.
8. Momenah TS., El Oakley R., Al Najashi K., Khoshhal S., Al Qethamy H., Bonhoeffer P. Extended Application of Percutaneous Pulmonary Valve Implantation. J Am Coll Cardiol 2009. Doi: 10.1016/j.jacc.2008.08.061.
9. Bonhoeffer P., Boudjemline Y., Qureshi SA., et al. Percutaneous insertion of the pulmonary valve. J Am Coll Cardiol 2002. Doi: 10.1016/S0735-1097(02)01822-3.
10. Boshoff DE., Cools BLM., Heying R., et al. Off-label use of percutaneous pulmonary valved stents in the right ventricular outflow tract: Time to rewrite the label? Catheter Cardiovasc Interv 2013;81(6). Doi: 10.1002/ccd.24594.
11. Demkow M., Biernacka EK., Śpiewak M., et al. Percutaneous pulmonary valve implantation preceded by routine prestenting with a bare metal stent. Catheter Cardiovasc Interv 2011. Doi: 10.1002/ccd.22700.
12. Boudjemline Y., Brugada G., Van-Aerschot I., et al. Outcomes and safety of transcatheter pulmonary valve replacement in patients with large patched right ventricular outflow tracts. Arch Cardiovasc Dis 2012. Doi: 10.1016/j.acvd.2012.05.002.
13. Khambadkone S., Coats L., Taylor A. Percutaneous Pulmonary Valve Implantation in Humans: Results in 59 Consecutive Patients. ACC Curr J Rev 2005. Doi: 10.1016/j.accreview.2005.11.088.
14. Gewillig, M.; Mertens L. SL. Percutaneous fenestration of the atrial septum with a stent: an experimental study. Cor Eur 4 1995:122–5.
15. Gibbs JL., Uzun O., Blackburn MEC., Parsons JM., Dickinson DF. Right ventricular outflow stent implantation: An alternative to palliative surgical relief of infundibular pulmonary stenosis. Heart 1997. Doi: 10.1136/hrt.77.2.176.
16. Barratt Boyes BG., Neutze JM. Primary repair of tetralogy of Fallot in infancy using profound hypothermia with circulatory arrest and limited cardiopulmonary bypass: a comparison with conventional two stage management. Ann Surg 1973. Doi: 10.1097/00000658-197310000-00003.
17. Zaragoza-Macias E., Stout KK. Management of pulmonic regurgitation and right ventricular dysfunction in the adult with repaired Tetralogy of Fallot. Curr Treat Options Cardiovasc Med 2013. Doi: 10.1007/s11936-013-0258-1.
18. Bouzas B., Kilner PJ., Gatzoulis MA. Pulmonary regurgitation: Not a benign lesion. Eur Heart J 2005. Doi: 10.1093/eurheartj/ehi091.
19. Murphy JG., Gersh BJ., Mair DD., et al. Long-Term Outcome in Patients Undergoing Surgical Repair of Tetralogy of Fallot. N Engl J Med 1993. Doi: 10.1056/NEJM199308263290901.
20. Nollert G., Fischlein T., Bouterwek S., Böhmer C., Klinner W., Reichart B. Long-term survival in patients with repair of tetralogy of Fallot: 36- year follow-up of 490 survivors of the first year after surgical repair. J Am Coll Cardiol 1997. Doi: 10.1016/S0735-1097(97)00318-5.
21. Gatzoulis MA., Balaji S., Webber SA., et al. Risk factors for arrhythmia and sudden cardiac death late after repair of tetralogy of Fallot: A multicentre study. Lancet 2000. Doi: 10.1016/S0140-6736(00)02714-8.
22. Therrien J., Marx GR., Gatzoulis MA. Late problems in tetralogy of Fallot - Recognition, management, and prevention. Cardiol Clin 2002. Doi: 10.1016/S0733-8651(02)00010-3.
23. Therrien J., Siu SC., McLaughlin PR., Liu PP., Williams WG., Webb GD. Pulmonary valve replacement in adults late after repair of tetralogy of Fallot: Are we operating too late? J Am Coll Cardiol 2000. Doi: 10.1016/S0735-1097(00)00930-X.
24. Geva T. Repaired tetralogy of Fallot: The roles of cardiovascular magnetic resonance in evaluating pathophysiology and for pulmonary valve replacement decision support. J Cardiovasc Magn Reson 2011. Doi: 10.1186/1532-429X-13-9.

25. Cheung EWY., Wong WHS., Cheung YF. Meta-analysis of pulmonary valve replacement after operative repair of tetralogy of fallot. Am J Cardiol 2010. Doi: 10.1016/j.amjcard.2010.03.065.
26. Oosterhof T., Van Straten A., Vliegen HW., et al. Preoperative thresholds for pulmonary valve replacement in patients with corrected tetralogy of Fallot using cardiovascular magnetic resonance. Circulation 2007. Doi: 10.1161/CIRCULATIONAHA.106.659664.
27. Frigiola A., Hughes M., Turner M., et al. Physiological and phenotypic characteristics of late survivors of tetralogy of fallot repair who are free from pulmonary valve replacement. Circulation 2013. Doi: 10.1161/CIRCULATIONAHA.113.001600.
28. Tandri H., Daya SK., Nasir K., et al. Normal Reference Values for the Adult Right Ventricle by Magnetic Resonance Imaging. Am J Cardiol 2006. Doi: 10.1016/j.amjcard.2006.07.049.
29. Lorenz CH. The range of normal values of cardiovascular structures in infants, children, and adolescents measured by magnetic resonance imaging. Pediatr Cardiol 2000. Doi: 10.1007/s002469910006.
30. Frigiola A., Tsang V., Bull C., et al. Biventricular response after pulmonary valve replacement for right ventricular outflow tract dysfunction: is age a predictor of outcome? Circulation 2008. Doi: 10.1161/CIRCULATIONAHA.107.756825.
31. Gillespie MJ., Rome JJ., Levi DS., et al. Melody valve implant within failed bioprosthetic valves in the pulmonary position: A multicenter experience. Circ Cardiovasc Interv 2012. Doi: 10.1161/CIRCINTERVENTIONS.112.972216.

CHAPTER 3

Resistance to deformation of stents, combinations of stents and risk of corrosion

Published as : Bjorn Cools, Stephen Brown, Martine Wevers, Jan Van Humbeeck, Derize Boshoff, Cis Verdonckt, Marc Gewillig. Right ventricle outflow tract pre-stenting: In vitro testing of rigidity and corrosion properties. Catheter Cardiovasc Interv. 2017; 1-7

3.1 ABSTRACT

Background: The aim of this study was to assess the resistance to compression (stiffness) of frequently used stents for right ventricular outflow tract pre-stenting. Also, to assess the corrosion potential when different types of stent alloys come into contact with each other.

Method: Different stents were tested in vitro in various combinations at specialized metallurgic laboratories. A bench compression test was used to assess resistance to compression of singular and joined combinations of stents. Corrosion was evaluated by standardized electrochemical galvanic tests in physiological solutions at 37°C. Single stents and combinations of stents were evaluated over a period of 4 -12 weeks.

Results: Relative stiffness of the stents Optimus™/AndraStent® XXL/IntraStent™ LD Max/ 8zig Cheatham-Platinum stent™, expressed as load per length to deform the stent for 1 mm at 22 mm was 100/104/161/190. Adding additional stents to a single stent significantly strengthened the joined couples ($p < 0.001$). The lowest galvanic corrosion rates (about 0.000001 mm/year) were observed for the joined CP-AndraStent, Andra-Sapien and Andra-SapienXT. The corrosion rate for coupled CP-Sapien and CP-SapienXT was somewhat higher (about 0.000003 mm/year). The materials with the highest corrosion rates resulted in material losses of respectively 17 and 24 µg/year, which is negligible over a lifetime.

Conclusion: Adding stents to a single stent significantly increases stiffness which will reduce the risk of metal fatigue failure. Corrosion of individual stents or stent combinations occurs, but is negligible over a human lifetime with low risk of biological effects. No mechanical integrity problems are thus expected since there is only 0.3% of the initial diameter of the struts of a stent that will be lost as a consequence of corrosion after 100 years.

3.2 INTRODUCTION

Stent dysfunction such as fracture and recompression is a major concern for long-term function after percutaneous pulmonary valve implantations (PPVI), since it may lead to hemodynamic compromise.(1–5) A valved stent is exposed to mechanical stress loads resulting in recompression and strain which ultimately may result in metal fatigue and stent fractures. Stent fractures have been described in up to 20% of Melody™ (Medtronic Inc., Minneapolis, MN, US) implants during the first year with hemodynamic compromise requiring re-intervention.(6) Lack of data regarding physical properties of large stents such as resistance to deformation and corrosion hampered guiding principles for the use of stents to prepare the right ventricular outflow tract (RVOT) for a valved stent.(7) As a result, the Melody™ valve was initially implanted without pre-stenting of the conduit. However, soon after the initial experiences, RVOT-obstruction and stent fractures forced protocols to be adapted and pre-stenting became routine in the majority of implanting centers.(6–8)

The aim of this strategy was to create an ideal landing zone and to reduce the risk of development of stent fractures. Medium-term follow-up has demonstrated that pre-stenting of the conduit significantly reduces the risk of developing hemodynamically important stent fractures.(3,8,9)

Pre-stenting adds stiffness and stability by creating a framework in the valve landing zone which redistributes stresses over the whole metal frame, reducing strain and metal fatigue in the material and therefore delays or may avoid fracture over a human lifetime. Several different stents are available and stents are selected based on length, diameter, cell design, material, compressibility, shortening, dilatability, rigidity, strut thickness, sharpness of edges and covering. In the clinical setting, either one or more different stents with different metallic contents may be used. However, when different metals are in close physical contact, galvanic currents may develop which may give rise to corrosion.(10,11) Corrosion may also be influenced by electromagnetic and thermodynamic forces in the body. As a result of continued corrosion, theoretically, stents may be at risk of not maintaining their strength. Metal ions may be released into the surrounding tissues; in hip replacements early degeneration of prostheses was associated high serum levels of cobalt chrome which may be toxic.(10,11)

Data on metal fatigue and fracture rates of the different stents used in PPVI is not available, especially data on combinations of different types of stents as used during pre-stenting. After Palmaz and Mullins published their first results of stent use in humans in 1988, accounts of the biological behavior of stents in vascular structures emerged in the following years.(12–14) Reports of corrosion testing of stents composed of nitinol, titanium and stainless steel have been published.(15–19) There is, however, limited published data of strength and corrosion tests for the commonly used stents during PPVI.

The aim of this study was to assess the resistance to flattening (stiffness) of frequently used stents for RVOT pre-stenting as well as the corrosion potential when different types of stent alloys come into contact with each other.

3.3 MATERIALS AND METHODS

Different stents were tested in vitro in various combinations at specialized metallurgic laboratories: department of Metallurgy and Materials Engineering, University of Leuven and METALogic NV, Rotselaar, Belgium.

The stents were tested in vitro in various combinations. The individual stents and composition can be viewed in Table 1. The stents were coupled in various combinations consisting of one to three stents. (AN = AndraStent® XXL (Andramed, Reutlingen, Germany), OP = Optimus™ XXL stent (AndraTech, Koblenz, Germany) , IN = IntraStent™ LD Max (ev3, Plymouth, MN, USA), CP = 8 zig Cheatham Platinum stent™ (NuMED, Hopkinton, NY, USA).

Stent	Manufacturer	Materials				Strut thickness (um)
CP bare	Numed, NY, USA	Platinum Iridium	laser weld, gold cover	closed cell	8Zig pattern	330
Andra XXL	Andramed, Reutlinger, Ger	Cobalt Chrome	Laser cut	hybrid		250
Optimus	AndraTech, GmbH, Koblenz, Germany	Cobalt Chrome	Laser cut	hybrid		270
Intrastent LD Max	EV3, Plymouth, MN, USA	316L - stainless steel	Laser cut	hybrid		270
Sapien	Edwards Life sciences Inc, Irvine, CA,US	316L - stainless steel	Laser cut	stented valve		520*
Sapien XT	Edwards Life sciences Inc, Irvine, CA,US	Cobalt Chrome	Laser cut	stented valve		500*

Table 1 Various stents used in testing

Abbreviations: CP=Cheatham Platinum stent™, AN=AndraStent® XXL; OP=Optimus XXL; IN=InstraStent LD Max
**Measured, not provided by manufacturer.*
**See text for details*

3.3.1 Mechanical stiffness testing

The different stents and stent combinations were carefully expanded up to an internal diameter of 22 mm and longitudinally loaded for compression testing in a hydraulic compression system to quantify compression of the stents. This diameter was selected to simulate the most common clinical (in vivo) diameter used during PPVI. Before testing, the dimensions of the stent (diameter and length) were measured. Single stents as well as the combinations of stents were loaded for compression testing between two plates on a universal Instron 4467 test bench, using a 1 kN load cell (catalog number: 2525-806) (Fig. 1). Displacement was monitored with an extensometer with gage length of 0.25 mm. The compression rate was 1 mm/min up to 5 mm. Tests were repeated for all single stents and combinations to control validity and repeatability of the measurements. Testing consisted of: single

CP, AN, OP, IN and the following combinations: CP+CP & CP+CP+CP and CP+AN & CP+AN+AN, CP+IN, CP+IN+IN.



Figure 1. Compression bench testing. Instron bench testing demonstrated. A: Single CP stent, B: CP combination

3.3.2 Corrosion testing

3.3.2.1 Galvanic corrosion test

A galvanic corrosion test is performed to determine the corrosion currents/rates which occur when two or more different metals come into contact with each other. Table 2 shows the stents and combinations that were analyzed. Couples were made with the stents described and those that are currently used in the valved stents: the CP is used in the Melody™ valve, and the Sapien™ and SapienXT™ consist of respectively 316L-stainless steel and a cobalt-chromium alloy (Edwards, Irvine, CA, USA).

Stent couples		Potential difference (mV)	Corrosion driving force
CP stent (Pt-Ir-Au)	Andrastent (Co-Cr)	101	+
Andrastent (Co-Cr)	Sapien (316L)	132	++
CP stent (Pt-Ir-Au)	Sapien (316L)	25	+++
Andrastent (Co-Cr)	Sapien XT (Co-Cr)	104	+
CP stent (Pt-Ir-Au)	Sapien XT (Co-Cr)	237	+++

Table 2. Measured open circuit corrosion potentials after 24hr equilibration

*Abrreviations: Pt, platinum; Ir, iridium; Au, gold; Co, cobalt; Cr, chrome; 306L, stainless steel,; Ag, silver; Cl, chloride: reference electrode. *Calculated potential difference between the maerials of all couples and a qualitative estimation of the driving force of galvanic corrosion. Mixed potentials (in mV vs Ag/AgCl) of all couples in function of time were measured.*

Both the IntraStent™ and Sapien™ stent consist of 316L - stainless steel, only the latter was used in the corrosion tests. All tests were performed in a buffered physiological solution (Plasmalyte AKE0324, Baxter, Lessines, Belgium) at 37°C to simulate conditions in the body. (Fig 2). This solution was refreshed weekly to prevent microbial contamination and to keep the pH of the solution around pH

7.4. The electrochemical galvanic tests were performed at a cathode:anode surface area ratio of 1:1 to simulate two stents positioned within each other. The exposed surface of every test specimen was 1.5 cm^2. The electrochemical measurement procedures were performed as follows:

- Samples were immersed without galvanic contact for 24h (allow equilibration of the test surfaces). After this period, the open circuit corrosion potential (OCP) of every material was determined against an Ag/AgCl reference electrode. These measurements result in the galvanic series representing the initial surface conditions.
- The samples were then coupled to each other (Table 2). The galvanic zero resistance amperometry (ZRA) current and the mixed potentials were measured for 1 hour after 24 hours of equilibration.
- After 1 and 2 weeks of exposure, new galvanic ZRA current and mixed potential measurements were performed for every couple (1 hour per measured couple).
- The test was continued for a period of 4 weeks, followed by new galvanic ZRA current and mixed potential measurements.
- All measurements lasted 1 hour to ensure that a stable condition was measured.

At the end of the immersion test the materials were inspected by visual and stereomicroscopic investigation to determine the type of corrosion as well as the extent of the corrosion effect on the stent surfaces.

3.3.2.2 Prolonged exposure corrosion test

The following test combinations were applied for a prolonged exposure test: CP + AN, AN + Sapien, An + SapienXT, CP + Sapien, CP+ SapienXT . Both stents of every couple were folded within each other resulting in a direct physical contact between both stent materials, simulating the actual physical condition. The samples were immersed in the saline solution at 37°C for a total period of 3 months to determine corrosion rates. Conditions were further identical as applied during the galvanic corrosion test.

The evaluation at the end of this phase was executed based on the following investigations:

- Visual and stereo microscopic investigation of the surfaces (determination of the corrosion type);
- Determination of the maximal local corrosion depth if a local corrosion type could be observed – defined as more than 10 µm;
- Weight decrease analysis (calculation based on the measured corrosion rate of the metals).

3.3.3 Statistics

Data was analyzed using standard statistical software (SPSS for windows, SPSS Inc., IBM company, Chicago, Illinois, US, version 18). A Student-t test was used to compare normally distributed data. A p-value < 0.05 was considered significant.



Figure 2. Galvanic corrosion test. Applied samples for galvanic corrosion test (see text). The samples were connected with a copper wire (left) for the electrochemical measurements and mounted in epoxy to isolate the copper material from the test solution.

3.4 RESULTS

3.4.1 Mechanical tests

Figure 3 shows the specific force (F/tested length) versus displacement of the plates during compression for the different types of stents. Relative stiffness of the stents OP/AN/IN/CP, expressed as load per length to deform the stent for 1 mm at 22 mm was 100/104/161/190. Relative stiffness was influenced by the thickness, material and structure of the cells. The deployment of a stent within another stent considerably increased stiffness. The CP stent™ was 54%-56% stiffer than the other stents (IN, AN and OP), but this difference was not statistically significant (p=0.140). The cobalt-chromium stents differed little compared to each other. The deployment of a stent within another stent considerably increased stiffness. The addition of one more stent stiffened up the combined units by a minimum of 17% compared to a single CP stent™ (p=0.030). Furthermore, adding more stents (CP+AN+AN) stiffened combinations by another 19%. Similar results were found when more stents of the same kind (CP) were inserted into each other. The stiffness of the combination increased by 74% by addition of one and by 178% by adding two additional CP stents™ (p=0.010). This indicates that, in combinations of more than 1 stent, for the same applied external forces, less strain will be experienced in the stent which also means less flexibility or strain in the most critical places in the stent.

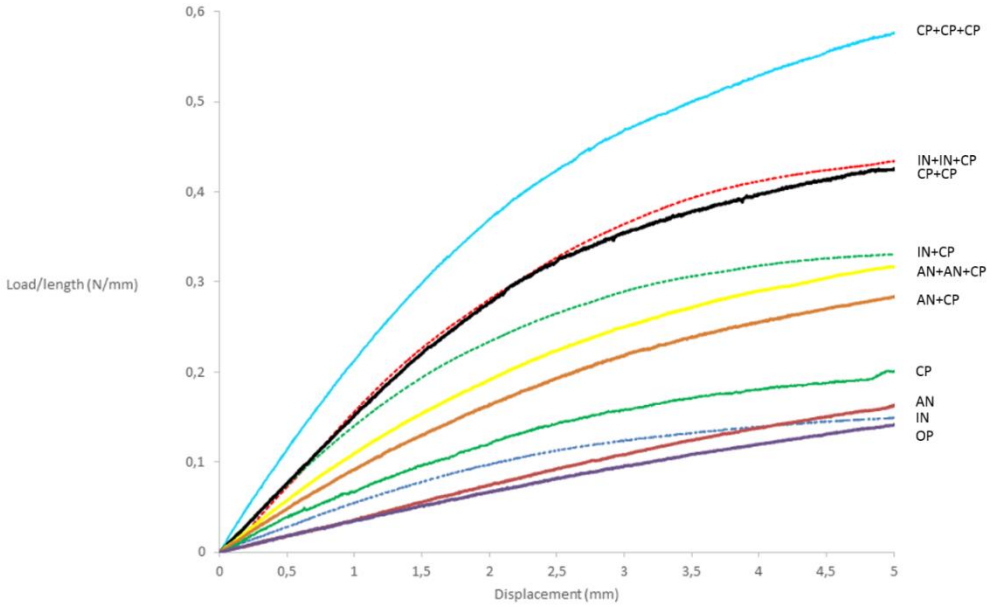

Figure 3. Compression force vs. displacement of stents.

3.4.2 Corrosion testing

3.4.2.1 Galvanic currents and mixed potentials

Galvanic corrosion potentials indicated that the CP stent™ was comprised of the most noble metals and thus corrosion resistant, followed by the Cobalt-Chromium stents (Table 3).

Mixed potentials (in mV vs. Ag/AgCl) of all couples in function of time were measured. The galvanic currents showed that a steady state corrosion rate for couples 1, 2 and 4 were established after 4 weeks and remained quite low thereafter. The currents for couples 4 and 5 were somewhat higher, but showed a similar decrease to a steady state after 4 weeks. The lowest galvanic corrosion rates (about 0.000001 mm/year) were observed for the joined CP+AN, AN-Sapien and Andra-SapienXT. The corrosion rate for coupled CP-Sapien and CP-SapienXT was somewhat higher (about 0.000003 mm/year). The materials with the highest corrosion rates (CP+Sapien XT and CP+Sapien XT) will result in material losses of respectively 17 and 24 µg/year, estimated for a coupled stent system. The material loss of the other couples was only about 10 µg/year.

Stent	Metal	Potential (mV)	Galvanic series
CP stent	Pt-Ir-Au	91	More noble
AndraStent	Co-Cr	42	
Sapien XT	316L	-102	
Sapien 316	Co-Cr	-129	Less noble

Table 3. Galvanic series based on the measured average open circuit potential (Eoc) of all tested materials. *Pt Platinum, Ir Iridium, Au Gold, Co Cobalt, Cr Chrome*

3.4.2.2 Exposure corrosion test

The maximum calculated uniform corrosion rates varied from 0.000008 to 0.0000028 mm/year for the coupled stents. No visible signs of corrosion could be observed on the materials of the Platinum Iridium or Cobalt Chromium stents, based on macroscopic and stereo-microscopic investigation of the surface after an exposure in physiological solution over 3 months (Fig. 4).

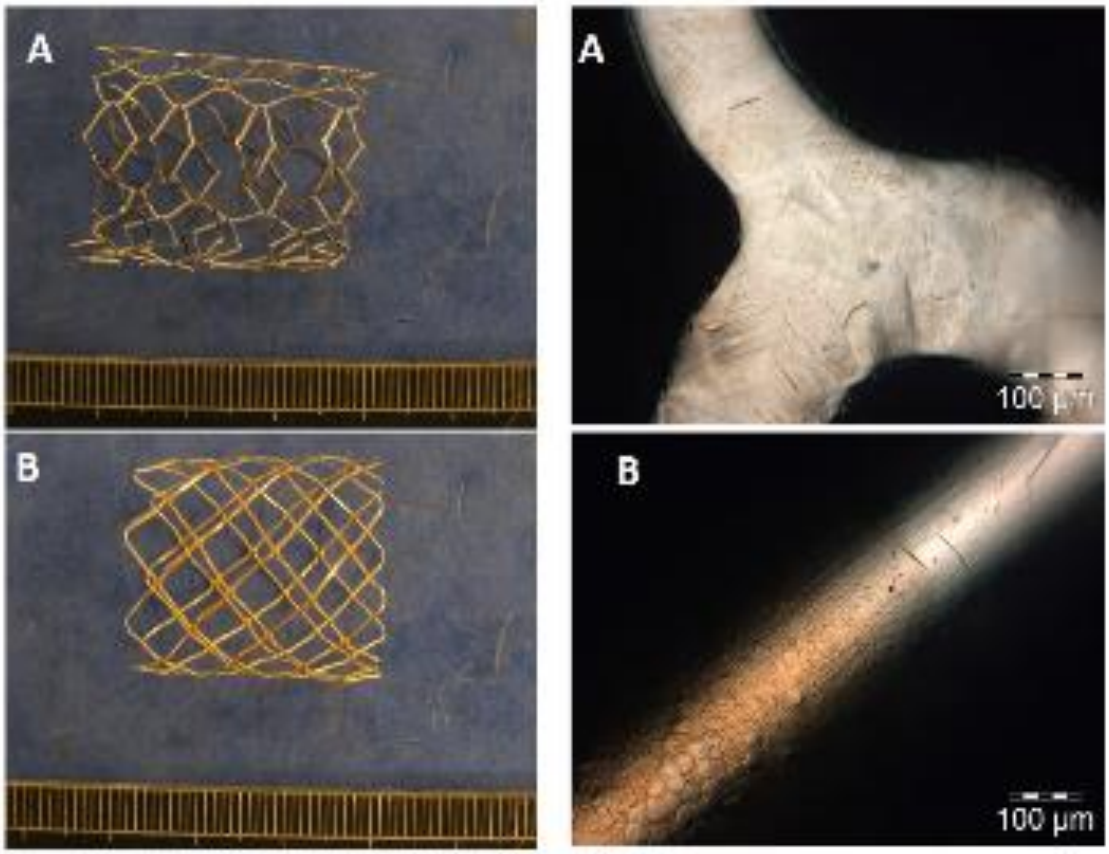

Figure 4. Macroscopic and Stereo microscopic images of stents after 3 month corrosion test. *A = AN; B = CP. Note no pitting observed macro or microscopically.

3.5 DISCUSSION

Stent fractures following PPVI give rise to varying degrees of hemodynamic impairment ranging from mild to severe with or without valve dysfunction.(1–3,5) Recent midterm follow-up of the Melody™ valve identified elements associated with a higher risk of stent fracture.(9) Geometrical anomalies of the stented valve such as deformation and compression increase the risks whilst implantation within a protected RVOT was proven to lower risks.(5,20,21)

Our bench testing shows that a singular (thicker) CP stent™ is more resistant to deformation than a single Optimus™, AndraStent® or IntraStent™. More importantly, mechanical compression testing unequivocally confirms what can logically be expected: by adding one or more combination of stents

to a single stent, deformation resistance is significantly augmented. The results show that, in combinations of more than 1 stent, for the same applied external forces, less strain will be experienced in the stent which also means less flexibility or strain in the most critical places in the stent.

Fatigue endurance curves of metals are known and show that higher stiffness leads to a lower strain amplitude which results in a longer lifetime or higher number of cycles to failure. This bench testing proves that lowering the strain amplitude by multiple pre-stenting adds more stiffness and therefore lowers the risk of deformation and ultimately fracture; this is metal fatigue known as the Basquin or Wohler law.(22) Therefore, our findings support clinical observations that a pre-stented RVOT leads to a lower incidence of stented valve fractures, dysfunction and re-interventions.(6) The results support what common logic predicts: increasing thickness of the wall of a cylindrical structure (by adding more stents) reduces wall stress and makes the cylinder stronger by an increasing margin. It also has additional benefit in the clinical situation by increasing roundness of the wall, which also improves resistance to fractures.(23)

The choice of a pre-stent can be influenced by many factors. A thin sharper laser cut strut with hybrid open cell design will have more friction and retention than a closed cell stent consisting of rounded wire. High retention forces may be an advantage when the pre-stent is deployed in a soft conduit free outflow tract, but can be a disadvantage when an unprotected valve (typical for the Sapien system) is maneuvered into the landing zone. Stent thickness must also be taken into account when preparing a landing zone in the RVOT: combinations of multiple stents will reduce the inner diameter. This can be a clinical advantage when size reduction of the landing zone is required, or a disadvantage as for the same inner diameter more external compression will occur or when the stents are deployed in a restrictive ring, thereby further reducing the functional lumen. Fractures of a CP stent™ can readily be seen since the CP stent™ has a closed cell design with thicker metal struts rendering it more radiopaque. Fractures can thus more easily be observed during routine radiography if cells are distorted as opposed to the thinner, more difficult to visualize hybrid open cells of the thinner laser cut stents. The different designs of the cells of the two stents may also respond differently to in vivo forces such as fretting and leverage which may accelerate focal metal fatigue.

When using different metals in close contact corrosion can be expected. Corrosion tests show that the CP stent™ has the noblest material, followed by the others. When the different stent alloys come into direct contact with one another, the least noble metal undergoes an anodic corrosion reaction, whilst the more noble metal will not corrode since electrons are held tightly together. The lowest galvanic corrosion rate was present in the combination of CP-Sapien, AN-Sapien and AN-SapienXT. The corrosion rate for coupled CP-Sapien and CP-SapienXT was only a little higher. More importantly, no pitting corrosion could be observed by stereomicroscopic inspection of the surface of the tested stent materials of the exposed test samples.

The corrosion rate and material loss of all tested stent compounds is very low. No mechanical integrity problems are expected as a result of corrosion since there is only 0.3% of the initial diameter of the wires of a stent that will be lost as a consequence of corrosion after 100 years. Per implication, the stents will outlive the patient. This compares favorably to findings in a study using other stents.(10,24) Similarly, no biological effect can be expected on the organism with such little metal ions being released into the tissues (e.g. safe dose for Cobalt < 7ppb). Even the combination of materials with the highest driving force for galvanic corrosion will result in minimal material losses which amounts to < 0.5 ppb.

Of particular interest, after an initial higher rate, corrosion in the samples appeared to decrease after 4 weeks. This can be ascribed to ions combining with oxygen to form a oxide film over the exposed stent surfaces preventing further corrosion and ion dissolution into the tissues.(10,24) Studies on nickel release of atrial septal defect devices reported similar findings: a calcium phosphate layer is formed over the oxide membrane during endothelialization in the body, further reducing metal ion release; this would likely also occur with RVOT stents.(25)

No ideal stent exists and current stents represent a compromise of advantages and disadvantages, but if the behavior of a stent or combinations of stents are known, it can allow clinicians to select the most ideal stent(s) for a given situation and influence future stent performance. There is little evidence to date, in mid-term follow-up, of significant disadvantages of pre-stenting such as corrosion, fretting, leverage, erosion with puncture of vessel walls and fracture/embolization, and endocarditis risk. Therefore, the potential advantages of adequate pre-stenting most likely outweigh the long-term disadvantages of pre-stenting. Adequate pre-stenting is required to relieve RVOT gradients prior to percutaneous valve implantation, create a stable landing zone to reduce fractures of the Melody™ valve and allow a proper circular configuration for proper function of the Sapien™ valve.(26)

3.6 Conclusion

Joined combinations of stents significantly increase stiffness and reduce the risk of metal fatigue failure. Corrosion of individual stents or stent combinations occur, but is negligible over a human lifetime and the concentration of dissolved ions is too low to cause biological effects. Knowledge of physical behavior of implanted materials is helpful when planning and performing RVOT pre-stenting.

REFERENCES

1. J. N., L. C., P. L., et al. Percutaneous pulmonary valve-in-valve implantation: A successful treatment concept for early device failure. Eur Heart J 2008.
2. J. N., S. K., L. C., et al. Risk stratification, systematic classification, and anticipatory management strategies for stent fracture after percutaneous pulmonary valve implantation. Circulation 2007.
3. McElhinney DB., Cheatham JP., Jones TK., et al. Stent fracture, valve dysfunction, and right ventricular outflow tract reintervention after transcatheter pulmonary valve implantation:

Patient-related and procedural risk factors in the US melody valve trial. Circ Cardiovasc Interv 2011. Doi: 10.1161/CIRCINTERVENTIONS.111.965616.
4. K AA., T BD., K CA., et al. One-Year Follow-Up of the Melody Transcatheter Pulmonary Valve Multicenter Post-Approval Study. JACC-CARDIOVASCULAR Interv 2014.
5. Schievano S., Petrini L., Migliavacca F., et al. Finite element analysis of stent deployment: Understanding stent fracture in percutaneous pulmonary valve implantation. J Interv Cardiol 2007. Doi: 10.1111/j.1540-8183.2007.00294.x.
6. Cheatham JP., Hellenbrand WE., Zahn EM., et al. Clinical and hemodynamic outcomes up to 7 years after transcatheter pulmonary valve replacement in the US melody valve investigational device exemption trial. Circulation 2015. Doi: 10.1161/CIRCULATIONAHA.114.013588.
7. Zahn EM., Hellenbrand WE., Lock JE., McElhinney DB. Implantation of the Melody Transcatheter Pulmonary Valve in Patients With a Dysfunctional Right Ventricular Outflow Tract Conduit. Early Results From the U.S. Clinical Trial. J Am Coll Cardiol 2009. Doi: 10.1016/j.jacc.2009.06.034.
8. McElhinney DB., Hellenbrand WE., Zahn EM., et al. Short-and medium-term outcomes after transcatheter pulmonary valve placement in the expanded multicenter US melody valve trial. Circulation 2010. Doi: 10.1161/CIRCULATIONAHA.109.921692.
9. Cools B., Budts W., Heying R., et al. Medium term follow-up after percutaneous pulmonary valve replacement with the Melody® valve. IJC Hear Vasc 2015;7. Doi: 10.1016/j.ijcha.2015.02.014.
10. Kazimierczak A., Podraza W., Lenart S., Wiernicki I., Gutowski P. Electrical potentials between stent-grafts made from different metals induce negligible corrosion. Eur J Vasc Endovasc Surg 2013. Doi: 10.1016/j.ejvs.2013.06.010.
11. Madl AK., Kovochich M., Liong M., Finley BL., Paustenbach DJ., Oberdörster G. Toxicology of wear particles of cobalt-chromium alloy metal-on-metal hip implants Part II: Importance of physicochemical properties and dose in animal and in vitro studies as a basis for risk assessment. Nanomedicine Nanotechnology, Biol Med 2015. Doi: 10.1016/j.nano.2015.02.006.
12. Mullins CE., O'Laughlin MP., Vick GW., et al. Implantation of balloon-expandable intravascular grafts by catheterization in pulmonary arteries and systemic veins. Circulation 1988. Doi: 10.1161/01.CIR.77.1.188.
13. Palmaz JC. Balloon-expandable intravascular stent. Am J Roentgenol 1988. Doi: 10.2214/ajr.150.6.1263.
14. Palmaz JC., Richter GM., Noeldge G., et al. Intraluminal stents in atherosclerotic iliac artery stenosis: Preliminary report of a multicenter study. Radiology 1988. Doi: 10.1148/radiology.168.3.2970098.
15. Venugopalan R. Corrosion testing of stents: A novel fixture to hold entire device in deployed form and finish. J Biomed Mater Res 1999. Doi: 10.1002/(sici)1097-4636(1999)48:6<829::aid-jbm10>3.0.co;2-%23.
16. Shabalovskaya S., Anderegg J., Van Humbeeck J. Critical overview of Nitinol surfaces and their modifications for medical applications. Acta Biomater 2008. Doi: 10.1016/j.actbio.2008.01.013.
17. Shabalovskaya S., Anderegg J., Rondelli G., Vanderlinden W., De Feyter S. Comparative in vitro performances of bare Nitinol surfaces. Biomed Mater Eng 2008.
18. Mueller Y., Tognini R., Mayer J., Virtanen S. Anodized titanium and stainless steel in contact with CFRP: An electrochemical approach considering galvanic corrosion. J Biomed Mater Res - Part A 2007. Doi: 10.1002/jbm.a.31198.
19. Paprottka KJ., Paprottka PM., Reiser MF., Waggershauser T. Comparative study of the corrosion behavior of peripheral stents in an accelerated corrosion model: Experimental in vitro study of 28 metallic vascular endoprostheses. Diagnostic Interv Radiol 2015. Doi: 10.5152/dir.2015.15062.
20. Schievano S., Taylor AM., Capelli C., et al. Patient specific finite element analysis results in more accurate prediction of stent fractures: Application to percutaneous pulmonary valve implantation. J Biomech 2010. Doi: 10.1016/j.jbiomech.2009.10.024.
21. Nordmeyer J., Lurz P., Khambadkone S., et al. Pre-stenting with a bare metal stent before

percutaneous pulmonary valve implantation: Acute and 1-year outcomes. Heart 2011. Doi: 10.1136/hrt.2010.198382.
22. Ashbey MS., Cebon D. materials: Science, processing and design. 2009.
23. Cosentino D., Quail MA., Pennati G., et al. Geometrical and stress analysis of factors associated with stent fracture after melody percutaneous pulmonary valve implantation. Circ Cardiovasc Interv 2014. Doi: 10.1161/CIRCINTERVENTIONS.113.000631.
24. Chakfé N., Heim F. Commentary on “electrical potentials between stent-grafts made from different metals induce negligible corrosion.” Eur J Vasc Endovasc Surg 2013. Doi: 10.1016/j.ejvs.2013.07.009.
25. Ries MW., Kampmann C., Rupprecht HJ., Hintereder G., Hafner G., Meyer J. Nickel release after implantation of the Amplatzer occluder. Am Heart J 2003. Doi: 10.1067/mhj.2003.7.
26. Muller B., Ghawi H., Heitschmidt MG., et al. Medium-term CT evaluation of stent geometry, integrity, and valve function of the Edwards SAPIEN transcatheter heart valve in the pulmonary position. Catheter Cardiovasc Interv 2016. Doi: 10.1002/ccd.26074.

3.7 **Supplement**

Mathematical Model to Demonstrate Stent Strength

Only looking at the formula for a vessel, the circumferential stress σ_1 is given by equation [1] and the total elongation of the ring δ_t is given by equation [2] and the elongation of the radius δ_r is given by equation [3].

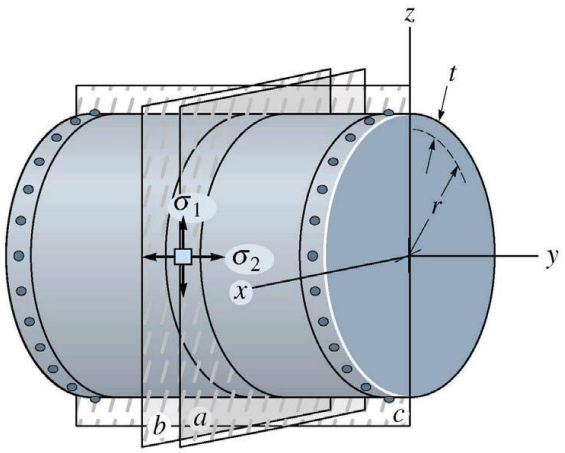

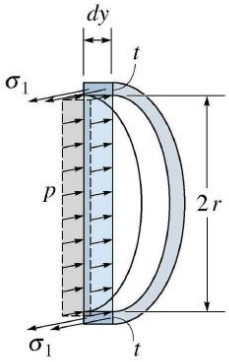

$$\sigma_1 = \frac{pr}{t} \quad [1]$$

$$\delta_t = \frac{NL}{EA} = \frac{2\pi pr^2}{Et} \quad [2]$$

$$\delta_t = 2\pi\delta_r \quad [3]$$

These formula clearly indicate that by increasing the stiffness of the wall material (E in the formula) or by increasing the thickness of the wall (t in the formula), the circumferential stress in the wall and the elongation of the ring (and hence also the elongation of the radius) is reduced. This is what happens if a stent is introduced in the blood vessel; it also proves that by adding more stents or a stent with a higher structural stiffness leads to lower stress for all components of the structure (blood vessel wall, stent struts) for the same pressure in the vessel.

When considering the fatigue endurance curve or Whöler curve of a metal (see below) and considering the reduction in stresses/strains, this ultimately also leads to a higher number of cycles to failure or a longer lifetime.

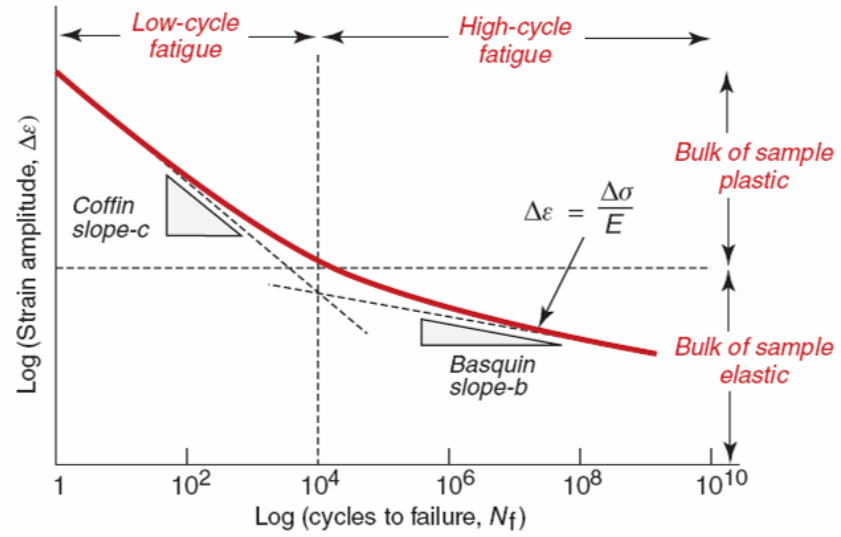
Low-cycle fatigue
High-cycle fatigue
Bulk of sample plastic
Coffin slope-c
$\Delta\varepsilon = \frac{\Delta\sigma}{E}$
Basquin slope-b
Bulk of sample elastic
Log (Strain amplitude, $\Delta\varepsilon$)
1
10^2
10^4
10^6
10^8
10^{10}
Log (cycles to failure, N_f)

CHAPTER 4

Creation of animal model with pulmonary valve regurgitation and RV volume overload

4.1 ABSTRACT

Introduction: Patients with surgically repaired tetralogy of Fallot (TOF) often develop pulmonary regurgitation (PR) with chronic right ventricular volume overload, leading to adverse outcomes. The aim is to create an animal model with severe PR and RV volume overload which enables studying RV remodeling after PR and reverse remodeling after PVR at different time intervals. Two historical animal models in whom PR was created were compared.

Methods: Historical comparison of two different types of ovine animal models with PR. In the first model (SURG model, n=8) in lamb stage at the age of 4.5±0.5 months PR was created by resection of at least 2 pulmonary valve leaflets (PV) through a transannular incision and a supra-annular PTFE strip was secured at a diameter of 22 mm. In the second model (STENT model, n=13) in lamb stage at the age of 4.5±0.5 months pressure load with PA banding was fashioned with preserved oxygen saturation and cardiac output. In the STENT model at the age of 7.5±0.5 months the PA banding was balloon dilated and a bare metal stent was placed across the pulmonary valve creating PR. Age and weight matched healthy animals (n=6) served as control. The severity of PR and right ventricular (RV) dilatation was assessed with cardiovascular magnetic resonance (CMR) at the age of 1 year in all animals.

Results: In the SURG model all animals survived. In STENT model 3 animals died due to ventricular fibrillation (VF) and 2 animals were excluded due to stent embolization (8/13 completed the series). The STENT model showed a maximal systolic velocity (Vmax) across the right ventricular outflow tract (RVOT) of 2.3±1.0 m/s at the age of 7.5±0.5 months compared to 1.6±0.6 m/s in the SURG model at the age of 12.5±0.5 months. At the age of 1 year the PR fraction was significantly higher in the STENT model 61±8% compared to the SURG model 16±16% ($p < 0.001$). RV end diastolic volume indexed for body surface (RVEDVi) was significantly higher in the STENT model 116.7±32 ml/m2 in compared to 70.0 ± 26 ml/m2 in SURG TOF 40.0±6 ml/m2 ($p < 0.05$). RVEDVi was significantly higher in SURG and STENT model compared to healthy animals ($p < 0.001$ and $p < 0.05$, respectively). Right ventricle (RV)-to-left ventricle (LV) EDV ratio was significantly higher in the STENT model 2.6±0.9 compared to the SURG model 1.2±0.5 ($p < 0.05$).

Conclusion: Comparison of two different historical types of animal models where PR was created. The STENT model had more but still mild PS and was more efficient in creating a severe PR leading to RV dilatation therefore simulating the changes that occur in patients with TOF. This model can be used to study remodeling and reversed remodeling of the RV thereby offering the possibility to develop improved treatment strategies for patients with TOF.

4.2 **INTRODUCTION**

Over 11.800 reports regarding tetralogy of Fallot (TOF) have been published. In 1944 the first surgical treatment was offered to these patients by means of the Blalock and Taussig shunt.(1,2) First intracardiac repair was performed in 1954.(3) At this stage the primary goal was relief of the pulmonary stenosis and a degree of pulmonary regurgitation (PR) was accepted. Initially the PR was well tolerated but in the long-term it appeared not to be a benign lesion.(4)

In this process the right ventricle (RV) switched from a pressure overload to a volume overload.(5) Over time, it became clear that the severity of the pulmonary valve regurgitation determines the long term outcome.(6,7) The long-term problems such as malignant arrhythmias leading to sudden cardiac death (SCD) and progressive right ventricular even biventricular failure occurred.(6,8–13) Pulmonary valve replacement (PVR) was believed necessary in patients with severe PR and RV volume overload, but the ideal timing of this intervention remains the substrate for a still ongoing discussion. (7,8,10,11,13–16) New surgical treatment strategies included valve-sparing techniques to avoid this progressive PR.(17,18)

The recent ESC and ACC recommendations for PVR in repaired TOF patients state PVR is recommended in symptomatic patients with severe PR and should be considered in asymptomatic patients with severe PR and in the presence of progressive RV dilatation (RV end-systolic volume index ≥80 ml/m^2, and/or RV end-diastolic volume index ≥160 ml/m^2, and/or progression of tricuspid regurgitation (TR) to at least moderate.(19)

Changes in treatment strategy can take decades to detect a difference in the long-term outcome in humans. Animal models with a short lifespan and sharing the same pathophysiological changes as the human patient may help to address some research questions. Different animal models have been developed using a variety of techniques in creating PR leading to RV volume overload. Some used a transannular patch, others used external suture plication of the PV. Sometimes a bare metal stent was placed across the pulmonary valve (PV) to create PR.(20–26)

The aim of this study was to compare two historical ovine animal models where pulmonary valve regurgitation (PR) was created. Two different techniques were employed to create pulmonary valve regurgitation and a comparison of the efficiency in creating severe PR and RV dilatation was made.

4.3 MATERIALS AND METHODS

The experiments were performed in sheep and started at lamb stage.

In the first model the PR was created by surgical leaflet resection as described below and is named SURG model. In the second model the PR was created by stenting the pulmonary valve (PV) as described below and is labeled the STENT model.

All experiments were conducted in the laboratory of experimental cardiac surgery animal facility of the Catholic University Leuven, the facility carries the license number LA 1210253. The project was approved by the ethical board for animal experiments with project number 024/2014. All interventions and CMR scans were performed under general anesthesia: intravenous injection (IV) of 22 mg/kg of ketamin (Nimatek® 100 mg/ml, Dechra), inhaled Isoflurane Veterinary 5% (Iso-Vet 1000 mg/g, Dechra) at induction and 2.5% maintenance. Analgesia during interventional procedures was given using 0,03 mg/kg IV buprenorphine (Vetergesic® 0.3mg/ml, Ceva) and 0,2 mg/kg IV meloxicam (Metacam® 20 mg/ml, Boehringer Ingelheim). Analgetics were continued after interventions as long as deemed necessary by the site staff. For infective prophylaxis 40.000 IU/kg IV penicillin (2.000.000 IE/UI, Kela Pharma) and 6.6 mg/kg IV gentamycin (Genta-Kel® 50 mg/ml Kela Pharma) was used. During endovascular procedures 100 IU/kg IV heparin was administered and repeated every 1 hour. Monitoring consisted of 3-lead ECG, oxygen saturation, exhaled CO_2, invasive blood pressure monitoring (arterial line at the ear site), IV access.

4.3.1 Description of the used technique in the different types model to create PR

4.3.1.1 SURG model (n = 8)

A total of 8 animals started and completed the experiment (8/8).

At the age of 4.5±0.5 months (lamb stage) at a mean weight of 31.0±5.2 kg a left thoracotomy was performed in the 4th intercostal space. After opening the pericardium a side clamp was positioned over the RVOT, pulmonary valve and pulmonary artery using a Satinsky forceps. Following surgical incision at least 2 leaflets were resected. The PA was closed with 5/0 Prolene sutures and the clamp was removed. Total clamping time did not exceed 5 minutes. Once the animal was hemodynamically stable a PTFE strip was placed around the PA trunk to encircle it. The diameter of the PA banding was fixed at 22 mm (2xπxR). The ends of the PTFE strip were sutured with Prolene 5/0 and 2 additional stitches with Prolene 5/0 attached the PFTE strip to the wall of the PA to prevent shifting. (Fig. 1)

The aim of the PA banding was to create a mild stenosis and to ensure a stable retention zone for stented valve apposition in future experiments.

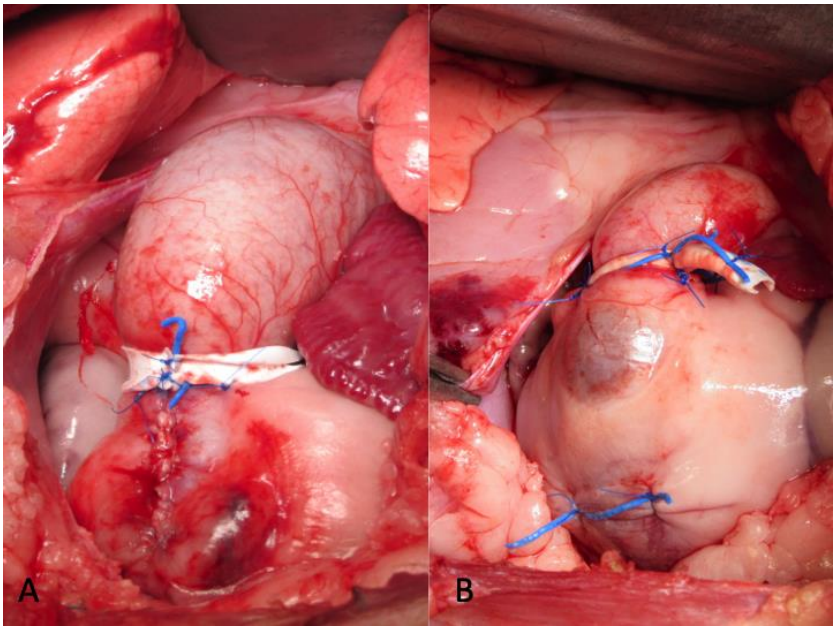

Figure 1 A/ Surgical model with sutured incision in the RVOT after resection of pulmonary valve leaflets and the supra-annular PTFE strip at 22 mm diameter. B/ stent model at the initial surgical step with the supra-annular PTFE strip creating a stenosis and the infundibular radio-opaque marker for orientation during subsequent endovascular procedures.

4.3.1.2 STENT model (n = 13)

At the age of 4.5± 0.5 months and a mean weight of 28.5±5.0 kg a left thoracotomy was performed in the 4th intercostal area. A PTFE strip was placed around the PA and tightened until a thrill was detected and the oxygen saturation and cardiac output maintained. The PA banding was secured to the PA wall 2 additional Prolene 5/0 sutures to prevent displacement.

At the age of 7.5±0.5 months and mean weight of 34.5±3.3 kg the PA banding was dilated using a high-pressure balloon and a bare metal stent was placed across the PV using fluoroscopy (OEC GE® healthcare). Access was provided with a 10 French (Fr) short introducer sheath (Cordis®, Santa Clara, US) in the left jugular vein. A 6 Fr end-hole Lehman catheter with a 0.035" J-tip Radifocus® guidewire M (Terumo® Leuven, Belgium) was placed into the distal pulmonary artery. The wire was exchanged for a 0.035" E-wire (Jotec®, Hechingen, Germany) using a 6 Fr right coronary guiding catheter. The PA banding was dilated using a 22 mm high-pressure balloon Atlas Gold (Bard®, Arizona, USA) with a pressure insufflator to a pressure of 20 atmosphere (ATM). The introducer was exchanged for a 14 Fr 85 cm Performer™ guiding sheath (Mullins design) (Cook Medical, Limerick, Ireland) placed distally in the PA trunk. A 45 mm bare metal CP-stent™ (Numed, Hopkinton NY, USA) was mounted on a 22 mm BIB™-balloon (Numed, Hopkinton NY, USA) and was delivered into the RVOT with the distal struts at the PA banding site. The length of stent was selected to ensure that the PV leaflets were enclosed by the stent. At start of the procedure 1 mg/kg IV lidocaine was administered.

4.3.2 Imaging

All animals of both groups underwent cardiovascular magnetic resonance (CMR) (3T Magnetom Trio Siemens®) after PR was created as indicated in Figure 3. All CMR scans were performed by one and the same observer (P.C.). Image analysis was done using Matlab® (MathWorks®, US) (B.C. and P.C.). Ventricular dimensions were obtained using slice by slice manual contouring of the endocardial and epicardial border in systolic and diastolic phase on the short axis views. The papillary muscles were excluded from the tracing. Pulmonary valve flow and regurgitation fraction were calculated on short axis view slices and phase contrast images. The pulmonary regurgitation was calculated by quantifying the reversal of diastolic flow on the phase contrast images, which were acquired perpendicular to the PA and distal from the PV. Data were indexed for body surface area (BSA) with use of the formula of Mitchell $0.09xW^{0.67}$.(27)

CMR analysis was performed in the SURG model (n=8) at the mean age of 12.5±2.4 months and mean weight 43.3±4.4 kg and in the STENT model (n=8) at the age of 12.6±2.5 months and mean weight 49.9±4.7 kg. Six healthy animals underwent CMR at mean age of 11.7±0.1 month and mean weight 48.6±6.5 kg. (Fig. 2)

4.3.3 Statistics

Statistical analysis was performed using SPSS© version 26 (IBM©). Test for normality was done using Kolmogorov-Smirnov test. Groups were compared using an independent Student t-test. Comparison among different groups was done using Anova (F) test. Continuous data are expressed as means and the standard error of the mean. Statistical significance was accepted with a p-value <0.05. Graphs were plotted using Prism® 8 (GraphPad©).

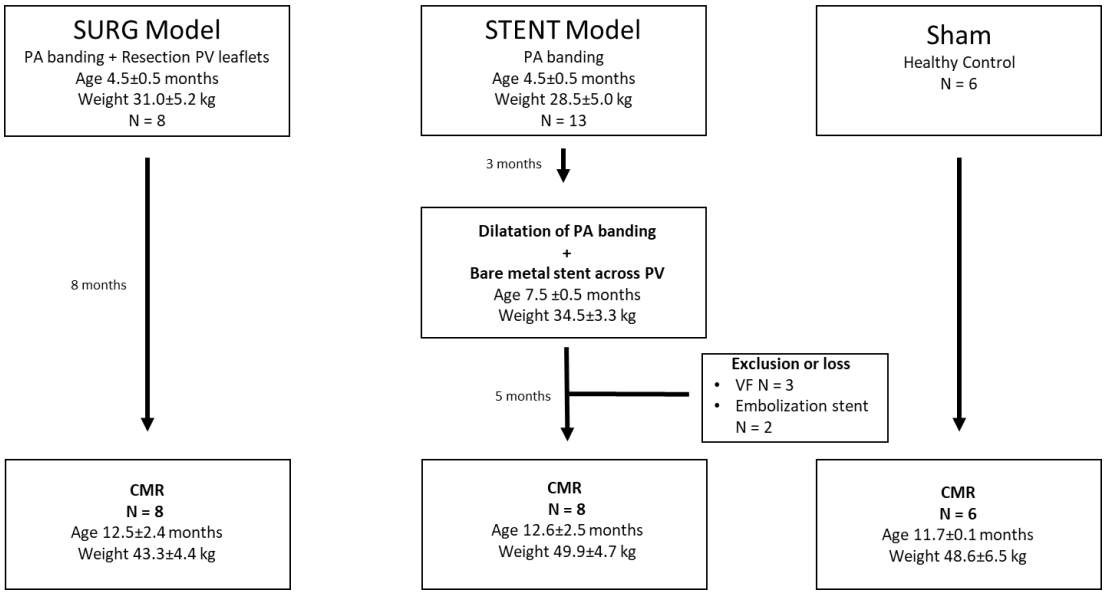

Figure 2 Flowchart of experiments ***PA*** *pulmonary artery*, ***VF*** *ventricular fibrillation,* ***PV*** *pulmonary valve,* ***CMR*** *cardiovascular magnetic resonance, PA pulmonary artery*

4.4 RESULTS

Data are presented in Table 1 and Fig. 3. There was no significant difference in age or weight between the groups. In the STENT model five animals (5/13) were lost or excluded whereas in the SURG model no animals were lost or excluded. (Fig. 2)

The maximal velocity (Vmax) across the RVOT was 2.3±1.0 m/s in the STENT model (age 7.5±0.5 months) compared to 1.6±0.6 m/s in the SURG model at the age of 12.5±0.5 months.

The PR fraction was significantly higher in the stent model compared to the surgical model which demonstrated a mild to moderate grade of PR. The PR resulted in dilatation of the right ventricle. The end systolic (RVESVi) and diastolic volume (RVEDVi) indexed for body surface (BSA) were significantly higher in the STENT model compared to the SURG model. Both interventional models did have significantly higher RVEDVi and RVESVi compared to healthy animals. (Table 1). The end diastolic and end systolic RV to LV ratio were significantly higher in the STENT model versus the SURG model. Complications were only experienced in the STENT model. The most common complications which led to animal loss or exclusion from the study were ventricular fibrillation (VF) (n=3) and stent embolization (n=2). (Figure 2) No animals were lost or needed to be excluded in the SURG model.

Table 1 CMR data

		SURG model n = 8	STENT model n = 8	Normal n = 6	*p value*		
	unit	*mean (SD)*	*mean (SD)*	*mean (SD)*	*SURG-STENT*	*SURG-Normal*	*STENT-Normal*
Age	*months*	12.4±2.4	13.6±2.6	11.7±0.0	*ns*	*ns*	*ns*
Weight	*kg*	43.3±1.4	49.9±4.7	48.5±6.6	*ns*	*ns*	*ns*
MRI							
Ventricular dimensions							
LV EDVi	*ml/m²*	59.7±8.8	46.2±11.5	57.0±5.5	*<0.05*	*ns*	*ns*
RV EDVi	*ml/m²*	70.0±26.5	116.7±32.5	40.0±5.9	*<0.05*	*<0.05*	*<0.001*
LV ESVi	*ml/m²*	34.3±6.6	22.2±3.2	33.8±7.9	*<0.001*	*ns*	*<0.05*
RV ESVi	*ml/m²*	41.4±13.5	50.5±19.7	24.0±5.6	*ns*	*<0.05*	*<0.05*
LV SVi	*ml/m²*	25.4±4.8	24.0±12.3	23.2±3.3	*ns*	*ns*	*ns*
RV SVi	*ml/m²*	28.9±14.9	66.3±20.7	16.0±3.5	*<0.05*	*ns*	*<0.001*
HR	*BPM*	102±15	93± 30	81± 10	*ns*	*<0.05*	*ns*
RV to LV EDVi ratio		1.2±0.5	2.6±0.9	0.7±0.1	*<0.05*	*<0.05*	*<0.001*
RV to LV ESVi ratio		1.3±0.6	2.2±0.7	0.7±0.1	*<0.05*	*<0.05*	*<0.001*
Pulmonary valve							
PR fraction	*%*	16±16	61±8	0.1±0.1	*<0.001*	*<0.05*	*<0.001*
Vmax	*m/s*	1.6±1.5[1]	0.8±0.5[2]	1.1±0.2	*<0.05*	*ns*	*ns*

SD *Standard deviation,* ***i*** *indexed for body surface area,* ***Vmax*** *maximal velocity measured on CMR,* [1] *Vmax measured at the age of 12.5 ±2.4 months,* [2] *Vmax measured at the age of 12.6±2.5 months*

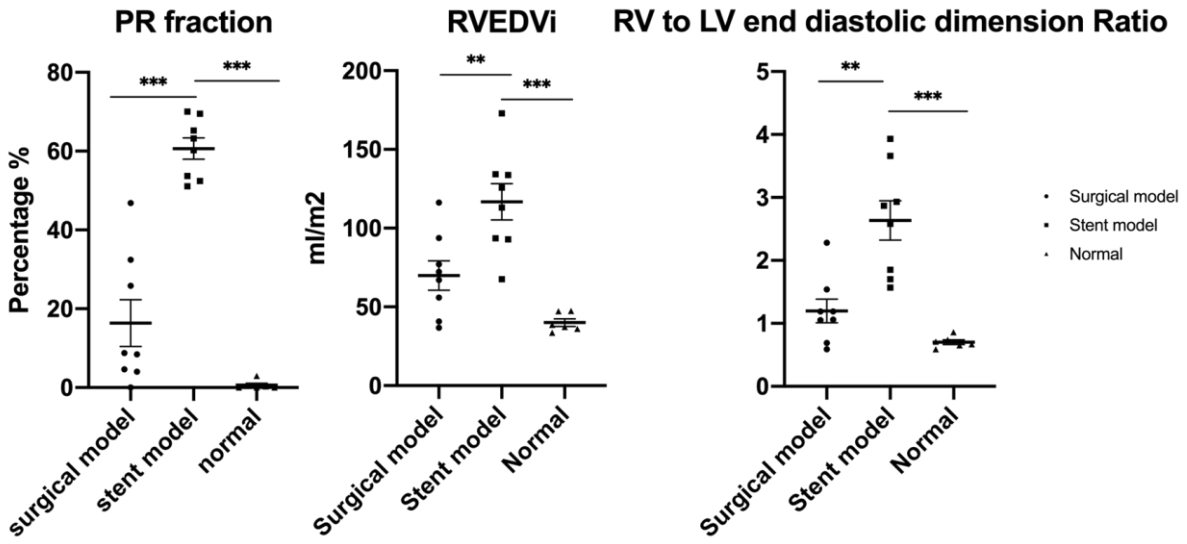

Figure 3 A/ pulmonary valve regurgitation fraction; B/ indexed right ventricular end diastolic volume on CMR; C/ RV to LV ratio of end diastolic ** p <0.05, *** p <0.001

4.5 DISCUSSION

Two historical different types of animal models with pulmonary valve regurgitation were compared. In the first model the PR was created by surgical leaflet resection and in the second model the PR was created by stenting the pulmonary valve.

All animals were evaluated at the age of 1 year for comparison of the severity of PR and RV dilatation. Both models developed PR which was more pronounced in the STENT model. The PR resulted in both

models in RV dilatation. Also, the RV dilation was most pronounced in the STENT model compared to the SURG model. In both models a PA banding was performed with different intentions. The PA banding in the STENT model was tighter in order to create a pulmonary stenosis. The aim of PA banding in the SURG model was to ensure a retention zone for future percutaneous PVR with stented valve. The animal loss was higher in the STENT model compared to the SURG model. The main reasons for loss or exclusion from the study were VF and stent embolization.

Different methods have been used to create PR in animal models. Some used a transannular patch, leaflet resection (valvectomy) or an external suture plication technique in order to create PR.(20–22,24,28–30) In pigs a bare metal stent across the PV was used to create PR.(23,26) The PR fraction quantified using CMR was less pronounced or not reported in the pig trials and PS was not created prior to PR.(23,31) Creating PS by means of a PA banding with and without PR has been reported in pigs.(22,32–34) In the majority of trials the follow-up time after PR was limited to 8-12 weeks and exceptionally up to 3 months; some were acute experiments.(20–22,24,28–30) The choice of the model depends on the purpose to be studied. Most animal studies focus on the RV remodeling due to PR.(20–22,24,30,32) Few reports on PVR in animal models do exist and mostly the focus was on the feasibility of valve implantation.(25,35) Ersboell *et al* performed PVR at different time intervals in pigs and looked at RV reverse remodeling on CMR.(23) A ΔRV >120 ml/m² was predictive for low probability of recovery within 1 month after PVR.

The objective of the chosen model is to evaluate the RV remodeling after PR and reverse remodeling after PVR in future experiments. The aim is to perform PVR using a stented valve (Melody™ TPV, Medtronic Inc, Minneapolis, US). The outer diameter of the Melody™ valve is limited to 24.1 mm when delivered on a 22 mm Ensemble™. The RVOT can become markedly dilated after a transannular patch and therefore this model is less suitable for PVR with a stented valve with limited outer diameter.(21,22,25) A large RVOT can result in embolization of the valve which has been encountered during a pilot study. To accommodate for this problem a PTFE strip at a diameter of 22 mm was fixed around the PA in the SURG model. Hereby a modest PS was created that could serve as a retention zone for good apposition of the stented valve. In the STENT model, the PA band was tightened more creating a more pronounced RVOT stenosis in order to simulate the PS prior to PR is created similar to patients with TOF. Even though on CMR and angiography the PA banding resulted in an important narrowing of the PA diameter, the measured RVOT gradient on CMR was rather mild. As mentioned previously, it consists of a comparison of historical models which evolved with growing insight.

The STENT model was prone to develop complications. The most common observed complication was ventricular fibrillation which occurred mainly upon advancing the Performer™ sheath into the RVOT. VF is not mentioned in the trials where stents were implanted in piglets.(23,26) In order to reduce this risk for VF Dardenne *et al* recommended administration of amiodarone 100 mg IV in the days prior to

the intervention and 25 to 50 mg/h during the procedure. Lidocaine can also be used during the procedure at a dose of 1 to 2 mg/kg IV.(36) In case of VF CPR protocol is as follows: external shock (120-200 J), chest compression and epinephrine 1 mg, atropine 1 mg IV.

To reduce the risk of animal loss upon PVR the use of extracorporeal membrane oxygenation (ECMO) was implemented.

A second complication was embolization of the stent upon retrieval of the BIB™ balloon. In the present study 45 mm CP-stent™ (Numed, Hopinkton NY, US) was used which has a closed cell design which is less ideal for delivering in non-stenotic conduit. Stents with a more open or hybrid cell design could accommodate for this issue.(37)

Animal models can help to address some research questions. When the aim is to detect a difference in long-term outcome, animals with short lifespan sharing the same pathophysiological changes as the patients may be of value. In patients with tetralogy of Fallot known long-term risks such as malignant arrhythmias leading to sudden cardiac death and ventricular failure pose a serious threat.(10–13) Upon relief of the RVOT stenosis at surgical repair, PR often results which can become severe and will lead to progressive RV volume overload. This chronic RV volume overload is a major contributing factor for the development of malignant arrhythmias, SCD and ventricular failure.(7,8,10,12,13,38,39) PVR is mostly needed in the patients with repaired TOF during life, the ideal timing remains however uncertain.(10,14,16,40) Performing earlier PVR leads to more re-interventions. Later PVR has been shown to result in less pronounced RV reverse remodeling with persistence of arrhythmias.(41,42) It may take decades to observe a difference in the long-term outcomes when treatment policies are changed. To address some of the questions regarding timing of PVR we were interested in an animal model where quick, severe PR can be induced leading to RV dilatation an in which PVR is feasible. The model should simulate the pathophysiological changes reminiscent of those observed in patients with TOF.

Stenting the RVOT resulted in a more distinct and reproducible RV dilatation despite the price of a higher animal loss. The STENT model initially has a PS and later a severe PR leading to chronic RV overload which makes this model to correlate well with the pathophysiology as seen in patients with tetralogy of Fallot. The presented ovine model can be used for the evaluation of the RV remodeling in chronic volume overload and reverse remodeling after PVR at different time intervals.

4.6 CONCLUSION

It is feasible to create a model with severe pulmonary regurgitation leading to RV volume overload. Stenting the PV resulted in a more reproducible and more distinct PR and RV dilatation compared to surgical leaflet resection. The STENT model with initial PS and subsequent severe PR leading to chronic RV overload simulates the pathophysiology of a tetralogy of Fallot. The model can be used to study RV

remodeling due to severe PR and reverse remodeling after PVR.

REFERENCES

1. Neill CA., Clark EB. Tetralogy of Fallot. The first 300 years. Tex Heart Inst J 1994.
2. Blalock A. Landmark article May 19, 1945: The surgical treatment of malformations of the heart in which there is pulmonary stenosis or pulmonary atresia. By Alfred Blalock and Helen B. Taussig. JAMA J Am Med Assoc 1984. Doi: 10.1001/jama.251.16.2123.
3. KIRKLIN JW., ELLIS FH., McGOON DC., DUSHANE JW., SWAN HJ. Surgical treatment for the tetralogy of Fallot by open intracardiac repair. J Thorac Surg 1959.
4. Bouzas B., Kilner PJ., Gatzoulis MA. Pulmonary regurgitation: Not a benign lesion. Eur Heart J 2005. Doi: 10.1093/eurheartj/ehi091.
5. Kirklin JK., Kirklin JW., Blackstone EH., Milano A., Pacifico AD. Effect of transannular patching on outcome after repair of tetralogy of Fallot. Ann Thorac Surg 1989. Doi: 10.1016/0003-4975(89)90671-1.
6. Knauth AL., Gauvreau K., Powell AJ., et al. Ventricular size and function assessed by cardiac MRI predict major adverse clinical outcomes late after tetralogy of Fallot repair. Heart 2008. Doi: 10.1136/hrt.2006.104745.
7. Fuller S. Tetralogy of fallot and pulmonary valve replacement: Timing and techniques in the asymptomatic patient. Semin Thorac Cardiovasc Surg Pediatr Card Surg Annu 2014. Doi: 10.1053/j.pcsu.2014.01.012.
8. Geva T. Indications and Timing of Pulmonary Valve Replacement After Tetralogy of Fallot Repair. Pediatr Card Surg Annu 2006. Doi: 10.1053/j.pcsu.2006.02.009.
9. Kogon BE., Rosenblum JM., Mori M. Current Readings: Issues Surrounding Pulmonary Valve Replacement in Repaired Tetralogy of Fallot. Semin Thorac Cardiovasc Surg 2015. Doi: 10.1053/j.semtcvs.2015.02.010.
10. Alvarez-Fuente M., Garrido-Lestache E., Fernandez-Pineda L., et al. Timing of Pulmonary Valve Replacement: How Much Can the Right Ventricle Dilate Before it Looses Its Remodeling Potential? Pediatr Cardiol 2016. Doi: 10.1007/s00246-015-1320-4.
11. Therrien J., Provost Y., Merchant N., Williams W., Colman J., Webb G. Optimal timing for pulmonary valve replacement in adults after tetralogy of Fallot repair. Am J Cardiol 2005. Doi: 10.1016/j.amjcard.2004.11.037.
12. Maury P., Sacher F., Rollin A., et al. Ventricular arrhythmias and sudden death in tetralogy of Fallot. Arch Cardiovasc Dis 2017. Doi: 10.1016/j.acvd.2016.12.006.
13. Cheung MMH., Konstantinov IE., Redington AN. Late complications of repair of tetralogy of fallot and indications for pulmonary valve replacement. Semin Thorac Cardiovasc Surg 2005. Doi: 10.1053/j.semtcvs.2005.02.006.
14. Geva T. Indications for pulmonary valve replacement in repaired tetralogy of fallot: The quest continues. Circulation 2013. Doi: 10.1161/CIRCULATIONAHA.113.005878.
15. Villafañe J., Feinstein JA., Jenkins KJ., et al. Hot topics in tetralogy of fallot. J Am Coll Cardiol 2013. Doi: 10.1016/j.jacc.2013.07.100.
16. Pondorfer P., Yun T-J., Cheung M., et al. Tetralogy of Fallot Repair — Long Term Follow-up: Preservation Strategy Improves Late Outcomes. Thorac Cardiovasc Surg 2016. Doi: 10.1055/s-0036-1571561.
17. Bacha E. Valve-Sparing Options in Tetralogy of Fallot Surgery. Semin Thorac Cardiovasc Surg Pediatr Card Surg Annu 2012. Doi: 10.1053/j.pcsu.2012.01.006.
18. Bacha E. Valve-Sparing or Valve Reconstruction Options in Tetralogy of Fallot Surgery. Semin Thorac Cardiovasc Surg Pediatr Card Surg Annu 2017. Doi: 10.1053/j.pcsu.2016.09.001.
19. Baumgartner H., De Backer J., Babu-Narayan S V., et al. 2020 ESC Guidelines for the management of adult congenital heart disease. Eur Heart J 2020. Doi:

10.1093/eurheartj/ehaa554.
20. Agger P., Hyldebrandt JA., Nielsen EA., Hjortdal V., Smerup M. A novel porcine model for right ventricular dilatation by external suture plication of the pulmonary valve leaflets – practical and reproducible☆. Interact Cardiovasc Thorac Surg 2010. Doi: 10.1510/icvts.2009.227264.
21. Robb JD., Harris MA., Minakawa M., et al. An ovine model of pulmonary insufficiency and right ventricular outflow tract dilatation. J Heart Valve Dis 2012.
22. Lambert V., Capderou A., Le Bret E., et al. Right ventricular failure secondary to chronic overload in congenital heart disease: An experimental model for therapeutic innovation. J Thorac Cardiovasc Surg 2010. Doi: 10.1016/j.jtcvs.2009.11.028.
23. Ersboell M., Vejlstrup N., Nilsson JC., et al. Percutaneous pulmonary valve replacement after different duration of free pulmonary regurgitation in a porcine model: Effects on the right ventricle. Int J Cardiol 2013. Doi: 10.1016/j.ijcard.2012.08.012.
24. Ko Y., Morita K., Abe T., Nakao M., Hashimoto K. Variability of Pulmonary Regurgitation in Proportion to Pulmonary Vascular Resistance in a Porcine Model of Total Resection of the Pulmonary Valve: Implications for Early- and Long-Term Postoperative Management of Right Ventricular Outflow Tract Reconstru. World J Pediatr Congenit Heart Surg 2015. Doi: 10.1177/2150135115598209.
25. Schoonbeek RC., Takebayashi S., Aoki C., et al. Implantation of the Medtronic Harmony Transcatheter Pulmonary Valve Improves Right Ventricular Size and Function in an Ovine Model of Postoperative Chronic Pulmonary Insufficiency. Circ Cardiovasc Interv 2016. Doi: 10.1161/CIRCINTERVENTIONS.116.003920.
26. Kuehne T., Saeed M., Reddy G., et al. Sequential magnetic resonance monitoring of pulmonary flow with endovascular stents placed across the pulmonary valve in growing swine. Circulation 2001. Doi: 10.1161/hc4401.098472.
27. Berman A. Effects of body surface area estimates on predicted energy requirements and heat stress. J Dairy Sci 2003. Doi: 10.3168/jds.S0022-0302(03)73966-6.
28. Robb JD., Harris MA., Minakawa M., et al. Melody valve implantation into the branch pulmonary arteries for treatment of pulmonary insufficiency in an ovine model of right ventricular outflow tract dysfunction following tetralogy of fallot repair. Circ Cardiovasc Interv 2011. Doi: 10.1161/CIRCINTERVENTIONS.110.959502.
29. Yerebakan C., Klopsch C., Prietz S., et al. Pressure-volume loops: feasible for the evaluation of right ventricular function in an experimental model of acute pulmonary regurgitation? Interact Cardiovasc Thorac Surg 2009. Doi: 10.1510/icvts.2008.198275.
30. Gray R., Greve G., Chen R., et al. Right ventricular myocardial responses to chronic pulmonary regurgitation in lambs: Disturbances of activation and conduction. Pediatr Res 2003. Doi: 10.1203/01.PDR.0000084829.67270.FA.
31. Kjaergaard J., Iversen KK., Vejlstrup NG., et al. Effects of chronic severe pulmonary regurgitation and percutaneous valve repair on right ventricular geometry and contractility assessed by tissue doppler echocardiography. Echocardiography 2010. Doi: 10.1111/j.1540-8175.2010.01153.x.
32. Bove T., Vandekerckhove K., Bouchez S., Wouters P., Somers P., Van Nooten G. Role of myocardial hypertrophy on acute and chronic right ventricular performance in relation to chronic volume overload in a porcine model: Relevance for the surgical management of tetralogy of Fallot. J Thorac Cardiovasc Surg 2014. Doi: 10.1016/j.jtcvs.2013.10.026.
33. Zeltser I., Gaynor JW., Petko M., et al. The roles of chronic pressure and volume overload states in induction of arrhythmias: An animal model of physiologic sequelae after repair of tetralogy of Fallot. J Thorac Cardiovasc Surg 2005. Doi: 10.1016/j.jtcvs.2005.08.034.
34. A. F., P. A., S. M-M., et al. Melody® transcatheter pulmonary valve implantation: Results from a French registry. Arch Cardiovasc Dis 2014. Doi: 10.1016/j.acvd.2014.10.001 LK - http://sfx.library.uu.nl/utrecht?sid=EMBASE&issn=18752128&id=doi:10.1016%2Fj.acvd.2014.10.001&atitle=Melody%C2%AE+transcatheter+pulmonary+valve+implantation%3A+Results+from+a+French+registry&stitle=Arch.+Cardiovasc.+Dis.&title=Archives+of+Cardiovascular+Diseases&volume=107&issue=11&spage=607&epage=614&aulast=Fraisse&aufirst=Alain&auinit=A

.&aufull=Fraisse+A.&coden=&isbn=&pages=607-614&date=2014&auinit1=A&auinitm=.
35. Godart F., Bouzguenda I., Juthier F., et al. Experimental off-pump transventricular pulmonary valve replacement using a self-expandable valved stent: A new approach for pulmonary incompetence after repaired tetralogy of Fallot? J Thorac Cardiovasc Surg 2009. Doi: 10.1016/j.jtcvs.2008.07.057.
36. Dardenne A., Fernandez C., Wagner A., et al. Benefits of standardizing the treatment of arrhythmias in the sheep (ovis aries) model of chronic heart failure after myocardial infarction. J Am Assoc Lab Anim Sci 2013.
37. Cools B., Brown SC., Heying R., et al. Percutaneous pulmonary valve implantation for free pulmonary regurgitation following conduit-free surgery of the right ventricular outflow tract. Int J Cardiol 2015;186. Doi: 10.1016/j.ijcard.2015.03.108.
38. Nørgaard MA., Lauridsen P., Helvind M., Pettersson G. Twenty-to-thirty-seven-year follow-up after repair for Tetralogy of Fallot. Eur J Cardio-Thoracic Surg 1999. Doi: 10.1016/S1010-7940(99)00137-2.
39. Gatzoulis MA., Balaji S., Webber SA., et al. Risk factors for arrhythmia and sudden cardiac death late after repair of tetralogy of Fallot: A multicentre study. Lancet 2000. Doi: 10.1016/S0140-6736(00)02714-8.
40. Lee C., Kim YM., Lee CH., et al. Outcomes of pulmonary valve replacement in 170 patients with chronic pulmonary regurgitation after relief of right ventricular outflow tract obstruction: Implications for optimal timing of pulmonary valve replacement. J Am Coll Cardiol 2012. Doi: 10.1016/j.jacc.2012.03.077.
41. Nollert G., Fischlein T., Bouterwek S., Böhmer C., Klinner W., Reichart B. Long-term survival in patients with repair of tetralogy of Fallot: 36- year follow-up of 490 survivors of the first year after surgical repair. J Am Coll Cardiol 1997. Doi: 10.1016/S0735-1097(97)00318-5.
42. Therrien J., Siu SC., McLaughlin PR., Liu PP., Williams WG., Webb GD. Pulmonary valve replacement in adults late after repair of tetralogy of Fallot: Are we operating too late? J Am Coll Cardiol 2000. Doi: 10.1016/S0735-1097(00)00930-X.

CHAPTER 5

Right ventricular remodeling and reverse remodeling after pulmonary valve replacement in an ovine TOF model

5.1 ABSTRACT

Introduction: Patients with tetralogy of Fallot (TOF) may develop severe pulmonary regurgitation (PR) after surgical repair resulting in chronic right ventricular (RV) volume overload. This leads to right ventricular failure, arrhythmias and premature sudden cardiac death. Pulmonary valve replacement (PVR) can normalize RV load and can partially reverse deleterious changes, but timing of PVR remains controversial. We evaluated RV remodeling in an ovine model of TOF and reverse remodeling after PVR at different time intervals after introducing PR.

Materials and methods: Lambs underwent supra-annular banding of the pulmonary artery (PS) via thoracotomy (n = 30). After 3 months this band was relieved by balloon dilation and the pulmonary valve (PV) was overstented to create regurgitation (PR) (n = 22). Sixteen animals received a Melody™ valve after 5 months (EARLY-PVR, n = 8) or after 10 months (LATE-PVR, n=8). Cardiac Magnetic Resonance (CMR) was performed in all groups before and within 2 weeks after each intervention and at sacrifice. Histological analysis to determine fibrosis and hypertrophy was done on full thickness myocardium at sacrifice.

Results: The PA banding, although tight on CMR and angiography, demonstrated 3 months after creation a peak velocity (Vmax) across the right ventricular outflow tract (RVOT) of 2.3±1.0 m/s in the EARLY-PVR group and 2.7±1.2 m/s in the LATE-PVR group. The PS was relieved resulting in decrease in invasive PTP gradient from 12±3 to 3±2 mmHg ($p < 0.001$) in EARLY-PVR and from 12±5 to 2±2 mmHg ($p < 0.05$) in LATE-PVR. Bare metal stent placement across the RVOT led to severe PR reflected by a PR fraction of 44±11% in EARLY-PVR and 41±8% in LATE-PVR. PR resulted in a major increase of right ventricular end diastolic volume indexed for body surface area (RVEDVi) in EARLY-PVR from 48.1±8.6 to 94.1±17.6 ml/m² ($p < 0.001$) and in LATE-PVR from 51.2±7.4 to 87.9±17.6 ml/m² ($p < 0.001$). Two weeks after PVR, RV reverse remodeling was more pronounced in the EARLY-PVR group with a ΔRVEDVi of 47.5±17.8 ml/m² compared to ΔRVEDVi of 27.5±12.5 ml/m² in the LATE-PVR group ($p < 0.05$). Five months after PVR the RVEDVi did not differ between EARLY-PVR 74.9±15.3 ml/m² and LATE-PVR 78.5± 34.4 ml/m² (ns) and still remained elevated. All animals who underwent PA banding showed hypertrophy. There was no difference in hypertrophy reflected by the number of transected myocytes per 1.3mm between the EARLY-PVR group (72.9±8.2) and LATE-PVR group (72.9+-10.6) (ns). The animals with chronic volume overload (PR group) who did not receive PVR showed more fibrosis reflected by a higher percentage of cross-linked collagen - 2.6±1.2% compared to animals who underwent EARLY-PVR 1.33±0.56% ($p < 0.05$) and LATE-PVR 1.89±0.85% (ns). The alpha smooth muscle cell actin (a-SMA) which is expressed by activated fibroblasts (myofibroblasts) was significantly more expressed in the PR group with 431.1±54.1 positive cells/mm² compared to 274.4±42.6 positive cells/mm² in EARLY-PVR ($p < 0.001$) and 261.5±68.0 positive cells/mm² in LATE-PVR ($p < 0.001$).

Conclusion: This ovine model showed pathophysiological changes comparable to the late postoperative course in TOF. Severe PR led to RV volume overload. EARLY-PVR showed a higher rate of RV reverse remodeling but after 5 months no difference in RVEDV changes between EARLY-PVR and LATE-PVR was observed. The severe PR with chronic RV volume overload induced fibrosis and PVR resulted in less fibrosis, which was most pronounced after EARLY-PVR.

5.2 INTRODUCTION

The treatment strategy in patients with a tetralogy of Fallot (TOF) has evolved over the past decades. Back in the 1980s' the aim was to achieve maximal relief the RVOT stenosis accepting any degree of pulmonary regurgitation (PR), because residual RVOT stenosis was a major risk factor for postoperative death.(1) The severe PR which led to progressive right ventricular (RV) volume overload was well tolerated for some decades, but in the long-term this chronic RV volume overload resulted in RV failure and malignant arrhythmias leading to sudden cardiac death (SCD).(2–9) Replacing the pulmonary valve (PVR) is deemed necessary in patients with TOF and severe PR. Until 2000 PVR was only possible surgically using a conduit or allograft. Surgical conduits has limited longevity ranging from 47-78% at 10 years after implantation.(10–13) Due to the limited durability and need for redo-PVR during life with increasing complexity after each redo sternotomy the aim was to keep the total number of surgical redo-PVR during a lifetime as low as possible.

Guidelines with recommendations for PVR were therefore established, using surrogate end-points.(2,14–17) PVR has never been proven to reduce the burden of malignant arrhythmias, SCD and RV failure.(18)

The surgical strategy was adapted with 'valve sparing' techniques in order to reduce the risk of developing PR and subsequent need for PVR.(19–21) With the development of the stented valve in the years 2000 the era of percutaneous pulmonary valve replacement therapy (PPVR) was initiated. The advantages of this technique include minimal procedural discomfort, low morbidity, hardly no procedural mortality and good medium-term longevity of the valve.(22,23) The PPVR technique became attractive for TOF patients; the debate on ideal timing of PVR was restarted.(2,4,6,8,18,24–31) It takes 3-4 decades before a change in treatment strategy can show a difference in the long-term risks. Animal models with shorter lifespan can help to address some of these research questions. Different animal models with PR leading to RV volume overload have been created.(32,33,42,43,34–41) used a transannular patch, others leaflet resection or external plication of the leaflets and some placed bare metal stents across the pulmonary valve in order to create PR.(32,37,41–45) Reports focus on the feasibility of the stent or valve implantation but only few performed PVR and looked at RV reverse remodeling.(37,38,46,47)

The aim was to study RV remodeling due to chronic volume overload and reversed RV remodeling after pulmonary valve replacement at different time intervals using an animal model which simulates pathophysiological changes with late postoperative TOF patients.

5.3 MATERIALS AND METHODS

All experiments were conducted in the laboratory of experimental cardiac surgery animal facility of the KUL. The facility carries the license number LA 1210253. The project was approved by the ethical board for animal experiments with project number 024/2014. All interventions and CMR scans were performed under general anesthesia: intravenous injection (IV) of 22 mg/kg of ketamine (Nimatek® 100 mg/ml, Dechra), inhaled Isoflurane Veterinary 5% (Iso-Vet 1000 mg/g, Dechra) at induction and 2.5% maintenance. Analgesia during interventional procedures was given using 0.03 mg/kg IV buprenorphine (Vetergesic® 0.3mg/ml, Ceva) and 0.2 mg/kg IV meloxicam (Metacam® 20 mg/ml, Boehringer Ingelheim). Analgesics were continued after interventions as long as deemed necessary by the site staff. For infective prophylaxis 40.000 IU/kg IV penicillin (2.000.000 IE/UI, Kela Pharma) and 6.6 mg/kg IV gentamycin (Genta-Kel® 50 mg/ml Kela Pharma) was used. During endovascular procedures 100 IU/kg IV heparin was administered and repeated every hour. Monitoring consisted of 3-lead ECG, oxygen saturation, exhaled CO_2, invasive blood pressure monitoring (arterial line at the ear site), IV access. Peripheral IV line was inserted in a posterior limb. Twenty-four hours prior to an endovascular procedure, 5 mg/kg IV amiodarone and at the start of the procedure 1 mg/kg IV lidocaine was administered. Animals who underwent PVR (n=16) received 100 mg acetylsalicylic acid orally once daily.

A total of 46 animals started the experiments. Eight animals were excluded from the analysis for the following reasons: ventricular fibrillation (VF) (n = 4), stent embolization (n = 2), endocarditis (n = 1), rupture of the PA on balloon dilation (n = 1). Eight (n=8) healthy animals were also analyzed and served as a reference group.

VF and stent embolization occurred at bare metal stent placement and were not observed at PVR.

The animals were allocated to the following groups: (Fig. 1)

Study groups

1. EARLY-PVR (n=8). PS was created at the age of 4.5±0.5 months. Relief of PS and bare metal stent placement across the PV at the age of 7.5±0.5 months. PVR with Melody™ valve at the age of 12.5±0.5 months. Sacrifice 5 months after PVR (age 17.5±0.5 months).
2. LATE-PVR (n=8). PS was created at the age of 4.5±0.5 months. Relief of PS and bare metal stent placement across the PV at the age of 7.5±0.5 months. PVR with Melody™ valve at the age of 17.5±0.5 months. Sacrifice 5 months after PVR (age of 22.5±0.5 months).

Reference groups

1. PR group (n=6). PS was created at the age of 4.5±0.5 months. Relief of PS and bare metal stent placement across the PV at the age of 7.5±0.5 months. No PVR was performed and sacrifice after 5 months PR (age 12.5±0.5 months).
2. PS group (n=8). PS was created at the age of 4.5±0.5 months. Sacrifice after 3 months (age 7.5±0.5 months).
3. Healthy animals (n=8). No intervention. Sacrifice at the age of 12.5±0.5 months.

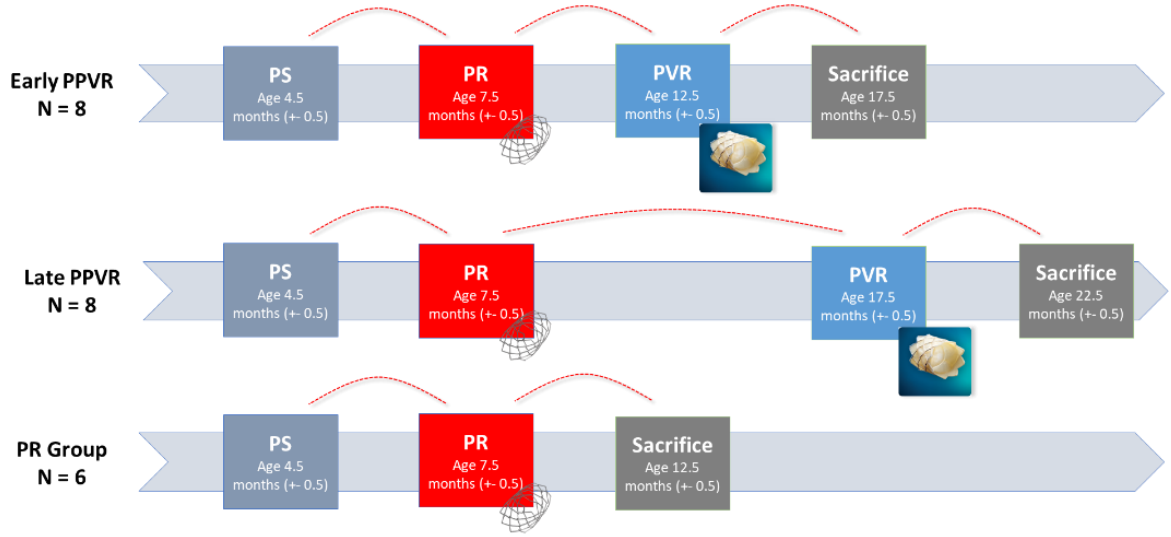

Figure 1 Timeline and interventional schedule of EARLY-PVR, LATE-PVR and PR group. PPVR percutaneous pulmonary valve replacement, PS pulmonary stenosis, PR pulmonary regurgitation, PVR pulmonary valve replacement

5.3.1 Interventions

5.3.1.1 Creation of the supravalvular pulmonary stenosis (PS)

In 30 animals a supravalvular PS was created. A left sided thoracotomy in the 4th intercostal space was performed at a mean age 4.5± 0.5 months (lamb stage). A polytetrafluoroethylene (PTFE) strip with a radio-opaque marker (the opaque marker from a surgical swab) attached was fixed at the level of the sino-tubular junction of the pulmonary trunk and sutured to avoid displacement and migration. (Fig. 2A)

5.3.1.2 Relief of the PS and creating pulmonary regurgitation (PR)

In the groups EARLY-PVR (n=8), LATE-PVR (n=8) and PR group (n=6) the PS was dilated and PR created percutaneously at the age of 7.5 months (± 0.5). A 12 Fr sheath (Cordis®, Santa Clara, USA) was placed at the left jugular vein. A 6 Fr end-hole Lehman catheter with a 0.035" J-tip wire Radifocus® guidewire M (Terumo® Leuven, Belgium) was placed into the distal pulmonary artery branch and exchanged for

a 0.035" Amplatz® Super Stiff wire (Boston Scientific, Voisins-Le-Bretonneux, France). A 6 Fr right coronary guiding catheter was advanced into the PA branch and a 0.035" E-wire® (Jotec, Hechingen, Germany) was advanced with removal of the Amplatz® Super Stiff wire. The PS was dilated using a 22 mm high-pressure balloon Atlas® Gold (Bard, Arizona, USA) with a pressure insufflator until full expansion of the balloon and opening of the band was achieved. A 14 Fr 85 cm Performer™ guiding sheath (Mullins design) (Cook Medical, Limerick, Ireland) was then placed into the PA trunk. A bare metal stent was implanted in the RVOT across the PV with at least 1 zig distal to the banding site. Stents were delivered on a 22 mm BIB™-balloon (Numed, Hopkinton NY, US). Two stent types were used depending on availability: 45 mm CP-stent™ (Numed®, Hopkinton, NY, US) (n=16) or 43 mm AndraStent® XXL (Andramed GmbH, Reutlingen, Germany) (n=8). (Fig. 2B&2C)

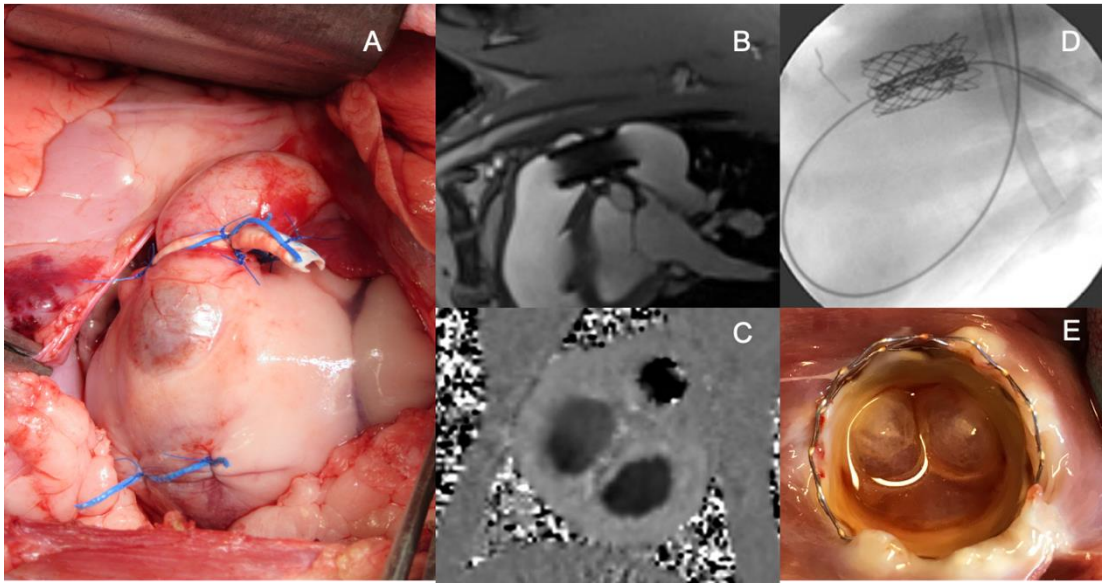

Figure 2A/ circular PTFE strip at the sino-tubular junction tightened until thrill at the pulmonary trunk ends were sutured with Prolene 5/0 and fixed with two stitches (Prolene 5/0) at the wall of the pulmonary trunk. On the PTFE strip is a radio-opaque marker fixed, another marker is sutured on the sub valvular level to facilitate the stent implantation later. **2B/** magnetic resonance image of bare metal stent across the pulmonary valve and fixed at the banding site. **2C/** short axis CMR image showing massive pulmonary valve regurgitation. **2D/** still frame of fluoroscopy during Melody valve implantation in stent, ECMO cannula. **2E/** view on the Melody™ valve at time of sacrifice, normal function and aspect of the valve leaflets, ingrowth of the stent at the RVOT and PA wall.

5.3.1.3 Valve replacement

A Melody™ valve was implanted at the age of 12.5 months (± 0.5) in the EARLY-PVR group (n=8) and at the age of 17.5 months (± 0.5) in the LATE-PVR group (n=8).

The initial experience in a pilot study showed high mortalility during PVR due to hemodynamic and electrical instability. Therefore it was decided to use extracorporeal membrane oxygenation (ECMO) during PVR. ECMO was performed using a 15 Fr cannula (Getinge, Gothenborg, Sweden) in the carotid

artery and a 19 Fr cannula in the jugular vein. A second jugular access was provided with an 8 Fr introducer sheath (Cordis®, Santa Clara, USA) 5 cm distal to the ECMO cannulae. Using ECMO no VT/VF was observed and no animals were lost duriung PVR.

With a 6 Fr Arrow® Berman wedge catheter (Teleflex®, Morrisville, USA) the bare stent in de RVOT was crossed (avoid passing through the struts). The Melody™ valve (Medtronic Inc, Minneapolis, USA) was delivered in the RVOT on a 22 mm Melody™ TPV Ensemble™ II under partial ECMO support (up to 2.5 L/min). (Fig. 2D)

5.3.2 Analysis

5.3.2.1 Imaging

All animals underwent a cardiac magnetic resonance imaging (CMR) at scheduled intervals (3T Magnetom Trio Siemens®): 1/ before the relief of the PS and creation of the pulmonary valve regurgitation (1-2 weeks) 2/ after creation of the PR (1-2 weeks) 3/ before valve replacement (1-2 weeks) 4/ after valve placement (1-2 weeks) and 5/ at time of sacrifice. In the healthy animals a CMR was also performed. All scans were performed by the same observer (P.C.). Image analysis was done using Matlab® (MathWorks®, USA) (B.C. and P.C.). Ventricular dimensions were obtained using slice by slice manual contouring of the endocardial and epicardial border in systolic and diastolic phases on the short axis views. The papillary muscles were excluded from the tracing in volumetric assessment. In the RV mass calculation only the RV free wall was used, the septum was excluded. Ventricular mass was calculated from the ventricular wall volume using the density of myocardium of 1.05 g/mL.(48)(49) The volumetric dimensions, mass, stroke volume and EF were obtained of all scans in each animal for the right and left ventricle. Pulmonary and tricuspid valve flows and regurgitation fraction were calculated on short axis view slices and phase contrast images. Pulmonary regurgitation was calculated by quantifying the reversal of diastolic flow on the phase contrast images, which were acquired perpendicular to the PA and distal from the PV. Data were indexed for body surface area (BSA) with use of the formula of Mitchell $0.09xW^{0.67}$. (50)

5.3.2.2 Hemodynamics

Prior to stent placement and before sacrifice, RA, RV and pulmonary artery pressures were obtained using an end-hole catheter. Arterial blood pressure was obtained using a standard arterial line.

5.3.2.3 Histology

All animals were sacrificed using a lethal dose of pentobarbital (Dolethal® Vetoquinol). Histological

analysis was performed by Ch.K.N. who was blinded for the study groups.

Fibrosis

The tissue samples from the right and left ventricle of the heart were fixed in 4% paraformaldehyde (PFA). Specimens were then processed in histokinette and embedded in paraffin. Tissue sections of 8µm size were prepared and deparaffinized, stained using Sirius red kit (Polysciences) according to manufacturing instructions. The sections were imaged using a Zeiss Axioplan microscope to quantify interstitial fibrosis. Based on the birefringence properties of collagen using polarized light, the collagen subtypes were quantified: type I thick fibers (red-yellow) and thin fibers, type III (green)(51). The images were quantified using Axiovision software to quantify fibrosis and collagen subtypes.

Hypertrophy

Cardiomyocyte hypertrophy was assessed as follows: the right ventricle tissue samples were embedded in OCT compound and 8µm size sections prepared. The tissue sections were fixed in 2% PFA and incubated with Wheat Germ Agglutinin (WGA) with Alexa Fluor™ 647 Conjugate (ThermoFisher Scientific, Waltham, USA) for one hour. The sections were mounted using Prolong antifade gold and imaged using a Nikon A1R microscope. Four random images in the non-fibrotic regions were selected. Horizontal and vertical lines of 165µm size were drawn on each image and the number of transected cardiomyocytes counted.(52)

Immunofluorescence staining for Myofibroblast (MyoFb) quantification in situ

The number of αSMA positive cells in the tissue were quantified and used as a marker for myofibroblasts.(53) The 8µm size cryo-sections were fixed in 2% PFA for 15 minutes, permeabilized with 0.2% Triton-X100 for 20 minutes at room temperature. Sections were blocked with 2% BSA for 30 minutes and subsequently incubated overnight at 4 degrees with α-SMA antibody (1:250 dilution, A2547, Sigma-Aldrich, Overijse, Belgium). Next, the sections were washed and incubated with goat-anti-mouse Alexa 488 secondary antibody (1:500 dilution, A28175, ThermoFisher Scientific, Waltham, USA) and further labeled with WGA and mounted using prolong antifade gold with DAPI (ThermoFisher Scientific, Waltham, USA). Imaging and quantification was performed.(53)

5.3.3 Statistical analysis

Statistical analysis was performed using SPSS© version 26 (IBM©). Test for normality was done using Kolmogorov-Smirnov test. Paired data were analyzed by a Student t-test. Comparison among different groups was done using Anova (F) test, with multiple comparison. Continues data are expressed as means and the standard error of the mean. Statistical significance was accepted with a p-value < 0.05.

Graphs were plotted using Prism® 8 (GraphPad©).

5.4 RESULTS

In each of the study groups EARLY-PVR and LATE-PVR 8 animals completed the series. In the PR group (n=6) 1 animal was excluded for further analysis as the bare metal stent got dislocated in the weeks after the procedure; the remaining 5 were used in the analysis. Malignant arrhythmias and ventricular failure were not observed in the studied animals.

5.4.1 Hemodynamics

The pulmonary artery band resulted in a tight supravalvular stenosis observed on CMR and angiography.

Three months after PA banding at the age of 7.5±0.5 months a mild PS was observed on CMR velocity measurement in the EARLY-PVR, LATE-PVR and the PR group. (Table 1) These observations were confirmed by invasive measurement of the gradient across the RVOT.

The pulmonary artery stenosis was completely relieved by balloon dilation resulting in a significant reduction of the RV to PA peak-to-peak (PTP) gradient, respectively EARLY-PVR ($p < 0.001$), LATE-PVR ($p < 0.05$) and PR group ($p < 0.05$). The PR fraction and the PV regurgitant volume indexed for BSA in the EARLY-PVR, LATE-PVR and PR group are depicted in Table 1 and Fig. 3.

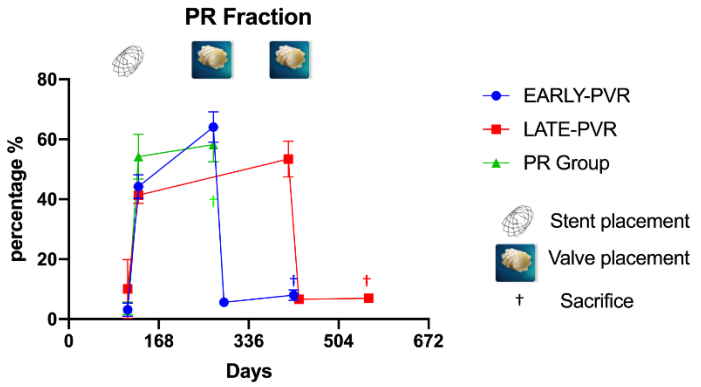

Figure 3 Pulmonary regurgitation (PR) fraction over time

5.4.2 RV remodeling after stent placement

The PR gave rise to a significant increase in the RV dimensions within 2 weeks after stent placement. (Table 1 and Fig. 4.) Right ventricular end diastolic volume indexed for BSA (RVEDVi) and end systolic volume (RVESVi) increased significantly in the EARLY-PVR, LATE-PVR and PR group. LV systolic and diastolic dimensions did not change after stent placement. The RV to LV diastolic ratio however,

increased significantly due to the RV dilation in the EARLY-PVR, LATE-PVR and PR groups. The mass-to-volume ratio decreased significantly after PR in EARLY-PVR ($p < 0.05$) and LATE-PVR ($p < 0.05$) and the reference PR group ($p < 0.05$).

5.4.3 RV reverse remodeling after pulmonary valve replacement

Once PVR was performed the PR fraction and the indexed PV regurgitant volume decreased significantly in the EARLY and the LATE-PVR group as shown in Fig 3 and Table 3. RVEDVi and RVESVi decreased significantly in both PVR groups ($p < 0.001$). Reverse remodeling of the RV was more pronounced in the EARLY-PVR group compared to the LATE-PVR early after PVR which was reflected by a significantly greater Delta (Δ) of change in RVEDVi ($p < 0.05$) in EARLY-PVR (47.5±17.8 ml/m²) compared to LATE-PVR (27.5±12.5 ml/m²). (Fig. 4A)

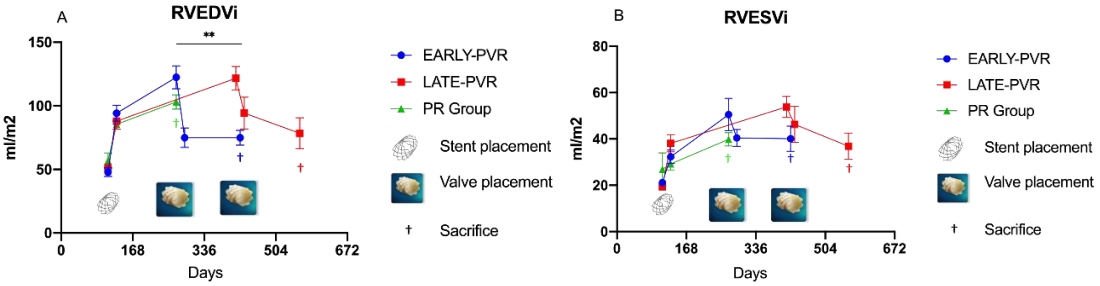

Figure 4 A/ Evolution of right ventricular end diastolic volume (indexed for body surface area BSA) after interventions in the EARLY-PVR, LATE-PVR and PR group, **B/** Evolution of right ventricular end systolic volume (indexed for BSA) after interventions in the EARLY-PVR, LATE-PVR and PR group. PVR pulmonary valve replacement, PR pulmonary regurgitation.

In the LATE-PVR group the RVEDVi and RVESVi decreased further in the months after PVR whereas in the EARLY-PVR group the RV dimensions remained unchanged. Five months after PVR the RVEDVi and RVESVi were similar between the EARLY-PVR and LATE-PVR group and remained elevated in both (Table 2 and Fig. 4).

The RV to LV systolic and diastolic ratio remained unchanged in the EARLY-PVR and LATE-PVR group between the PVR and time of sacrifice. Left ventricular systolic and diastolic dimensions did not differ from the moment of PVR to time of sacrifice in EARLY and LATE-PVR.

The RV mass-to-volume ratio did increase significantly after PVR in EARLY-PVR and LATE-PVR (both $p < 0.05$) though. (Table 2)

Table 1 CMR data and hemodynamics before and after pulmonary regurgitation

		Before PR						After PR					
		Vmax	RV-PA systolic gradient	PR fraction	PV regurgitant volume (i)	RVEDVi	RVESVi	Vmax	RV-PA systolic gradient	PR fraction	PV regurgitant volume (i)	RVEDVi	RVESVi
		m/s	*mmHg*	*%*	*ml*	*ml/m²*	*ml/m²*	*m/s*	*mmHg*	*%*	*ml*	*ml/m²*	*ml/m²*
EARLY-PVR	**n = 8**	2.3±1.0	12±3	3±5	0.97±1.6	48.1±8.6	21.2±2.7	1.3±0.5**	3±2***	44±11***	24.3±4.1***	94.1±17.6***	32.3±8.3**
LATE-PVR	**n = 8**	2.7±1.2	12±5	0.3±0.4	0.12±0.15	51.2±7.4	19.3±3.5	1.6±0.5**	2±2**	41±8***	21.2±5.8***	87.9±17.6***	38.1±10.4***
PR Group	**n = 5**	2.6±1.2	11±1	3±4	1.1±1.5	57±13.8	26.9±15.9	1.4±0.5*	3±3**	55±17**	24.1±6.0***	85.5±8.5**	29.2±5.9*
p value¹		*ns*	*ns*	*ns*	*ns*	*ns*	*ns*	*ns*	*ns*	*<0.05*	*ns*	*ns*	*ns*
PS Group	**n = 8**	2.4 ±1.1	14±11										
Healthy animals	**n = 8**	1.4±0.5	2±2										
p value²		*<0.05*	*<0.001*										
		LVEDVi	**LVESVi**	**RV-LV diastolic ratio**	**RV-LV systolic ratio**	**RV mass i**	**Mass-to-Volume ratio**	**LVEDVi**	**LVESVi**	**RV-LV diastolic ratio**	**RV-LV systolic ratio**	**RV mass i**	**Mass-to-Volume ratio**
		ml/m²	*ml/m²*			*ml/m²*		*ml/m²*	*ml/m²*			*ml/m²*	
EARLY-PVR	**n = 8**	53.0±8.2	22.5±3.9	0.91±0.11	0.95±0.08	22.3±2.4	0.5±0.1	52.5±6.5*	24.1±3.7*	1.81±0.39**	1.33±0.24**	32.8±9.3**	0.3±0.2**
LATE-PVR	**n = 8**	58.9±8.3	21.3±4.2	0.87±0.84	0.91±0.11	22.0±2.7	0.4±0.1	45.8±8.2**	26.0±4.5**	1.93±0.22***	1.44±0.22***	27.3±4.4**	0.3±0.1**
PR Group	**n = 5**	55.3±4.6	23.2±3.1	1.05±0.34	1.18±0.78	24.8±2.4	0.45±0.1	45.7±11.1**	21.0±6.6*	1.93±0.36**	1.48±0.54*	27.9±4.0**	0.3±0.1**
p value¹		*ns*	*ns*	*<0.05*	*ns*	*ns*	*ns*	*ns*	*ns*	*ns*	*ns*	*ns*	*ns*

p value¹ *comparison between EARLY-PVR, LATE-PVR and PR group,* ***p value²*** *comparison between all groups*

*** p value <0.001, ** p value <0.05, * not significant (ns)

Vmax *maximum velocity on CMR in m/s,* ***(i)*** *indexed for body surface arrea*

RVEDVi *right ventricular end diastolic volume indexed for body surface area (BSA).* ***RVESVi*** *right ventricular end systolic volume indexed for BSA*

LVEDVi *left ventricular end diastolic volume indexed for BSA.* ***LVESVi*** *left ventricular end systolic volume indexed for BSA.* ***RV-LV*** *right to left ventricular*

Table . CMR data before and after PVR and sacrifice

		Before PVR					After PVR					Sacrifice			
		PR fraction	PV regurgitant volume (i)	RVEDVi	RVESVi	RV mass i	PR fraction	PV regurgitant volume (i)	RVEDVi	RVESVi	RV mass i	RVEDVi	RVESVi	RV-LV Diastolic ratio	RV mass i
		%	*ml/m²*	*ml/m²*	*ml/m²*		*%*	*ml/m²*	*ml/m²*	*ml/m²*		*ml/m²*	*ml/m²*		*ml/m²*
EARLY-PVR	**n = 8**	64±14	33.7±8.3	122.4±25.3	52.3±17.7	37.0±7.9	6±3***	1.7±0.9***	75±21.5***	40.5±10.5**	32.9±7.9**	74.9±15.3*	40.1±14.5*	1.7±0.7*	31.9±5.3*
LATE-PVR	**n = 8**	53±17	23.5±8.4	121.5±26.3	53.8±12.8	36.7±6.4	7±2***	2.0±0.7***	94.3±35.3***	43.4±20.0*	37.7±5.7*	78.5±34.4**	36.8±15.9**	1.7±0.7*	31.7±8.7**
p value¹		*ns*	*<0.05*	*ns*	*ns*	ns	*ns*	*ns*	*ns*	*ns*	ns	*ns*	*ns*	*ns*	*ns*
PR Group	**n = 5**											103.2±12.5	39.8±6.5	2.4±0.5	30.1±4.7*
PS Group	**n = 8**											49.4±9.4	20.8±6.2	0.9±0.1	23.8±5.2
Healthy animals	**n = 8**											46.1±12.1	17.4±5.2	0.8± 0.1	20.9±4.0
p value²												*<0.001*	*<0.001*	*<0.001*	*<0.001*
		LVEDVi	**LVESVi**	**RV-LV Diastolic ratio**	**RV-LV Systolic Ratio**	**Mass-to-Volume ratio**	**LVEDVi**	**LVESVi**	**RV-LV Diastolic ratio**	**RV-LV Systolic Ratio**	**Mass-to-Volume ratio**	**LVEDVi**	**LVESVi**	**RV-LV Systolic Ratio**	**Mass-to-Volume ratio**
		ml/m²	*ml/m²*				*ml/m²*	*ml/m²*				*ml/m²*	*ml/m²*		
EARLY-PVR	**n = 8**	46.1±11.5	22.2±3.1	2.3±0.7	2.0±0.6	0.3±0.1	50.3±11.8*	22.2±5.7*	1.6±0.6***	2.0±0.9*	0.4±0.1**	49.0±12.5*	20.9±5.7*	2.1±1.2*	0.4±0.1*
LATE-PVR	**n = 8**	48.4±6.9	23.5±5.3	2.2±0.7	2.2±0.8	0.3±0.1	52.0±11.0*	21.2±7.5*	1.8±0.5***	2.1±0.5*	0.4±0.1**	46.4±6.3*	21.6±3.3*	1.7±0.7*	0.4±0.1*
p value¹		*ns*	*ns*	*ns*	*ns*	ns	*ns*	*ns*	*ns*	*ns*	ns				
PR Group	**n = 5**											44.2±5.7	22.3±4.0	1.8±0.4	0.3±0.0**
PS Group	**n = 8**											56.8±11.1	24.2±5.6	0.9±0.2	0.5±0.1
Healthy animals	**n = 8**											56.4±9.9	23.6±5.0	0.7±0.2	0.5±0.1
p value²												*<0.05*	*ns*	*<0.001*	*<0.05*

p value¹ *comparison between EARLY-PVR and LATE-PVR ,* ***p value²*** *comparison between all groups*

*** p value <0.001, ** p value <0.05, * not significant (ns)

RVEDVi *right ventricular end diastolic volume indexed for body surface area (BSA).* ***RVESVi*** *right ventricular end systolic volume indexed for BSA, , PVR pulmonary valve replacement*

LVEDVi *left ventricular end diastolic volume indexed for BSA.* ***LVESVi*** *left ventricular end systolic volume indexed for BSA.* ***RV-LV*** *right to left ventricular*

5.4.4 Fibrosis

The animals with RV volume overload (reference group PR) showed the highest percentage of RV interstitial fibrosis and cross-linked collagen. Interstitial fibrosis was significantly more pronounced in the PR group compared to the EARLY ($p < 0.05$) and the LATE-PVR group ($p < 0.05$). There was no difference between EARLY-PVR and LATE-PVR. RV interstitial fibrosis was significantly more in the PR group compared to the PS group ($p < 0.05$) and healthy animals ($p < 0.001$). (Fig. 5. and Table 3)

The percentage of cross-linked collagen in the RV was significantly higher in the PR group compared to the EARLY-PVR ($p < 0.05$) but not significantly different from the LATE-PVR group (ns). EARLY-PVR showed a lower percentage of RV cross-linked collagen compared to the LATE-PVR, the difference did not reach statistical significance (ns).

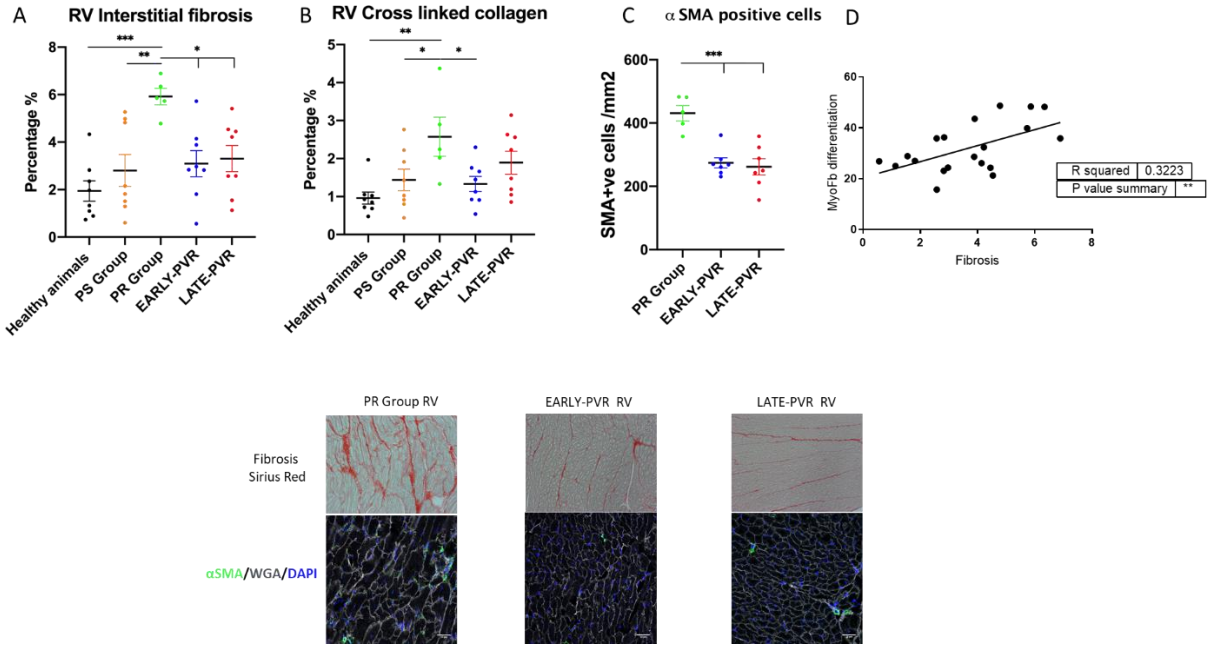

Figure 5 Fibrosis of the right ventricle. Sirius red staining and expression of alfa SMA. A/ Right ventricular interstitial fibrosis, B/ RV cross linked collagen, C/expression of alfa SMA positive cells, D/ correlation between fibrosis and myofibroblast (MyoFb) differentiation.

Table 3. Fibrosis and hypertrophy

		RV Interstitial fibrosis	RV cross linked collagen	α SMA positive cells	Number of transected myocytes
		%	*%*	*number/ mm²*	number/ 1.3 mm
EARLY-PVR	**n=8**	3.1±1.6	1.3±0.6	274.4± 42.6	72.9±8.2
LATE-PVR	**n=8**	3.3±1.6	1.9±0.9	261.5±68.0	72.9±10.6
PR Group	**n=5**	5.6±1.1	2.6±1.2	431.1±54.1	58.2±5.5
PS Group	**n=8**	3.0± 1.8	1.4±0.8		71.6±11.2
Healthy Animals	**n=8**	1.9± 1.2	1.0±0.5		91.5±11.9
p value		*<0.001*	*<0.001*	*<0.001*	*<0.001*

p value *comparison between all groups*

RV *right ventricle,* ***α SMA*** *alpha smooth muscle cell actin*

The alpha-smooth muscle cell actin (α-SMA) which was expressed in myofibroblasts (MyoFb) was analyzed in EARLY-PVR, LATE-PVR and PR group. The α-SMA was significantly more expressed in the PR group compared to the EARLY-PVR group (p <0.001) and the LATE-PVR group (p <0.001). There was no difference between EARLY and LATE-PVR. (Fig. 5C)

All animals that underwent PA banding demonstrated hypertrophy. The hypertrophy (reflected by the number of transected myocytes per 1.3mm) did not differ between the EARLY-PVR and LATE-PVR group (ns). The hypertrophy was most pronounced in the PR group who had a significantly lower number of myocytes per 1.3 mm compared to the healthy animals (p <0.001). (Fig. 2. and table 3)

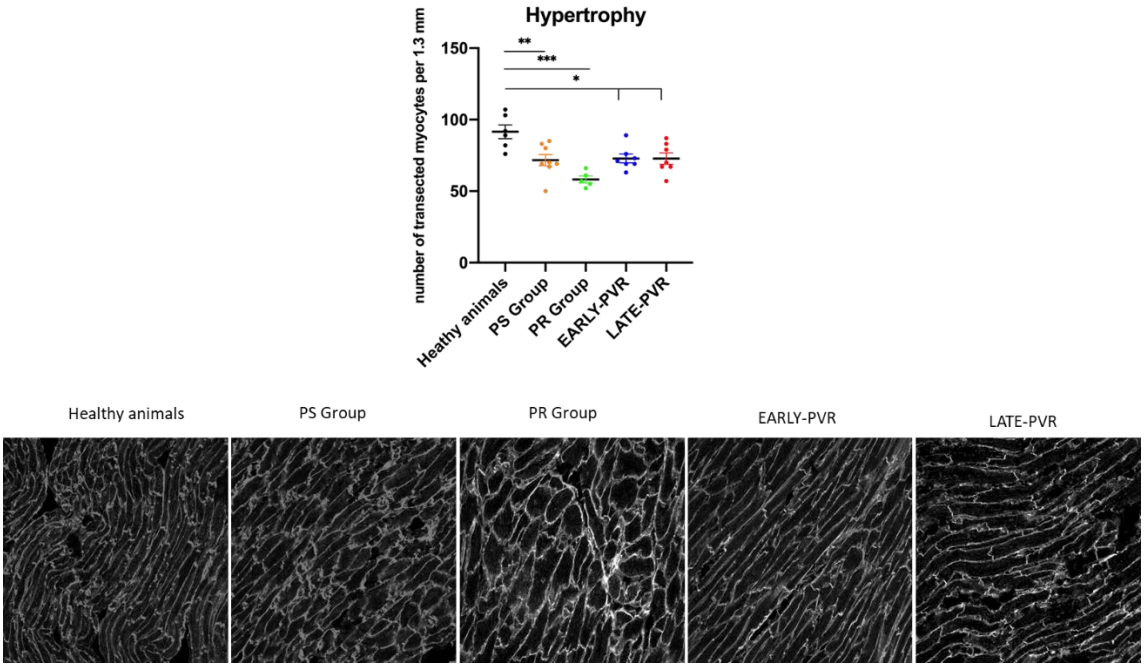

Figure 6 Hypertrophy; number of transected myocytes per 1.3 mm, from left to right the Healthy animals (n=8), PS group (n=8), PR group (n=5), EARLY-PVR (n=8), LATE-PVR (n=8), *Healthy animals and EARLY-PVR/LATE-PVR both p <0.05, ** healthy animals and PS group p <0.05, *** healthy and PR group p <0.001

5.5 Discussion

We present an ovine model with pathophysiologic changes comparable to the late postoperative course of patients with tetralogy of Fallot. The animals in the study developed severe pulmonary valve regurgitation leading to important right ventricular volume overload. Early valve replacement resulted in fast RV reverse remodeling within 2 weeks after PVR. Late valve replacement showed delayed RV reverse remodeling. Five months after PVR the RV dimensions between both PVR groups were remarkably similar, but remained elevated.

PR led to activation of fibroblasts (myofibroblasts) reflected by a higher expression of the alpha-

smooth muscle cell actin (α-SMA). The animals with chronic RV volume overload (PR) showed an increased percentage of interstitial and cross-linked collagen. PVR reduced the expression of α-SMA. In both PVR groups a lower percentage of interstitial and cross-linked collagen was observed compared to animals with PR. The percentage of cross-linked collagen was lower in the early valve replacement group compared to the late valve replacement group.

The presented ovine model with severe PR and RV volume overload compares well to the late postoperative course of patients with TOF.

PA banding resulted in a mild gradient after 3 months, although it was tight on CMR and angiography. Other animals studies with creation of PS and/or PR were performed in pigs.(35,42,43,54) Lambert *et al* performed pulmonary valve leaflet resection with enlargement of the RVOT and PA banding. After four months the RVOT gradient on echocardiography was mean 45.6±11.7 mmHg which was higher compared to the studied lambs.(35) The pigs' weight increased 300% in 4 months from 18.9±1.1 kg to 56.8±3.0 kg. The lambs' weight increased 134% in 3 months which can partially explain the slightly lower gradient.

Stenting of the RVOT resulted in immediate and progressive severe PR which led to important RV dilatation. A similar technique has been used in pigs resulting in PR.(37,44,55) Kuehne *et al* placed a stent across the PV in 6 pigs. The PR fraction was 30.2±5.6% after 2 days and 50.6±8.9% after 3 months. The PR fraction in the current study was more pronounced compared to the pig model. In Søndergaards' experiments in pigs, the PR fraction ranged in the studied groups from 45.7±12.5% to 60.2±4.9% before PPVR.(37,55) In the pig models no PS was created before PR was created. Other techniques which have been used to create PR are external suture plication of the pulmonary valve, leaflet resection (valvectomy) and/or a transannular patch.(32,33,35,39–41) After a transannular patch the RVOT can become dilated and therefore the model is less suitable for PVR with a stented valve (Melody™) with limited outer diameter of 24.1 mm.

It is difficult to compare data of a growing animal model to human data and a lot of assumptions need to be made. The age of 12.5±0.5 months for EARLY-PVR and 17.5±0.5 months for LATE-PVR was chosen based on the key physiological milestones and weight gain of the sheep. Wang *et al* described a quantitative translation of dog-to-human aging. (56) The Deoxyribonucleic Acid (DNA) methylomes of dogs (Labradors) were compared with human methylomes and showed a nonlinear relationship in translation of dog to human years. Unfortunately, similar and more specific ovine data do not exist. Assuming the lifespan and the timing of key physiological milestones of dog and sheep are quite similar, the calculation method can be extrapolated. Using this calculation method on the ovine model,

EARLY-PVR should correspond to a human age of 15-25 years and LATE-PVR to 30-40 years.

The PR resulted in RV volume overload. Immediately after PVR, right ventricle reverse remodeling takes places and was more noticeable in EARLY-PVR with a higher ΔRVEDVi. The animals of the LATE-PVR group showed a delayed reverse remodeling. Five months after PVR there was no difference between EARLY- and LATE-PVR. Ersboell *et al* performed PVR at different time intervals in pigs with sacrifice 1 month after PVR. An increase beyond ΔRV of 120 ml/m² was predictive for a low probability of recovery.(37) The delayed reverse remodeling as demonstrated in LATE-PVR might not have been depicted in 1 month after PVR. In patients with TOF the RV reverse remodeling takes place immediately after PVR, followed by a continuing process of further but incomplete remodeling. Further reduction of the RVESVi has been observed 3 years after PVR.(57)

In the present study an increased expression of α-SMA was observed in animals with chronic RV volume overload (PR group) and once PVR was performed the expression decreased significantly. Due to any injury of the heart the cardiac fibroblasts can become activated. Activated fibroblasts (myofibroblasts) express alpha-smooth muscle cell actin (α-SMA). These cells play an important role in cardiac repair, remodeling and protection from adverse remodeling as seen for example in myocardial infarction.(58) When the myocardial injury however persists there is prolonged expression resulting in fibrosis with increased collagen deposition. The observed data suggest that PR and RV volume overload activated the fibrotic process and following PVR the number of activated fibroblasts decreased. Accordingly, the percentage of interstitial and cross-linked collagen was increased in animals with chronic RV volume overload and once PVR was performed the fibrotic changes became less pronounced. The reverse remodeling process after PVR for a chronic overloaded right ventricle has effects on the regulation of extracellular matrix and cellular composition. To the best of our knowledge, we developed one of the first animal models where chronic volume overload on the RV has been studied in relation to histology. The ovine model cannot incorporate chronic hypoxia as in patients with TOF before repair. Transcriptomic analysis in patients with TOF showed that chronic hypoxia induces expression of genes associated with apoptosis and remodeling, as well expression of genes associated with myocardial contractility and function.(59)

Fibrotic changes in the RV with an increased collagen deposition are mostly observed in case of chronic RV pressure overload.(60) CMR studies in patients with TOF showed that fibrosis is more pronounced in case of pressure overload, late repair and increased patient age.(61) In a pressure overloaded RV there is an increased secretion of collagen I with a change in ratio of collagen I and III leading to increased RV stiffness and diastolic dysfunction.(60,62) Fibrotic changes due to RV volume overload have hardly been evaluated. Kozak *et al* found in 18 children with TOF repair shorter post-contrast T1

values of the right ventricular anterior wall compared to healthy children suggesting a higher degree of fibrosis.(63) The group of Tal Geva showed that in patients with TOF using T1 mapping, expansion of the extracellular volume (ECV) fraction was present which reflects the ratio of extracellular matrix volume to total myocardial volume. This increased ECV was demonstrated in RV volume overload and was negatively related to RV mass-to-volume ratio which suggested myocyte loss. In the present animal data, the RV mass-to-volume ratio did indeed decrease after PR and increased again once PVR was performed. The decreased mass-to-volume ratio has been identified as a marker of failed compensatory eccentric hypertrophy to maintain normal wall stress.(64) The group of Tal Geva speculated that in patients with TOF with RV volume overload an increased ECV with decreased mass-to-volume ratio correlates with a maladaptive process characterized by diffuse fibrosis and loss of cardiomyocytes.(64) The findings of this study support this speculation - decreased mass-to-volume ratio on CMR after PR with increased activated fibroblasts and increased cross-linked collagen was observed. As stated by the group of Tal Geva myocardial fibrosis is a key element of the maladaptive response to chronic hemodynamic overload and its onset precedes ventricular dysfunction.(64) The progressive diastolic dysfunction and dyskinesia due to surgical scars together with the volume overload can lead to RV failure and LV failure as a result of the interventricular interdependence.(65,66)

The life expectancy of TOF patients remains lower than that of the general population mainly due to premature sudden cardiac death.(14,30,67–69) Chronic RV volume overload due to PR together with changes in the conduction system and slow conducting isthmuses can cause malignant arrhythmias.(7,8,30,70–75) Autopsy studies in patients with TOF with SCD revealed an undamaged conduction system and showed extensive fibrosis of the right ventricle at the site of the surgical scars and in the septum.(7,76) The observed fibrotic changes in our data cannot be attributed to surgical scar tissue. In a study from Toronto in adult patients with TOF undergoing surgical PVR severe fibrosis was observed and was associated with increased RV mass and increased RVESVi.(77) The indication for PVR in this study was in 92% of the cases PR. Kido *et al* showed myocardial fibrosis in adult TOF patients at time of PVR, in the majority of patients RVOT stenosis was the indication for PVR.(78,79) In a mouse model with chronic RV volume overload, increased subendocardial fibrosis was observed with downregulation of TGF-β and increased transcription of matricellular proteins, was demonstrated.(80)

The observation that PVR decreases fibrotic alterations by restoring RV volume is something new. Unloading of the LV with a left ventricular assist device (LVAD) in end stage heart failure did not demonstrate changes in fibrosis or myofibroblast density compared to loaded hearts.(81) The data obtained might suggest reversibility of the fibrotic process in the RV and needs further investigation.

Serial histologic analysis would have been interesting but was not feasible as full thickness myocardium was needed (sacrifice).

The animal data do not prove that the burden of arrhythmia can be reduced by performing PVR. Malignant arrhythmia or SCD was not observed in these animals apart from a low threshold to develop ventricular fibrillation (VF) upon advancing large sheaths into the RVOT at the time of bare stent implantation. No electrophysiological study or programmed electrical stimulation was performed in the current study.
In a porcine model with PR and PS slow and discontinuous conduction was shown which predispose for re-entry arrhythmias.(36) Zeltser *et al* created different groups (PS, PR, PS+PR and infundibular scar) in pigs.(42) Programmed electrical stimulation was done 5.6 months after surgery. Atrial arrhythmias could be induced in 33.3% and VT in 31.1%. The PR group was 30 times more likely to develop arrhythmias compared to healthy animals. RV failure was also not observed in the studied animals.

The most recent ESC and AHA/ACC recommendations on PVR in repaired TOF patients state that PVR is recommended in symptomatic patients with severe PR and/or moderate RVOTO.(16,17) In asymptomatic patients with severe PR and/or RVOTO PVR should be considered when either a decrease in exercise capacity is present, or RVEDVi≥160ml/m² and/or RVESVi ≥80 ml/m², or progressive RV systolic dysfunction is present. When the pre-operative RV dimensions exceeded RVEDVi > 170 ml/m² and RVESVi > 85 ml/m² no RV reverse remodeling was seen on CMR.(6) A meta-analysis of PVR in repaired TOF demonstrated that PVR led to improvement in RV and LV function and volume, decrease in QRS duration and improvement of symptoms.(82) PVR has not been proven to alter the risk for VT or ventricular failure, despite the RV reverse remodeling.(2,3,6,18,31,83–87)

The optimal timing of PVR remains uncertain. It is a difficult balance between performing PVR before irreversible RV dysfunction sets in and the disadvantage of graft failure and need for (multiple) re-interventions as a result of earlier PVR.(2) Currently available conduits for PVR have a the limited longevity; thus, the earlier PVR is performed the more redo-PVR will be required over a lifetime.(88)
The data showed that RV volume overload resulted in active fibrotic changes and following PVR some changes were less pronounced. The decrease was more pronounced after early valve replacement compared to late. The fact that PVR led to reduced fibrotic changes does raise the question whether the fibrotic process might be at least partially reversible after unloading the dilated RV. Further investigation is needed.

Limitations

Firstly, the presented animal model did not show deficient RV reverse remodeling, RV failure or malignant arrhythmias. A more chronic follow-up of animals with severe PR might be of interest. The model shares pathophysiological changes as TOF patients, but fails to address some issues.

The model lacks chronic hypoxia as seen in TOF patients before surgical repair. The pulmonary stenosis was rather mild and not yet present in utero as in patients with TOF.

This trial was performed in growing animals (ovine); translating this data to the human situation is difficult and imply the need to make some assumptions. With regards to the timeline the paper of Wang *et al* helps to correlate human and animal age, but as it relates to dogs it still requires extrapolation with some assumptions.(56)

In the CMR analysis no Late Gadolinium Enhancement (LGE) or T1 mapping was performed. LGE on the RV free wall was not performed as there is no scar tissue (no surgical scar) to be expected in this particular model. T1-mapping technology was not available in the CMR facility in the animal lab at the time of the trial.

Our data showed a decrease in fibrotic changes after PVR. To address the question of reversibility of fibrosis, serial histological analysis throughout the trial could have given more insight. It was, however, not feasible to collect serial histological data as full thickness myocardium requires sacrificing the animals. The model lacks chronic hypoxia as seen in TOF patients.

As mentioned in the discussion, the difference between both PVR groups regarding reverse remodeling disappeared 5 months following PVR. It might be of interest to add more groups in which PVR is performed at later stage (e.g. after 20 months PR) and following animals with chronic PR without PVR until SCD, RV dysfunction or failure occurs. This might delineate a point of no recovery in terms of no reverse remodeling and irreversible fibrosis. Further investigation is needed.

5.6 Conclusion

This ovine model shows pathophysiological changes comparable to the late postoperative course in patients with TOF. Severe PR leads to RV volume overload. Early valve replacement shows a higher rate of RV reverse remodeling shortly following PVR, but after 5 months no difference in RV dimensions between early and late valve replacement were still present. The severe PR with chronic RV volume overload induces fibrosis with increased percentage of cross-linked collagen and expression of α-SMA. After PVR a lower percentage of cross-linked collagen and lower expression of α-SMA is observed and is most pronounced after early valve replacement.

Grants and support

This trial was made possible by a research grant from the Foundation of Cardiac Surgery Research Belgium, Medtronic and the Henri and Mariëtte Mertens-Berx Foundation. The Melody™ valves and Ensembles™ were delivered by Medtronic. A part of the used CP-stents™ and BIB™ balloons were provided by Numed.

Disclosures**:** Marc Gewillig is proctor for Medtronic, Numed and Edwards.

REFERENCES

1. Kirklin JW., Blackstone EH., Jonas RA., et al. Morphologic and surgical determinants of outcome events after repair of tetralogy of Fallot and pulmonary stenosis: A two-institution study. Journal of Thoracic and Cardiovascular Surgery. 1992.
2. Geva T. Indications and Timing of Pulmonary Valve Replacement After Tetralogy of Fallot Repair. Pediatr Card Surg Annu 2006. Doi: 10.1053/j.pcsu.2006.02.009.
3. Kogon BE., Rosenblum JM., Mori M. Current Readings: Issues Surrounding Pulmonary Valve Replacement in Repaired Tetralogy of Fallot. Semin Thorac Cardiovasc Surg 2015. Doi: 10.1053/j.semtcvs.2015.02.010.
4. Alvarez-Fuente M., Garrido-Lestache E., Fernandez-Pineda L., et al. Timing of Pulmonary Valve Replacement: How Much Can the Right Ventricle Dilate Before it Looses Its Remodeling Potential? Pediatr Cardiol 2016. Doi: 10.1007/s00246-015-1320-4.
5. Knauth AL., Gauvreau K., Powell AJ., et al. Ventricular size and function assessed by cardiac MRI predict major adverse clinical outcomes late after tetralogy of Fallot repair. Heart 2008. Doi: 10.1136/hrt.2006.104745.
6. Therrien J., Provost Y., Merchant N., Williams W., Colman J., Webb G. Optimal timing for pulmonary valve replacement in adults after tetralogy of Fallot repair. Am J Cardiol 2005. Doi: 10.1016/j.amjcard.2004.11.037.
7. Maury P., Sacher F., Rollin A., et al. Ventricular arrhythmias and sudden death in tetralogy of Fallot. Arch Cardiovasc Dis 2017. Doi: 10.1016/j.acvd.2016.12.006.
8. Cheung MMH., Konstantinov IE., Redington AN. Late complications of repair of tetralogy of fallot and indications for pulmonary valve replacement. Semin Thorac Cardiovasc Surg 2005. Doi: 10.1053/j.semtcvs.2005.02.006.
9. Kirklin JK., Kirklin JW., Blackstone EH., Milano A., Pacifico AD. Effect of transannular patching on outcome after repair of tetralogy of Fallot. Ann Thorac Surg 1989. Doi: 10.1016/0003-4975(89)90671-1.
10. Abbas JR., Hoschtitzky JA. Which is the best tissue valve used in the pulmonary position, late after previous repair of tetralogy of Fallot? Interact Cardiovasc Thorac Surg 2013. Doi: 10.1093/icvts/ivt332.
11. Bibevski S., Ruzmetov M., Fortuna RS., Turrentine MW., Brown JW., Ohye RG. Performance of SynerGraft Decellularized Pulmonary Allografts Compared With Standard Cryopreserved Allografts: Results From Multiinstitutional Data. Ann Thorac Surg 2017. Doi: 10.1016/j.athoracsur.2016.07.068.
12. Pardo González L., Ruiz Ortiz M., Delgado M., et al. Pulmonary homograft stenosis in the Ross procedure: Incidence, clinical impact and predictors in long-term follow-up. Arch Cardiovasc Dis 2017. Doi: 10.1016/j.acvd.2016.09.008.
13. Yong MS., Yim D., d'Udekem Y., et al. Medium-term outcomes of bovine jugular vein graft and homograft conduits in children. ANZ J Surg 2015. Doi: 10.1111/ans.13018.
14. Warnes CA., Williams RG., Bashore TM., et al. ACC/AHA 2008 Guidelines for the Management of Adults With Congenital Heart Disease. J Am Coll Cardiol 2008. Doi:

10.1016/j.jacc.2008.10.002.
15. Warnes CA. Adult Congenital Heart Disease. Importance of the Right Ventricle. J Am Coll Cardiol 2009. Doi: 10.1016/j.jacc.2009.06.048.
16. Baumgartner H., De Backer J., Babu-Narayan S V., et al. 2020 ESC Guidelines for the management of adult congenital heart disease. Eur Heart J 2020. Doi: 10.1093/eurheartj/ehaa554.
17. Stout KK., Daniels CJ., Aboulhosn JA., et al. 2018 AHA/ACC Guideline for the Management of Adults With Congenital Heart Disease: A Report of the American College of Cardiology/American Heart Association Task Force on Clinical Practice Guidelines. Circulation 2019. Doi: 10.1161/CIR.0000000000000603.
18. Fuller S. Tetralogy of fallot and pulmonary valve replacement: Timing and techniques in the asymptomatic patient. Semin Thorac Cardiovasc Surg Pediatr Card Surg Annu 2014. Doi: 10.1053/j.pcsu.2014.01.012.
19. Bacha E. Valve-Sparing Options in Tetralogy of Fallot Surgery. Semin Thorac Cardiovasc Surg Pediatr Card Surg Annu 2012. Doi: 10.1053/j.pcsu.2012.01.006.
20. Bacha E. Valve-Sparing or Valve Reconstruction Options in Tetralogy of Fallot Surgery. Semin Thorac Cardiovasc Surg Pediatr Card Surg Annu 2017. Doi: 10.1053/j.pcsu.2016.09.001.
21. Robinson JD., Rathod RH., Brown DW., et al. The evolving role of intraoperative balloon pulmonary valvuloplasty in valve-sparing repair of tetralogy of Fallot. J Thorac Cardiovasc Surg 2011. Doi: 10.1016/j.jtcvs.2011.02.047.
22. Cools B., Budts W., Heying R., et al. Medium term follow-up after percutaneous pulmonary valve replacement with the Melody® valve. IJC Hear Vasc 2015;7. Doi: 10.1016/j.ijcha.2015.02.014.
23. McElhinney DB., Hellenbrand WE., Zahn EM., et al. Short-and medium-term outcomes after transcatheter pulmonary valve placement in the expanded multicenter US melody valve trial. Circulation 2010. Doi: 10.1161/CIRCULATIONAHA.109.921692.
24. Pondorfer P., Yun T-J., Cheung M., et al. Tetralogy of Fallot Repair — Long Term Follow-up: Preservation Strategy Improves Late Outcomes. Thorac Cardiovasc Surg 2016. Doi: 10.1055/s-0036-1571561.
25. Cools B., Brown SC., Heying R., et al. Percutaneous pulmonary valve implantation for free pulmonary regurgitation following conduit-free surgery of the right ventricular outflow tract. Int J Cardiol 2015;186. Doi: 10.1016/j.ijcard.2015.03.108.
26. Boshoff DE., Cools BLM., Heying R., et al. Off-label use of percutaneous pulmonary valved stents in the right ventricular outflow tract: Time to rewrite the label? Catheter Cardiovasc Interv 2013;81(6). Doi: 10.1002/ccd.24594.
27. Bonhoeffer P., Boudjemline Y., Saliba Z., et al. Transcatheter implantation of a bovine valve in pulmonary position: A lamb study. Circulation 2000. Doi: 10.1161/01.CIR.102.7.813.
28. Boudjemline Y., Bonhoeffer P. The percutaneous implantable heart valve. Prog Pediatr Cardiol 2001. Doi: 10.1016/S1058-9813(01)00124-2.
29. Bonhoeffer P., Boudjemline Y., Qureshi SA., et al. Percutaneous insertion of the pulmonary valve. J Am Coll Cardiol 2002. Doi: 10.1016/S0735-1097(02)01822-3.
30. Geva T. Indications for pulmonary valve replacement in repaired tetralogy of fallot: The quest continues. Circulation 2013. Doi: 10.1161/CIRCULATIONAHA.113.005878.
31. Villafañe J., Feinstein JA., Jenkins KJ., et al. Hot topics in tetralogy of fallot. J Am Coll Cardiol 2013. Doi: 10.1016/j.jacc.2013.07.100.
32. Robb JD., Harris MA., Minakawa M., et al. An ovine model of pulmonary insufficiency and right ventricular outflow tract dilatation. J Heart Valve Dis 2012.
33. Agger P., Hyldebrandt JA., Nielsen EA., Hjortdal V., Smerup M. A novel porcine model for right ventricular dilatation by external suture plication of the pulmonary valve leaflets – practical and reproducible☆. Interact Cardiovasc Thorac Surg 2010. Doi: 10.1510/icvts.2009.227264.
34. Valdeomillos E., Jalal Z., Metras A., et al. Animal Models of Repaired Tetralogy of Fallot: Current Applications and Future Perspectives. Can J Cardiol 2019. Doi:

10.1016/j.cjca.2019.07.622.
35. Lambert V., Capderou A., Le Bret E., et al. Right ventricular failure secondary to chronic overload in congenital heart disease: An experimental model for therapeutic innovation. J Thorac Cardiovasc Surg 2010. Doi: 10.1016/j.jtcvs.2009.11.028.
36. Benoist D., Dubes V., Roubertie F., et al. Proarrhythmic remodelling of the right ventricle in a porcine model of repaired tetralogy of Fallot. Heart 2017. Doi: 10.1136/heartjnl-2016-309730.
37. Ersboell M., Vejlstrup N., Nilsson JC., et al. Percutaneous pulmonary valve replacement after different duration of free pulmonary regurgitation in a porcine model: Effects on the right ventricle. Int J Cardiol 2013. Doi: 10.1016/j.ijcard.2012.08.012.
38. Godart F., Bouzguenda I., Juthier F., et al. Experimental off-pump transventricular pulmonary valve replacement using a self-expandable valved stent: A new approach for pulmonary incompetence after repaired tetralogy of Fallot? J Thorac Cardiovasc Surg 2009. Doi: 10.1016/j.jtcvs.2008.07.057.
39. Yerebakan C., Klopsch C., Prietz S., et al. Pressure-volume loops: feasible for the evaluation of right ventricular function in an experimental model of acute pulmonary regurgitation? Interact Cardiovasc Thorac Surg 2009. Doi: 10.1510/icvts.2008.198275.
40. Ko Y., Morita K., Abe T., Nakao M., Hashimoto K. Variability of Pulmonary Regurgitation in Proportion to Pulmonary Vascular Resistance in a Porcine Model of Total Resection of the Pulmonary Valve: Implications for Early- and Long-Term Postoperative Management of Right Ventricular Outflow Tract Reconstru. World J Pediatr Congenit Heart Surg 2015. Doi: 10.1177/2150135115598209.
41. Gray R., Greve G., Chen R., et al. Right ventricular myocardial responses to chronic pulmonary regurgitation in lambs: Disturbances of activation and conduction. Pediatr Res 2003. Doi: 10.1203/01.PDR.0000084829.67270.FA.
42. Zeltser I., Gaynor JW., Petko M., et al. The roles of chronic pressure and volume overload states in induction of arrhythmias: An animal model of physiologic sequelae after repair of tetralogy of Fallot. J Thorac Cardiovasc Surg 2005. Doi: 10.1016/j.jtcvs.2005.08.034.
43. Bove T., Vandekerckhove K., Bouchez S., Wouters P., Somers P., Van Nooten G. Role of myocardial hypertrophy on acute and chronic right ventricular performance in relation to chronic volume overload in a porcine model: Relevance for the surgical management of tetralogy of Fallot. J Thorac Cardiovasc Surg 2014. Doi: 10.1016/j.jtcvs.2013.10.026.
44. Kuehne T., Saeed M., Reddy G., et al. Sequential magnetic resonance monitoring of pulmonary flow with endovascular stents placed across the pulmonary valve in growing swine. Circulation 2001. Doi: 10.1161/hc4401.098472.
45. Thambo JB., Roubertie F., De Guillebon M., et al. Validation of an animal model of right ventricular dysfunction and right bundle branch block to create close physiology to postoperative tetralogy of Fallot. Int J Cardiol 2012. Doi: 10.1016/j.ijcard.2010.08.063.
46. Smith J., Goetze JP., Søndergaard L., et al. Myocardial hypertrophy after pulmonary regurgitation and valve implantation in pigs. Int J Cardiol 2012. Doi: 10.1016/j.ijcard.2011.02.022.
47. Schoonbeek RC., Takebayashi S., Aoki C., et al. Implantation of the Medtronic Harmony Transcatheter Pulmonary Valve Improves Right Ventricular Size and Function in an Ovine Model of Postoperative Chronic Pulmonary Insufficiency. Circ Cardiovasc Interv 2016. Doi: 10.1161/CIRCINTERVENTIONS.116.003920.
48. Van Der Ven JPG., Sadighy Z., Valsangiacomo Buechel ER., et al. Multicentre reference values for cardiac magnetic resonance imaging derived ventricular size and function for children aged 0-18 years. Eur Heart J Cardiovasc Imaging 2020. Doi: 10.1093/ehjci/jez164.
49. Grothues F., Moon JC., Bellenger NG., Smith GS., Klein HU., Pennell DJ. Interstudy reproducibility of right ventricular volumes, function, and mass with cardiovascular magnetic resonance. Am Heart J 2004. Doi: 10.1016/j.ahj.2003.10.005.
50. Berman A. Effects of body surface area estimates on predicted energy requirements and heat stress. J Dairy Sci 2003. Doi: 10.3168/jds.S0022-0302(03)73966-6.

51. Nagaraju CK., Dries E., Popovic N., et al. Global fibroblast activation throughout the left ventricle but localized fibrosis after myocardial infarction. Sci Rep 2017;7(1):10801. Doi: 10.1038/s41598-017-09790-1.
52. Geens JH., Jacobs S., Claus P., et al. Partial mechanical circulatory support in an ovine model of post-infarction remodeling. J Heart Lung Transplant 2013;32(8):815–22. Doi: 10.1016/j.healun.2013.05.019.
53. Nagaraju CK., Robinson EL., Abdesselem M., et al. Myofibroblast Phenotype and Reversibility of Fibrosis in Patients With End-Stage Heart Failure. J Am Coll Cardiol 2019;73(18):2267–82. Doi: 10.1016/j.jacc.2019.02.049.
54. A. F., P. A., S. M-M., et al. Melody® transcatheter pulmonary valve implantation: Results from a French registry. Arch Cardiovasc Dis 2014. Doi: 10.1016/j.acvd.2014.10.001 LK - http://sfx.library.uu.nl/utrecht?sid=EMBASE&issn=18752128&id=doi:10.1016%2Fj.acvd.2014.10.001&atitle=Melody%C2%AE+transcatheter+pulmonary+valve+implantation%3A+Results+from+a+French+registry&stitle=Arch.+Cardiovasc.+Dis.&title=Archives+of+Cardiovascular+Diseases&volume=107&issue=11&spage=607&epage=614&aulast=Fraisse&aufirst=Alain&auinit=A.&aufull=Fraisse+A.&coden=&isbn=&pages=607-614&date=2014&auinit1=A&auinitm=.
55. Kjaergaard J., Iversen KK., Vejlstrup NG., et al. Effects of chronic severe pulmonary regurgitation and percutaneous valve repair on right ventricular geometry and contractility assessed by tissue doppler echocardiography. Echocardiography 2010. Doi: 10.1111/j.1540-8175.2010.01153.x.
56. Wang T., Ma J., Hogan AN., et al. Quantitative translation of dog-to-human aging by conserved remodeling of epigenetic networks. BioRxiv 2019. Doi: 10.1101/829192.
57. Heng EL., Gatzoulis MA., Uebing A., et al. Immediate and midterm cardiac remodeling after surgical pulmonary valve replacement in adults with repaired tetralogy of fallot: A prospective cardiovascular magnetic resonance and clinical study. Circulation 2017. Doi: 10.1161/CIRCULATIONAHA.117.027402.
58. Shinde A V., Humeres C., Frangogiannis NG. The role of α-smooth muscle actin in fibroblast-mediated matrix contraction and remodeling. Biochim Biophys Acta - Mol Basis Dis 2017. Doi: 10.1016/j.bbadis.2016.11.006.
59. Ghorbel MT., Cherif M., Jenkins E., et al. Transcriptomic analysis of patients with tetralogy of Fallot reveals the effect of chronic hypoxia on myocardial gene expression. J Thorac Cardiovasc Surg 2010. Doi: 10.1016/j.jtcvs.2009.12.055.
60. Frangogiannis NG. Fibroblasts and the extracellular matrix in right ventricular disease. Cardiovasc Res 2017. Doi: 10.1093/cvr/cvx146.
61. Babu-Narayan S V., Kilner PJ., Li W., et al. Ventricular fibrosis suggested by cardiovascular magnetic resonance in adults with repaired tetralogy of Fallot and its relationship to adverse markers of clinical outcome. Circulation 2006. Doi: 10.1161/CIRCULATIONAHA.105.548727.
62. Baicu CF., Li J., Zhang Y., et al. Time course of right ventricular pressure-overload induced myocardial fibrosis: Relationship to changes in fibroblast postsynthetic procollagen processing. Am J Physiol - Hear Circ Physiol 2012. Doi: 10.1152/ajpheart.00482.2012.
63. Kozak MF., Redington A., Yoo SJ., Seed M., Greiser A., Grosse-Wortmann L. Diffuse myocardial fibrosis following tetralogy of Fallot repair: A T1 mapping cardiac magnetic resonance study. Pediatr Radiol 2014. Doi: 10.1007/s00247-013-2840-9.
64. Chen CA., Dusenbery SM., Valente AM., Powell AJ., Geva T. Myocardial ECV Fraction Assessed by CMR Is Associated with Type of Hemodynamic Load and Arrhythmia in Repaired Tetralogy of Fallot. JACC Cardiovasc Imaging 2016. Doi: 10.1016/j.jcmg.2015.09.011.
65. Broberg CS., Aboulhosn J., Mongeon FP., et al. Prevalence of left ventricular systolic dysfunction in adults with repaired tetralogy of fallot. Am J Cardiol 2011. Doi: 10.1016/j.amjcard.2010.12.026.
66. Ait Ali L., Trocchio GL., Crepaz R., et al. Left ventricular dysfunction in repaired tetralogy of Fallot: incidence and impact on atrial arrhythmias at long term-follow up. Int J Cardiovasc Imaging 2016. Doi: 10.1007/s10554-016-0928-7.

67. Baumgartner H., Bonhoeffer P., De Groot NMS., et al. ESC Guidelines for the management of grown-up congenital heart disease (new version 2010): The Task Force on the Management of Grown-up Congenital Heart Disease of the European Society of Cardiology (ESC). Eur Heart J 2010. Doi: 10.1093/eurheartj/ehq249.
68. Quail MA., Frigiola A., Giardini A., et al. Impact of pulmonary valve replacement in tetralogy of fallot with pulmonary regurgitation: A comparison of intervention and nonintervention. Ann Thorac Surg 2012. Doi: 10.1016/j.athoracsur.2012.06.062.
69. Frigiola A., Giamberti A., Chessa M., et al. Right ventricular restoration during pulmonary valve implantation in adults with congenital heart disease. Eur J Cardio-Thoracic Surg 2006. Doi: 10.1016/j.ejcts.2006.03.007.
70. Gatzoulis MA., Balaji S., Webber SA., et al. Risk factors for arrhythmia and sudden cardiac death late after repair of tetralogy of Fallot: A multicentre study. Lancet 2000. Doi: 10.1016/S0140-6736(00)02714-8.
71. Cuypers JAAE., Menting ME., Konings EEM., et al. Unnatural history of tetralogy of fallot: Prospective follow-up of 40 years after surgical correction. Circulation 2014. Doi: 10.1161/CIRCULATIONAHA.114.009454.
72. Geva T., Mulder B., Gauvreau K., et al. Preoperative predictors of death and sustained ventricular tachycardia after pulmonary valve replacement in patients with repaired tetralogy of Fallot enrolled in the indicator cohort. Circulation 2018. Doi: 10.1161/CIRCULATIONAHA.118.034740.
73. Kapel GFL., Laranjo S., Blom NA., et al. Impact of surgery on presence and dimensions of anatomical isthmuses in tetralogy of Fallot. Heart 2018. Doi: 10.1136/heartjnl-2017-312452.
74. Kapel GFL., Sacher F., Dekkers OM., et al. Arrhythmogenic anatomical isthmuses identified by electroanatomical mapping are the substrate for ventricular tachycardia in repaired Tetralogy of Fallot. Eur Heart J 2017. Doi: 10.1093/eurheartj/ehw202.
75. Probst J., Diller G-P., Reinecke H., et al. Prevention of sudden cardiac death in patients with Tetralogy of Fallot: Risk assessment and long term outcome. Int J Cardiol 2018;269:91–6. Doi: 10.1016/J.IJCARD.2018.06.107.
76. Deanfield JE., Ho SY., Anderson RH., McKenna WJ., Allwork SP., Hallidie-Smith KA. Late sudden death after repair of tetralogy of Fallot: A clinicopathologic study. Circulation 1983. Doi: 10.1161/01.CIR.67.3.626.
77. Yamamura K., Yuen D., Hickey EJ., et al. Right ventricular fibrosis is associated with cardiac remodelling after pulmonary valve replacement. Heart 2019. Doi: 10.1136/heartjnl-2018-313961.
78. Kido T., Ueno T., Taira M., et al. Clinical predictors of right ventricular myocardial fibrosis in patients with repaired tetralogy of fallot. Circ J 2018. Doi: 10.1253/circj.CJ-17-1088.
79. Kido T., Ueno T., Taira M., et al. Stroke Volume Ratio Predicts Redilatation of the Right Ventricle After Pulmonary Valve Replacement. Ann Thorac Surg 2017. Doi: 10.1016/j.athoracsur.2016.12.045.
80. Reddy S., Zhao M., Hu DQ., et al. Physiologic and molecular characterization of a murine model of right ventricular volume overload. Am J Physiol - Hear Circ Physiol 2013. Doi: 10.1152/ajpheart.00776.2012.
81. Farris SD., Don C., Helterline D., et al. Cell-Specific Pathways Supporting Persistent Fibrosis in Heart Failure. J Am Coll Cardiol 2017. Doi: 10.1016/j.jacc.2017.05.040.
82. Ferraz Cavalcanti PE., Sá MPBO., Santos CA., et al. Pulmonary valve replacement after operative repair of Tetralogy of Fallot: Meta-analysis and meta-regression of 3,118 patients from 48 studies. J Am Coll Cardiol 2013. Doi: 10.1016/j.jacc.2013.04.107.
83. van der Ven JPG., van den Bosch E., Bogers AJCC., Helbing WA. Current outcomes and treatment of tetralogy of Fallot. F1000Research 2019. Doi: 10.12688/f1000research.17174.1.
84. Tretter JT., Friedberg MK., Wald RM., McElhinney DB. Defining and refining indications for transcatheter pulmonary valve replacement in patients with repaired tetralogy of Fallot: Contributions from anatomical and functional imaging. Int J Cardiol 2016. Doi:

10.1016/j.ijcard.2016.07.120.
85. O'Byrne ML., Glatz AC., Mercer-Rosa L., et al. Trends in pulmonary valve replacement in children and adults with tetralogy of Fallot. Am J Cardiol 2015. Doi: 10.1016/j.amjcard.2014.09.054.
86. Pagourelias ED., Daraban AM., Mada RO., et al. Right ventricular remodelling after transcatheter pulmonary valve implantation. Catheter Cardiovasc Interv 2017;90(3). Doi: 10.1002/ccd.26966.
87. Therrien J., Siu S., Harris L. Impact of pulmonary valve replacement on arrhythmia propensity late after repair of tetralogy of fallot. ACC Curr J Rev 2001. Doi: 10.1016/s1062-1458(01)00508-6.
88. Dobbels B., Herregods MC., Troost E., et al. Early versus late pulmonary valve replacement in patients with transannular patch-repaired tetralogy of Fallot. Interact Cardiovasc Thorac Surg 2017. Doi: 10.1093/icvts/ivx118.

GENERAL DISCUSSION

GENERAL DISCUSSION

Background

Despite several advances in interventional strategies during the past decades, the life expectancy of patients with TOF remains lower compared to that of the general population.(12) The initial strategy in the 60s' was focused on relieving the RVOTO at the cost of creating PR.(132,133) At that time, the PR was considered to be well tolerated. However, chronic PR appeared not to be a benign lesion after all.(134) Patients with significant PR presented with episodes of ventricular tachycardia and sudden death during the 3rd and 4th decade of life.(4) On the longer term right and even left ventricular failure can develop.(40,49,54,74,89,135,136) One of the major determinants of progressive RV failure is the chronic volume overload.(40,46,134) Therefore patients with TOF require pulmonary valve replacement (PVR). In symptomatic, repaired TOF patients limited RV reversed remodeling was observed with persistence of mechanical dysfunction and electrical instability.(41,47,137,138) PVR needed to be performed before irreversible RV dysfunction ensues.(134) This resulted in the consideration to intervene earlier in the life of the TOF patient. However, the available conduits had limited longevity, and earlier PVR resulted in the need for more re-interventions.(90–92)

Recommendations for timing of PVR in repaired TOF patients have been established using a combination of clinical data, CMR and exercise capacity data.(3,72,74,77) However, it has not been unequivocally proven to date that PVR improves the life expectancy by altering the risk of SCD and RV failure.(55) Thus, the optimal timing of PVR remains unclear and contentious.

Until the year 2000 PVR could only be performed surgically. Following the development of a bovine valved stent for percutaneous pulmonary valve replacement, a new era in the treatment options for congenital heart disease has been initiated.(106,107) In 2006 selected centers started the first percutaneous implants and since 2010 this technique became widely available.

1. Feasibility of percutaneous pulmonary valve implantation. The durability of implanted valves and the morbidity and mortality of the technique

A single center non-randomized (ongoing) prospective observational study of all performed PPVRs with the Melody™ valve (Medtronic Inc., Minneapolis, MN, USA) was performed. The data of all percutaneous implanted valves between 2006 and 2017 were evaluated.

The follow-up data showed up to 11 years of a good graft survival. Leaflet function of the valve was well preserved as demonstrated by the absence of significant gradient across the RVOT and/or PR. Overall freedom from conduit dysfunction was 78% after 10 years which compares favorably to similar

studies of surgical conduits.(94,139,140) Decellularized conduits appear to perform better than the standard allografts with a freedom from dysfunction at 10 years of 83% compared to 58 % for the standard allografts.(141)

The most common reason for graft failure was the result of endocarditis.(114,115,142,143) In less than half of the IE cases redo-valve replacement was required, which has also been described in other reports.(111) The study was not powered to identify specific risk factors for IE; in this series the majority of the IE cases were observed in male adolescents. It has not been proven that antiplatelet therapy in order to prevent formation of micro-thrombi prevents IE.(143–145)

Stent fractures are a major threat to the valve and can lead to early valve dysfunction. Adequate pre-stenting of the RVOT has been demonstrated to be a crucial factor to avoid device failure both in the published European and the US experiences.(113,118,146) In our series stent fractures with hemodynamic consequences were exceptional most likely due to the fact that we adopted an aggressive approach to ensure adequate pre-stenting and subsequently fractures occurred much less than in most reports.(113,118,146) This data however, did not beyond any doubt prove that stent-in-stent combinations decrease the strain amplitude and metal fatigue, thereby avoiding or delaying stent fractures.

2. Feasibility and safety of pre-stenting followed by percutaneous pulmonary valve implantation in patients with TOF with dilated RVOT and severe PR

The PPVR technique being minimally invasive, short recovery periods and well preserved leaflet function in the medium term became an appealing strategy for patients with repaired TOF.(110) The RVOT can become dilated after transannular patch which makes stent deployment and PPVR less likely. In a group of 23 patients with a dilated conduit free right ventricular outflow tract, this PPVR technique was evaluated. PPVR in these conduit free right ventricle outflow tracts was shown to be feasible and safe. Ninety six percent of stents were safely implanted which is in agreement with other reports.(121,147) Balloon-interrogation of the landing zone is a crucial element to define the underlying anatomy, determine suitability for PPVR and predict valve/stent diameters. Stents with hybrid open cell design increased apposition to the vessel wall following deployment.

Coronary compression was not observed in this series probably as a result of symmetrical expansion of the conduit in all directions in contrast to a calcified conduit where expansion tends to be asymmetrical.(148) During short-term follow-up of up to 24 months, right ventricular dimensions improved in all patients demonstrated by means of CMR. Exercise ability also improved during the short-term follow-up. There were no stent fractures or stent compressions which is an important consideration for the longevity and long-term function of stented valves. The stent in the RVOT will fix

the diameter and prevent further dilation of the specific zone. The applicability of the PPVR technique in patients with repaired TOF increases the treatment options.

3.1 Resistance to deformation of stent and combination of stents

Stent fractures following PPVR can lead to hemodynamic impairment ranging from mild to severe with or without valve dysfunction.(112,113,118–120) The risk of deformation and compression of the stented valve was proven to be lower in a protected right ventricular outflow tract.(149,150)

The study evaluated resistance to deformation of combinations of stents by means of bench testing using mechanical forces to compress the stents. A single CP-stent™ was more resistant to deformation when compared to the Optimus™, AndraStent® or IntraStent™. Deformation resistance was significantly augmented by adding one or more combination of stents to a single stent. The metal fatigue endurance curves of stent metals showed that higher stiffness leads to a lower strain amplitude which results in a longer lifetime or higher number of cycles to failure (Basquin or Wohler law).(151) The bench testing proved that lowering the strain amplitude by multiple pre-stenting adds more stiffness and therefore lowers the risk of deformation and ultimately fracture. Increasing the "roundness" of the wall improves resistance to fracture and improved valve function.(152) Laser cut hydrid open cell design stents such as the. AndraStent® had more friction and retention compared to a closed cell design stent and are therefore preferred in a compliant conduit free outflow tract. The CP-stent™(platinum-iridium) was thicker than the laser cut stents which meant that combinations of multiple CP-stents™ would reduce the inner diameter more than combinations of the cobalt-chromium stents. The CP-stent™ was due to its resistance to deformation more suitable for stenotic conduits.

3.2 Stent corrosion

Galvanic currents may develop when different metals are in close contact and can lead to corrosion. Corrosion tests were performed using combinations of stents. The CP-stent™ was composed of the noblest material. When the different stent alloys come into direct contact with one another, the least noble metal undergoes an anodic corrosion reaction, whilst the more noble metal will not corrode since electrons are bound tightly together. The corrosion rate and material loss of all tested stent compounds were very low. Thus, no mechanical integrity problems are expected as a result of corrosion since there was only 0.3% of the initial diameter of the wires of a stent that will be lost as a consequence of corrosion after 100 years. The corrosion rate decreased even after 4 weeks which can be attributed to the development of an oxide film on the stents' surface.(153) Therefore, no biological effect can be expected on the organism with such metal ions being released into the tissues (e.g. safe dose for Cobalt < 7ppb). Even the combination of materials with the highest driving force for galvanic corrosion will result in minimal material loss which is less than 0.5 parts per billion (ppb).

4. The creation of animal model with pulmonary valve regurgitation and RV volume overload

A growing animal (ovine) model with severe pulmonary regurgitation simulating the pathophysiological changes that occur in patients with tetralogy of Fallot was created. Different animal models have already been developed: some used a transannular patch, others an external plication of the pulmonary valve leaflets or a bare metal stent placed across the pulmonary valve.(64,128,154–160) The aim was to compare 2 historically different types of animal model in which pulmonary regurgitation was created. In the first model PR was created at lamb stage by resecting at least 2 pulmonary valve leaflets together with a PA banding fixed at 22 mm of diameter. In the second model a tighter PA banding was created in lambs. In a later stage the banding was relieved and the valve was stented creating PR. Stenting the PV resulted in reproducible and more pronounced PR and RV dilatation compared to surgical leaflet resection. Most complications were observed in the stent model. The model with initial mild PS and secondary stent giving severe PR and leading to RV volume overload, correlated well with the pathophysiology of tetralogy of Fallot. The model can be used to evaluate RV remodeling and reverse remodeling following PVR at different time intervals.

5. Right ventricular remodeling and reverse remodeling after pulmonary valve replacement in an ovine TOF model.

The animal model with stenting of the PV was used to evaluate RV remodeling as a result of severe PR and the reverse remodeling after pulmonary valve replacement at different time intervals. The studied animals developed severe pulmonary valve regurgitation leading to important right ventricular volume overload. PVR was performed at 2 different time intervals (after 5 and 10 months of PR). PVR resulted in reverse remodeling in both PVR groups, but the process of reverse remodeling progressed at a significantly higher rate after early valve replacement compared to the late valve replacement with a more delayed reverse remodeling. Despite this observation the difference in RV dimensions between both PVR groups disappeared in the following 5 months after PVR. The chronic volume overloaded RV (PR group) showed significantly more activated fibroblasts (myofibroblasts) reflected by a higher expression of the alpha-smooth muscle cell actin (α-SMA) and more fibrosis in the RV evidenced by a higher percentage of interstitial and cross-linked collagen. In the animals where PVR was performed, the α-SMA was noticeably lower in both PVR groups compared to the PR group. In both PVR groups a lower percentage of the interstitial and cross-linked collagen was observed compared to PR. Early valve replacement showed less cross-linked collagen compared to late valve replacement.

To the best of our knowledge, we developed one of the first animal models where chronic RV volume overload on can be studied in relation to histology. Increased collagen deposition is mostly observed in case of chronic RV pressure overload and leads to increased RV stiffness and diastolic

dysfunction.(59,62)Fibrotic changes due to RV volume overload has hardly been evaluated. In a CMR analysis in 18 children with TOF repair shorter post-contrast T1 values of the right ventricular anterior wall was demonstrated compared to healthy children suggesting a higher degree of fibrosis.(161) An expansion of the extracellular volume (ECV) fraction which involves myocardial fibrosis, is often seen in adverse myocardial remodeling and in patients with TOF a greater ECV is more commonly associated with a pure volume overloaded RV rather than pressure or a mixed type of overload.(44) It has been speculated by the group of Tal Geva that an increased ECV with decreased mass-to-volume ratio correlates with a maladaptive process characterized by diffuse fibrosis and loss of cardiomyocytes in patients with TOF with RV volume overload.(44) Our findings support this speculation as a decrease in mass-to-volume ratio on CMR after PR and an increase in activated fibroblasts and increase in cross-linked collagen on histology is observed.
The observation that PVR decreases fibrotic alterations by restoring RV volume is something new. Mechanical unloading of the LV with a left ventricular assist device (LVAD) in end stage heart failure did not demonstrate a change in fibrosis or myofibroblast density.(162) The decrease in fibrotic changes was more pronounced after early valve replacement compared to late.

In summary, percutaneous PVR has proven to be a low risk procedure with good valve longevity. The risk of graft failure due to stent fractures can be reduced using adequate pre-stenting. Stent-in-stent combinations lowers the strain amplitude and adds more stiffness lowering the risk of deformation and ultimately fractures. Pre-stenting and percutaneous pulmonary valve replacement has also been proven to be beneficial in patients with dilated right ventricular outflow tracts as in patients with TOF. In an ovine model with pathophysiological changes comparable to TOF, early PVR leads to faster reverse remodeling, but after 5 months there is no difference compared to late PVR. Chronic RV volume overload led to more fibrosis. After PVR a lower percentage of cross-linked collagen and lower expression of α-SMA is observed. This observation is most pronounced after EARLY-PVR.

The optimal timing of PVR remains unclear. There needs to found a balance between performing PVR before irreversible RV dysfunction sets in with the disadvantage of graft failure and need for more re-interventions.(40) Current available conduits for PVR all have limited longevity. The earlier PVR is performed the more redo-PVR's are needed over a lifetime.(163) Thus, defining the early changes which might predict a future decline in RV function or the risk for malignant arrhythmias can assist in tailoring future treatment strategies.
The ideal treatment for patients with repaired TOF would consist of PVR in timely manner before irreversible RV dysfunction takes place using a conduit with hardly no procedural risks together with optimal longevity. However, this ideal solution does not exist yet.

FUTURE PERSPECTIVES

FUTURE PERSPECTIVES

It remains unclear whether the current changes in treatment strategy will ultimately reduce the burden of arrhythmias, heart failure and SCD. Current data on PVR in repaired TOF patients have shown RV reverse remodeling, even more pronounced after earlier PVR in asymptomatic patients. It has not been proven to reduce the long-term risks and increase life expectancy. The follow-up time of most of these trials remains too short to observe a difference in the long-term outcome.

The optimal timing of PVR still remains uncertain. It remains difficult to delineate the moment where the RV loses its capability of reverse remodeling and irreversible fibrotic changes will occur. An aim should be defining the early changes which might predict the future decline in RV function or the risk for malignant arrhythmias. The presented animal data did show fibrotic changes in the chronic volume overloaded RV.(67,164) Detecting early fibrotic changes in the RV of patients with TOF and defining its relation to arrhythmias and ventricular failure is key issue for the future. Post-contrast T1 mapping on CMR can be used in search for diffuse myocardial fibrosis patients with repaired TOF.(44,68,161) Serially CMR with post-contrast T1 mapping and LGE in patients with repaired TOF might to depict early fibrotic changes. A circulating biomarker for fibrotic changes as for example carboxy-terminal propeptide of procollagen type I (PICP) could have an added value. The PICP-level did correlate with the right ventricular late gadolinium enhancement findings on CMR in patients with TOF.(165)

An aim for future animal experiments might be chronic follow-up of animals with severe PR. Performing at appropriate time interval serial RV biopsies and post contrast T1 mapping on CMR, hemodynamics and programmed electrical stimulation. The aim is to delineate the moment of irreversible RV dysfunction, irreversible fibrosis and its relation to the development of arrhythmias.
In all of the studied animals the RV did show reverse remodeling, it might be of interest adding groups with more delayed PVR (e.g. 20 months PR).
Due to limited longevity of the current available conduits the earlier PVR is performed the more re-interventions are needed during life. An aim for the future towards the ideal treatment strategy for patients with TOF is the development of new or adapting existing conduits to attain an extreme good longevity with negligible degree of morbidity and mortality.

REFERENCES

REFERENCES

1. Bailliard F., Anderson RH. Tetralogy of Fallot. Orphanet J Rare Dis 2009. Doi: 10.1186/1750-1172-4-2.
2. Morgenthau A., Frishman WH. Genetic Origins of Tetralogy of Fallot. Cardiol Rev 2018. Doi: 10.1097/CRD.0000000000000170.
3. Baumgartner H., De Backer J., Babu-Narayan S V., et al. 2020 ESC Guidelines for the management of adult congenital heart disease. Eur Heart J 2020. Doi: 10.1093/eurheartj/ehaa554.
4. Starr JP. Tetralogy of Fallot: Yesterday and today. World J Surg 2010. Doi: 10.1007/s00268-009-0296-8.
5. Van Praagh R. Etienne-Louis Arthur Fallot and his tetralogy: a new translation of Fallot's summary and a modern reassessment of this anomaly. Eur J Cardio-Thoracic Surg 1989. Doi: 10.1016/1010-7940(89)90044-4.
6. Bertranou E., Blackstone E., Hazelrig J., Turner M., Kirklin JW. Life Expectancy Without Surgery in ToF. Am J Cardiol 1978.
7. Arciniegas E., Farooki ZQ., Hakimi M., Green EW. Results of two-stage surgical treatment of tetralogy of Fallot. J Thorac Cardiovasc Surg 1980.
8. Karamlou T., McCrindle BW., Williams WG. Surgery Insight: Late complications following repair of tetralogy of Fallot and related surgical strategies for management. Nat Clin Pract Cardiovasc Med 2006. Doi: 10.1038/ncpcardio0682.
9. Nørgaard MA., Lauridsen P., Helvind M., Pettersson G. Twenty-to-thirty-seven-year follow-up after repair for Tetralogy of Fallot. Eur J Cardio-Thoracic Surg 1999. Doi: 10.1016/S1010-7940(99)00137-2.
10. Steiner MB., Tang X., Gossett JM., Malik S., Prodhan P. Timing of complete repair of non-ductal-dependent tetralogy of Fallot and short-term postoperative outcomes, a multicenter analysis. J Thorac Cardiovasc Surg 2014. Doi: 10.1016/j.jtcvs.2013.06.019.
11. Park CS., Lee JR., Lim HG., Kim WH., Kim YJ. The long-term result of total repair for tetralogy of Fallot. Eur J Cardio-Thoracic Surg 2010. Doi: 10.1016/j.ejcts.2010.02.030.
12. Cuypers JAAE., Menting ME., Konings EEM., et al. Unnatural history of tetralogy of fallot: Prospective follow-up of 40 years after surgical correction. Circulation 2014. Doi: 10.1161/CIRCULATIONAHA.114.009454.
13. Luijten LWG., Van den Bosch E., Duppen N., et al. Long-term outcomes of transatrial-transpulmonary repair of tetralogy of Fallot. Eur J Cardio-Thoracic Surg 2015. Doi: 10.1093/ejcts/ezu182.
14. Blalock A. Experimental Observations on the Effects of Connecting by Suture the Left Main Pulmonary Artery to the Systemic Circulation. J Thorac Surg 1939;8:525–30.
15. Meade RH. A History of Thoracic Surgery. Springfield: Charles C Thomas; 1961.
16. Neill CA., Clark EB. Tetralogy of Fallot. The first 300 years. Tex Heart Inst J 1994.
17. Blalock A. Landmark article May 19, 1945: The surgical treatment of malformations of the heart in which there is pulmonary stenosis or pulmonary atresia. By Alfred Blalock and Helen B. Taussig. JAMA J Am Med Assoc 1984. Doi: 10.1001/jama.251.16.2123.
18. HOLMAN WL., BUHRMAN WC., OLDHAM HN., SABISTON DC. The Blalock-Taussig Shunt: An Analysis of Trends and Techniques in the Fourth Decade. J Card Surg 1989. Doi: 10.1111/j.1540-8191.1989.tb00266.x.
19. AboulHosn J., Child JS. Management after childhood repair of tetralogy of Fallot. Curr Treat Options Cardiovasc Med 2006. Doi: 10.1007/s11936-006-0036-4.
20. Blalock A., Taussig HB. The surgical treatment of malformations of the heart: In which there is pulmonary stenosis or pulmonary atresia. J Am Med Assoc 1945. Doi: 10.1001/jama.1945.02860200029009.
21. Murphy AM., Cameron DE. The Blalock-Taussig-Thomas collaboration: A model for medical progress. JAMA - J Am Med Assoc 2008. Doi: 10.1001/jama.300.3.328.

22. Kochav J. Adult Congenital Heart Disease in Clinical Practice. 2018.
23. LILLEHEI CW. Controlled cross circulation for direct-vision intracardiac surgery; correction of ventricular septal defects, atrioventricularis communis, and tetralogy of Fallot. Postgrad Med 1955. Doi: 10.1080/00325481.1955.11708211.
24. LILLEHEI CW., COHEN M., WARDEN HE., et al. Direct vision intracardiac surgical correction of the tetralogy of Fallot, pentalogy of Fallot, and pulmonary atresia defects; report of first ten cases. Ann Surg 1955. Doi: 10.1097/00000658-195509000-00010.
25. KIRKLIN JW., ELLIS FH., McGOON DC., DUSHANE JW., SWAN HJ. Surgical treatment for the tetralogy of Fallot by open intracardiac repair. J Thorac Surg 1959.
26. Kirklin JW., Wallace RB., McGoon DC., DuShane JW. Early and late results after intracardiac repair of Tetralogy of Fallot. 5-Year review of 337 patients. Ann Surg 1965. Doi: 10.1097/00000658-196510000-00004.
27. Stoney WS. Evolution of cardiopulmonary bypass. Circulation 2009. Doi: 10.1161/CIRCULATIONAHA.108.830174.
28. Hirsch-Romano JC., Bove EL., Si MS., Bove EL. Transatrial repair of tetralogy of fallot. Surgery of Conotruncal Anomalies. 2016.
29. Karl TR., Sano S., Pornviliwan S., Mee RBB. Tetralogy of fallot: Favorable outcome of nonneonatal transatrial, transpulmonary repair. Ann Thorac Surg 1992. Doi: 10.1016/0003-4975(92)90646-L.
30. G. S., O. M., M. R., et al. Repair of tetralogy of Fallot in the first six months of life: transatrial versus transventricular approach. Ann Thorac Surg 1995.
31. Bacha E. Valve-Sparing or Valve Reconstruction Options in Tetralogy of Fallot Surgery. Semin Thorac Cardiovasc Surg Pediatr Card Surg Annu 2017. Doi: 10.1053/j.pcsu.2016.09.001.
32. Bacha E. Valve-Sparing Options in Tetralogy of Fallot Surgery. Semin Thorac Cardiovasc Surg Pediatr Card Surg Annu 2012. Doi: 10.1053/j.pcsu.2012.01.006.
33. Robinson JD., Rathod RH., Brown DW., et al. The evolving role of intraoperative balloon pulmonary valvuloplasty in valve-sparing repair of tetralogy of Fallot. J Thorac Cardiovasc Surg 2011. Doi: 10.1016/j.jtcvs.2011.02.047.
34. Menaissy Y., Omar I., Mofreh B., Alassal M. Total Correction of Tetralogy of Fallot in the First 60 Days of Life in Symptomatic Infants: Is It The Gold Standard? Thorac Cardiovasc Surg 2019. Doi: 10.1055/s-0039-1678698.
35. Broberg CS., Aboulhosn J., Mongeon FP., et al. Prevalence of left ventricular systolic dysfunction in adults with repaired tetralogy of fallot. Am J Cardiol 2011. Doi: 10.1016/j.amjcard.2010.12.026.
36. Ait Ali L., Trocchio GL., Crepaz R., et al. Left ventricular dysfunction in repaired tetralogy of Fallot: incidence and impact on atrial arrhythmias at long term-follow up. Int J Cardiovasc Imaging 2016. Doi: 10.1007/s10554-016-0928-7.
37. Valente AM., Gauvreau K., Assenza GE., et al. Contemporary predictors of death and sustained ventricular tachycardia in patients with repaired tetralogy of Fallot enrolled in the INDICATOR cohort. Heart 2014. Doi: 10.1136/heartjnl-2013-304958.
38. van der Ven JPG., van den Bosch E., Bogers AJCC., Helbing WA. Current outcomes and treatment of tetralogy of Fallot. F1000Research 2019. Doi: 10.12688/f1000research.17174.1.
39. Bordachar P., Iriart X., Chabaneix J., et al. Presence of ventricular dyssynchrony and haemodynamic impact of right ventricular pacing in adults with repaired Tetralogy of Fallot and right bundle branch block. Europace 2008. Doi: 10.1093/europace/eun178.
40. Geva T. Indications and Timing of Pulmonary Valve Replacement After Tetralogy of Fallot Repair. Pediatr Card Surg Annu 2006. Doi: 10.1053/j.pcsu.2006.02.009.
41. Villafañe J., Feinstein JA., Jenkins KJ., et al. Hot topics in tetralogy of fallot. J Am Coll Cardiol 2013. Doi: 10.1016/j.jacc.2013.07.100.
42. Plymen CM., Finlay M., Tsang V., et al. Haemodynamic consequences of targeted single-and dual-site right ventricular pacing in adults with congenital heart disease undergoing surgical pulmonary valve replacement. Europace 2014. Doi: 10.1093/europace/euu281.

43. Redington AN. Physiopathology of Right Ventricular Failure. Pediatr Card Surg Annu 2006. Doi: 10.1053/j.pcsu.2006.02.005.
44. Chen CA., Dusenbery SM., Valente AM., Powell AJ., Geva T. Myocardial ECV Fraction Assessed by CMR Is Associated with Type of Hemodynamic Load and Arrhythmia in Repaired Tetralogy of Fallot. JACC Cardiovasc Imaging 2016. Doi: 10.1016/j.jcmg.2015.09.011.
45. Gatzoulis MA., Till JA., Somerville J., Redington AN. Mechanoelectrical Interaction in Tetralogy of Fallot. Circulation 1995. Doi: 10.1161/01.cir.92.2.231.
46. Gatzoulis MA., Balaji S., Webber SA., et al. Risk factors for arrhythmia and sudden cardiac death late after repair of tetralogy of Fallot: A multicentre study. Lancet 2000. Doi: 10.1016/S0140-6736(00)02714-8.
47. Murphy J. Long-term follow-up after repair of tetralogy of Fallot. Cardiol Rev 1996. Doi: 10.1097/00045415-199611000-00007.
48. Bonello B., Kempny A., Uebing A., et al. Right atrial area and right ventricular outflow tract akinetic length predict sustained tachyarrhythmia in repaired tetralogy of Fallot. Int J Cardiol 2013. Doi: 10.1016/j.ijcard.2013.04.048.
49. Probst J., Diller G-P., Reinecke H., et al. Prevention of sudden cardiac death in patients with Tetralogy of Fallot: Risk assessment and long term outcome. Int J Cardiol 2018;269:91–6. Doi: 10.1016/J.IJCARD.2018.06.107.
50. Egbe AC., Miranda WR., Madhavan M., et al. Cardiac implantable electronic devices in adults with tetralogy of Fallot. Heart 2019. Doi: 10.1136/heartjnl-2018-314072.
51. Khairy P., Harris L., Landzberg MJ., et al. Implantable cardioverter-defibrillators in tetralogy of Fallot. Circulation 2008. Doi: 10.1161/CIRCULATIONAHA.107.726372.
52. Priori SG., Blomström-Lundqvist C. 2015 European Society of Cardiology Guidelines for the management of patients with ventricular arrhythmias and the prevention of sudden cardiac death summarized by co-chairs. Eur Heart J 2015. Doi: 10.1093/eurheartj/ehv445.
53. Al-Khatib SM., Stevenson WG., Ackerman MJ., et al. 2017 AHA/ACC/HRS Guideline for Management of Patients With Ventricular Arrhythmias and the Prevention of Sudden Cardiac Death. Circulation 2018. Doi: 10.1161/CIR.0000000000000549.
54. Geva T., Mulder B., Gauvreau K., et al. Preoperative predictors of death and sustained ventricular tachycardia after pulmonary valve replacement in patients with repaired tetralogy of Fallot enrolled in the indicator cohort. Circulation 2018. Doi: 10.1161/CIRCULATIONAHA.118.034740.
55. Bokma JP., Geva T., Sleeper LA., et al. A propensity score-adjusted analysis of clinical outcomes after pulmonary valve replacement in tetralogy of Fallot. Heart 2018. Doi: 10.1136/heartjnl-2017-312048.
56. Kapel GFL., Sacher F., Dekkers OM., et al. Arrhythmogenic anatomical isthmuses identified by electroanatomical mapping are the substrate for ventricular tachycardia in repaired Tetralogy of Fallot. Eur Heart J 2017. Doi: 10.1093/eurheartj/ehw202.
57. Maury P., Sacher F., Rollin A., et al. Ventricular arrhythmias and sudden death in tetralogy of Fallot. Arch Cardiovasc Dis 2017. Doi: 10.1016/j.acvd.2016.12.006.
58. Kapel GFL., Laranjo S., Blom NA., et al. Impact of surgery on presence and dimensions of anatomical isthmuses in tetralogy of Fallot. Heart 2018. Doi: 10.1136/heartjnl-2017-312452.
59. Frangogiannis NG. Fibroblasts and the extracellular matrix in right ventricular disease. Cardiovasc Res 2017. Doi: 10.1093/cvr/cvx146.
60. Shinde A V., Humeres C., Frangogiannis NG. The role of α-smooth muscle actin in fibroblast-mediated matrix contraction and remodeling. Biochim Biophys Acta - Mol Basis Dis 2017. Doi: 10.1016/j.bbadis.2016.11.006.
61. Biernacka A., Dobaczewski M., Frangogiannis NG. TGF-β signaling in fibrosis. Growth Factors 2011. Doi: 10.3109/08977194.2011.595714.
62. Baicu CF., Li J., Zhang Y., et al. Time course of right ventricular pressure-overload induced myocardial fibrosis: Relationship to changes in fibroblast postsynthetic procollagen processing. Am J Physiol - Hear Circ Physiol 2012. Doi: 10.1152/ajpheart.00482.2012.

63. Reddy S., Zhao M., Hu DQ., et al. Physiologic and molecular characterization of a murine model of right ventricular volume overload. Am J Physiol - Hear Circ Physiol 2013. Doi: 10.1152/ajpheart.00776.2012.
64. Lambert V., Capderou A., Le Bret E., et al. Right ventricular failure secondary to chronic overload in congenital heart disease: An experimental model for therapeutic innovation. J Thorac Cardiovasc Surg 2010. Doi: 10.1016/j.jtcvs.2009.11.028.
65. Farah MCK., Castro CRP., Moreira VDM., et al. The impact of preexisting myocardial remodeling on ventricular function early after tetralogy of Fallot repair. J Am Soc Echocardiogr 2010. Doi: 10.1016/j.echo.2010.06.008.
66. Alpat S., Yilmaz M., Onder S., et al. Histologic alterations in tetralogy of Fallot. J Card Surg 2017. Doi: 10.1111/jocs.12873.
67. Kido T., Ueno T., Taira M., et al. Clinical predictors of right ventricular myocardial fibrosis in patients with repaired tetralogy of fallot. Circ J 2018. Doi: 10.1253/circj.CJ-17-1088.
68. Babu-Narayan S V., Kilner PJ., Li W., et al. Ventricular fibrosis suggested by cardiovascular magnetic resonance in adults with repaired tetralogy of Fallot and its relationship to adverse markers of clinical outcome. Circulation 2006. Doi: 10.1161/CIRCULATIONAHA.105.548727.
69. Lock JE., Castaneda Zuniga WR., Fuhrman BP., Bass JL. Balloon dilation angioplasty of hypoplastic and stenotic pulmonary arteries. Circulation 1983. Doi: 10.1161/01.CIR.67.5.962.
70. Bass JL. Percutaneous balloon dilation angioplasty of pulmonary artery branch stenosis. Cardiovasc Intervent Radiol 1986. Doi: 10.1007/BF02577960.
71. Bacha EA., Kreutzer J. Comprehensive management of branch pulmonary artery stenosis. Journal of Interventional Cardiology. 2001.
72. Stout KK., Daniels CJ., Aboulhosn JA., et al. 2018 AHA/ACC Guideline for the Management of Adults With Congenital Heart Disease: A Report of the American College of Cardiology/American Heart Association Task Force on Clinical Practice Guidelines. Circulation 2019. Doi: 10.1161/CIR.0000000000000603.
73. Geva T. Repaired tetralogy of Fallot: The roles of cardiovascular magnetic resonance in evaluating pathophysiology and for pulmonary valve replacement decision support. J Cardiovasc Magn Reson 2011. Doi: 10.1186/1532-429X-13-9.
74. Geva T. Indications for pulmonary valve replacement in repaired tetralogy of fallot: The quest continues. Circulation 2013. Doi: 10.1161/CIRCULATIONAHA.113.005878.
75. Quail MA., Frigiola A., Giardini A., et al. Impact of pulmonary valve replacement in tetralogy of fallot with pulmonary regurgitation: A comparison of intervention and nonintervention. Ann Thorac Surg 2012. Doi: 10.1016/j.athoracsur.2012.06.062.
76. Ferraz Cavalcanti PE., Sá MPBO., Santos CA., et al. Pulmonary valve replacement after operative repair of Tetralogy of Fallot: Meta-analysis and meta-regression of 3,118 patients from 48 studies. J Am Coll Cardiol 2013. Doi: 10.1016/j.jacc.2013.04.107.
77. Baumgartner H., Bonhoeffer P., De Groot NMS., et al. ESC Guidelines for the management of grown-up congenital heart disease (new version 2010): The Task Force on the Management of Grown-up Congenital Heart Disease of the European Society of Cardiology (ESC). Eur Heart J 2010. Doi: 10.1093/eurheartj/ehq249.
78. Warnes CA. Adult Congenital Heart Disease. Importance of the Right Ventricle. J Am Coll Cardiol 2009. Doi: 10.1016/j.jacc.2009.06.048.
79. Warnes CA., Williams RG., Bashore TM., et al. ACC/AHA 2008 Guidelines for the Management of Adults With Congenital Heart Disease. J Am Coll Cardiol 2008. Doi: 10.1016/j.jacc.2008.10.002.
80. Therrien J., Provost Y., Merchant N., Williams W., Colman J., Webb G. Optimal timing for pulmonary valve replacement in adults after tetralogy of Fallot repair. Am J Cardiol 2005. Doi: 10.1016/j.amjcard.2004.11.037.
81. Therrien J., Siu S., Harris L. Impact of pulmonary valve replacement on arrhythmia propensity late after repair of tetralogy of fallot. ACC Curr J Rev 2001. Doi: 10.1016/s1062-1458(01)00508-6.

82. Frigiola A., Giamberti A., Chessa M., et al. Right ventricular restoration during pulmonary valve implantation in adults with congenital heart disease. Eur J Cardio-Thoracic Surg 2006. Doi: 10.1016/j.ejcts.2006.03.007.
83. Oosterhof T., Van Straten A., Vliegen HW., et al. Preoperative thresholds for pulmonary valve replacement in patients with corrected tetralogy of Fallot using cardiovascular magnetic resonance. Circulation 2007. Doi: 10.1161/CIRCULATIONAHA.106.659664.
84. Tretter JT., Friedberg MK., Wald RM., McElhinney DB. Defining and refining indications for transcatheter pulmonary valve replacement in patients with repaired tetralogy of Fallot: Contributions from anatomical and functional imaging. Int J Cardiol 2016. Doi: 10.1016/j.ijcard.2016.07.120.
85. Frigiola A., Tsang V., Bull C., et al. Biventricular response after pulmonary valve replacement for right ventricular outflow tract dysfunction: is age a predictor of outcome? Circulation 2008. Doi: 10.1161/CIRCULATIONAHA.107.756825.
86. Borik S., Crean A., Horlick E., et al. Percutaneous pulmonary valve implantation: 5 years of follow-up does age influence outcomes? Circ Cardiovasc Interv 2015. Doi: 10.1161/CIRCINTERVENTIONS.114.001745.
87. Pagourelias ED., Daraban AM., Mada RO., et al. Right ventricular remodelling after transcatheter pulmonary valve implantation. Catheter Cardiovasc Interv 2017;90(3). Doi: 10.1002/ccd.26966.
88. Valsangiacomo Buechel ER., Dave HH., Kellenberger CJ., et al. Remodelling of the right ventricle after early pulmonary valve replacement in children with repaired tetralogy of Fallot: Assessment by cardiovascular magnetic resonance. Eur Heart J 2005. Doi: 10.1093/eurheartj/ehi581.
89. Fuller S. Tetralogy of fallot and pulmonary valve replacement: Timing and techniques in the asymptomatic patient. Semin Thorac Cardiovasc Surg Pediatr Card Surg Annu 2014. Doi: 10.1053/j.pcsu.2014.01.012.
90. Oliver JM., Garcia-Hamilton D., Gonzalez AE., et al. Risk factors for prosthetic pulmonary valve failure in patients with congenital heart disease. Am J Cardiol 2015. Doi: 10.1016/j.amjcard.2015.07.043.
91. Chen PC., Sager MS., Zurakowski D., et al. Younger age and valve oversizing are predictors of structural valve deterioration after pulmonary valve replacement in patients with tetralogy of Fallot. J Thorac Cardiovasc Surg 2012. Doi: 10.1016/j.jtcvs.2011.10.079.
92. Sabate Rotes A., Bonnichsen CR., Reece CL., et al. Long-term follow-up in repaired tetralogy of Fallot: Can deformation imaging help identify optimal timing of pulmonary valve replacement? J Am Soc Echocardiogr 2014. Doi: 10.1016/j.echo.2014.09.012.
93. Sfyridis PG., Avramidis DP., Kirvassilis G V., Zavaropoulos PN., Papagiannis JK., Sarris GE. The contegra ® valved heterograft conduit for right ventricular outflow tract reconstruction: A reliable solution. Hell J Cardiol 2011.
94. Abbas JR., Hoschtitzky JA. Which is the best tissue valve used in the pulmonary position, late after previous repair of tetralogy of Fallot? Interact Cardiovasc Thorac Surg 2013. Doi: 10.1093/icvts/ivt332.
95. Cocomello L., Meloni M., Rapetto F., et al. Long-Term Comparison Between Pulmonary Homograft Versus Bioprosthesis for Pulmonary Valve Replacement in Tetralogy of Fallot. J Am Heart Assoc 2019. Doi: 10.1161/JAHA.119.013654.
96. Wijayarathne PM., Skillington P., Menahem S., Thuraisingam A., Larobina M., Grigg L. Pulmonary Allograft Versus Medtronic Freestyle Valve in Surgical Pulmonary Valve Replacement for Adults Following Correction of Tetralogy of Fallot or Its Variants. World J Pediatr Congenit Hear Surg 2019. Doi: 10.1177/2150135119859853.
97. Oosterhof T., Meijboom FJ., Vliegen HW., et al. Long-term follow-up of homograft function after pulmonary valve replacement in patients with tetralogy of Fallot. Eur Heart J 2006. Doi: 10.1093/eurheartj/ehl033.
98. Bokma JP., Winter MM., Oosterhof T., et al. Individualised prediction of pulmonary homograft

durability in tetralogy of Fallot. Heart 2015. Doi: 10.1136/heartjnl-2015-307754.
99. Van De Woestijne PC., Mokhles MM., De Jong PL., Witsenburg M., Takkenberg JJM., Bogers AJJC. Right ventricular outflow tract reconstruction with an allograft conduit in patients after tetralogy of fallot correction: Long-term follow-up. Ann Thorac Surg 2011. Doi: 10.1016/j.athoracsur.2011.02.036.
100. Kanter KR., Budde JM., Parks WJ., et al. One hundred pulmonary valve replacements in children after relief of right ventricular outflow tract obstruction. Ann Thorac Surg 2002. Doi: 10.1016/S0003-4975(02)03568-3.
101. Wells WJ., Arroyo H., Bremner RM., Wood J., Starnes VA. Homograft conduit failure in infants is not due to somatic outgrowth. J Thorac Cardiovasc Surg 2002. Doi: 10.1067/mtc.2002.121158.
102. Urso S., Rega F., Meuris B., et al. The Contegra conduit in the right ventricular outflow tract is an independent risk factor for graft replacement. Eur J Cardio-Thoracic Surg 2011. Doi: 10.1016/j.ejcts.2010.11.081.
103. Kanter KR., Fyfe DA., Mahle WT., Forbess JM., Kirshbom PM. Results with the Freestyle Porcine Aortic Root for Right Ventricular Outflow Tract Reconstruction in Children. Ann Thorac Surg 2003. Doi: 10.1016/S0003-4975(03)01304-3.
104. Albanesi F., Sekarski N., Lambrou D., Von Segesser LK., Berdajs DA. Incidence and risk factors for contegra graft infection following right ventricular outflow tract reconstruction: Long-term results. Eur J Cardio-Thoracic Surg 2014. Doi: 10.1093/ejcts/ezt579.
105. Van Dijck I., Budts W., Cools B., et al. Infective endocarditis of a transcatheter pulmonary valve in comparison with surgical implants. Heart 2015. Doi: 10.1136/heartjnl-2014-306761.
106. Bonhoeffer P., Boudjemline Y., Saliba Z., et al. Transcatheter implantation of a bovine valve in pulmonary position: A lamb study. Circulation 2000. Doi: 10.1161/01.CIR.102.7.813.
107. Bonhoeffer P., Boudjemline Y., Saliba Z., et al. Percutaneous replacement of pulmonary valve in a right-ventricle to pulmonary-artery prosthetic conduit with valve dysfunction. Lancet 2000. Doi: 10.1016/S0140-6736(00)02844-0.
108. Boudjemline Y., Bonhoeffer P. The percutaneous implantable heart valve. Prog Pediatr Cardiol 2001. Doi: 10.1016/S1058-9813(01)00124-2.
109. Khambadkone S., Bonhoeffer P. Percutaneous Pulmonary Valve Implantation. Pediatr Card Surg Annu 2006. Doi: 10.1053/j.pcsu.2006.02.006.
110. Cools B., Budts W., Heying R., et al. Medium term follow-up after percutaneous pulmonary valve replacement with the Melody® valve. IJC Hear Vasc 2015;7. Doi: 10.1016/j.ijcha.2015.02.014.
111. McElhinney DB., Hellenbrand WE., Zahn EM., et al. Short-and medium-term outcomes after transcatheter pulmonary valve placement in the expanded multicenter US melody valve trial. Circulation 2010. Doi: 10.1161/CIRCULATIONAHA.109.921692.
112. Schievano S., Petrini L., Migliavacca F., et al. Finite element analysis of stent deployment: Understanding stent fracture in percutaneous pulmonary valve implantation. J Interv Cardiol 2007. Doi: 10.1111/j.1540-8183.2007.00294.x.
113. J. N., S. K., L. C., et al. Risk stratification, systematic classification, and anticipatory management strategies for stent fracture after percutaneous pulmonary valve implantation. Circulation 2007.
114. Malekzadeh-Milani S., Ladouceur M., Patel M., et al. Incidence and predictors of Melody® valve endocarditis: A prospective study. Arch Cardiovasc Dis 2015. Doi: 10.1016/j.acvd.2014.09.003.
115. Malekzadeh-Milani S., Ladouceur M., Iserin L., Bonnet D., Boudjemline Y. Incidence and outcomes of right-sided endocarditis in patients with congenital heart disease after surgical or transcatheter pulmonary valve implantation. J Thorac Cardiovasc Surg 2014. Doi: 10.1016/j.jtcvs.2014.07.097.
116. McElhinney DB., Sondergaard L., Armstrong AK., et al. Endocarditis After Transcatheter Pulmonary Valve Replacement. J Am Coll Cardiol 2018. Doi: 10.1016/j.jacc.2018.09.039.

117. Morgan G., Prachasilchai P., Promphan W., et al. Medium-term results of percutaneous pulmonary valve implantation using the Venus P-valve: international experience. EuroIntervention 2019. Doi: 10.4244/EIJ-D-18-00299.
118. J. N., L. C., P. L., et al. Percutaneous pulmonary valve-in-valve implantation: A successful treatment concept for early device failure. Eur Heart J 2008.
119. McElhinney DB., Cheatham JP., Jones TK., et al. Stent fracture, valve dysfunction, and right ventricular outflow tract reintervention after transcatheter pulmonary valve implantation: Patient-related and procedural risk factors in the US melody valve trial. Circ Cardiovasc Interv 2011. Doi: 10.1161/CIRCINTERVENTIONS.111.965616.
120. K AA., T BD., K CA., et al. One-Year Follow-Up of the Melody Transcatheter Pulmonary Valve Multicenter Post-Approval Study. JACC-CARDIOVASCULAR Interv 2014.
121. Boshoff DE., Cools BLM., Heying R., et al. Off-label use of percutaneous pulmonary valved stents in the right ventricular outflow tract: Time to rewrite the label? Catheter Cardiovasc Interv 2013;81(6). Doi: 10.1002/ccd.24594.
122. Malekzadeh-Milani S., Ladouceur M., Cohen S., Iserin L., Boudjemline Y. Results of transcatheter pulmonary valvulation in native or patched right ventricular outflow tracts. Arch Cardiovasc Dis 2014. Doi: 10.1016/j.acvd.2014.07.045.
123. Rockefeller T., Shahanavaz S., Zajarias A., Balzer D. Transcatheter implantation of SAPIEN 3 valve in native right ventricular outflow tract for severe pulmonary regurgitation following tetralogy of fallot repair. Catheter Cardiovasc Interv 2016. Doi: 10.1002/ccd.26480.
124. Haas NA., Carere RG., Kretschmar O., et al. Early outcomes of percutaneous pulmonary valve implantation using the Edwards SAPIEN XT transcatheter heart valve system. Int J Cardiol 2018. Doi: 10.1016/j.ijcard.2017.10.015.
125. Haas NA., Moysich A., Neudorf U., et al. Percutaneous implantation of the Edwards SAPIEN™ pulmonic valve: Initial results in the first 22 patients. Clin Res Cardiol 2013. Doi: 10.1007/s00392-012-0503-8.
126. Plessis J., Hascoët S., Baruteau A., et al. Edwards SAPIEN Transcatheter Pulmonary Valve Implantation. JACC Cardiovasc Interv 2018. Doi: 10.1016/j.jcin.2018.05.050.
127. Wilson WM., Benson LN., Osten MD., Shah A., Horlick EM. Transcatheter Pulmonary Valve Replacement with the Edwards Sapien System: The Toronto Experience. JACC Cardiovasc Interv 2015. Doi: 10.1016/j.jcin.2015.08.016.
128. Schoonbeek RC., Takebayashi S., Aoki C., et al. Implantation of the Medtronic Harmony Transcatheter Pulmonary Valve Improves Right Ventricular Size and Function in an Ovine Model of Postoperative Chronic Pulmonary Insufficiency. Circ Cardiovasc Interv 2016. Doi: 10.1161/CIRCINTERVENTIONS.116.003920.
129. Bergersen L., Benson LN., Gillespie MJ., et al. Harmony Feasibility Trial: Acute and Short-Term Outcomes With a Self-Expanding Transcatheter Pulmonary Valve. JACC Cardiovasc Interv 2017. Doi: 10.1016/j.jcin.2017.05.034.
130. Promphan W., Prachasilchai P., Siripornpitak S., Qureshi SA., Layangool T. Percutaneous pulmonary valve implantation with the Venus P-valve: Clinical experience and early results. Cardiol Young 2016. Doi: 10.1017/S1047951115001067.
131. Nevvazhay T., Zeppenfeld K., Brouwer C., Hazekamp M. Intraoperative cryoablation in late pulmonary valve replacement for tetralogy of Fallot. Interact Cardiovasc Thorac Surg 2020. Doi: 10.1093/icvts/ivaa013.
132. Barratt Boyes BG., Neutze JM. Primary repair of tetralogy of Fallot in infancy using profound hypothermia with circulatory arrest and limited cardiopulmonary bypass: a comparison with conventional two stage management. Ann Surg 1973. Doi: 10.1097/00000658-197310000-00003.
133. Zaragoza-Macias E., Stout KK. Management of pulmonic regurgitation and right ventricular dysfunction in the adult with repaired Tetralogy of Fallot. Curr Treat Options Cardiovasc Med 2013. Doi: 10.1007/s11936-013-0258-1.
134. Bouzas B., Kilner PJ., Gatzoulis MA. Pulmonary regurgitation: Not a benign lesion. Eur Heart J

2005. Doi: 10.1093/eurheartj/ehi091.
135. Cheung MMH., Konstantinov IE., Redington AN. Late complications of repair of tetralogy of fallot and indications for pulmonary valve replacement. Semin Thorac Cardiovasc Surg 2005. Doi: 10.1053/j.semtcvs.2005.02.006.
136. Pondorfer P., Yun T-J., Cheung M., et al. Tetralogy of Fallot Repair — Long Term Follow-up: Preservation Strategy Improves Late Outcomes. Thorac Cardiovasc Surg 2016. Doi: 10.1055/s-0036-1571561.
137. Nollert G., Fischlein T., Bouterwek S., Böhmer C., Klinner W., Reichart B. Long-term survival in patients with repair of tetralogy of Fallot: 36- year follow-up of 490 survivors of the first year after surgical repair. J Am Coll Cardiol 1997. Doi: 10.1016/S0735-1097(97)00318-5.
138. Therrien J., Siu SC., McLaughlin PR., Liu PP., Williams WG., Webb GD. Pulmonary valve replacement in adults late after repair of tetralogy of Fallot: Are we operating too late? J Am Coll Cardiol 2000. Doi: 10.1016/S0735-1097(00)00930-X.
139. Pardo González L., Ruiz Ortiz M., Delgado M., et al. Pulmonary homograft stenosis in the Ross procedure: Incidence, clinical impact and predictors in long-term follow-up. Arch Cardiovasc Dis 2017. Doi: 10.1016/j.acvd.2016.09.008.
140. Yong MS., Yim D., d'Udekem Y., et al. Medium-term outcomes of bovine jugular vein graft and homograft conduits in children. ANZ J Surg 2015. Doi: 10.1111/ans.13018.
141. Bibevski S., Ruzmetov M., Fortuna RS., Turrentine MW., Brown JW., Ohye RG. Performance of SynerGraft Decellularized Pulmonary Allografts Compared With Standard Cryopreserved Allografts: Results From Multiinstitutional Data. Ann Thorac Surg 2017. Doi: 10.1016/j.athoracsur.2016.07.068.
142. O'Donnell C., Holloway R., Tilton E., Stirling J., Finucane K., Wilson N. Infective endocarditis following Melody valve implantation: Comparison with a surgical cohort. Cardiol Young 2017. Doi: 10.1017/S1047951116000494.
143. Patel M., Malekzadeh-Milani S., Ladouceur M., Iserin L., Boudjemline Y. Percutaneous pulmonary valve endocarditis: Incidence, prevention and management. Arch Cardiovasc Dis 2014. Doi: 10.1016/j.acvd.2014.07.052.
144. Jung CJ., Yeh CY., Shun CT., et al. Platelets enhance biofilm formation and resistance of endocarditis-inducing streptococci on the injured heart valve. J Infect Dis 2012. Doi: 10.1093/infdis/jis021.
145. Hoen B. Platelets and platelet inhibitors in infective endocarditis. Curr Infect Dis Rep 2002. Doi: 10.1007/s11908-002-0021-3.
146. Cheatham JP., Hellenbrand WE., Zahn EM., et al. Clinical and hemodynamic outcomes up to 7 years after transcatheter pulmonary valve replacement in the US melody valve investigational device exemption trial. Circulation 2015. Doi: 10.1161/CIRCULATIONAHA.114.013588.
147. Demkow M., Ruzyłło W., Biernacka EK., et al. Percutaneous edwards SAPIENTM valve implantation for significant pulmonary regurgitation after previous surgical repair with a right ventricular outflow patch. Catheter Cardiovasc Interv 2014. Doi: 10.1002/ccd.25096.
148. Gewillig M., Brown S. Coronary compression caused by stenting a right pulmonary artery conduit. Catheter Cardiovasc Interv 2009. Doi: 10.1002/ccd.21928.
149. Nordmeyer J., Lurz P., Khambadkone S., et al. Pre-stenting with a bare metal stent before percutaneous pulmonary valve implantation: Acute and 1-year outcomes. Heart 2011. Doi: 10.1136/hrt.2010.198382.
150. Schievano S., Taylor AM., Capelli C., et al. Patient specific finite element analysis results in more accurate prediction of stent fractures: Application to percutaneous pulmonary valve implantation. J Biomech 2010. Doi: 10.1016/j.jbiomech.2009.10.024.
151. Ashbey MS., Cebon D. materials: Science, processing and design. 2009.
152. Cosentino D., Quail MA., Pennati G., et al. Geometrical and stress analysis of factors associated with stent fracture after melody percutaneous pulmonary valve implantation. Circ Cardiovasc Interv 2014. Doi: 10.1161/CIRCINTERVENTIONS.113.000631.
153. Chakfé N., Heim F. Commentary on "electrical potentials between stent-grafts made from

different metals induce negligible corrosion." Eur J Vasc Endovasc Surg 2013. Doi: 10.1016/j.ejvs.2013.07.009.
154. Ersboell M., Vejlstrup N., Nilsson JC., et al. Percutaneous pulmonary valve replacement after different duration of free pulmonary regurgitation in a porcine model: Effects on the right ventricle. Int J Cardiol 2013. Doi: 10.1016/j.ijcard.2012.08.012.
155. Ishimaru K., Miyagawa S., Fukushima S., et al. Functional and pathological characteristics of reversible remodeling in a canine right ventricle in response to volume overloading and volume unloading. Surg Today 2014. Doi: 10.1007/s00595-014-0847-y.
156. Agger P., Hyldebrandt JA., Nielsen EA., Hjortdal V., Smerup M. A novel porcine model for right ventricular dilatation by external suture plication of the pulmonary valve leaflets – practical and reproducible☆. Interact Cardiovasc Thorac Surg 2010. Doi: 10.1510/icvts.2009.227264.
157. Robb JD., Harris MA., Minakawa M., et al. An ovine model of pulmonary insufficiency and right ventricular outflow tract dilatation. J Heart Valve Dis 2012.
158. Kuehne T., Saeed M., Gleason K., et al. Effects of Pulmonary Insufficiency on Biventricular Function in the Developing Heart of Growing Swine. Circulation 2003. Doi: 10.1161/01.CIR.0000092887.84425.09.
159. Bove T., Vandekerckhove K., Bouchez S., Wouters P., Somers P., Van Nooten G. Role of myocardial hypertrophy on acute and chronic right ventricular performance in relation to chronic volume overload in a porcine model: Relevance for the surgical management of tetralogy of Fallot. J Thorac Cardiovasc Surg 2014. Doi: 10.1016/j.jtcvs.2013.10.026.
160. Ko Y., Morita K., Abe T., Nakao M., Hashimoto K. Variability of Pulmonary Regurgitation in Proportion to Pulmonary Vascular Resistance in a Porcine Model of Total Resection of the Pulmonary Valve: Implications for Early- and Long-Term Postoperative Management of Right Ventricular Outflow Tract Reconstru. World J Pediatr Congenit Heart Surg 2015. Doi: 10.1177/2150135115598209.
161. Kozak MF., Redington A., Yoo SJ., Seed M., Greiser A., Grosse-Wortmann L. Diffuse myocardial fibrosis following tetralogy of Fallot repair: A T1 mapping cardiac magnetic resonance study. Pediatr Radiol 2014. Doi: 10.1007/s00247-013-2840-9.
162. Farris SD., Don C., Helterline D., et al. Cell-Specific Pathways Supporting Persistent Fibrosis in Heart Failure. J Am Coll Cardiol 2017. Doi: 10.1016/j.jacc.2017.05.040.
163. Dobbels B., Herregods MC., Troost E., et al. Early versus late pulmonary valve replacement in patients with transannular patch-repaired tetralogy of Fallot. Interact Cardiovasc Thorac Surg 2017. Doi: 10.1093/icvts/ivx118.
164. Yamamura K., Yuen D., Hickey EJ., et al. Right ventricular fibrosis is associated with cardiac remodelling after pulmonary valve replacement. Heart 2019. Doi: 10.1136/heartjnl-2018-313961.
165. Chen CA., Tseng WYI., Wang JK., et al. Circulating biomarkers of collagen type i metabolism mark the right ventricular fibrosis and adverse markers of clinical outcome in adults with repaired tetralogy of Fallot. Int J Cardiol 2013;167(6):2963–8. Doi: 10.1016/j.ijcard.2012.08.059.

SUMMARY

SUMMARY

Patients with surgically corrected tetralogy of Fallot (TOF) often develop severe pulmonary regurgitation (PR) leading to chronic volume overload of the right ventricle. The long-term risks are malignant arrhythmias leading to sudden cardiac death (SCD) and ventricular failure. TOF patients will require pulmonary valve replacement (PVR) during life. Recommendations for PVR in symptomatic and asymptomatic patients with TOF have been established by the ESC and AHA/ACC. The optimal timing of PVR remains uncertain. Balance still has to be found between performing PVR before irreversible RV dysfunction sets in with the disadvantage of graft failure and need for re-interventions due to earlier PVR. Following the development of percutaneous stented valves in 2000 a new era in treatment options for congenital heart disease has been initiated.

The aim was to evaluate the percutaneous pulmonary valve replacement (PPVR) technique, the durability of the valve and procedural morbidity and mortality. The PPVR technique had no procedural or valve related mortality. There was a good preserved leaflet function up to 11 years after implantation of the Melody™ valve. The main reason for graft failure in this series was endocarditis (IE), leading to re-intervention in half of these patients with IE. Adequate pre-stenting reduced the risk of hemodynamic important stent fractures and led very exceptionally to re-intervention.

The applicability of the PPVR technique in TOF patients was evaluated. The right ventricular outflow tract (RVOT) can become dilated which makes PPVR challenging. The feasibility and safety of pre-stenting the dilated RVOT in patients with severe pulmonary valve regurgitation prior to percutaneous pulmonary valve replacement (PPVR) was evaluated. The data demonstrated that it is feasible and safe to perform pre-stenting and PPVR in patients with post-surgical conduit-free and non-stenotic RVOT with severe pulmonary regurgitation. Balloon interrogation was crucial as sizing is extremely important. This technique had in this specific subgroup of patients no mortality and low morbidity.

Stent fractures can lead to valve dysfunction which is a major threat to the long-term durability of the valve. The aim was to assess the resistance to compression (stiffness) of frequently used stents for right ventricular outflow tract pre-stenting. Adding stents to a single stent significantly increased stiffness which will reduce the risk of metal fatigue failure. The corrosion potential when different types of stent alloys come into contact with each other was evaluated. Corrosion of individual stents or stent combinations did occur, but is negligible over a human lifetime with low risk of biological effects. No mechanical integrity problems were expected as there is only 0.3% of the initial diameter of the struts of a stent that will be lost as a consequence of corrosion after 100 years.

An animal model with the pathophysiology comparable to patients with TOF was created. Two historical models in whom PR was created and banding of the pulmonary artery (PA) was performed, were compared: surgical leaflet resection versus bare metal stent across the pulmonary valve (PV). The model with the bare metal stent across the PV resulted in significant higher PR and RV dilatation compared to the surgical leaflet resection. The model with initial PA banding and secondary stent giving severe PR and leading to RV volume overload, correlated well with the pathophysiology of tetralogy of Fallot. This model can be used to evaluate RV remodeling and reverse remodeling after PVR.

Pulmonary valve replacement can overcome the RV overload, but the timing of PVR remains controversial. The animal model with stenting of the PV was used to evaluate RV remodeling as a result of severe PR and the reverse remodeling after pulmonary valve replacement at different time intervals. The animals developed severe PR leading to important RV volume overload. PVR was performed at 2 different time intervals (after 5 months and 10 months of PR). PVR resulted in RV reverse remodeling at higher rate after early valve replacement compared to late valve replacement with a more delayed reverse remodeling. Five months after PVR the difference in RV dimensions between both PVR groups disappeared. Chronic RV volume overload led to fibrotic changes with increased cross-linked collagen and activated fibroblasts reflected by increased expression of alpha-smooth muscle cell actin (α-SMA). Both PVR groups showed a lower percentage of cross-linked collagen and expression of α-SMA is observed, which was most pronounced after early valve replacement.

The ideal treatment solution for patients with TOF does not exist yet. PVR should be performed in timely manner before irreversible RV dysfunction takes place. Defining the early changes which might predict a future decline in RV function or the risk for malignant arrhythmias can assist in tailoring future treatment strategies.

SAMENVATTING

Patiënten met heelkundig gecorrigeerde tetralogie van Fallot (TOF) ontwikkelen vaak een ernstige lekkage van de longslagaderklep die tot een volumeoverbelasting van de rechter ventrikel leidt. De lange termijn risico's zijn ventriculair falen en maligne aritmie die tot plotse cardiale dood kan leiden. Gedurende het leven zal bij patiënten met TOF de longslagaderklep vervangen moeten worden. De ESC en AHA/ACC hebben aanbevelingen opgesteld voor de vervanging van de longslagaderklep in symptomatische en asymptomatische patiënten met TOF. Tot op heden is het onduidelijk wat het ideale moment is voor vervanging van de longslagaderklep. Er is een moeilijke balans tussen de vervanging van longslagaderklep alvorens er irreversibele dysfunctie van de rechter ventrikel optreedt enerzijds en de nood voor meerdere ingrepen anderzijds door vroegere klepvervanging gezien beperkte duurzaamheid van de kleppen. In 2000 werd een percutane klepstent ontwikkeld die een nieuw tijdperk inluiden van behandel opties voor patiënten met een congenitale hartziekte.

De morbititeit en mortaliteit van percutane vervangingstechniek van de longslagaderklep werd geëvalueerd. De duurzaamheid van de geïmplanteerde kleppen werd geëvalueerd. De percutane vervanging van de longslagaderklep vertoonde geen procedure of klep gerelateerd overlijden. De klepfunctie van de Melody™ klepstent bleef goed bewaard tot 11 jaar na implantatie. De voornaamste reden voor klepdysfunctie was endocarditis. De helft van de patiënten met endocarditis hadden nood aan een heringreep. Adequaat plaatsen van pre-stent in de rechter kamer uitstroombaan deed het risico op hemodynamisch belangrijke stent fracturen dalen.

De toepasbaarheid van percutane vervanging van de longslagaderklep in patiënten met TOF werd geëvalueerd. De rechter ventrikel uitstroombaan kan zeer uitgezet worden waardoor percutane vervanging van de longslagaderklep moeilijk wordt. De haalbaarheid en veiligheid van het plaatsen van een pre-stent in een sterk uitgezette rechter ventrikel uitstroombaan gevolgd door percutane vervanging van de longslagaderklep werden geëvalueerd. De studie toont aan dat in patiënten met TOF met een uitgezette rechter ventrikel uitstroombaan het mogelijk om een pre-stent te plaatsen gevolgd door percutane vervanging van de longslagaderklep en dat dit veilig kan worden uitgevoerd. Het gebruik van ballon ondervraging van de uitstroombaan is cruciaal in correcte maatberekening. In een specifieke subgroep van patiënten kent deze techniek een lage morbiditeit en geen mortaliteit.

Stent fracturen kunnen aanleiding geven tot dysfunctie van de klepstent en vormen een belangrijke bedreiging voor de lange termijn duurzaamheid van de klepstent. Frequent gebruikte stents en combinatie van stents werden geanalyseerd op hun weerstand tegen vervorming (stijfheid). De combinatie van meerdere stents verhoogde aanzienlijk de stijfheid en verminderde hierdoor het risico op metaal moeheid. Als verschillende stents in fysiek contact met elkaar komen, ontstaan er galvanische stromen en kan corrosie optreden. Het risico op corrosie werd geëvalueerd. Er trad

corrosie op van de individuele stents alsook de combinatie van stents, maar verwaarloosbaar weinig zodat het niet aanleiding kan geven tot een biologisch effect gedurende een mensenleven. Als gevolg van corrosie zal er 0.3% van de interne diameter van de stentsteunen verdwenen zijn na ongeveer 100 jaar.

Een proefdiermodel werd ontwikkeld met pathofysiologische kenmerken zoals patiënten met tetralogie van Fallot. Twee historische modellen werden vergeleken waarbij een lekkage van de longslagaderklep werd geïnduceerd en een banding van de longslagader werd uitgevoerd. Een model waarbij de klepblaadjes van de longslagaderklep werden weggesneden en een model waarbij een stent over de longslagaderklep werd geplaatst. De lekkage de longslagaderklep en de uitzetting van het rechter hart waren significant meer uitgesproken in het model met de stent over de klep. Het model met initiële banding van de longslagader en vervolgens stent over de klep correleert best met de pathofysiologische kenmerken van patiënten met TOF. Dit model kan gebruikt worden om rechter ventrikel remodeling en omgekeerde remodeling na vervanging van de longslagaderklep te bestuderen.

Vervanging van de longslagaderklep kan de volumeoverbelasting van de rechter ventrikel herstellen, maar het ideale moment is nog steeds controversieel. Het proefdiermodel met stent over de klep werd gebruikt om de remodeling en omgekeerde remodeling van de rechter ventrikel na vervanging van de longslagaderklep op verschillende tijdstippen te bestuderen. De longslagaderklep vertoonde ernstige lekkage en de rechter ventrikel ernstige volumeoverbelasting in de proefdieren. De longslagaderklep werd vervangen op 2 verschillende tijdstippen (na 5 maanden en 10 maanden lekkage van de klep). Vroege vervanging van de longslagaderklep leidde tot snellere omgekeerde remodeling van de rechter ventrikel, vergeleken met late vervanging waarbij het omgekeerd remodeling proces meer vertraagd verliep. Vijf maanden na klep vervanging was er geen verschil meer in dimensies van de rechter ventrikel tussen de dieren met vroege en late klepvervanging. Chronische rechter ventrikel volumeoverbelasting gaf aanleiding tot fibrose met meer cross-linked collageen en geactiveerde fibroblasten met verhoogde expressie van alfa-gladdespiercel actine. Proefdieren die klepvervanging ondergingen hadden minder cross-linked collageen en minder expressie van alfa-gladdespiercel actine, dit was meest uitgesproken na vroege klepvervanging.

De ideale behandelingsoplossing voor patiënten met TOF bestaat nog niet. De longslagaderklep dient vervangen te worden voordat er irreversibele dysfunctie van de rechter ventrikel kan optreden. Het definiëren en opsporen van vroege veranderingen die een toekomstige achteruitgang van de rechter ventrikel functie of het risico op aritmie kunnen voorspellen, vormt een belangrijke uitdaging voor de toekomst om zo de behandelingsstrategie te kunnen verfijnen.

ACKNOWLEDGEMENTS, PERSONAL CONTRIBUTION AND CONFLICT OF INTEREST

SCIENTIFIC ACKNOWLEDGEMENT

- Joeri Van Puyvelde: for surgical help during the animal experiments
- Katrien Vandendriessche: for surgical help during the animal experiments
- Shota Yasuda: for surgical help during the animal experiments
- Nina Vandendriessche: for help during the animal experiments and sampling
- Mieke Ginckels: for the planning of experiments and help during the animal experiments
- David Celis: for help during the animal experiments
- Chandan Kadur Nagaraju: for performing the histological analysis
- Karin Sipido: for analysis of the histological data
- Piet Claus: for the design of the studies, performing the CMR imaging and the revision of the manuscript
- Filip Rega: for the design of the studies, surgical help during the animal experiments and the revision of the manuscript
- Marc Gewillig: for the design of the studies and the revision of the manuscript

PERSONAL CONTRIBUTION

The contribution of Cools Bjorn to this work

- Conducting the animal experiments
- Analysis of CMR images
- Collecting patient data
- Analysis of the data
- Statistical analysis of the data
- Writing the manuscript

THIS PROJECT WAS FUNDED BY RESEARCH GRANTS

- In part by the Belgian Heart Surgery Foundation
- In part by Medtronic
- In part by the Henri and Mariëtte Mertens-Berx Foundation
- In part by the Eddy Merckx Research Foundation
- In part by Sporta MonVentoux Research Foundation
- In part by Belgian Foundation for research in Pediatric Cardiology (FNRCP)

CONFLICT OF INTEREST STATEMENT

- Cools Bjorn has no financial or proprietary interests in any product mentioned in this manuscript
- Marc Gewillig is proctor for Medtronic, Numed and Edwards

DANKWOORD

DANKWOORD

2020 loopt op zijn einde, een bewogen jaar waarin een organisme ter grootte van amper 0.02 micrometer de hele wereld in zijn greep hield en nog steeds houdt. Een bijzonder moment om even stil te staan. Ook een moment om terug te blikken op de aflopen jaren en dank te betuigen aan zeer veel mensen zonder wie dit werk niet mogelijk zou zijn geweest.

Vooreerst wil ik Prof. Dr. Luc Sels, Rector van de KULeuven, Prof. Dr. Chris Van Geet, vice-rector Biomedische Wetenschappen en Prof. Dr. Paul Herijgers, Decaan van de Faculteit Geneeskunde, alsook hun voorgangers Prof. Dr. Rik Torfs, Prof. Dr. Minne Casteels en Prof. Dr. Jan Goffin, te danken voor de mogelijkheid dit proefschrift voor te bereiden aan de KULeuven. Mijn dank gaat uiteraard ook uit naar Prof. Dr. Werner Budts, voorzitter van het Departement Cardiovasculaire Wetenschappen en Prof. Dr. Kathleen Freson, voorzitter van de jury.

I sincerely want to thank the external members of the jury, Prof. Dr. Lars Søndergaard and Prof. Dr. Shakeel Qureshi for reading the manuscript carefully and giving their expert opinion and comments which are greatly appreciated.
Uiteraard wens ik mijn oprechte dank en appreciatie te betuigen voor Prof. Dr. Werner Budts en Prof. Dr. Bart Meyns van de interne jury voor hun steeds kritische en opbouwende evaluaties de afgelopen jaren.

Na mijn opleiding pediatrie kreeg ik de opportuniteit om me verder te bekwamen in de pediatrische en congenitale cardiologie. Een zeer speciaal woord van dank hiervoor aan Prof. Dr. Bert Suys, die me inspireerde om kindercardiologie te gaan doen. Beste Bert, bedankt om me mee op sleeptouw te nemen en mijn mentor te willen zijn. Je gaf me de mogelijkheid om in de kindercardiologie verder te bekwamen. Ik wil je bedanken voor al de fijne momenten de afgelopen jaren en je begrip en steun tijdens moeilijke momenten. Een dikke welgemeende merci.

Een oprechte dank aan ieder die mijn opleiding binnen de kindercardiologie heeft verzorgd. Een bijzondere dank hiervoor aan Prof. Dr. Wim Helbing en zijn team van het Erasmus MC Rotterdam.

In 2010 kreeg ik de kans om in UZ Leuven te werken. Graag wil ik de collega's bedanken voor de fijne samenwerking de afgelopen jaren. Beste Marc, Benedicte, Ruth en Derize van harte dank en hopelijk mogen er nog vele mooie jaren van aangename samenwerking volgen.
Ik kreeg de kans om me verder te bekwamen in de interventionele kindercardiologie. Een zeer grote dank ben ik hiervoor verschuldigd aan Prof Dr. Marc Gewillig die me kans gaf hierin verder te laten groeien. Marc, ik kijk enorm naar je op, je legt de lat steeds hoog – ook voor jezelf- maar dat heeft ervoor gezorgd dat je tot de top behoort. Je bent de afgelopen jaren een schitterende mentor voor me geweest en ik hoop nog zeer veel van je te mogen leren. Je gaf me de mogelijkheid en vrijheid om in het laboratorium mijn eigen weg in te slaan.

Ik herinner me het moment nog als gisteren dat Prof. Dr. Filip Rega me uitnodigde om een experiment te volgen in het laboratorium. Dat moment was de start van een bijzondere reis. De eerste stappen in proefdierexperimenten zette ik destijds in het animalium in de Minderbroederstraat of 'beneden' zoals dat heette. Stephanie en Tom, graag wil ik jullie nog eens bedanken om mij te helpen bij mijn eerste voorzichtige stapjes op dit pad. Uiteraard kan ik de rots in de branding David Celis niet vergeten. David bedankt voor al je hulp bij de experimenten, je mateloze toewijding, zorg voor de dieren maar ook voor de fijne babbel tijdens de experimenten en scans. Na de verhuis van het animalium naar 'boven' of dus op de site van Gasthuisberg, kreeg ik het kans om samen te mogen werken met Mieke Ginckels en Nina Vandendriessche. Mieke en Nina, woorden schieten te kort om jullie te bedanken voor al jullie werk de afgelopen jaren. De steeds feilloze planning, hulp tijdens de experimenten en de toegewijde zorg voor de dieren is van een onmeetbaar hoog niveau. Zonder jullie was dit echt onmogelijk geweest.

Gezien ik geen chirurg ben – twee linker handen laat ons zeggen - kon ik gelukkig wel rekenen op enkele zeer enthousiaste maar vooral ook zeer handige chirurgen. Joeri Van Puyvelde, Katrien Vandendriessche en Shota Yasuda een oprechte dank voor al jullie hulp en de fijne samenwerking. Doumo arigatou gozaimasu.
Graag wil ik Ariane Paps danken om ons destijds uit de nood te helpen met het gipsverband van een onfortuinlijk schaap, beter bekend als Olaf.

Graag wil ik ook Prof. Dr. Karin Sipido en Dr. Chandan Kadur Nagaraju bedanken voor hun expertise, histologische analyses en hun kritische inzichten in het project en manuscript.

Een speciaal woord van dank voor Prof. Dr. Piet Claus. Beste Piet vooreerst enorm bedankt voor het uitvoeren van de talloze scans. Je was altijd bereid en steeds beschikbaar. Je leerde me de scans ook analyseren en hielp me telkens uit de nood als ik weer eens vastliep. Ik kan je ook niet genoeg bedanken voor je kritisch inzicht in het hele project, het manuscript, maar vooral voor je hulp de aflopen jaren. Hopelijk volgt er nog veel samenwerking in diverse wetenschappelijke projecten.

Filip, jaren geleden nam je me mee op sleeptouw en daar ben ik je eeuwig dankbaar voor. Ik zal de vele momenten dat we samen op het labo gezwoegd hebben, nooit vergeten. We deelden momenten van euforie bij een geslaagd experiment, maar verteerden ook de moeilijke momenten wanneer het minder vlot liep. Ik wil je bedanken voor de ontelbare tijd en bergen energie die je de afgelopen jaren in me hebt gestopt. Je leerde me kritisch denken. Je hebt een gave om mensen te inspireren en te laten groeien. Ik hoop dat we nog aan veel projecten samen mogen werken en kijk met plezier uit naar de toekomst.

A special word for Prof. Dr. Stephen Brown from the University of Bloemfontein, South Africa. Dear Stephen, I sincerely want to thank you for the cooperation on scientific level over the years. Your visits to our hospital were always a pleasure and honour. I am looking forward for joint projects and hopefully we can meet again in the near future.

Catheterisatie is een team gebeuren. Het team van congenitale catheterisatie van UZ Leuven is er een om zeer trots op te zijn en ik ben dan ook zeer vereerd om er deel van te mogen uitmaken. Een dikke merci aan Amber, Anja, Guy, Ines, Ingrid, Jolien, Nathalie, Pieter en Ann die spijtig genoeg ondertussen niet meer op catheterisatie werkt. Jullie inzet en toewijding kent geen grens, zonder jullie zou dit programma niet mogelijk zijn. Ook een oprechte dank aan het anesthesie team van Prof. Dr. Marc Van de Velde, vooral Sarah en Frederik genieten een bijzonder woord van dank voor jullie inzet en flexibiliteit de afgelopen jaren.

Twee fantastische dames die ik niet mag vergeten te bedanken zijn Astrid en Andrea. Steevast zorgen jullie dat de raadplegingen in goede banen worden geleid en vangen jullie bergen telefoons en mails op. Hartelijk dank voor al jullie werk de afgelopen jaren.

Het hele verhaal zou nooit begonnen zijn, zonder dat ik van mijn ouders de kans kreeg om geneeskunde te mogen studeren. Er zijn geen woorden mooi genoeg om jullie te bedanken dat jullie me die kans hebben geboden. Vake, spijtig genoeg heb je ons veel te vroeg moeten verlaten en kan je dit moment niet meer meemaken. Ik draag dit dan ook speciaal op aan jou.

Hannah, Jolien en Lise, onze drie prachtige madammen. Ik ben super fier om jullie papa te mogen zijn. Hopelijk moet het zinnetje ‘moet papa nu weer naar het werk’ de komende jaren iets minder te worden uitgesproken.
Mieke, vanaf de eerste seconden dat ik je leerde kennen, wist ik dat je een sterke vrouw bent. Je toonde de afgelopen jaren eindeloos begrip voor al die momenten dat ik nog aan het werk was of terug naar het werk diende te gaan. Ik kan jullie en vooral jou daar niet genoeg voor bedanken. Ik zeg het

veel te weinig: onze dochters hebben een prachtige mama, ik heb de liefste echtgenote, kortom je bent een prachtvrouw. Mogen we nog jaren samen genieten van ons leuk hecht gezinnetje en ik kijk er naar uit om zodra het nog eens kan van een welverdiende vakantie te genieten.

Allicht ben ik mensen vergeten te bedanken, dat is zeker niet met opzet en daarom een algemene en vooral welgemeende dankjewel.

Bjorn

CURRICULUM VITAE

PERSONAL DATA

Name	Cools Bjorn Leo Maria
Birth date	February 13th, 1977 in Rumst (Belgium)
Marital state	married to Boon Mieke
Children	Hannah, Jolien and Lise
E-mail	bjorn.cools@uzleuven.be

PROFESSIONAL ACTIVITY

- Consultant Pediatric and Congenital Cardiology
  University Hospital Leuven
  Herestraat 49
  B-3000 Leuven
  Belgium

- Part-time PhD student
  Catholic University Leuven, department of cardiovascular sciences
  Project entitled "Timing of Pulmonary Valve replacement in Tetralogy of Fallot"
  Under supervision of Prof. Dr. Marc Gewillig, Prof. Dr. Filip Rega and Prof. Dr. Piet Claus

EDUCATION AND TRAINING

1989-1995	High School, Latin-Greek, Onze-Lieve-Vrouwe College, Boom, Belgium.
1995-2002	Medicine, University of Antwerp, Belgium. Summa cum laude.
2002-2007	Pediatrics, University of Antwerp, Belgium.
2007-2010	Fellowship Pediatric and Congenital Cardiology - University of Antwerp and Ghent, Belgium. - University of Rotterdam, Erasmus MC, Rotterdam, The Netherlands.
2016	Observership Pediatric Heart Transplantation, Sick Kids, Toronto, Canada

ADDITIONAL COURSES AND TRAINING

- ECG course University of Antwerp, Belgium. (1999)
- Radiation expert level 4A/M, University of Leiden, The Netherlands. (2010)
- Pediatric Interventional Cardiology Fellow course (SCAI), Las Vegas, US. (2010)
- Radioprotection and dosimetry, Catholic University Leuven, Belgium. (2013)
- Laboratory Animal Science – FELASA B, Catholic University Leuven, Belgium. (2016)

AWARDS AND GRANTS

- Clinical pre-doctoral scholarship FWO (Fonds Wetenschappelijk Onderzoek) Flanders Belgium. (2012)
- Clinical Research Fund (KOF) Leuven, Belgium. (2014)
- Research grant Cardiac Surgery Foundation, Brussels, Belgium. (2014)

- Research grant Medtronic, US. (2016)
-The Association for European Paediatric and Congenital Cardiology (AEPC) meeting in Lyon 2017 Prize Best oral abstract : Successful creation of an ovine pulmonary stenosis-regurgitation model simulating a Tetralogy of Fallot.

-The Association for European Paediatric and Congenital Cardiology (AEPC) meeting in Sevilla 2019 Prize: Best Moderated Poster: A chronic preload reduction animal (ovine) model: acute effects of reloading.

PROFESSIONAL MEMBER OF

- Ordinary member of the Belgian Association of Paediatrics. (BVK-SBP)

- Ordinary member of The Association of European Paediatric Cardiology. (AEPC)

- Ordinary member at the Society for Cardiovascular Angiography and Interventions. (SCAI)

LIST OF PUBLICATIONS

1. Pulmonary Vascular Reserve in Fontan Patients: Looking Upstream for the True Heart of the Matter. Gewillig M, **Cools B**, Van De Bruaene A. J Am Coll Cardiol. 2020 Dec 8;76(23):2764-2767
2. Infective endocarditis in patients after percutaneous pulmonary valve implantation with the stent-mounted bovine jugular vein valve: Clinical experience and evaluation of the modified Duke criteria. Bos D, De Wolf D, **Cools B**, Eyskens B, Hubrechts J, Boshoff D, Louw J, Frerich S, Ditkowski B, Rega F, Meyns B, Budts W, Sluysmans T, Gewillig M, Heying R. Int J Cardiol. 2020 Aug 26:S0167-5273(20)33641
3. Can ductus arteriosus morphology influence technique/outcome of stent treatment? Roggen M, **Cools B**, Brown S, Boshoff D, Heying R, Eyskens B, Gewillig M. Catheter Cardiovasc Interv. 2020 Jan 17.
4. Effect of xenon and dexmedetomidine as adjuncts for general anesthesia on postoperative emergence delirium after elective cardiac catheterization in children: study protocol for a randomized, controlled, pilot trial. Devroe S, Devriese L, Debuck F, Fieuws S, **Cools B**, Gewillig M, Van de Velde M, Rex S. Trials. 2020 Apr 3;21(1):310.
5. Percutaneous embolization of lymphatic fistulae as treatment for protein-losing enteropathy and plastic bronchitis in patients with failing Fontan circulation. Maleux G, Storme E, **Cools B**, Heying R, Boshoff D, Louw JJ, Frerich S, Malekzadeh-Milanii S, Hubrechts J, Brown SC, Gewillig M. Catheter Cardiovasc Interv. 2019 Dec 1;94(7):996-1002.
6. Pulmonary endarterectomy in a 12-year-old boy with multiple comorbidities. Verbelen T, **Cools B**, Fejzic Z, Van Den Eynde R, Maleux G, Delcroix M, Meyns B. Pulm Circ. 2019 Nov 7;9(4):2045894019886249
7. First report of a successful pediatric heart transplantation from donation after circulatory death with distant procurement using normothermic regional perfusion and cold storage. Tchana-Sato V, Ledoux D, Vandendriessche K, Van Cleemput J, Hans G, Ancion A, Cools B, Amabili P, Detry O, Massion PB, Monard J, Delbouille MH, Meyns B, Defraigne JO, Rega F. J Heart Lung Transplant. 2019 Oct;38(10):1112-1115
8. The long-term outcome of an isolated vascular ring - A single-center experience.Depypere A, Proesmans M, **Cools B**, Vermeulen F, Daenen W, Meyns B, Rega F, Boon M. Pediatr Pulmonol. 2019 Aug 27.

9. Percutaneous obliteration of the right ventricle to avoid coronary damage by sinusoids in patients with pulmonary atresia intact ventricular septum during staged single ventricle palliation. Hubrechts J, **Cools B**, Brown SC, Eyskens B, Heying R, Boshoff D, Gewillig M. Catheter Cardiovasc Interv. 2019 Aug 21.
10. 238th ENMC International Workshop: Updating management recommendations of cardiac dystrophinopathyHoofddorp, The Netherlands, 30 November - 2 December 2018. Bourke JP, Guglieri M, Duboc D; ENMC 238th Workshop Study Group. Neuromuscul Disord. 2019 Jul 1. pii: S0960-8966(19)30374-8.
11. Vasoreactive pulmonary arterial hypertension manifesting with misleading epileptic seizure: Diagnostic and treatment pitfalls., by Nesrine FARHAT, **Bjorn Cools**, Marc Gewillig, Marie-Christine Seghaye, Yacine Aggoun, Maurice Beghetti, Front. Pediatr., 04 July 2019 |
12. Creation of the Fontan circulation in sheep: a survival model. Van Puyvelde J, Rega F, Minami T, Claus P, **Cools B**, Gewillig M, Meyns B. Interact Cardiovasc Thorac Surg. 2019 Jul 1;29(1):15-21.
13. Clinical Characteristics of Infective Endocarditis in Children. Kelchtermans J, Grossar L, Eyskens B, **Cools B**, Roggen M, Boshoff D, Louw J, Frerich S, Veloso TR, Claes J, Ditkowski B, Rega F, Meyns B, Gewillig M, Heying R. Pediatr Infect Dis J. 2019 May;38(5):453-458.
14. Adverse outcome of coarctation stenting in patients with Turner syndrome. **Cools B**, Brown S, Gewillig M. Catheter Cardiovasc Interv. 2018 Sep 1;92(3):E212-E213. doi: 10.1002/ccd.27060. Epub 2017 May 8.
15. Cardiac outcome in classic infantile Pompe disease after 13 years of treatment with recombinant human acid alpha-glucosidase. van Capelle CI, Poelman E, Frohn-Mulder IM, Koopman LP, van den Hout JMP, Régal L, **Cools B**, Helbing WA, van der Ploeg AT. Int J Cardiol. 2018 Oct 15;269:104-110
16. Up to 11 years of experience with the Melody valved stent in the right ventricular outflow tract. **Cools B**, Brown S, Budts W, Heying R, Troost E, Boshoff D, Eyskens B, Gewillig M. EuroIntervention. 2018 Oct 12;14(9):e988-e994
17. A custom-made percutaneous flow-restrictor to manage a symptomatic congenital porto-systemic shunt in an infant. Roggen M, **Cools B**, Maleux G, Gewillig M. Catheter Cardiovasc Interv. 2018 May 4. Postoperative left ventricular function in different types of pulmonary hypertension: a comparative study. Verbelen T, Van De Bruaene A, Cools B, Van Raemdonck D, Delcroix M, Rega F, Meyns B. Interact Cardiovasc Thorac Surg. 2018 Jan 2.
18. Right ventricle outflow tract prestenting: In vitro testing of rigidity and corrosion properties. **Cools B**, Brown S, Wevers M, Humbeeck JV, Boshoff D, Verdonckt C, Gewillig M. Catheter Cardiovasc Interv. 2017 Sep 12. doi: 10.1002/ccd.27320. [Epub ahead of print]
19. Xenon as an adjuvant to sevoflurane anesthesia in children younger than 4 years of age, undergoing interventional or diagnostic cardiac catheterization: A randomized controlled clinical trial. Devroe S, Meeusen R, Gewillig M, **Cools B**, Poesen K, Sanders R, Rex S. Paediatr Anaesth. 2017 Sep 5.
20. Dysfunction of the foetal arterial duct results in a wide spectrum of cardiovascular pathology. Gewillig M, Brown SC, Roggen M, Eyskens B, Heying R, Givron P, **Cools B**, de Catte L. Acta Cardiol. 2017 Jul 26:1-11. doi: 10.1080/00015385.2017.1314876. [Epub ahead of print]
21. Radiofrequency perforation of the pulmonary valve: an efficient low cost solution. Brown SC, **Cools B**, Boshoff D, Heying R, Eyskens B, Gewillig M. Acta Cardiol. 2017 Aug;72(4):419-424.
22. Percutaneous intervention for central shunts: new routes, new strategies. **Cools B,** Brown SC, Boshoff DE, Eyskens B, Heying R, Rega F, Meyns B, Gewillig M. Acta Cardiol. 2017 Apr;72(2):142-148.
23. Right ventricular remodelling after transcatheter pulmonary valve implantation.. Pagourelias ED, Daraban AM, Mada RO, Duchenne J, Mirea O, **Cools B,** Heying R, Boshoff D, Bogaert J, Budts W, Gewillig M, Voigt JU. Catheter Cardiovasc Interv. 2017 Mar 15.
24. A rare cause of persisting anaemia in a patient with a failing Fontan circulation. Lambrecht L, **Cools B**, Witters P. Cardiol Young. 2017 Jan;27(1):176-177.

25. Transhepatic implant of a trimmed Melody™ valved stent in tricuspid position in a 1-year-old infant. **Cools B,** Rega F, Gewillig M. Catheter Cardiovasc Interv. 2017 Feb 15;89(3):E84-E89.
26. Bailout shunt/banding for backward left heart failure after adequate neonatal coarctectomy in borderline left hearts. Brown SC, Eyskens B, Boshoff D, **Cools B,** Heying R, Rega F, Meyns B, Gewillig M. Interact Cardiovasc Thorac Surg. 2016 Dec;23(6):929-932.
27. Cracking a tricuspid perimount bioprosthesis to optimize a second transcatheter sapien valve-in-valve placement. Brown SC, **Cools B**, Gewillig M. Catheter Cardiovasc Interv. 2016 Mar 25.
28. Can a volume challenge pinpoint the limiting factor in a Fontan circulation? De Mey W, **Cools B**, Heying R, Budts W, Louw JJ, Boshoff DE, Brown SC, Gewillig M. Acta Cardiol. 2015 Oct;70(5):536-42.
29. Design and feasibility of "PREMATurity as predictor of children's Cardiovascular-renal Health" (PREMATCH): A pilot study. Raaijmakers A, Petit T, Gu Y, Zhang Z, Wei F, **Cools B**, Jacobs L, Thijs L, Thewissen L, Levtchenko E, Staessen JA, Allegaert K. Blood Press. 2015 Jun 24:1-9.
30. Medium Term follow-up after percutaneous pulmonary valve replacement with the Melody valve. Bjorn Cools, Werner Budts, Ruth Heying, Derize Boshoff, Benedicte Eyskens, Stefan Frerich, Els Troost, Marc Gewillig, Int J Cardiol Heart&Vasculature, 2015 march 7:92-97
31. Percutaneous pulmonary valve implantation for free pulmonary regurgitation following conduit-free surgery of the right ventricular outflow tract. **Cools B**, Brown SC, Heying R, Jansen K, Boshoff DE, Budts W, Gewillig M. Int J Cardiol. 2015 May 1;186:129-35.
32. Flow reduction of a neonatal stented arterial duct by covered coronary stent. Demir F, **Cools B**, Gewillig M. Catheter Cardiovasc Interv. 2015 Jan 19.
33. Infective endocarditis of a transcatheter pulmonary valve in comparison with surgical implants. Van Dijck I, Budts W, **Cools B**, Eyskens B, Boshoff DE, Heying R, Frerich S, Vanagt WY, Troost E, Gewillig M. Heart. 2015 May 15;101(10):788-93.
34. 20 years of arterial switch operation for simple TGA. De Praetere H, Vandesande J, Rega F, Daenen W, Marc G, Eyskens B, Heying R, **Cools B**, Meyns B. Acta Chir Belg. 2014 Mar-Apr;114(2):92-8.
35. Use of covered Cheatham-Platinum stents in congenital heart disease. Vanagt WY, **Cools B**, Boshoff DE, Frerich S, Heying R, Troost E, Louw J, Eyskens B, Budts W, Gewillig M. Int J Cardiol. 2014 Jul 15;175(1):102-7.
36. Neonatal circulatory failure due to acute hypertensive crisis: clinical and echocardiographic clues. Louw J, Brown S, Thewissen L, Smits A, Eyskens B, Heying R, **Cools B**, Levtchenko E, Allegaert K, Gewillig M. Cardiovasc J Afr. 2013 Apr;24(3):72-5.
37. Delivering stents in congenital heart disease using the double wire technique: Technical considerations. Brown SC, **Cools B**, Boshoff DE, Ozbarlas N, Heying R, Budts W, Buys D, Gewillig M. Catheter Cardiovasc Interv. 2013 Apr 16.
38. Treatment strategies for pulmonary sequestration in childhood : resection, embolization, observation ? Brown SC, De Laat M, Proesmans M, De Boeck K, Van Raemdonck D, Louw J, Heying R, **Cools B**, Eyskens B, Gewillig M Acta Cardiol 2012;67(6):629-634.
39. When coronary arteries need systolic pressure: surgical considerations. **Cools B**, Brown SC, Sluysmans T, Dewolf D, Dessy H, Gewillig M. Eur J Cardiothorac Surg. 2012 Oct 24.
40. Mechanism of autograft insufficiency after the Ross operation in children. Goda M, Gewillig M, Eyskens B, Heying R, **Cools B**, Rega F, Meyns B. Cardiol Young. 2012 Oct 31:1-7.
41. Pulmonary Artery Banding as 'open end' palliation of Systemic Right Ventricles : an interim Analysis. **Cools B**, Brown SC, Louw JJ, Heying R, Meyns B, Gewillig M. Eur J Cardiothoracic Surg 2012 Apr; 41(4):913-8.
42. Off-label use of percutaneous pulmonary valved stents in the right ventricular outflow tract: Time to rewrite the label? Boshoff D, **Cools B**, Heying R, Troost E, Kefer J, Budts W, Gewillig M. Catheter Cardiovasc Interv. 2012 Aug 6.
43. Transventricular Balloon dilation and Stenting of the RVOT in Small Infants with Tetralogy of Fallot and Pulmonary Atresia. **Cools B**, Boshoff D, Heying R, Eyskens B, Rega F, Meyns B, Gewillig M. Catheter Cardiovasc Interv 20122012 Jun 29.

44. Hybrid Stenting of Aortic Coarctation in Very Low Birth Weight Infant. **Cools B**, Meyns B, Gewillig M. Catheter Cardiovasc Interv. 2012 Mar 19.
45. Neonatal Circulatory Failure due to Acute Hypertensive Crisis : Clinical and Echocardiographic clues. Louw JJ, Brown SC, Thewissen L, Smits A, Eyskens B, Heying R, **Cools B**, Levtchenko E, Allegaert K, Gewillig M. In review at Arch Dis Childhood
46. Boys with a simple delayed puberty reach their target height. **Cools B.L.M.,** Rooman R.. Op De Beeck L., Du Caju M.V.L. Horm Res. 2008;70(4):209-14. Epub 2008 Sep 5.
47. Unsuccesful Resuscitation of a Preterm Infant Due to a Pneumothorax and a Masked Tension Pneumopericardium. **Cools B**, Plaskie K, Van de Vijver K, Suys B Resuscitation. 2008 Aug;78(2):236-9.
48. From typical pneumonia to atypical Kawasaki disease. Gerard I, **Cools B**, Van Neste E, Wojciechowski M, Suys B, Ramet J. Tijdschrift voor Geneeskunde Vol 64 (7) 348-51. 2008