AMERICAN SOCIETY OF® TRANSPLANTATION

COMPREHENSIVE TRAINEE CURRICULUM

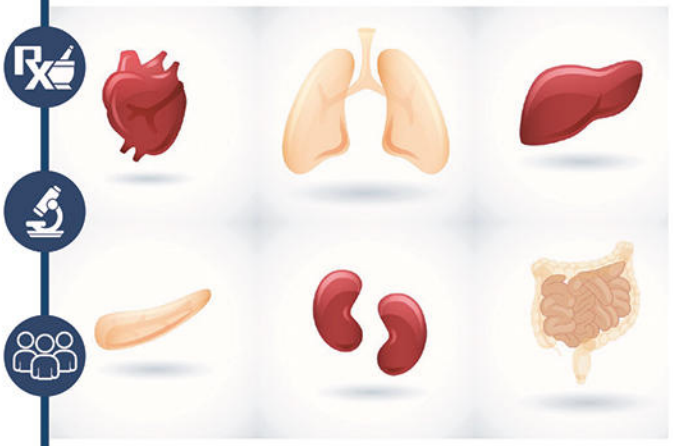

COMPREHENSIVE TRAINEE CURRICULUM

WATCH 52 ONLINE LESSONS INCLUDING:

- *Adult and Pediatric Liver*
- *Adult Cardiac and Pulmonary*
- *Abdominal Transplant Surgery*
- *Cardiothoracic Transplant Surgery*
- *Adult and Pediatric Kidney*
- *Transplant Pharmacy*

Solid organ transplantation is a multidisciplinary field, leading to a diverse community of professionals within the AST. As a result, it is often necessary for trainees to have extensive knowledge of all areas of transplantation—not just their specialty.

Check out this brand new resource, meant to supplement the training trainees and fellows receive at their university or hospital.

$50 members / $200 non-members

AMERICAN SOCIETY OF TRANSPLANTATION

Received: 8 May 2018 | Revised: 28 June 2018 | Accepted: 12 July 2018

DOI: 10.1111/ajt.15029

CASE REPORT

Allogeneic HSCT transfers wild-type cystinosin to nonhematological epithelial cells in cystinosis: First human report

Mohamed A. Elmonem[1,2] | Koenraad Veys[1] | Fanny Oliveira Arcolino[1] | Maria Van Dyck[1] | Maria C. Benedetti[3] | Francesca Diomedi-Camassei[3] | Gert De Hertogh[4] | Lambertus P. van den Heuvel[1,5] | Marleen Renard[6] | Elena Levtchenko[1]

[1]Department of Pediatric Nephrology & Development and Regeneration, University Hospitals Leuven, KU Leuven – University of Leuven, Leuven, Belgium

[2]Department of Clinical and Chemical Pathology, Faculty of Medicine, Cairo University, Cairo, Egypt

[3]Department of Laboratories, Pathology Unit, Bambino Gesù Children's Hospital, IRCCS, Rome, Italy

[4]Department of Translational Cell and Tissue Research, KU Leuven – University of Leuven, Leuven, Belgium

[5]Department of Pediatric Nephrology, Radboud University Medical Center, Nijmegen, the Netherlands

[6]Department of Pediatric Hematology and Oncology, KU Leuven – University of Leuven, Leuven, Belgium

Correspondence: Elena Levtchenko, Department of Pediatric Nephrology & Development and Regeneration, University Hospitals Leuven, KU Leuven. UZ Herestraat 49, Box 817-3000 Leuven, Belgium
Email: elena.levtchenko@uzleuven.be

Funding information
Fonds Wetenschappelijk Onderzoek, Grant/Award Number: 11Y5216N and 1801110N; University of California

Cystinosis is an autosomal recessive lysosomal storage disorder characterized by the defective transport of the amino acid cystine out of the lysosome due to a deficiency of cystinosin, the lysosomal cystine transporter. Patients have lysosomal cystine accumulation in various tissues, leading to cellular stress and damage, particularly in the kidney, cornea, and other extrarenal tissues. Cysteamine, a cystine-depleting agent, improves survival and delays the progression of disease, but it does not prevent the development of either renal failure or extrarenal complications. Furthermore, the drug has severe adverse effects that significantly reduce patient compliance. Allogeneic hematopoietic stem cell transplantation (HSCT) is currently established as a therapeutic option for many inborn errors of metabolism, where the main pathologic driving factor is an enzyme deficiency. Recent studies in the cystinosis mouse-model suggested that HSCT could be a curative treatment alternative to cysteamine therapy. We treated a 16-year-old boy who had infantile cystinosis and side effects of cysteamine therapy with HSCT. We were able to demonstrate successful transfer of the wild-type cystinosin protein and *CTNS* mRNA to nonhematological epithelial cells in the recipient, as well as a decrease in the tissue cystine-crystal burden. This is the first report of allogeneic HSCT in a patient with cystinosis, the prototype of lysosomal membrane-transporter disorders.

KEYWORDS
bone marrow/hematopoietic stem cell transplantation, clinical research/practice, genetics, graft-versus-host disease (GVHD), immunohistochemistry, kidney disease: metabolic, molecular biology: mRNA/mRNA expression, pediatrics, translational research/science

1 | INTRODUCTION

Cystinosis (MIM 219800) is a lysosomal storage disorder (LSD) caused by bi-allelic mutations in the *CTNS* gene (17p13.2) encoding the lysosomal membrane cystine/proton cotransporter cystinosin.[1] Cystinosis is characterized by lysosomal cystine accumulation and crystallization, and manifests clinically with severe polyuria and loss of a diverse range of substances normally reabsorbed in

Abbreviations: ALD, adrenoleukodystrophy; ATG, anti-thymocyte globulin; ESRD, end-stage renal disease; GVHD, graft-versus-host disease; HSCT, hematopoietic stem cell transplantation; IEMs, inborn errors of metabolism; LSDs, lysosomal storage disorders; MPS, mucopolysaccharidosis.

Mohamed A. Elmonem and Koenraad Veys contributed equally as first authors. Marleen Renard and Elena Levtchenko contributed equally as senior authors.

© 2018 The American Society of Transplantation and the American Society of Transplant Surgeons

the kidney proximal tubules (renal Fanconi syndrome), leading to end-stage renal disease (ESRD) during childhood or early adolescence. Extrarenal manifestations include photophobia, retinopathy, endocrine dysfunction (hypothyroidism, endocrine pancreatic insufficiency, hypogonadism), peripheral myopathy, and central nervous system complications, which mostly develop during the second and third decades of life.[1,2] In cystinosis patients, phagocytic cells, such as blood granulocytes and bone marrow and tissue macrophages, accumulate large amounts of cystine due to their phagocytic nature and their inability to process the phagocytized crystals.[3,4] The only available treatment for cystinosis is the cystine-depleting amino thiol cysteamine. However, this drug does not prevent progressive disease, but merely postpones the development of ESRD and extrarenal complications.[2] Moreover, cysteamine has numerous side effects that severely limit patient compliance.[5–7]

Allogeneic hematopoietic stem cell transplantation (HSCT) has been established as a successful therapy for not only hereditary hematological disorders, but also for inborn errors of metabolism (IEMs), including many LSDs.[8,9] The first case of a successful bone marrow transplantation in a lysosomal disorder dates back to 1981 in a child affected by Hurler syndrome, or mucopolysaccharidosis type-1 (MPS1).[10] Since then, thousands of children have received HSCT as a therapeutic modality for LSDs, including other MPS syndromes, such as metachromatic leukodystrophy, Gaucher, Niemann-Pick A/B, α-mannosidosis, and many others.[8] However, the basic concept behind allogeneic HSCT in all these disorders is to replace the production of a deficient enzyme caused by the genetic defect of each LSD. The only IEM in which HSCT has been established as a therapy for a transporter deficiency is the peroxisomal disorder adrenoleukodystrophy (ALD). Allogeneic HSCT can reverse demyelination and progression of neurological symptoms when performed early in ALD, but the mechanism of action of HSCT is not clear, and the disease lacks an established animal model.[11,12]

The Cherqui group showed that in the cystinosis (*Ctns*$^{-/-}$) mouse model, HSCT significantly decreased cystine accumulation in different organs, preserved kidney function, and reversed extrarenal organ damage.[13–16] They demonstrated the in situ differentiation of stem cells to tissue macrophages within target organs, which transferred cystinosin-bearing lysosomes to adjacent deficient cells via tunneling nanotubes.[17] The paracrine release of cellular microvesicles containing *CTNS* mRNA and protein has also been suggested as another potential mechanism of action.[18] Strikingly, similar beneficial effects of HSCT have been demonstrated in a mouse model of Dent disease, a nonlysosomal proximal tubular disorder presenting with renal Fanconi syndrome, and caused by the defective function of endosomal chloride-proton exchanger.[19] These animal studies provide the proof of concept for a beneficial effect of HSCT in hereditary diseases, where the defective proteins are endosomal or lysosomal membrane transporters, rather than enzymes. Here, we present a case of an adolescent male who had severe infantile cystinosis and who underwent HSCT.

2 | CASE REPORT

We treated a 16-year-old white boy, who was diagnosed with cystinosis at the age of 2.7 years and was started on cysteamine treatment at that time. DNA analysis demonstrated compound heterozygous mutations in the *CTNS* gene: 57-kb deletion and c.926dup (p.Ser310fs*55). At the age of 15, he developed signs of cysteamine toxicity, with cutaneous lesions at the level of lumbar vertebrae and bone lesions (cervical vertebrae, femur and tibia, overgrowth of rib cartilage) due to ongoing renal Fanconi syndrome associated with therapy-resistant copper deficiency.[7] Moreover, he had severe psychological and social problems due to cysteamine-induced halitosis.[5] The patient was subsequently referred to the bone marrow transplantation program at the University Hospitals Leuven. A family conference was held to discuss the potential risks and benefits of HSCT, and both the patient and his parents consented to this treatment option. The procedure was approved by the Institutional Ethical Board at University Hospitals Leuven in December 2012.

At the age of 16, the patient underwent allogeneic HSCT from a fully HLA-matched (10/10) unrelated donor using mobilized peripheral blood stem cells. Cysteamine treatment was discontinued 2 months before transplantation. Pretransplant myeloablative conditioning consisted of treosulfan (14 g/m^2 per day from day -7 to day -5), fludarabine (30 mg/m^2 per day from day -7 to day -3), thiotepa (10 mg/kg on day -4), and anti-thymocyte globulin (ATG) (2.5 mg/kg from day -3 to day -1). At the time of transplantation, the patient received 7.88 × 10^6 CD34-positive cells/kg and 166 × 10^6 CD3-positive T cells/kg. For posttransplant graft-versus-host disease (GVHD) prophylaxis, tacrolimus (2 × 2 mg/d, target trough levels 5-10 ng/mL), mycophenolate mofetil (3 × 915 mg/d), and methotrexate (15 mg/m^2 on day 1 and 10 mg/m^2 on days 3, 6, and 11) were administered. Filgrastim (300 μg/d) was also given on days 16, 17, and 19, and neutrophil engraftment was evident on day 22 post-HSCT (day 21: 1020 neutrophils/mm^3 and day 22: 1300 neutrophils/mm^3). Full donor chimerism (>95%) was demonstrated in the bone marrow at days 142 and 184 post-HSCT, and in the peripheral blood at days 28, 62, 107, 323, 400, and 462.

The early posttransplant period was complicated by an acute GVHD (grade III-IV) and adenovirus reactivation presenting with fever and profound diarrhea during the third week post-HSCT. Treatment with cidofovir and systemic corticosteroids (methylprednisolone 2 mg/kg per day) was initiated. Response to corticosteroids was satisfactory after 5 days and the dose was tapered gradually. Due to persistently high adenovirus copy numbers and hypogammaglobulinemia, intravenous immunoglobulin was administered at day 36, and later, treatment with ganciclovir was initiated at day 65.

At day 25 posttransplant, the patient developed an altered level of consciousness, speaking and swallowing difficulties, a central facial nerve palsy, diplopia, ataxia, dysmetria, and hyperreflexia. Brain MRI demonstrated central pontine myelinolysis, which was thought to be caused by tacrolimus toxicity. Tacrolimus was therefore replaced with sirolimus. Sirolimus levels were closely monitored and kept within a safe therapeutic range (6-12 ng/mL). Further work-up

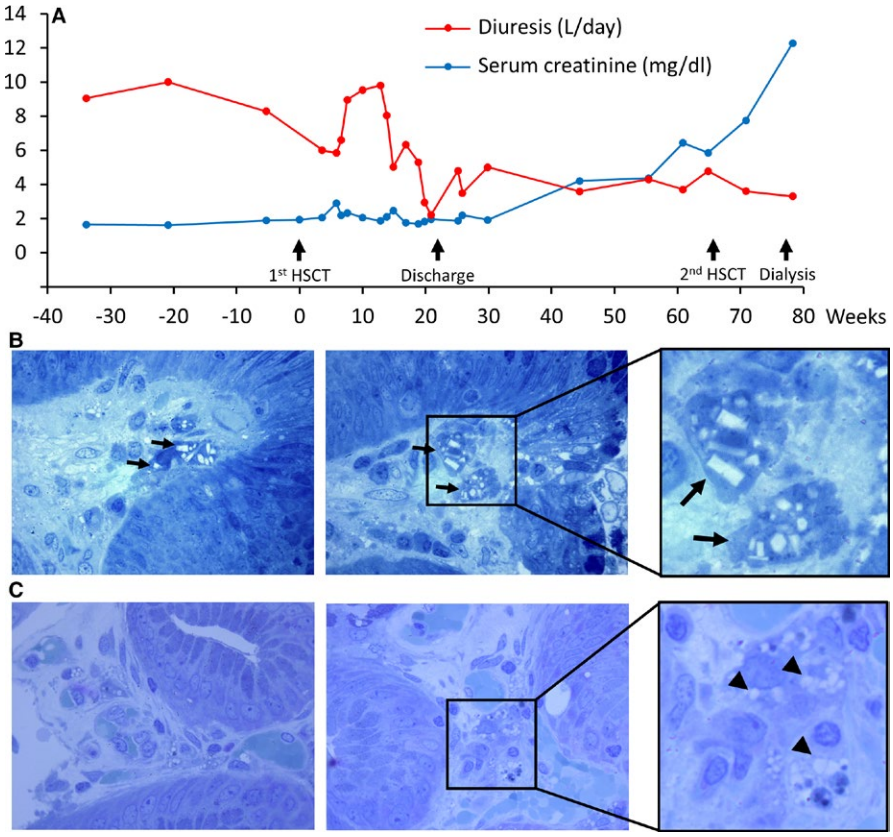

FIGURE 1 Evolution of kidney function and tissue cystine-crystal accumulation pre- and post-HSCT. A, Evolution of diuresis and serum creatinine before and after HSCT. B, Representative images of tissue cystine accumulation in gastric mucosal biopsy before transplantation. Numerous rhomboid and hexagonal cystine crystals are visible inside interstitial macrophages (arrows). The median number of cystine crystals per macrophage was 11.3 (range 7-16). C, Gastric mucosal biopsy 30 mo after transplantation showing macrophages with globular vacuoles (arrowheads). The median number of crystals per macrophage was 7.8 (range 4-13). Tissues were fixed in glutaraldehyde, prepared as 1-µm-thick sections, and stained with toluidine blue. Images were acquired using a Leica DM2000 LED microscope, Leica DFC290 HD camera, and LAS acquisition software (Leica microsystems) at a magnification of 1000×. HSCT, hematopoietic stem cell transplantation

did not reveal any evidence of infection in the cerebrospinal fluid. Subsequently a more severe pyramidal syndrome developed, for which treatment with levodopa (but not baclofen and diazepam) resulted in a gradual neurological recovery. However, subsequently the patient developed recurrent epileptic seizures and hallucinations associated with the administration of various drugs (calcineurin inhibitors, antiviral and antifungal agents), suggesting a possible disruption of the patient's blood–brain barrier.

Strikingly, within the first few months post-HSCT, the patient's kidney function stabilized and his polyuria resolved (Figure 1A). This suggested that HSCT had been efficacious in reducing his clinical symptoms of cystinosis. Pre-existing low molecular weight proteinuria and glucosuria were initially elevated posttransplant, but then decreased gradually to pre-HSCT levels after 6 months. The patient's photophobia score also improved over the first 6 months posttransplant from grade 5 to no photophobia. Stomach biopsies taken after transplantation also showed a significant decrease in cystine crystal accumulation (Figure 1B, C). Notably, peripheral white blood cell cystine levels dropped to the normal range as circulating blood cells differentiated from the healthy donor bone marrow cells.

Due to partial graft failure caused by a parvovirus B19 infection, a second HSC infusion from the same donor was administered 15 months after first HSCT, resulting in good reconstitution of the blood. The patient did not receive pretransplant conditioning or GVHD prophylaxis for the second HSC donation. Full donor chimerism (>95%) was also demonstrated in peripheral blood 140 days following the second donation. However, a severe therapy-resistant acute followed by chronic gastrointestinal, hepatic, and cutaneous GVHD developed, for which several immunosuppressive agents were used, including prednisolone, azathioprine, cyclosporine, ATG, and sirolimus. The severity scores for the liver, GI tract, and skin GVHD were grades 3, 3, and 2, respectively.[20] The kidney function gradually declined and the patient ultimately required chronic dialysis 18 months following initial HSCT. Unfortunately, 35 months after transplantation the patient developed a severe pneumonia due to a multiresistant *Pseudomonas* infection, and he succumbed to the disease.

To evaluate the long-term levels of the donor's mRNA in recipient tissues, we measured the percentage of expression of the wild-type (Wt) *CTNS* RNA in renal and liver cells 24 months after HSCT through reverse transcription, followed by next-generation sequencing (Figure 2A, B). To obtain renal cells devoid of hematopoietic elements, we isolated tubular epithelial cells from the patient's urine as described previously by our group.[21] In addition, we measured solid organ (liver) Wt *CTNS* RNA in a liver specimen, which was obtained from a biopsy performed to assess the patient's GVHD. We also used RNA isolated from tubular epithelial cells derived from the urine of the same patient prior to the transplantation and a healthy individual as negative and positive controls for the Wt *CTNS* sequencing, respectively. As expected, the healthy individual cDNA showed 100% Wt allele, while the pretransplanted patient cDNA showed 100% mutant allele. Interestingly, the cDNA derived from patient's tubular epithelial cells and liver biopsy 24 months post-HSCT showed incorporation of the Wt allele of 22% and 40%, respectively (Figure 2B). While Wt gene transfer has clearly occurred, the percentage of Wt allele may have been overestimated due to the potentially decreased mutant RNA stability caused by the nonsense-mediated mRNA decay.[22]

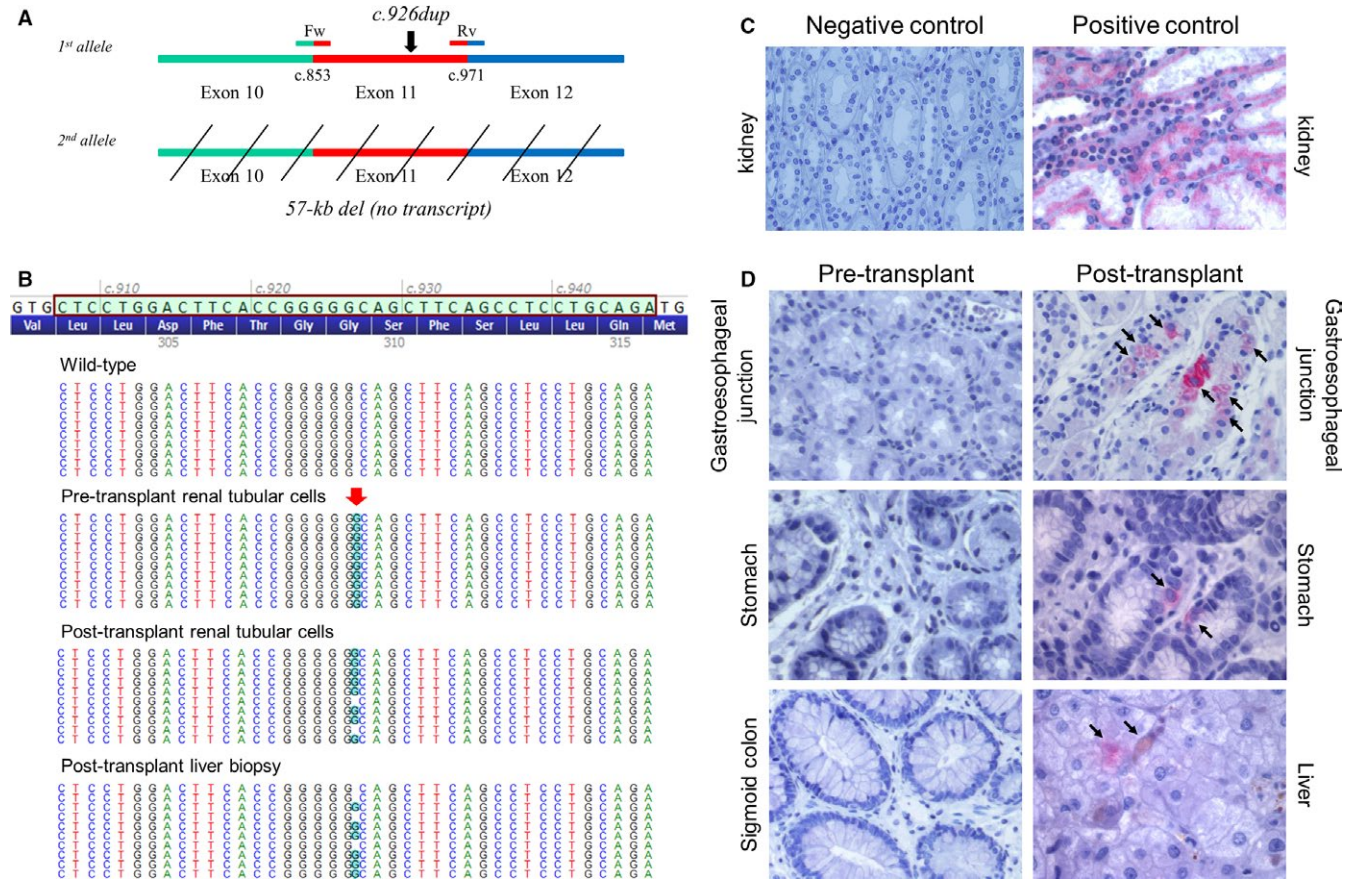

FIGURE 2 Next-generation sequencing (NGS) and cystinosin-LKG expression pre- and post-HSCT. A, Schematic representation of the primer design and the concept behind determining the percentage of the wild-type (Wt) allele incorporated in the posttransplant samples. The mutated cells are only represented by 1 allele, as the second allele is lacking a transcript due to the 57-kb deletion. B, NGS diagram showing only a representative coverage of 10× for each sample. Actual amplicon coverage by NGS was ≈100×. RNA isolation for renal tubular cells was performed using the RNeasy plus mini-kit (QIAGEN, Valencia, CA), while for the liver biopsy the TRIzol® reagent (Invitrogen, Waltham, MA) was used. RNA isolated from tubular epithelial cells derived from the pretransplanted patient and a healthy individual was used as negative and positive controls for the Wt *CTNS* sequence, respectively. cDNA was synthesized with the SuperScript III RT kit (Invitrogen, Waltham, MA). Polymerase chain reaction was performed in duplicate for all cDNA samples for the propagation of exons 11 harboring the location of the point mutation of the patient, c.926dup using the primers (Fw: 5′ - CCACAGGCCTACATGAACTT-3′, Rv: 5′ - TCCACTGGTCGTTGTTGTAG- 3′). NGS was performed using the MiSeq system platform (Illumina, San Diego, CA). The site of the point mutation (c.926dup) is marked by the red arrow. C, Immunohistochemical staining showing negative and positive controls for the cystinosin-LKG antibody. D, Immunohistochemical staining for cystinosin-LKG in different tissues of the patient before and 24 months (liver) or 30 months (stomach and gastroesophageal junction) after HSCT showing the expression in some epithelial cells. Immunostaining was according to the method of Taranta et al,[23] but antigen retrieval was performed at high pH9 (Dako). Images were acquired using a Zeiss AXIO Imager.A1 microscope, AxioCam MRc 5 camera, and AxioVision software (Zeiss). All images have a magnification of 400×, except stomach mucosa and liver tissue posttransplantation have a magnification of 630×. HSCT, hematopoietic stem cell transplantation

We further investigated the protein expression of cystinosin by immunohistochemistry in different tissues pre- and post-HSCT using antibodies against cystinosin-LKG, which is an isoform of cystinosin, resulting from an alternative splicing of exon 12 that removes the C-terminal GYDQL motif and replaces it with a string of 38 amino acids containing a "SSLK" domain that is strongly conserved among species.[23] At this time, no specific antibodies against conventional cystinosin isoform are available. Pretransplantation, the patient had no expression of cystinosin-LKG. This is due to 1 allele lacking the gene promotor needed for mRNA transcription (57-kb del) with the other allele having a frameshift mutation at AA-310 (p.Ser310fs*55), while the antiserum was directed against a cystinosin-LKG-specific sequence spanning amino acids 366-389.[23] Following HSCT, focal expression of the Wt cystinosin-LKG was evident in nonhematological epithelial cells in several organs, such as the esophagus, stomach, and liver up to 30 months posttransplant (Figure 2C, D).

3 | DISCUSSION

There are 3 major phenotypes for cystinosis. Infantile nephropathic cystinosis is the most severe type, and constitutes >95% of cases. This disease presents with renal impairment during the first year of life, and development of renal failure by the end of the first decade,

along with multiorgan damage. Few cystinosis patients present with juvenile nephropathic cystinosis, which is a milder form of the disease that induces renal injury at a later age. Thirdly is the ocular type, which manifests only with photophobia due to corneal cystine crystal deposition, and spares other organs.[1,2]

Our patient presented with typical infantile nephropathic cystinosis; however, he was diagnosed and started cysteamine therapy relatively late, at 2.7 years of age. Cysteamine efficiently decreases cystine content in lysosomes through direct biochemical interaction with cystine. While it delays the natural course of the disease, it unfortunately is not able to prevent many of the pathogenic aspects of cystinosis, including the Fanconi syndrome and the subsequent renal failure.[1,2] Furthermore, our patient experienced significant side effects of cysteamine therapy, including bone involvement and halitosis, which severely impacted him psychosocially.

Allogeneic HSCT has contributed substantially to the improved survival and quality of life in children affected by different IEMs.[8] Moreover, animal models of cystinosis provided the initial proof for the clinical benefits of HSCT. In the study by Syres et al,[13] organ-specific cystine content was reduced in all organs tested in cystinotic mice treated with Wt bone marrow. These organs included brain (57% reduction), eye (71%), heart (82%), kidney (70%), liver (95%), muscle (66%), and spleen (87%). Yeagy et al[16] further confirmed the long-term protection of HSCT for the mouse kidney up to 15 months posttransplant and showed that high-level donor-cell engraftment was essential for efficient therapy. In subsequent studies, HSCT in the cystinotic mouse protected against both eye pathology and hypothyroidism.[14,15]

Although our patient showed signs of clinical improvement of cystinosis (decreased polyuria and photophobia), he developed early signs of tacrolimus toxicity starting 4 weeks following the first HSCT. Similar cases with increased chances of nephrotoxicity and neurotoxicity may benefit from a calcineurin-free GVHD prophylaxis, such as the low-dose cyclophosphamide regimen.[24] Following the second HSC donation, our patient developed a severe form of GVHD, which did not respond to systemic corticosteroids, calcineurin inhibitors, or antimetabolites. Moreover, he developed seizures and hallucinations, due presumably to the administration of calcineurin inhibitors and other drugs. These complications combined with his subsequent systemic infection with a multidrug-resistant *Pseudomonas* led to his clinical deterioration, and ultimate demise. Despite this tragic outcome, this patient demonstrated clear reductions in the cystine crystal loads in mucosal interstitial macrophages in his stomach, as well as transfer of the Wt cystinosin RNA and protein to epithelial cells in multiple organs (GI tract, liver, and kidney), which together are indicative of the potential efficacy of HSCT in the treatment of cystinosis.

In conclusion, this is the first report describing allogeneic HSCT in a human patient with cystinosis, a lysosomal membrane transporter deficiency. This study broadens the spectrum of genetic diseases that may benefit from HSCT in clinical practice, and validates a novel mechanism of function of HSCs in hereditary metabolic disorders beyond simple compensation for enzyme deficiencies. However, this case history also highlights that the potential benefits of allogeneic HSCT should be carefully balanced against its risks and potential mortality. In our study, the expression of the Wt allele in the recipient's nonhematological epithelial cells with the subsequent decrease in cystine crystal accumulation, resolution of photophobia, and reduction in urinary output demonstrates that the *CTNS* donor-recipient gene and protein transfer does indeed occur, and that it can be functional in humans.

Similar to ALD, and other monogenic diseases, such as different forms of severe combined immune deficiency, thalassemia, and MPS,[25,26] the feasibility and efficacy of autologous HSCT following ex vivo gene therapy should be explored in cystinosis in future studies to avoid the risks associated with allogeneic HSCT.

ACKNOWLEDGMENTS

The authors thank Stephanie Cherqui (Department of Pediatrics, University of California, San Diego, La Jolla, CA, USA) for the critical revision of the manuscript. We are also grateful to Francesco Emma (Division of Nephrology, Department of Pediatric Subspecialties, Bambino Gesù Children's Hospital, Rome, Italy) for insightful discussion and kind help. M.A.E. is supported by ERA-Net, E-Rare2-JTC2014: Novel therapies for cystinosis. K.V. is supported by the Research Foundation - Flanders (F.W.O. Vlaanderen), grant 11Y5216N. E.L. is supported by F.W.O. Vlaanderen, grant 1801110N, and the Cystinosis Research Network (CRN) and Cystinosis Research Foundation (CRF).

DISCLOSURE

The authors of this manuscript have no conflicts of interest to disclose as described by the *American Journal of Transplantation*.

AUTHOR CONTRIBUTIONS

E.L., M.R., L.P.V., M.A.E., and K.V. designed the research. M.A.E., K.V., F.O.A., M.V., M.C.B., F.D., G.D., L.P.V., M.R., and E.L. performed the research. M.R. and E.L. were responsible for patient care during transplantation. F.O.A., M.C.B., F.D., and G.D. contributed vital analytical tools. M.A.E., K.V., G.D., L.P.V., and E.L. analyzed the data. M.A.E., K.V., and E.L. wrote the paper.

REFERENCES

1. Gahl WA, Thoene JG, Schneider JA. Cystinosis. *N Engl J Med*. 2002;347(2):111-121.
2. Elmonem MA, Veys KR, Soliman NA, et al. Cystinosis: a review. *Orphanet J Rare Dis*. 2016;11:47.
3. Prencipe G, Caiello I, Cherqui S, et al. Inflammasome activation by cystine crystals: implications for the pathogenesis of cystinosis. *J Am Soc Nephrol*. 2014;25(6):1163-1169.
4. Elmonem MA, Makar SH, van den Heuvel L, et al. Clinical utility of chitotriosidase enzyme activity in nephropathic cystinosis. *Orphanet J Rare Dis*. 2014;9:10.

5. Besouw M, Blom H, Tangerman A, de Graaf-Hess A, Levtchenko E. The origin of halitosis in cystinotic patients due to cysteamine treatment. *Mol Genet Metab*. 2007;91(3):228-233.
6. Besouw MT, Bowker R, Dutertre JP, et al. Cysteamine toxicity in patients with cystinosis. *J Pediatr*. 2011;159(6):1004-1011.
7. Besouw M, Schneider J, Janssen MC, et al. Copper deficiency in patients with cystinosis with cysteamine toxicity. *J Pediatr*. 2013;163(3):754-760.
8. Chiesa R, Wynn RF, Veys P. Haematopoietic stem cell transplantation in inborn errors of metabolism. *Curr Opin Hematol*. 2016;23(6):530-535.
9. Ferreira CR, Gahl WA. Lysosomal storage diseases. *Transl Sci Rare Dis*. 2017;2(1–2):1-71.
10. Hobbs JR, Hugh-Jones K, Barret AJ, et al. Reversal of clinical features of Hurler's disease and biochemical improvement by bone-marrow transplantation. *Lancet*. 1981;2(8249):709-712.
11. Pierpont EI, Eisengart JB, Shanley R, et al. Neurocognitive trajectory of boys who received a hematopoietic stem cell transplant at an early stage of childhood cerebral adrenoleukodystrophy. *JAMA Neurol*. 2017;74(6):710-717.
12. Boelens J, van Hasselt PM. Neurodevelopmental outcome after hematopoietic cell transplantation in inborn errors of metabolism: current considerations and future perspectives. *Neuropediatrics*. 2016;47(5):285-292.
13. Syres K, Harrison F, Tadlock M, et al. Successful treatment of the murine model of cystinosis using bone marrow cell transplantation. *Blood*. 2009;114(12):2542-2552.
14. Rocca CJ, Kreymerman A, Ur SN, et al. Treatment of inherited eye defects by systemic hematopoietic stem cell transplantation. *Investig Ophthalmol Vis Sci*. 2015;56(12):7214-7223.
15. Gaide Chevronnay HP, Janssens V, Van Der Smissen P, et al. Hematopoietic stem cells transplantation can normalize thyroid function in a cystinosis mouse model. *Endocrinology*. 2016;157(4):1363-1371.
16. Yeagy BA, Harrison F, Gubler MC et al. Kidney preservation by bone marrow cell transplantation in hereditary nephropathy. *Kidney Int*. 2011;79(11):1198-1206.
17. Naphade S, Sharma J, Gaide Chevronnay HP, et al. Brief reports: lysosomal cross-correction by hematopoietic stem cell-derived macrophages via tunneling nanotubes. *Stem Cells*. 2015;33(1):301-309.
18. Iglesias DM, El-Kares R, Taranta A, et al. Stem cell microvesicles transfer cystinosin to human cystinotic cells and reduce cystine accumulation in vitro. *PLoS One*. 2012;7(8):e42840.
19. Gabriel SS, Belge H, Gassama A, et al. Bone marrow transplantation improves proximal tubule dysfunction in a mouse model of Dent disease. *Kidney Int*. 2017;91(4):842-855.
20. Jagasia MH, Greinix HT, Arora M, et al. National Institutes of Health consensus development project on criteria for clinical trials in chronic graft-versus-host disease: I. the 2014 diagnosis and staging working group report. *Biol Blood Marrow Transplant*. 2015;21(3):389–401.e1.
21. Wilmer M, De Graaf-Hess A, Blom HJ, et al. Elevated oxidized glutathione in cystinotic proximal tubular epithelial cells. *Biochem Biophys Res Commun*. 2005;337(2):610–614.
22. Lykke-Andersen S, Jensen TH. Nonsense-mediated mRNA decay: an intricate machinery that shapes transcriptomes. *Nat Rev Mol Cell Biol*. 2015;16:665–677.
23. Taranta A, Petrini S, Citti A, et al. Distribution of cystinosin-LKG in human tissues. *Histochem Cell Biol*. 2012;138(2):351–363.
24. Solomon SR, Sanacore M, Zhang X, et al. Calcineurin inhibitor-free graft-versus-host disease prophylaxis with post-transplantation cyclophosphamide and brief-course sirolimus following reduced-intensity peripheral blood stem cell transplantation. *Biol Blood Marrow Transplant*. 2014;20(11):1828–1834.
25. Eichler F, Duncan C, Musolino PL, et al. Hematopoietic stem-cell gene therapy for cerebral adrenoleukodystrophy. *N Engl J Med*. 2017;377(17):1630–1638.
26. Cowan MJ, Dvorak CC, Long-Boyle J. Opening marrow niches in patients undergoing autologous hematopoietic stem cell gene therapy. *Hematol Oncol Clin North Am*. 2017;31(5):809–822.

How to cite this article: Elmonem MA, Veys K, Oliveira Arcolino F, et al. Allogeneic HSCT transfers wild-type cystinosin to nonhematological epithelial cells in cystinosis: First human report. *Am J Transplant*. 2018;00:1–6. https://doi.org/10.1111/ajt.15029