

Meandering main pancreatic duct syndrome: a single-center cohort study and aggregated review

Timothy Adam^a, Hannah Van Malenstein^a, Wim Laleman^{a,b}

University Hospitals Leuven; Universitätsklinikum Münster, Münster University, Münster, Germany

Abstract

Background Meandering main pancreatic duct (MMPD) refers to an uncommon ductal variant of the normal smooth curvilinear course of the pancreatic duct. More specifically, MMPD is characterized by a hairpin (reverse Z-type) or loop (loop-type) turn in the pancreatic head. It has been suggested as a predisposing factor for the development of pancreatitis. Studies regarding treatment are scarce.

Methods We conducted a narrative review of the current literature regarding MMPD. Additionally, we present a cohort of 9 symptomatic patients treated endoscopically at our tertiary center.

Results Seven retrospective cohort studies and 4 case reports were included in our review. Only 1 study focuses on the clinical significance of MMPD and describes a positive association between MMPD and the onset of pancreatitis, especially recurrent acute pancreatitis. Only 1 case reports an endoscopic treatment. In our cohort of 9 MMPD patients, 7 did indeed present with recurrent acute pancreatitis. Endotherapy provided substantial regression of symptoms in 6 patients, all of whom had signs of ductal hypertension.

Conclusions Our review shows the scarcity of data regarding MMPD, especially concerning treatment, in the current literature. With our cohort, we not only hope to raise awareness of this often-neglected entity of recurrent acute pancreatitis, but also support the case for endotherapy for the first time in 9 symptomatic MMPD patients, especially in the presence of ductal hypertension.

Keywords Meandering main pancreatic duct, anatomic anomaly, acute recurrent pancreatitis, ductal hypertension, endoscopic retrograde cholangiopancreatography

Ann Gastroenterol 2024; 37 (XX): 1-8

^aDepartment of Gastroenterology and Hepatology, Section of Liver & Biliopancreatic Disorders and Liver Transplantation, University Hospitals Leuven, KU Leuven, Belgium (Timothy Adam, Hannah Van Malenstein, Wim Laleman); ^bMedizinische Klinik B, Universitätsklinikum Münster, Münster University, Münster, Germany (Wim Laleman)

Conflict of Interest: None

Correspondence to: Timothy Adam, Department of Gastroenterology and Hepatology, University Hospital Gasthuisberg, KU Leuven, Herestraat 49, 3000 Leuven, Belgium, e-mail: timothy.adam@uzleuven.be

Received 20 March 2024; accepted 29 May 2024; published online 12 July 2024

DOI: <https://doi.org/10.20524/aog.2024.0901>

This is an open access journal, and articles are distributed under the terms of the Creative Commons Attribution-NonCommercial-ShareAlike 4.0 License, which allows others to remix, tweak, and build upon the work non-commercially, as long as appropriate credit is given and the new creations are licensed under the identical terms

Introduction

The pancreas is formed during the 6-7th week of embryological development by a complex fusion of the ventral and dorsal pancreatic bud. This process can give rise to multiple variations of pancreatic ductal anatomy which can be divided into configuration, course, duplication, migration and pancreaticobiliary ductal junction variants. The prevalence of these variations is estimated to be between 1% and 10% in most studies, and is averaged at 5.7% by a recent systematic review [1,2].

Meandering main pancreatic duct (MMPD) syndrome is a group of pancreatic duct anomalies, first classified together in 2012 by Gonoï *et al.* It includes 2 types of course variants in which the main pancreatic duct (MPD) either makes a hairpin (reverse Z-type) or a loop (loop-type) curve in the coronal plane of imaging modalities. Based on the observations by Gonoï *et al.*, the prevalence of MMPD is estimated at 2.2%, which according to the authors makes MMPD the second most frequent pancreatic duct anomaly after *pancreas divisum*. MMPD is also described

as a potential predisposing factor for (recurrent) pancreatitis, which therefore makes it a relevant entity [3]. To our knowledge, the number of published reports on MMPD is less than 10 [3-8]. Furthermore, apart from 1 case report, there are no studies concerning the endoscopic management of MMPD [4].

In this article we provide a narrative review regarding the prevalence and clinical significance of MMPD. Additionally, we describe the clinical presentation, endoscopic management, and outcome in a cohort of 9 symptomatic MMPD patients treated at our tertiary center.

Materials and methods

For our literature review we searched PubMed using the following MeSH terms: “Meandering main pancreatic duct,” “pancreatic duct anomaly” and “anomaly of the pancreatic duct”. All available literature was reviewed. The articles were screened by title and abstract for relevance regarding the prevalence, clinical significance and treatment of MMPD. The articles returned by the database were read completely, and only relevant articles were included in our review.

For our cohort study a convenience sample of 9 patients treated for MMPD was extracted from an existing database of endoscopic retrograde cholangiopancreatography (ERCP) procedures at our center between January 1st, 2018, and December 31st, 2023. We reviewed the medical records for relevant information regarding patient characteristics, type of pancreatitis, diagnosis, type of MMPD and treatment. The following patient characteristics were retrieved: date of birth, age at diagnosis of MMPD, sex, alcohol and tobacco use, and presence of diabetes mellitus or metabolic syndrome. Alcohol and tobacco use were described as present or absent. Metabolic syndrome was defined according to the definition of the international diabetes federation [9].

The presence and type of pancreatitis were described at the time of diagnosis of MMPD. The date of the first documented pancreatitis episode was also retrieved. The following criteria were used: (a) acute pancreatitis: presence of at least 2 of the following 3 criteria: typical pancreatic pain, amylase or lipase elevation 3 times upper limit of normal, or typical findings of pancreatitis on imaging [10]; (b) recurrent acute pancreatitis: 2 or more episodes of acute pancreatitis with complete interceding resolution, separated by at least 3 months [11]; and (c) chronic pancreatitis: clinical suspicion of chronic pancreatitis and typical imaging findings [11].

For the diagnosis of MMPD we used the diagnostic criteria defined by Gono *et al*: a main pancreatic duct with the presence of at least 2 extrema in a direction vertical to the body axis in the head of the pancreas, forming a curve or a loop and not accompanied by an anomalous arrangement of the pancreaticobiliary ductal system (AAPB) or *pancreas divisum* [3]. Magnetic resonance imaging (MRI), endoscopic ultrasound (EUS) and ERCP were considered as diagnostic tools. The date and method of diagnosis were retrieved. The time between the first pancreatitis episode and the definitive diagnosis was calculated. We also reviewed whether the diagnosis was missed on MRI, EUS or ERCP imaging predating

the diagnosis. We classified the types of MMPD according to the classification systems proposed by Gono *et al* [3] (Fig. 1). The available imaging modalities were also screened for pancreatic duct dilation suggestive of ductal hypertension.

MMPD was considered the cause for a pancreatitis episode if there were no other possible etiologies identified according to the minimal diagnostics proposed by the American College of Gastroenterology’s guideline for the management of acute pancreatitis. These include cholelithiasis, alcohol use and the presence of a neoplasia above the age of 40 years [10]. MMPD was also considered a relevant factor in cases of persistent recurrent acute pancreatitis and evolution to chronic pancreatitis, in which there was a possible other cause for the initial episode that was subsequently eliminated. If present, the analysis of genetic causes of pancreatitis was also retrieved.

All the ERCP procedures in the medical records were reviewed systematically. The first therapeutic procedure was classified into 2 categories according to the performed intervention: endoscopic sphincterotomy, or endoscopic sphincterotomy combined with transpapillary stenting of the pancreatic duct. If a procedure was followed by at least 1 other intervention in which the stent was replaced, it was considered a stenting program.

The response to therapy was classified as complete, partial or no response, based on the following interpretation of the medical records: (a) complete response, if there were no more pancreatitis episodes documented after treatment; (b) partial response was defined as a reduced frequency of pancreatitis episodes or diminished pain in chronic pancreatitis; and (c) if

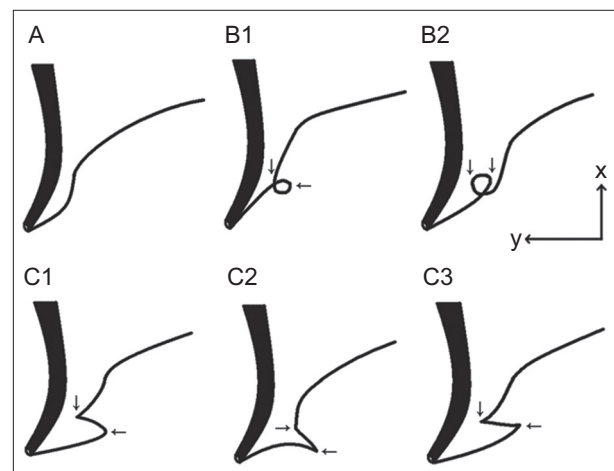


Figure 1 Types of meandering main pancreatic duct (MMPD) according to the classification of Gono *et al*. The thick line indicates the common bile duct, and the thin line indicates the main pancreatic duct. MMPD is classified into subtypes based on its morphology in the head of the pancreas: normal type (A), examples of loop type (B1-2), and examples of reverse-Z type (C1-3). Assuming the body axis as the x-axis and horizontal as the y-axis, the MPD curves in the loop- and reverse-Z types have 2 extrema in a horizontal direction (arrows), while the normal type has none (Figure and text reproduced from Gono W, Akai H, Hagiwara K, *et al*. Meandering main pancreatic duct as a relevant factor to the onset of idiopathic recurrent acute pancreatitis. *PLoS One* 2012;7:e37652. This is an open-access article distributed under the terms of the Creative Commons Attribution License, which permits unrestricted use, distribution, and reproduction in any medium, provided the original author and source are credited.)

the frequency and intensity of pain remained or worsened, it was categorized as no response.

The follow-up period was calculated from the date of diagnosis until the last known contact with our service or the service of the referring specialist. We only performed descriptive statistics given the exploratory nature of our study. This study was authorized by the Ethics Committee of the University Hospitals Leuven.

Results

Literature review

Our search strategy yielded 2385 results in PubMed on October 29, 2023. After screening the abstracts 22 articles were selected. These articles were fully read and 9 of them were included in our review [3,4,7,8,12-16]. Two case reports that were found in the references of other articles, but not in our PubMed search, were also included [5,6].

Two single-center studies retrospectively described pancreatic duct anomalies based on ERCP images. The first, by Uomo *et al* in Italy, included 485 patients and found 48 anatomical variants (9.9%) of which 4 (0.8%) were a loop-type pancreatic duct, which is one of the forms of MMPD [12]. The second study, by Bang *et al*, found 51 pancreatic duct anomalies in 582 patients in South Korea. Of these, 27 (4.7%) fit the description of loop-type pancreatic duct. This study also analyzed the relationship between anatomical variations of the ductal system and pancreaticobiliary diseases, but the classification system that was used did not allow firm conclusions with regard to a loop-type pancreatic duct [14]. A third single-center retrospective study analyzed the MRI images of 1158 patients in Turkey and found a prevalence of 2% for loop-type pancreatic duct [15]. A smaller fourth study described fusion variants in 37 patients with an AAPB in Japan. Two of these patients (5%) had a loop-type pancreatic duct [13].

MMPD as a group of pancreatic duct anomalies was described for the first time in a single-center retrospective study in Tokyo by Gonoï *et al*. It compared a group of 30 patients with idiopathic pancreatitis to a community group of 504 subjects who underwent a checkup, including MRI. The prevalence of MMPD was 2.2% in the community group and 20% in the idiopathic pancreatitis group. [3]

There was a significant positive association of MMPD with the onset of pancreatitis. Subgroup analysis showed that this association was especially clear for recurrent acute pancreatitis, whereas it was not for acute or chronic pancreatitis. Despite this association, no subjects with MMPD in the community group had a history of pancreatitis. This led to the hypothesis of MMPD as a predisposing factor for pancreatitis, with only a small portion of patients becoming symptomatic [3]. In a second study, Gonoï *et al* also found an association between pancreatic duct anomalies, including MMPD, and chronic asymptomatic pancreatic hyperenzymia [16].

Since the initial article by Gonoï, 4 case reports have been published, presenting 3 pediatric and 2 adult cases of acute

(recurrent) pancreatitis attributable to MMPD. One adult patient underwent an endoscopic pancreatic sphincterotomy; all other cases were managed conservatively. One of the pediatric patients also had a type IVa choledochal cyst, which was managed surgically after the acute episode of pancreatitis [4-7].

A second quite large single-center retrospective study was performed at the university hospital of Helsinki. Interestingly, this study focused on determining a possible association between intraductal papillary mucinous neoplasia (IPMN) and variations of the pancreatic ducts. It compared 108 IPMN patients with a control group of 106. MRI was used as diagnostic tool. Twenty-one cases of MMPD were detected, of which 18 patients (18.4%) had an associated IPMN and only 3 patients (3%) did not.

A secondary analysis, comparing MMPD patients to non-MMPD patients, showed a statistically significant odds ratio (6.4×) for the presence of IPMN in MMPD patients. Based on these data, an association was suggested between IPMN and MMPD. The clinical significance and relevance are unclear for now, as this involves only 1 report, but an IPMN follow up in MMPD is suggested as a possibility. This study also described a new type of MMPD in 8 patients, referred to as N-type. It was characterized by a main pancreatic duct that forms a notch at the head of the pancreas. IPMN patients with N-type MMPD were more likely to have a cystic mural nodule. However, as the study only included 6 patients this finding must be viewed with caution [8].

An overview of the published MMPD cohort studies and MMPD cases is summarized in Table 1.

Leuven MMPD Cohort

Nine patients, 3 men and 6 women, were included in our cohort. The age at the time of diagnosis ranged between 39 and 67 years, with a mean of 51 years. Both alcohol and tobacco use were present 4 times, with an overlap of 2 subjects who used both. Three patients had metabolic syndrome and 1 had type 2 diabetes. The patients' characteristics can be found in Table 2.

All diagnoses of MMPD were made during ERCP. An MRI preceding the diagnostic ERCP was found in 8 patients. The initial protocols of these MRIs described an anatomical variant in only 2 cases. Both times *pancreas divisum* was deemed most likely. After revision of the images, 2 more variants were suspected, of which 1 was thought to be a MMPD without a definitive diagnosis. The other was not further specified. EUS was also performed in 8 patients, preceding the diagnostic ERCP, but MMPD was strongly suspected only once. The diagnosis was also confirmed by ERCP immediately afterwards.

Seven patients presented with acute recurrent pancreatitis at the time of diagnosis. Acute and chronic pancreatitis were only found once each. The time between the first episode of pancreatitis and the diagnosis ranged between 0 and 73 months, and was 30 months on average. An overview of these data, along with the affected pancreatic segment and type of MMPD for each case, can be found in Table 3.

Table 1 Overview of MMPD cases in the articles included in the aggregated review

Author [ref.], year	No. of patients	Types of MMPD	Age (average if n >3)	Symptomatic	Type of pancreatitis	Endotherapy	Long-term outcome
Uomo <i>et al</i> [12], 1995 subset MMPD	4	loop	not reported	not reported	not reported	no	not reported
Bang <i>et al</i> [14], 2006 subset MMPD	27	loop	not reported	not reported	not reported	no	not reported
Adibelli <i>et al</i> [15], 2016 subset MMPD	23	loop	not reported	not reported	not reported	no	not reported
Ishii <i>et al</i> [12], 1998 subset MMPD	2	loop	not reported	not reported	not reported	no	not reported
Gonoi <i>et al</i> [3], 2012 patient group	6	loop (2) reverse Z (4)	60,7	yes	recurrent acute (4) acute (1) chronic (1)	no	not reported
Gonoi <i>et al</i> [3], 2012 control group	11	loop (6) reverse Z (5)	51,4	no	N/A	no	not reported
Gonoi <i>et al</i> [16], 2019 patient group	3	reverse Z	66,7	CAPH	N/A	no	not reported
Gonoi <i>et al</i> [16], 2019 control group	23	not reported	not reported	no	N/A	no	not reported
Kadimella <i>et al</i> [6], 2016	1	reverse Z	37	yes	recurrent acute	no	no recurrence follow up: 2 months
Sundar <i>et al</i> [5], 2018	1	loop	13	yes	recurrent acute	no	no recurrence follow up: unclear
Panchoo <i>et al</i> [7], 2019	2	loop	5 and 15	yes	recurrent acute	no	not reported
Praharaj <i>et al</i> [4], 2024	1	loop	42	yes	acute	EPST	no recurrence follow up: 6 months
Johansson <i>et al</i> [8], 2022	21	loop (12) reverse Z (9)	not reported	not reported	not reported	not reported	not reported

The articles are mentioned in order of their appearance in the Results section. Numbers in parentheses signify the number of cases. Age is reported in years. Both studies by Gonoi *et al* used the same cohort of patients who underwent a health checkup at their center as the control group, but with a different time frame (from October 12, 2006, to March 31, 2007, in 2012; from October 12, 2006, to May 31, 2007, in 2019). This implies that all cases in the control group of 2012 were also included in the control group of 2019

MMPD, meandering main pancreatic duct; CAPH, chronic asymptomatic pancreatic hyperenzymia; EPST, endoscopic pancreatic sphincterotomy

Multiple possible triggering factors other than MMPD were found for the initial episodes of pancreatitis: 4 patients drank alcohol, 2 used methotrexate and 1 had microlithiasis. A negative genetic screening for mutations in the *serine protease inhibitor Kazal-type 1 (SPINK1)* and *Cystic Fibrosis Transmembrane conductance Regulator (CFTR)* gene was available in 3 cases. Further evaluation for mutations in *PRSS1*, *CTRT*, *CASR*, *CLDN2*, and *CPA1* genes was performed once and was also negative. Signs of ductal hypertension were seen in 6 patients.

Only 1 patient was treated with isolated endoscopic sphincterotomy during the first ERCP. In all other patients the sphincterotomy was combined with stenting. A stenting

program was initiated in 5 patients, of whom 4 had a stenosis associated with their MMPD. A positive evolution after endoscopic therapy was seen in 6 patients, of whom 4 had a complete response and 2 a partial response. Three patients showed no response. Post-ERCP pancreatitis was seen 3 times out of a total of 37 procedures (8.1%). One procedure was complicated by a guidewire perforation at the site of a stricture in the loop of the MMPD and secondary formation of an intra-abdominal collection. An overview of the interventions and outcomes can be found in Table 4. Per-procedural ERCP images can be found in Fig. 2 and Supplementary Fig. 1-5.

Table 2 UZ Leuven patient cohort characteristics

Case	Age	Sex	Alcohol	Tobacco	Metabolic syndrome	Diabetes	Time needed for diagnosis	Other	Genetic screening
1	47	f	yes	yes	no	no	20	alcohol	no
2	47	f	no	yes	yes	yes	67	microlithiasis	no
3	39	m	no	yes	no	no	6	no	yes
4	44	f	no	no	yes	no	73	methotrexate	yes
5	53	f	yes	yes	no	no	0	alcohol	no
6	56	m	no	no	no	no	62	no	yes
7	47	f	yes	no	yes	no	25	alcohol	no
8	67	f	no	no	no	no	8	methotrexate	no
9	63	m	yes	no	no	no	14	alcohol	no

The age at the time of diagnosis is noted in years. Sex is denoted as male (m) or female (f). Time needed for diagnosis is calculated between the first documented episode of pancreatitis and the diagnostic endoscopic retrograde cholangiopancreatography in months. The column "other" shows possible precipitating factors for the development of pancreatitis that were present during the first documented episode. Genetic screening was considered to be present when an analysis in at least the *CFTR* and *SPINK1* gene were carried out

Table 3 The types of meandering main pancreatic duct (MMPD) and pancreatitis

Case	Type	Type of pancreatitis	Affected segment
1	C1	recurrent acute	head
2	B2	chronic	Head
3	C3	recurrent acute	tail
4	B1	recurrent acute	tail
5	B1	acute	body and tail
6	B1	recurrent acute	variable
7	C1	recurrent acute	head, body and tail
8	C3	recurrent acute	head
9	C2	recurrent acute	not specified

The types of MMPD are described for each case according to the classification published by Gonoï *et al* [3]. The type of pancreatitis is classified according to the criteria described in the Materials and methods section. The affected segment column notes the parts of the pancreas affected by the pancreatitis, based on computed tomography or magnetic resonance imaging

Discussion

Meandering main pancreatic duct (MMPD) refers to an uncommon ductal variant of the normal smooth curvilinear course of the pancreatic duct. More specifically, MMPD is characterized by a hairpin (reverse Z-type) or loop (loop-type) turn in the pancreatic head. It has been suggested as a predisposing factor for the development of pancreatitis [3]. Our literature review shows that data on MMPD are scarce and relate to only 7 retrospective cohort studies and 4 case reports [3-8,12-16]. Only 1 study focuses on MMPD and its clinical significance in idiopathic pancreatitis [3]. The other studies describe pancreatic duct anomalies in various populations, including anomalies that fit MMPD [4-8,12-16].

MMPD was defined for the first time in 2012 and was classified into 2 subtypes: a loop- and a reverse Z-type (Fig. 1).

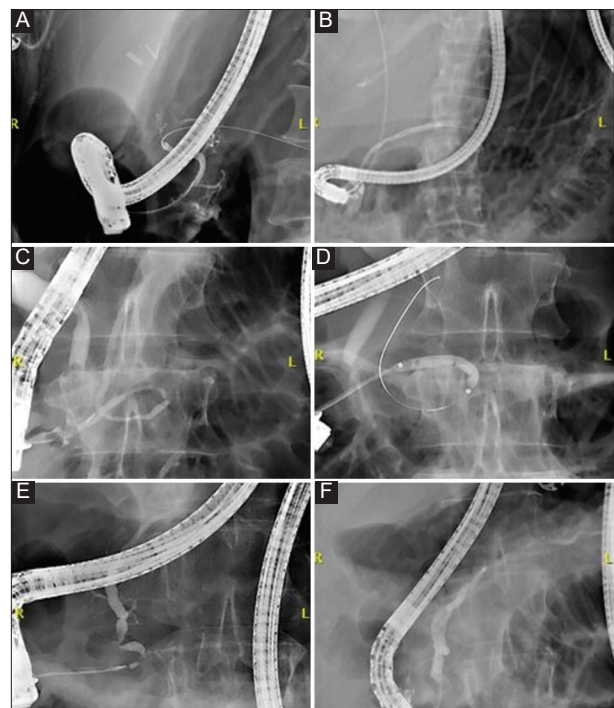


Figure 2 Examples of different types of MMPD, endotherapy and results: (A) Type C1 MMPD with a pre-papillary stenosis during index ERCP (case 1); (B) regression of MMPD and stenosis after stenting program (case 1); (C) type B1 MMPD with a stenosis in the medial part of the alpha-loop during index ERCP (case 6); (D) pneumatic balloon dilation of the stenosis in the alpha-loop during the same procedure (case 6); (E) type C2 MMPD associated with 2 short segmental stenoses during the index ERCP (case 9); (F) regression of the MMPD and stenosis after stenting program (case 9)
MMPD, meandering main pancreatic duct; ERCP, endoscopic retrograde cholangiopancreatography

A third N-type, in which the MPD forms a notch in the pancreatic head, was suggested in 2022 [8]. The N-type does not strictly fit the initial definition, as the extrema are oriented

Table 4 Overview of treatment

Case	Type	DH	Intervention	Stenting program	Description	Response	Follow up
1	C1	yes	ES + Stent	yes	repeated stenting and pneumatic balloon dilation of the MMPD and associated stenosis downstream Regression of the stenosis and MMP	partial	68
2	B2	no	ES + Stent	yes	repeated stenting of the MMPD, without overcoming the loop of the MMPD	no	40
3	C3	yes	ES + Stent	yes	Post gastric bypass, procedures through a gastrogastrostomy development of a multifocal stricture between papilla major and branching of Santorini after first procedure Repeated sphincterotomy of minor papilla and no possibility for antero- or retrograde stenting initially without response During fourth procedure successful stenting through papillary minor and start of stenting program with regression of stenosis in Santorini	partial	46
4	B1	no	ES + Stent	no	Single procedure with sphincterotomy and transpapillary stenting of Wirsung, without overcoming the loop of the MMPD Removal of stent after 4 weeks.	no	4
5	B1	yes	ES + Stent	no	Single procedure with sphincterotomy and transpapillary stenting of Wirsung, without overcoming the loop of the MMPD Removal of stent after 4 weeks.	complete	1
6	B1	yes	ES + Stent	yes	MMPD associated with a stenosis in the most medial part of the alfa loop Sphincterotomy and transpapillary stenting of the MMPD and stenosis complicated with a guidewire perforation at site of stenosis Afterwards no possibility for antero- or retrograde stenting and decision to consolidate the pancreaticogastrostomy formed during antero-approach	complete	62
7	C1	no	ES	no	Post mason gastroplasty, procedure through narrow gastrogastrostomy After sphincterotomy adequate drainage and no further stenting but persistent complaints Failed attempts for antero- or retrograde drainage in second procedure	no	54
8	C3	yes	ES + Stent	no	Single procedure with sphincterotomy and transpapillary stenting of Wirsung, without overcoming the hairpin of the MMPD spontaneous migration of stent	partial	1
9	C2	yes	ES + Stent	yes	MMPD associated with 2 short segmental stenosis After EUS rendezvous ERCP approach dilation and stenting of stenosis and MMPD Complete regression of stenosis and MMPD after repeated stenting	complete	64

The type of meandering main pancreatic duct (MMPD) according to the classification by Gono *et al* [3] is repeated in the second column. The third column categorizes the cases depending on the presence (yes) or absence (no) of signs of ductal hypertension (DH). The fourth column shows the intervention performed during the first index endoscopic retrograde cholangiopancreatography (ERCP). Possible interventions are endoscopic sphincterotomy (ES) and endoscopic placement of a transpapillary stent in the pancreatic duct (Stent). The fifth column notes the presence (yes) or absence (no) of a stenting program after the index procedure. A short description of the therapeutics performed is provided in the sixth column. Transpapillary stenting was performed past the loop or hairpin of the MMPD, unless specified otherwise. The response to therapy is classified as complete, partial or no response, as defined in the Materials and methods section. The follow-up period is given in months

horizontally, and not vertically, with respect to the body axis; it is thus still a subject of debate. In our cohort study we described 4 loop-type and 5 reverse Z-type pancreatic ducts, but found no N-type. If further research reveals more clinically relevant cases of the N-type, it should be considered to expand the definition.

The global prevalence of MMPD is currently estimated to be between 2% and 3%, based on a Japanese community group (2.2%) [3] and a Finnish population study (3%) [8].

The prevalences in all other studies should be interpreted with even more caution, as the populations were preselected: either they underwent ERCP [12,14] or MRCP [15] for various indications, or they were symptomatic [13].

It is difficult to compare the prevalence of MMPD to other pancreatic duct anomalies, as studies used different populations and various classification systems. A 2018 systematic review estimated the prevalence of pancreatic duct anomalies at 5.7%, of which 4.5% referred to *pancreas divisum* [1]. Considering an

estimated prevalence of 2-3%, MMPD is probably one of the most frequent, if not the most frequent, anomaly after *pancreas divisum*.

Currently, most studies use (and recommend) MRI for diagnosing MMPD. As stated by Gonoï *et al*, MRI is considered a noninvasive technique with a high sensitivity and specificity for the depiction of the pancreatic ducts [3]. MRI is also described by the American Gastroenterological Association's clinical practice update on acute recurrent and chronic pancreatitis as helpful in identifying anatomical variants of the pancreatic duct [11]. Therefore, it is remarkable that all the diagnoses in our cohort were made during ERCP, despite the availability of a prior MRI for most patients. Only 4 patients with pancreatic duct anomalies were detected primarily by MRI in our cohort, without a definitive diagnosis of MMPD. The fact that 2 of these were detected after revision of the images points up the importance of the radiologist's awareness of pancreatic duct anomalies, and the proper medical information when requesting imaging. From this perspective, and in our own view, a diagnostic ERCP, as one of the last standing indications, can be advocated in the clinical stalemate of recurrent acute pancreatitis without any clue during a full diagnostic workup (including magnetic resonance cholangiopancreatography), provided this has been extensively discussed with the patient prior to the exam.

The exact clinical significance of MMPD is still reported as unclear, but its role in the onset of pancreatitis, especially recurrent acute pancreatitis is endorsed by the (obvious) reported symptomatic clinical cases. Gonoï *et al*, as one of the few, has reported that only 5-10% of patients with MMPD become symptomatic, analogous to *pancreas divisum* [3]. A possible association between MMPD and IPMN has also been suggested [8], but no cases of IPMN were found in our series.

In our cohort, almost all patients presented with recurrent acute pancreatitis. The average age at diagnosis was 51 years. If MMPD was the sole contributor to the development of pancreatitis, earlier symptoms could be expected, as MMPD is considered a congenital anomaly [3]. Additionally, in 7 of our patients the initial pancreatitis episode could have been triggered by other factors than MMPD, such as lithiasis, alcohol or medication. Most of these patients did however develop recurrent acute pancreatitis, which could no longer be attributed to these triggers as they were no longer present after the initial episode. These findings support the hypothesis of MMPD as a predisposing factor for pancreatitis recurrence, and seem to suggest the presence of a coexisting triggering factor to initiate the first episode, according to the "sentinel acute pancreatitis event" hypothesis [17].

We propose mechanical (sub)obstruction or delayed secretion as the most probable mechanism by which MMPD contributes to the development of pancreatitis, as 6 of our patients had signs of ductal hypertension. This aligns with the findings of published case reports [4-6]. In contrast, Gonoï

et al found no pancreatic duct dilation nor parenchymal atrophy, for which reason they considered mechanical (sub) obstruction less likely. Genetic etiologies, such as mutations in the *CFTR* or *SPINK1* gene, were suggested as an alternative [3]. We cannot support this hypothesis, as no mutations in these genes were found in the 3 patients that were screened in our cohort.

If ductal hypertension is present, we believe endoscopic therapy focused on relieving the possible outflow obstruction can be advocated, similarly to *pancreas divisum* [11]. Until our cohort, there was only 1 case report describing endoscopic pancreatic sphincterotomy in a symptomatic MMPD patient, with a positive subsequent evolution [4]. We describe 9 patients undergoing endotherapy for MMPD, the largest reported interventional series to our knowledge. Overall, there was a mixed response, as 6 of 9 patients showed substantial regression of their symptoms. All these patients had signs of ductal hypertension, and 4 had a stenosis associated with their MMPD, probably secondary to the recurrent bouts of pancreatitis. Remarkably, no signs of ductal hypertension were found in the 3 patients who did not respond to treatment. These findings might suggest that selection for endotherapy should be based on the presence of a stenosis or signs of ductal hypertension.

Adverse events of endotherapy were not observed in a higher rate than classically expected and reported after ERCP. Three episodes of post-ERCP pancreatitis (8.1%) were documented in a total of 37 procedures, which is within the range of the estimated prevalence of 10% [18]. One guidewire perforation of the pancreatic duct was seen, which is a rare complication, happening in less than 1% of the procedures, and in the context of MMPD was favored by the anatomical anomaly.

Despite our findings, our study is hampered by some unavoidable shortcomings. First of all, it involved a small cohort of only 9 patients, without a control group, and was therefore not able to answer the question of relevance in a general (unselected) population. Yet, in light of the scarce data and mostly even smaller series, we consider our analysis to be of added value to the overall literature currently available. Second, there most certainly was selection bias, since all our patients were symptomatic and thus might have represented a more severe subgroup of MMPD patients. On the other hand, our series is the first to explore and describe endotherapy in 9 patients.

In conclusion, MMPD is a pancreatic duct anomaly with an estimated prevalence of 2.2%, in which the MPD forms a loop or a reverse-Z in the head of the pancreas. It is considered as a predisposing factor for the development of pancreatitis, especially for acute recurrent pancreatitis. With our cohort, we not only hope to raise awareness of this often neglected or unknown entity of recurrent acute pancreatitis, but also support the case for endotherapy (for the first time in 9 symptomatic MMPD patients), especially in cases of ductal hypertension.

Summary Box

What is already known:

- Meandering main pancreatic duct (MMPD) is an uncommon variant of the pancreatic duct, characterized by a hairpin (reverse Z-type) or loop (loop-type) in the pancreatic head
- With an estimated prevalence of 2-3%, MMPD is considered the second most frequent pancreatic duct anomaly
- Magnetic resonance imaging (MRI) is frequently used and suggested as method of diagnosis
- Although the clinical relevance of MMPD is still unclear, a role in the onset of pancreatitis, especially acute recurrent pancreatitis is suggested

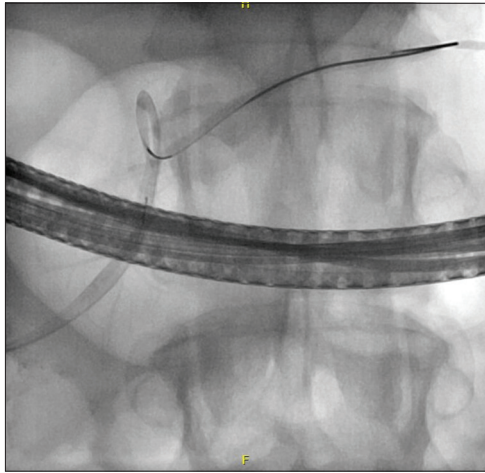What the new findings are:

- MRI might not be as sensitive as thought in clinical practice, and diagnostic endoscopic retrograde cholangiopancreatography can be considered in idiopathic recurrent acute pancreatitis to diagnose MMPD
- We suggest mechanical obstruction or delayed secretion as the most probable mechanism by which MMPD contributes to the onset of pancreatitis, based on the presence of ductal hypertension in most of our cases
- The first episode of pancreatitis in MMPD patients often seems to be initiated by a coexisting triggering factor, in accordance with the “sentinel acute pancreatitis event” hypothesis
- Endotherapy is described as a treatment option for the first time in a series of 9 symptomatic MMPD patients and might be effective, especially in the presence of ductal hypertension

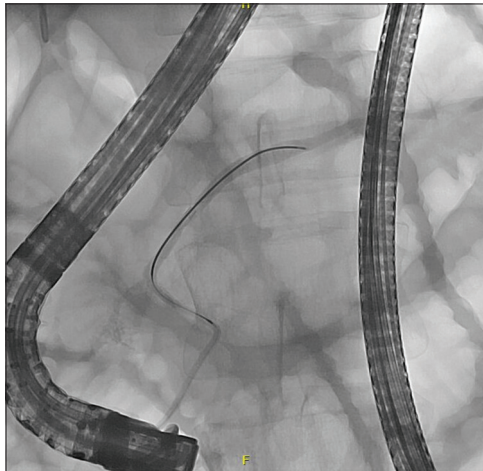
References

1. Dimitriou I, Katsourakis A, Nikolaidou E, Noussios G. The main anatomical variations of the pancreatic duct system: review of the literature and its importance in surgical practice. *J Clin Med Res* 2018;**10**:370-375.
2. Dugic A, Nikolic S, Mühldorfer S, et al. Clinical importance of main pancreatic duct variants and possible correlation with pancreatic diseases. *Scand J Gastroenterol* 2020;**55**:517-527.
3. Gonoï W, Akai H, Hagiwara K, et al. Meandering main pancreatic duct as a relevant factor to the onset of idiopathic recurrent acute pancreatitis. *PLoS One* 2012;**7**:e37652.
4. Praharaï D, Mallick B, Nath P, Giri S, Panigrahi SC, Sahu SK. Meandering main pancreatic duct—a rare cause of recurrent acute pancreatitis. *Am J Gastroenterol* 2024;**119**:23.
5. Sundar S, Purushotham B, Rathinasamy R, Kathiresan P. Meandering pancreatic duct as a cause of idiopathic recurrent pancreatitis. *World J Lap Surg* 2018;**11**:48-50.
6. Kadimella A, Sampath T, Gudi V. Reversed Z-shaped anomaly of main pancreatic duct as a cause of recurrent acute pancreatitis: a review. *J Dr NTR Univ Health Sci* 2016;**5**:165-168.
7. Panchoo AV, Infante JC, Rivera Rivera ED. Meandering main pancreatic duct in association with choledochal cysts and acute pancreatitis in pediatrics. *Pediatr Ann* 2019;**48**:e412-e416.
8. Johansson K, Mustonen H, Seppänen H, Lehtimäki TE. Anatomical pancreatic variants in intraductal papillary mucinous neoplasm patients: a cross-sectional study. *BMC Gastroenterol* 2022;**22**:394.
9. Zimmet P, M M Alberti KG, Serrano Ríos M. [A new international diabetes federation worldwide definition of the metabolic syndrome: the rationale and the results]. *Rev Esp Cardiol* 2005;**58**:1371-1376.
10. Tenner S, Baillie J, DeWitt J, Vege SS; American College of Gastroenterology. American College of Gastroenterology guideline: management of acute pancreatitis. *Am J Gastroenterol* 2013;**108**:1400-1415; 1416.
11. Strand DS, Law RJ, Yang D, Elmunzer BJ. AGA clinical practice update on the endoscopic approach to recurrent acute and chronic pancreatitis: expert review. *Gastroenterology* 2022;**163**:1107-1114.
12. Uomo G, Manes G, D'Anna L, Laccetti M, Di Gaeta S, Rabitti PG. Fusion and duplication variants of pancreatic duct system. Clinical and pancreatographic evaluation. *Int J Pancreatol* 1995;**17**:23-28.
13. Ishii H, Arai K, Fukushima M, et al. Fusion variations of pancreatic ducts in patients with anomalous arrangement of pancreaticobiliary duct system. *J Hepatobiliary Pancreat Surg* 1998;**5**:327-332.
14. Bang S, Suh JH, Park BK, Park SW, Song SY, Chung JB. The relationship of anatomic variation of pancreatic ductal system and pancreaticobiliary diseases. *Yonsei Med J* 2006;**47**:243-248.
15. Adibelli ZH, Adatepe M, Imamoglu C, Esen OS, Erkan N, Yildirim M. Anatomic variations of the pancreatic duct and their relevance with the Cambridge classification system: MRCP findings of 1158 consecutive patients. *Radiol Oncol* 2016;**50**:370-377.
16. Gonoï W, Hayashi TY, Hayashi N, Abe O. Association between chronic asymptomatic pancreatic hyperenzymemia and pancreatic ductal anomalies: a magnetic resonance cholangiopancreatography study. *Abdom Radiol (NY)* 2019;**44**:2494-2500.
17. Whitcomb DC. Central role of the sentinel acute pancreatitis event (SAPE) model in understanding recurrent acute pancreatitis (RAP): Implications for precision medicine. *Front Pediatr* 2022;**10**:941852.
18. Akshintala VS, Kanthasamy K, Bhullar FA, et al. Incidence, severity, and mortality of post-ERCP pancreatitis: an updated systematic review and meta-analysis of 145 randomized controlled trials. *Gastrointest Endosc* 2023;**98**:1-6.

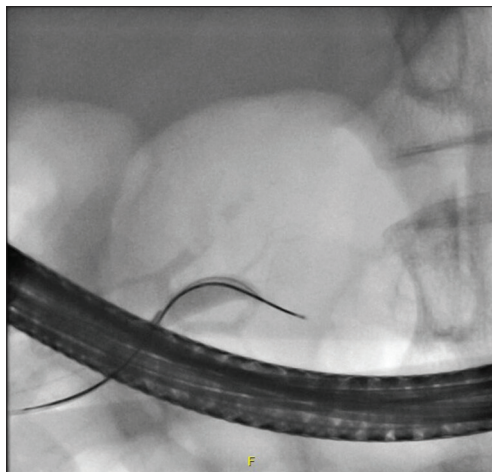
Supplementary material



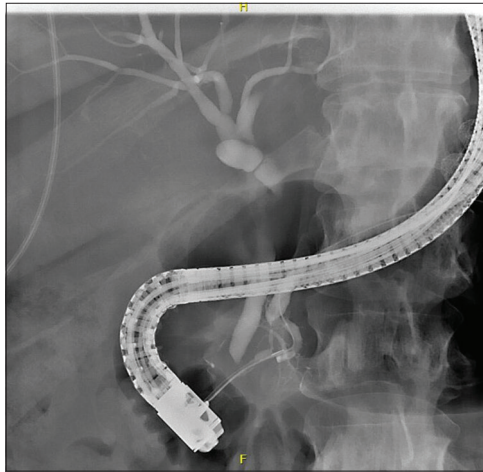
Supplementary Figure 1 Type B2 meandering main pancreatic duct (case 2)



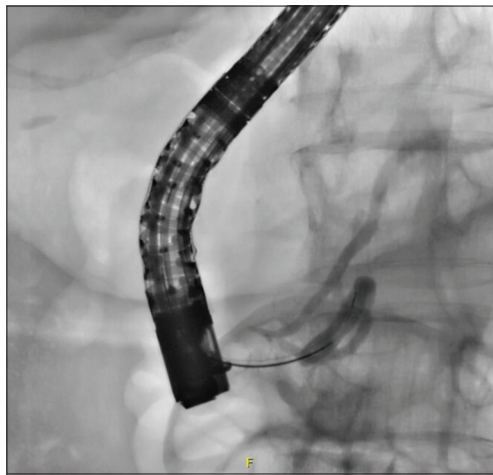Supplementary Figure 2 Type C3 meandering main pancreatic duct (case 3)



Supplementary Figure 3 Type B1 meandering main pancreatic duct (case 5)



Supplementary Figure 4 Type C1 meandering main pancreatic duct (case 7)



Supplementary Figure 5 Type C3 meandering main pancreatic duct (case 8)