






Cite this article as: Iskender I, Pecoraro Y, Moreno Casado P, Kubisa B, Schiavon M, Faccioli E *et al.* Lung transplantation in patients with a history of anatomical native lung resection. *Interact CardioVasc Thorac Surg* 2022; doi:10.1093/icvts/ivac256.

## Lung transplantation in patients with a history of anatomical native lung resection

Ilker Iskender <sup>a,b</sup>, Ylenia Pecoraro<sup>c</sup>, Paula Moreno Casado<sup>d</sup>, Bartosz Kubisa <sup>e</sup>, Marco Schiavon<sup>f</sup>, Eleonora Faccioli<sup>f</sup>, Jonas Ehrsam<sup>g</sup>, Francesco Damarco<sup>h</sup>, Mario Nosotti <sup>h</sup>, Ilhan Inci<sup>g</sup>, Federico Venuta <sup>c</sup>, Dirk Van Raemdonck<sup>a,b</sup> and Laurens J. Ceulemans <sup>a,b,\*</sup>

<sup>a</sup> Department of Thoracic Surgery, University Hospitals Leuven, Leuven, Belgium

<sup>b</sup> Department of Chronic Diseases and Metabolism, Laboratory of Respiratory Diseases and Thoracic Surgery (BREATHE), Lung Transplant Unit, KU Leuven, Leuven, Belgium

<sup>c</sup> Department of Thoracic Surgery, Policlinico Umberto I, University of Rome La Sapienza, Rome, Italy

<sup>d</sup> Department of Thoracic Surgery, University Hospital Reina Sofia, Cordoba, Spain

<sup>e</sup> Department of Thoracic Surgery, Pomeranian Medical University of Szczecin, Szczecin, Poland

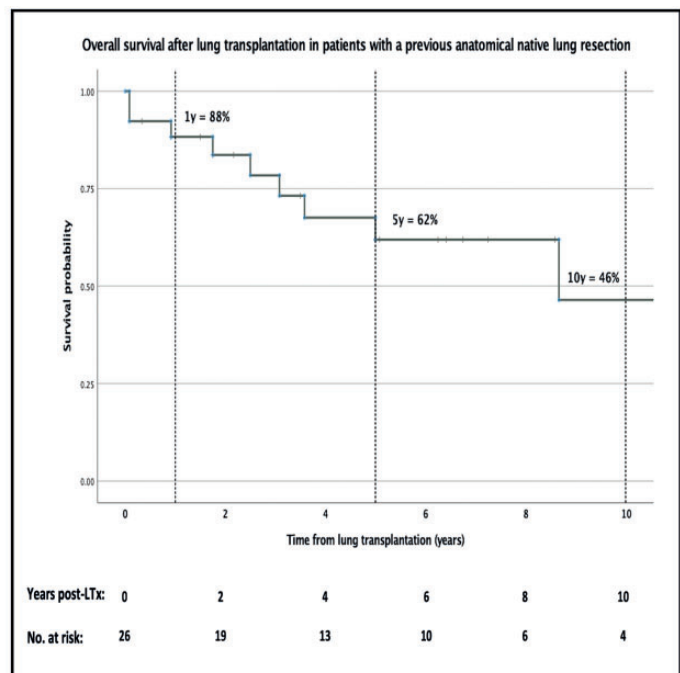
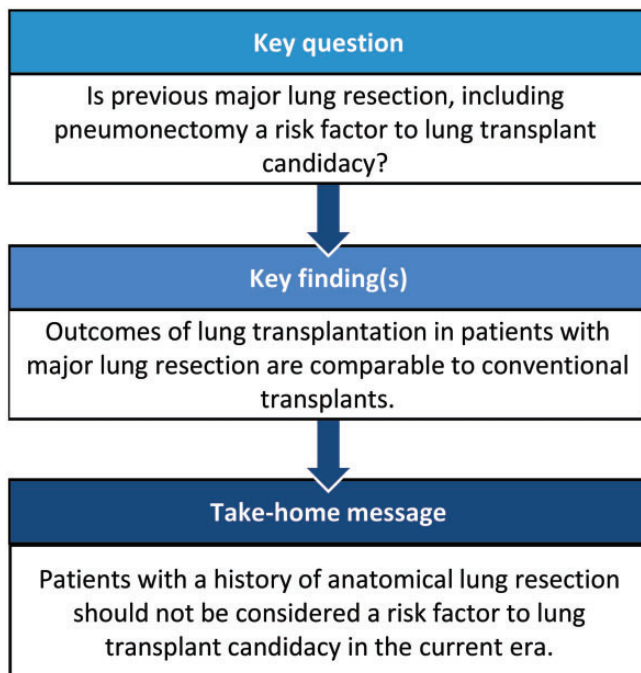
<sup>f</sup> Department of Thoracic Surgery, University of Padua, Padua, Italy

<sup>g</sup> Department of Thoracic Surgery, University Hospital Zurich, Zurich, Switzerland

<sup>h</sup> Department of Thoracic Surgery, Foundation IRCCS Ca' Granda Ospedale Maggiore Policlinico, Milan, Italy

\* Corresponding author. Thoraxheekunde, UZ Leuven, Herestraat 49, 3000 Leuven, Belgium. Tel: +32-16346820; e-mail: laurens.ceulemans@uzleuven.be (L.J. Ceulemans).

Received 22 June 2022; received in revised form 19 September 2022; accepted 6 October 2022



### Abstract

**OBJECTIVES:** History of anatomical lung resection complicates lung transplantation (LTx). Our aim was to identify indications, intraoperative approach and outcome in these challenging cases in a retrospective multicentre cohort analysis.

Presented at the 29th European Conference on General Thoracic Surgery, 20–22 June 2021 (VIRTUAL).

© The Author(s) 2022. Published by Oxford University Press on behalf of the European Association for Cardio-Thoracic Surgery.

This is an Open Access article distributed under the terms of the Creative Commons Attribution-NonCommercial License (<https://creativecommons.org/licenses/by-nc/4.0/>), which permits non-commercial re-use, distribution, and reproduction in any medium, provided the original work is properly cited. For commercial re-use, please contact [journals.permissions@oup.com](mailto:journals.permissions@oup.com)

**METHODS:** Members of the ESTS Lung Transplantation Working Group were invited to submit data on patients undergoing LTx after a previous anatomical native lung resection between January 2005 and July 2020. The primary end point was overall survival (Kaplan–Meier estimation).

**RESULTS:** Out of 2690 patients at 7 European centres, 26 (1%) patients (14 males; median age 33 years) underwent LTx after a previous anatomical lung resection. The median time from previous lung resection to LTx was 12 years. The most common indications for lung resection were infections ( $n=17$ ), emphysema ( $n=5$ ), lung tumour ( $n=2$ ) and others ( $n=2$ ). Bronchiectasis (cystic fibrosis or non-cystic fibrosis related) was the main indication for LTx ( $n=21$ ), followed by COPD ( $n=5$ ). Two patients with a previous pneumonectomy underwent contralateral single LTx and 1 patient with a previous lobectomy had ipsilateral single LTx. The remaining 23 patients underwent bilateral LTx. Clamshell incision was performed in 12 (46%) patients. Moreover, LTx was possible without extracorporeal life support in 13 (50%) patients. 90-Day mortality was 8% ( $n=2$ ) and the median survival was 8.7 years.

**CONCLUSIONS:** The history of anatomical lung resection is rare in LTx candidates. The majority of patients are young and diagnosed with bronchiectasis. Although the numbers were limited, survival after LTx in patients with previous anatomical lung resection, including pneumonectomy, is comparable to reported conventional LTx for bronchiectasis.

**Keywords:** Lung transplantation • Lung resection • Patient selection

#### ABBREVIATIONS

CF	Cystic fibrosis
CLAD	Chronic lung allograft dysfunction
CPB	Cardiopulmonary bypass
ECLS	Extracorporeal life support
ECMO	Extracorporeal membrane oxygenation
ESTS	European Society of Thoracic Surgeons
ISHLT	International Society for Heart and Lung Transplantation
LTx	Lung transplantation
PPS	Postpneumonectomy syndrome

## INTRODUCTION

Reoperation in thoracic surgery is a risk factor for complications. Advances in perioperative management have minimized unwanted effects of previous thoracic surgery in patients undergoing lung transplantation (LTx) [1, 2]. Nevertheless, previous thoracic surgery remains considered a risk factor to LTx candidacy [3], probably due to the inclusion of a broad range of thoracic procedures from minimally invasive procedures to open resections in previous publications. Data remain scarce for patients undergoing LTx after a major lung resection.

Patients with previous lung resections would require a completion pneumonectomy during LTx, which is often considered a high-risk procedure, especially for benign indications [4]. Donor lung size reduction may also be needed to overcome a potential size discrepancy between resected and non-resected sites related to a shrunken chest years after a lung resection [5]. LTx in patient with a previous contralateral pneumonectomy requires special considerations. The success of this rare procedure largely depends on the management of mediastinal shift-related changes [6].

The prevalence of LTx in patients with a history of previous lung resection has been found to be <1% according to a recent database review [7]. Although this study is the largest case series published to date, it has several limitations related to the nature of a large database review with limited data available [7]. It is important to accumulate more data in a multicentre project to collect more evidence to support the indication for LTx in future candidates with previous lung resection in the current era. Our aim was to identify indications, specific surgical methodology

and outcomes in this patient population in a retrospective multicentre cohort analysis organized by the members of the European Society of Thoracic Surgeons (ESTS) LTx Working Group.

## PATIENTS AND METHODS

### Ethics statement

The study was conducted in accordance with the Declaration of Helsinki. The study was approved by the Ethics Board Leuven, project S51577. Individual consent for this retrospective analysis was waived.

In this multicentre study, the members of ESTS LTx Working Group were invited to submit data for patients undergoing single or bilateral LTx after a previous anatomical native lung resection, including segmentectomy, lobectomy, bilobectomy or pneumonectomy between January 2005 and July 2020. Patients with a previous non-anatomical lung resection (i.e. wedge resection) and lung resections performed after LTx were excluded from the study. Centres were invited to submit their data related to patient and donor characteristics, types of previous lung resections and outcomes. Participating centres were from Leuven–Belgium, Rome, Padua and Milan–Italy, Cordoba–Spain, Szczecin–Poland and Zurich–Switzerland. Centres reviewed their institutional databases to complete required data.

Centres listed their patients according to the institutional protocols developed from international guidelines [3]. LTx technique, perioperative management and post-LTx follow-up were not unified among centres. The primary end point of the study was overall patient survival. Follow-up was completed by the end of 2020 in all patients.

IBM SPSS Statistics, Version 27 (IBM Corp., Armonk, NY, USA) and GraphPad Prism 9 (La Jolla, CA, USA) were utilized to analyse all data. Continuous variables were expressed as the median (first to third quartiles). Categorical variables were presented as the total number of patients and percentages. Chronic lung allograft dysfunction (CLAD)-free survival was calculated from the date of LTx to the date of CLAD diagnosis or mortality for patients surviving to hospital discharge. Mann-Whitney test was utilized to compare the donor/recipient height ratio. Overall survival was calculated from the date of LTx to the date of mortality or the last follow-up date. Kaplan–Meier survival estimation was utilized

to present survival. Missing variables were excluded from the data analysis.

## RESULTS

During the study period, a total of 2690 patients underwent an LTx. Of those, 26 had a history of anatomical lung resection, which constituted the study group with a prevalence of 1% in this cohort (Table 1).

Recipients were remarkably young with a median age of 33 years. Cystic fibrosis (CF) or non-CF-related bronchiectasis was the main indication for LTx in 21, followed by chronic obstructive pulmonary disease in 5 patients. The median time from listing to LTx was 8 months. Recipient characteristics are listed in Table 2.

The median time from lung resection to LTx was 12 years. The most common indications for lung resection were infections

in 17, emphysema in 5 and lung tumour in 2 patients. All lung resections were performed as open procedures, lobectomy being the most frequent in 18 patients. Details of the procedures are presented in Table 3.

Recipients received lungs from young donors with a median age of 41 years. Majority of these lungs (85%) were procured from donation after brain death with excellent arterial blood gases. Two lungs were evaluated with *ex vivo* lung perfusion prior to LTx. Donor characteristics are listed in Table 4.

Majority of LTx procedures were performed bilaterally in 23 patients. Three of them required lobar LTx due to significant donor/recipient size mismatching, which is illustrated in Fig. 1. Additional 3 patients underwent right single LTx, 2 of them were after contralateral pneumonectomies and the remaining one was

**Table 1:** Participating centres

Centre	Total number of LTx (2005–2020)	Number of LTx after PALR	% of LTx after PALR
Leuven, BE	944	14	1.5
Rome, IT	154	3	1.9
Cordoba, ES	497	3	0.6
Szczecin, PL	82	2	1.2
Padua, IT	368	2	0.5
Zurich, CH	382	1	0.3
Milan, IT	263	1	0.4
Total	2690	26	1

LTx: lung transplantation; PALR: previous anatomical lung resection.

**Table 2:** Recipient characteristics

Parameters	PALR (n = 26)
Age at LTx (years)	33 (22–49)
Sex	
Male, n (%)	14 (54)
Female, n (%)	12 (46)
Body mass index <sup>a</sup> (n = 25)	19 (18–21)
FEV1 <sup>a</sup> (n = 25)	23 (19–30)
DLCO <sup>a</sup> (n = 19)	36 (29–47)
V/Q scan <sup>a</sup> (n = 22)	
Perfusion: right (%)	42 (26–74)
Left (%)	58 (26–74)
sPAP <sup>a</sup> (mmHg) (n = 18)	39 (33–42)
Indication for LTx, n (%)	
CF	15 (58)
Bronchiectasis	5 (19)
COPD	5 (19)
Kartagener	1 (4)
Time from listing to LTx (months)	8 (2–18)

Values are median (first to third quartiles) or n (%).

<sup>a</sup>Variable with missing data and number of patients with complete data are given in parenthesis.

CF: cystic fibrosis; COPD: chronic obstructive pulmonary disease; DLCO: diffusion capacity of carbon monoxide; FEV<sub>1</sub>: forced expiratory volume in 1 s; LTx: lung transplantation; PALR: previous anatomical lung resection; sPAP: systolic pulmonary arterial pressure; V/Q: ventilation–perfusion.

**Table 3:** Characteristics of previous anatomical lung resection

Parameters	PALR (n = 26)
Time from PALR to LTx (years)	12 (7–21)
Indication for PALR, n (%)	
Infectious	17 (65)
Emphysema	5 (19)
Lung tumour	2 (8)
Lung cirrhosis	1 (4)
Atelectasis	1 (4)
PALR type, n (%)	
Segmentectomy	2 (8)
Lobectomy	18 (69)
Lobectomy + segment	2 (8)
Bilobectomy	1 (4)
Bilateral lobectomy	1 (4)
Pneumonectomy	2 (8)

Values are median (first to third quartiles) or n (%).

LTx: lung transplantation; PALR: previous anatomical lung resection.

**Table 4:** Donor characteristics

Parameters	PALR (n = 26)
Age (years)	41 (23–52)
Sex	
Male, n (%)	15 (58)
Female, n (%)	11 (42)
Body mass index <sup>a</sup> (n = 22)	24 (23–27)
Length of IMV (days) <sup>a</sup> (n = 24)	2 (1–4)
Type, n (%)	
DBD	22 (85)
DCD	4 (15)
Cause of Brain injury in DBD, n (%) <sup>a</sup> (n = 23)	
Trauma	14 (61)
CVA	9 (39)
P/F ratio	466 (391–522)
EVLV, n (%)	2 (8)

Values are median (first to third quartiles) or n (%).

<sup>a</sup>Variable with missing data, number of donors with complete data are given in parenthesis.

CVA: cerebrovascular accident; DBD: donation after brain death; DCD: donation after circulatory death; EVLP: *ex vivo* lung perfusion; IMV: invasive mechanical ventilation; PALR: previous anatomical lung resection; P/F ratio: arterial partial pressure of oxygen divided by the fraction of inspired oxygen.

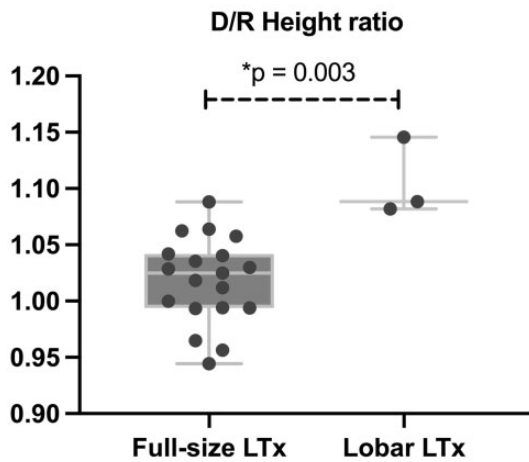


Figure 1: Donor/recipient height ratio.

after an ipsilateral lobectomy. Clamshell incision was performed in 12 patients. Moreover, LTx was possible without extracorporeal life support (ECLS) in half of the cohort. LTx was performed using cardiopulmonary bypass (CPB) in 5 patients, including 2 patients with previous pneumonectomies. Five patients required postoperative extracorporeal membrane oxygenation (ECMO) support and tracheostomy. The median intensive care unit stay was 11 days. Overall, 90-day mortality was 8% in 2 patients related to primary graft dysfunction and shock. Short-term outcomes of entire cohort and status after pneumonectomy subgroup are presented in Table 5.

The median follow-up time was 43 months. The 1-, 5- and 10-year survival rates were 88%, 62% and 46%, which were comparable to the International Society for Heart and Lung Transplantation (ISHLT) registry in patients undergoing LTx for CF or non-CF bronchiectasis [8] (Fig. 2). CLAD was diagnosed in 10 patients. The median CLAD-free survival was 61 (95% confidence interval: 54–67) months. Additional to the 90-day mortality, there were 7 deaths during the follow-up due to CLAD in 6 cases and infection in 1 patient, resulting in an overall mortality of 9 patients. Long-term outcomes of entire cohort and status after pneumonectomy subgroup are presented in Table 6.

## DISCUSSION

In this study, we investigated the incidence, patient characteristics and outcomes in LTx recipients after a previous anatomical native lung resection and found that the operation is feasible and short and long outcomes of this unique cohort were excellent with an overall median survival of 8.7 years.

Our multicentre cohort consists of a moderate sample size with 26 patients and has unique characteristics if compared to the ISHLT registry regarding the recipient age and diagnosis [8, 9]. With a median age of 33 years, the study cohort is undoubtedly younger than the ISHLT registry (median age >50) [9]. Furthermore, only 18% of the registry patients are diagnosed with CF or non-CF bronchiectasis, whereas this was >80% in our cohort [8]. Therefore, we decided to compare the outcomes of this study with patients undergoing LTx for bronchiectasis in the literature.

Although the underlying mechanisms leading to bronchiectasis and treatment options are different in patients with CF versus non-CF-related bronchiectasis, treatment for patients with

Table 5: Perioperative outcomes

Parameters	PALR—all (n = 26)	s.p. pneumonectomy (n = 2)
LTx procedure type, n (%)		
Bilateral	23 (89)	
Right single <sup>a</sup>	3 (11)	2 (100)
Donor lung size reduction		None
Lobar LTx	3 (12)	
Non-anatomical resection	1 (4)	
LTx incision, n (%)		
Clamshell	12 (46)	2 (100)
Anterolateral thoracotomy	10 (38)	
Posterolateral thoracotomy	4 (15)	
HU-LTx, n (%)	3 (12)	None
Preoperative ECLS, n (%)		
VV ECMO	2 (8)	Non
CIT 1st lung (min)	311 (266–385)	301 (291–)
CIT 2nd lung for bilateral LTx (min)	510 (410–553)	
Duration of LTx (min) <sup>b</sup> (n = 23)	493 (400–550)	385
Estimated blood loss (ml) <sup>b</sup> (n = 13)	2000 (900–2750)	N/A
Transfusion (units)		
Packed red blood cells <sup>b</sup> (n = 19)	5 (2–8)	4.5 (3–)
Fresh frozen plasma <sup>b</sup> (n = 19)	2 (0–7)	0 (0–0)
Platelets <sup>b</sup> (n = 19)	0 (0–1)	1 (0–)
Intraoperative ECLS, n (%)		
Off pump	13 (50)	
VA ECMO	7 (27)	
CPB	5 (19)	2 (100)
VV ECMO	1 (4)	
Postop ECLS, n (%)		
None	21 (81)	2 (100)
VA/VV ECMO	5 (19)	
ICU stay (days)	11 (6–17)	7 (7)
Hospital stay (days)	36 (23–46)	23 (23–)
Complications, any, n (%)	18 (69)	2 (100)
Tracheostomy	5 (19)	
Revision	9 (35)	
Haemothorax	5 (19)	
Pleural effusion	3 (12)	
Bronchial dehiscence	1 (4)	
90-Day mortality	2 (8)	0

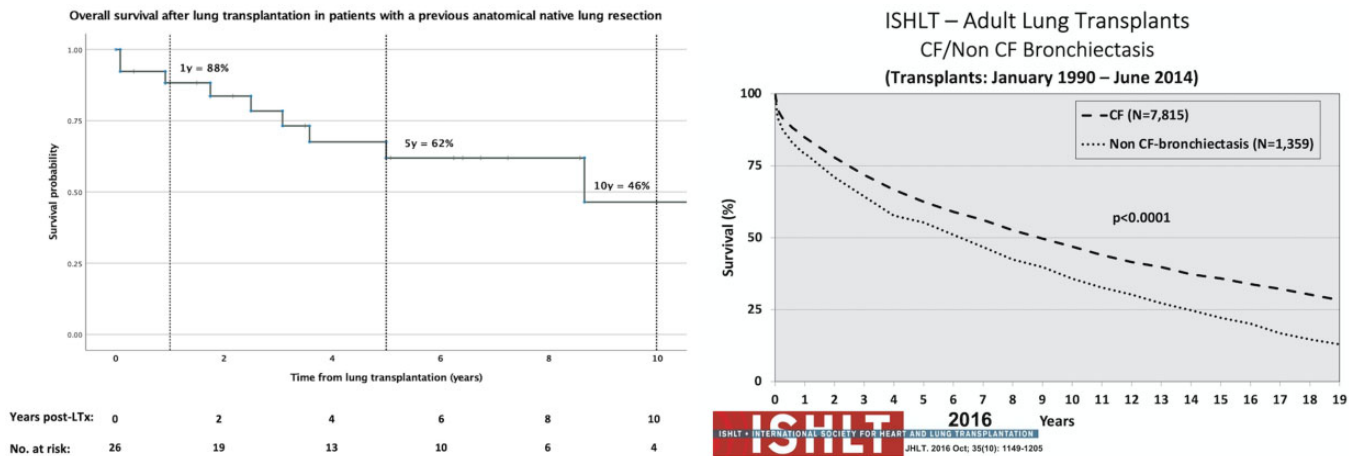
Values are median (first to third quartiles) or n (%).

<sup>a</sup>Two right single LTx were performed after previous contralateral pneumonectomies and the other right single LTx was performed after an ipsilateral lobectomy.

<sup>b</sup>Variable with missing data, number of patients with complete data are given in parenthesis.

CIT: cold ischemic time; CPB: cardiopulmonary bypass; ECLS: extracorporeal life support; ECMO: extracorporeal membrane oxygenation; HU-LTx: high urgent LTx; ICU: intensive care unit; LTx: lung transplantation; N/A: not available; PALR: previous anatomical lung resection; s.p.: status post; VA: venoarterial; VV: venovenous.

respiratory failure is similarly limited to LTx [10]. Rusanov *et al.* [11] looked at the outcomes of LTx in patients with bronchiectasis and reported comparable long-term survival (8.4 years for CF and 7.1 years for non-CF cohorts) with our cohort and the ISHLT registry. In-hospital mortality was notably higher for non-CF patients (21%) likely to be related to increased utilization of CPB in the early years of the program [11]. Recently, Rolla *et al.* [12] reported no hospital mortality for CF patients with previous thoracic procedures undergoing LTx. In our cohort, early mortality rate was 8% after LTx related to surgical complications. Notably, CPB was the choice of intraoperative support in these patients. If required, ECMO is the preferred intraoperative ECLS method during LTx nowadays [13].



**Figure 2:** Kaplan-Meier survival curve of lung transplant recipients with a previous anatomical native lung resection compared to the survival curve for patients with bronchiectasis undergoing LTx from the ISHLT registry slides [8]. Source: <http://www.isHLT.org/research-data/registries/ttx-registry/ttx-registry-slides>

**Table 6:** Long-term outcomes

Parameters	PALR (n = 26)	s.p. pneumonectomy (n = 2)
FEV1% @ 1 year <sup>a</sup> (n = 22)	75 (59–85)	61 (48–)
CLAD, any, n (%)	10 (39)	1 (50)
BOS	8 (31)	1 (50)
RAS	1 (4)	
BOS/RAS combined	1 (4)	
Mortality, n (%)	9 (35)	1 (50)
CLAD	6 (23)	1 (50)
Early postop	2 (8)	
Infectious	1 (4)	
Follow-up time after LTx (months)	43 (17–83)	107 (60–)

Values are median (first to third quartiles) or n (%).

<sup>a</sup>Variable with missing data and number of patients with complete data are given in parenthesis.

BOS: bronchiolitis obliterans syndrome; CLAD: chronic lung allograft dysfunction; FEV<sub>1</sub>: forced expiratory volume in 1 s; LTx: lung transplantation; PALR: previous anatomical lung resection; RAS: restrictive allograft syndrome; s.p.: status post.

Previous studies looking at the impact of previous cardiothoracic procedures are limited with the inclusion of a wide range of surgical procedures in the assessment of LTx outcomes [1, 2, 14]. The largest study to date investigating the role of previous major resection in LTx candidates found an increased risk of dialysis and 90-day mortality early after LTx, but acceptable long-term outcomes [7]. Similar to our report, this study also included patients with both lobectomies (80%) and pneumonectomies (20%). However, only 13% of their cohort had bronchiectasis for LTx indication and 15% of the lung resections were performed after a previous LTx. Furthermore, the prevalence of bilateral LTx was much lower (60%) than in our cohort (89%). They also did not list the indication, timing and laterality of previous lung resections [7].

All previous lung resections in our cohort were performed by an open procedure. In general, redo thoracotomies carry an increased risk for complications related to adhesions [15]. Due to increased risks at the operated side, one might think of starting implantation from the non-operated 'clean' side during LTx. In

the case of bilateral sequential LTx, ventilation-perfusion scintigraphy has an important role to answer the question of which lung should be implanted first. Common practice is to start from the least perfused lung to avoid haemodynamic compromise during LTx [16]. The strategy in this cohort was mostly the same, regardless of the previous resection side, explantations were usually started on the least perfused side. In case of a smaller discrepancy between the sides, around 40–60% range, we tend to start implanting the right lung first, since the vascular bed is larger in the right lung and exposure of the right hilum is superior, compared to left, especially if a sternum-sparing anterior thoracotomy is used.

The rate of lobar LTx varies across centres ranging from 4% to as high as 24% [17]. In our cohort, there were 3 lobar LTx (12%). One would expect to observe higher size-reduced LTx rates in patients with previous lung resection due to expected reduction in chest cavity volume. Whether compensatory lung growth or alveolar dilatation, increase in the remaining lung volume after pulmonary resection is a well-known phenomenon [18]. Although the donors were more healthy, the Kyoto group demonstrated compensatory lung growth in living LTx donors after lower lobectomy [19]. When we look at the donor/recipient size matching, the stature of full-size LTx recipients was relatively normal and the donor/recipient height ratio was well balanced. Whereas lobar LTx cases were small-stature recipients receiving lungs from relatively taller donors. Although body height alone is not a good indicator for ideal size matching, our results indicate that postresection changes in the chest cavity do not increase the need for donor size reduction in patients with CF or non-CF bronchiectasis undergoing bilateral LTx.

Completion pneumonectomy carries substantial risks associated with bleeding after an anatomical lung resection. Surgical anatomical planes of hilar vascular structures are usually distorted intrapleurally, rendering dissection difficult with increased risk of accidental vascular injuries. In case of difficulties, intraparenchymal dissection may facilitate exposure of vascular planes. Alternatively, central intrapericardial control of pulmonary veins may increase the safety of hilar dissection. Regarding the right pulmonary artery, planes medial to the superior vena cava or intrapericardial access may be used for dissection. On the left side, however, division of ductus Botalli may ease mobilization of the pulmonary artery. In cases of pericardial adhesions, a posterior approach may be

preferred starting from the division of the bronchus and then the vessels during left completion pneumonectomy [20]. In case of bleeding, central control is essential to avoid catastrophic complications. When this manoeuvre is not possible, ECLS—especially CPB—may be considered to establish haemodynamic stability and to control the bleeding. Although the routine use of intraoperative ECMO has been recently popularized [21], we personally tend to avoid ECMO whenever possible to avoid unwanted effects of anticoagulation during LTx surgery. We noted excessive bleeding problems especially after initiation of ECMO support during LTx in patients with post-thoracotomy adhesions in this study. Recently, we experienced that using an energy device (like the Aquamantys™ Bipolar Sealer) is quite effective during difficult pneumonectomies under ECLS.

Although the number is limited to 2 patients in our cohort, previous pneumonectomy requires special considerations during LTx related to postpneumonectomy changes [6]. Here, we refer to metachronous pneumonectomy performed months or years before contralateral LTx. Piotrowski *et al.* [22] reported the first successful single LTx 8 months after a contralateral pneumonectomy in a paediatric patient with CF and asymmetric thorax. The French experience is the largest series to date summarizing the surgical considerations in this challenging patient group [6]. Considering surgical incisions, right single LTx were performed via clamshell incisions, which consist of a limited contralateral anterior thoracotomy in both patients with previous left pneumonectomies in our series. Depending on the surgeons' experience, these procedures can safely be performed via posterolateral thoracotomy or median sternotomy as well [6]. In some patients, postpneumonectomy syndrome (PPS) like changes may occur due to extreme rotation of the heart and the great vessels towards the empty hemithorax [23]. In such patients, preoperative CT scan should be carefully examined when planning the cannulation strategies and size matching [22]. Undoubtedly, CPB is the choice of ECLS during implantation in these patients. We were able to perform these procedures using central cannulation without noted difficulties. In cases of difficulties in central cannulation due to rotation of the heart, femoral venous access seems to be a good solution. It should be noted that rotation of intrathoracic inferior vena cava may preclude the advancement of the venous cannula towards the heart. In such cases, using cervical approach cannulation of the right jugular vein may be indicated [6]. Indeed, adhesions related to previous lung resection after pneumonectomy are not a major concern due to the contralaterality of the planned single LTx procedure. There are other factors to take into consideration, such as the size of allograft and dissection techniques during implantation. In cases of severe asymmetry an oversized single LTx may be considered [24]. Regarding anastomoses of hilar structures, PPS like changes may create technical difficulties regardless the laterality of the procedure [25]. Here, alongside mediastinal dissection and repositioning manoeuvres, it is important to maintain lengthy arterial and venous cuffs to avoid overstretching after reperfusion. Patients with established PPS undergoing single LTx may also be a candidate for simultaneous prostheses implantation [26]. Possibilities are countless when considering LTx associated with priori, simultaneous or delayed pneumonectomy. Ris *et al.* [26] reported the first successful bilateral LTx after previous pneumonectomy in a patient with destroyed lung. Although unilateral LTx remains the preferred approach in this unique subset of LTx candidates, a bilateral LTx may be considered in appropriate candidates after careful benefit-risk assessment.

Other than established contraindications, history of a previous thoracic surgery, including anatomical lung resections alone, is

not considered an absolute contraindication rather a risk factor to LTx candidacy [3]. However, surgical experience in completion pneumonectomy is warranted. Candidates with a previous pneumonectomy consist of the most risky population in this group. Anatomical changes implying PPS should be carefully examined and the surgical plan should include laterality of transplant, cannulation strategies, size matching and implantation techniques to avoid any catastrophic event during LTx. Ideally, these procedures should be performed in experienced centres in our opinion. In general, LTx remains controversial in patients with the history of previous lung tumour. Two patients from our cohort underwent pulmonary lobectomies followed by oncological treatment modalities due to stage IIB primary lung cancer in 1 and lung metastasis of neuroblastoma in another paediatric patient. Multiple factors should be considered when evaluating a patient with the history of malignancy for LTx [27]. The decisions to proceed with an LTx were made due to the absence of other contraindications, the disease-free interval of >5 years and progressive worsening of respiratory function in both patients. The patient with a history of lung cancer is still alive 8 years after initial lung tumour treatment and 2 years after LTx with no signs of relapse. Sadly, the other patient died during early postoperative period after LTx. Decision to proceed with an LTx after any malignancy is not always straightforward. In selected patients, LTx may be an option after careful evaluation including the oncologist's opinion [3].

## Limitations

Besides the multicentre strength of the study, it has several limitations. Other than its retrospective nature, the main limitation is the lack of a comparison group within the multicentre cohort. A propensity score matching analysis is frequently utilized to generate a control group when conducting multicentre database analysis. Due to the unavailability of a uniform database among participating centres, such analysis was not possible. As a result of shortage of publications on this very selected subset of LTx candidates, we did not perform a systematic review as well. Instead, we executed a focused literature review including all high-quality articles, especially in patients with a previous pneumonectomy. Furthermore, our cohort consisted of patients from 7 European centres only. The present study is conducted under the umbrella of ESTS LTx working group that has members from 21 centres in 14 countries in Europe, North America and the Middle East. Not all the members participated in data collection. Moreover, some large volume centres from Europe are not a member of the working group, which further increases the bias in this study. Future efforts are warranted to engage other centres, especially from Europe in developing a prospective multicentre LTx database under ESTS. Finally, some of the important variables such as estimated blood loss and transfusion requirements and primary graft dysfunction score were not available for all patients.

## CONCLUSION

In conclusion, the history of anatomical native lung resection is a rare clinical entity in LTx candidates. The majority of LTx candidates are young and diagnosed with CF or non-CF-related bronchiectasis. Although the numbers were limited, survival after LTx in patients with previous anatomical lung resection, including

pneumonectomy, is good and comparable to reported conventional LTx for CF and non-CF-related bronchiectasis.

## Funding

Ilker Iskender has received a fellowship grant from the European Society for Organ Transplantation. Dirk Van Raemdonck is supported by the Broere Charitable Foundation. Laurens J. Ceulemans is supported by a KU Leuven University Chair funded by Medtronic, a post-doctoral grant from the University Hospitals Leuven (KOOR-UZ Leuven) and an Research Foundation Flanders (FWO) project (G090922N).

**Conflict of interest:** none declared.

## Data availability

The data supporting the findings of this study will be made available on reasonable request to the corresponding author (Laurens J. Ceulemans).

## Author contributions

**Ilker Iskender:** Data curation; Formal analysis; Investigation; Methodology; Visualization; Writing—original draft. **Ylenia Pecoraro:** Data curation; Investigation; Writing—review & editing. **Paula Moreno Casado:** Data curation; Investigation; Resources; Writing—review & editing. **Bartosz Kubisa:** Data curation; Investigation; Resources; Writing—review & editing. **Marco Schiavon:** Data curation; Investigation; Resources; Writing—review & editing. **Eleonora Faccioli:** Data curation; Investigation; Writing—review & editing. **Jonas Ehrsam:** Data curation; Investigation; Writing—review & editing. **Francesco Damarco:** Data curation; Investigation; Writing—review & editing. **Mario Nosotti:** Data curation; Investigation; Resources; Writing—review & editing. **Ilhan Inci:** Data curation; Investigation; Resources; Writing—review & editing. **Federico Venuta:** Data curation; Investigation; Resources; Writing—review & editing. **Dirk Van Raemdonck:** Conceptualization; Methodology; Resources; Supervision; Visualization; Writing—review & editing. **Laurens J. Ceulemans:** Methodology; Resources; Supervision; Visualization; Writing—review & editing.

## Reviewer information

Interactive CardioVascular and Thoracic Surgery thanks Giuseppe Marulli, Meinoshin Okumura, David Schibilsky and the other, anonymous reviewer(s) for their contribution to the peer review process of this article.

## REFERENCES

- [1] Omara M, Okamoto T, Arafat A, Thuita L, Blackstone EH, McCurry KR. Lung transplantation in patients who have undergone prior cardiothoracic procedures. *J Heart Lung Transplant* 2016;35:1462–70.
- [2] Shigemura N, Bhama J, Gries CJ, Kawamura T, Crespo M, Johnson B *et al.* Lung transplantation in patients with prior cardiothoracic surgical procedures. *Am J Transplant* 2012;12:1249–55.
- [3] Leard LE, Holm AM, Valapour M, Glanville AR, Attawar S, Aversa M *et al.* Consensus document for the selection of lung transplant candidates: an update from the International Society for Heart and Lung Transplantation. *J Heart Lung Transplant* 2021;40:1349–79.
- [4] Puri V, Tran A, Bell JM, Crabtree TD, Kreisel D, Krupnick AS *et al.* Completion pneumonectomy: outcomes for benign and malignant indications. *Ann Thorac Surg* 2013;95:1885–91.
- [5] Van Raemdonck D, Neyrinck A, Verleden GM, Dupont L, Coosemans W, Decaluwé H *et al.* Lung donor selection and management. *Proc Am Thorac Soc* 2009;6:28–38.
- [6] Pimpec-Barthes FL, Thomas PA, Bonnette P, Musso S, DeFrancquen P, Hernigou A *et al.* Single-lung transplantation in patients with previous contralateral pneumonectomy: technical aspects and results. *Eur J Cardiothorac Surg* 2009;36:927–32.
- [7] Ganapathi AM, Speicher PJ, Castleberry AW, Englum BR, Osho AA, Davis RD *et al.* The effect of prior pneumonectomy or lobectomy on subsequent lung transplantation. *Ann Thorac Surg* 2014;98:1922–9.
- [8] Yusef RD, Edwards LB, Dipchand AI, Goldfarb SB, Kucheryavaya AY, Levvey BJ *et al.*; International Society for Heart and Lung Transplantation. The Registry of the International Society for Heart and Lung Transplantation: thirty-third adult lung and heart-lung transplant report-2016; focus theme: primary diagnostic indications for transplant. *J Heart Lung Transplant* 2016;35:1170–84. [https://ishlregistries.org/downloadables/slides/2016/lung\\_adult.pptx](https://ishlregistries.org/downloadables/slides/2016/lung_adult.pptx)
- [9] Chambers DC, Perch M, Zuckermann A, Cherikh WS, Harhay MO, Hayes D Jr *et al.*; International Society for Heart and Lung Transplantation. The International Thoracic Organ Transplant Registry of the International Society for Heart and Lung Transplantation: thirty-eighth adult lung transplantation report—2021; focus on recipient characteristics. *J Heart Lung Transplant* 2021;40:1060–72.
- [10] Mauchley DC, Daley CL, Iseman MD, Mitchell JD. Pulmonary resection and lung transplantation for bronchiectasis. *Clin Chest Med* 2012;33:387–96.
- [11] Rusanov V, Fridman V, Wille K, Kramer MR. Lung transplantation for cystic fibrosis and non-cystic fibrosis bronchiectasis: a single-center experience. *Transplant Proc* 2019;51:2029–34.
- [12] Rolla M, Anile M, Venuta F, Diso D, Quattrucci S, De Giacomo T *et al.* Lung transplantation for cystic fibrosis after thoracic surgical procedures. *Transplant Proc* 2011;43:1162–3.
- [13] Bermudez CA, Shiose A, Esper SA, Shigemura N, D’Cunha J, Bhama JK *et al.* Outcomes of intraoperative venoarterial extracorporeal membrane oxygenation versus cardiopulmonary bypass during lung transplantation. *Ann Thorac Surg* 2014;98:1936–43.
- [14] Deterbeck FC, Egan TM, Mill MR. Lung transplantation after previous thoracic surgical procedures. *Ann Thorac Surg* 1995;60:139–43.
- [15] Massard G, Lyons G, Wihlm JM, Fernoux P, Dumont P, Kessler R *et al.* Early and long-term results after completion pneumonectomy. *Ann Thorac Surg* 1995;59:196–200.
- [16] Pinho DF, Banga A, Torres F, Mathews D. Ventilation perfusion pulmonary scintigraphy in the evaluation of pre-and post-lung transplant patients. *Transplant Rev (Orlando)* 2019;33:107–14.
- [17] Silva JS, Olland A, Massard G, Falcoz PE. Does lobar or size-reduced lung transplantation offer satisfactory early and late outcomes? *Interact CardioVasc Thorac Surg* 2020;31:93–7.
- [18] Paisley D, Bevan L, Choy KJ, Gross C. The pneumonectomy model of compensatory lung growth: insights into lung regeneration. *Pharmacol Ther* 2014;142:196–205.
- [19] Shikuma K, Chen-Yoshikawa TF, Oguma T, Kubo T, Ohata K, Hamaji M *et al.* Radiologic and functional analysis of compensatory lung growth after living-donor lobectomy. *Ann Thorac Surg* 2018;105:909–14.
- [20] Muysens FE, Rivière A d I, Defauw JJ, Dossche KM, Knaepen PJ, van Swieten HA *et al.* Completion pneumonectomy: analysis of operative mortality and survival. *Ann Thorac Surg* 1998;66:1165–9.
- [21] Hoetzenecker K, Benazzo A, Stork T, Sinn K, Schwarz S, Schweiger T *et al.*; Vienna Lung Transplant Group. Bilateral lung transplantation on intraoperative extracorporeal membrane oxygenator: an observational study. *J Thorac Cardiovasc Surg* 2020;160:320–7.e1.
- [22] Piotrowski JA, Splittgerber FH, Donovan TJ, Ratjen F, Zerkowski HR. Single-lung transplantation in a patient with cystic fibrosis and an asymmetric thorax. *Ann Thorac Surg* 1997;64:1456–8.
- [23] Shen KR, Wain JC, Wright CD, Grillo HC, Mathisen DJ. Postpneumonectomy syndrome: surgical management and long-term results. *J Thorac Cardiovasc Surg* 2008;135:1210–9.e6.
- [24] Sinn K, Stork T, Schwarz S, Stupnik T, Kurz M, Jaksch P *et al.*; Vienna Lung Transplant Team. Outcome of lung transplantation in cystic fibrosis patients with severe asymmetric chest cavities. *JTCVS Open* 2021;8:652–63.
- [25] Lloyd MS, Wallis C, Muthialu N, Elliott M, Bulstrode NW. Treatment of postpneumonectomy syndrome with tissue expanders: the Great Ormond Street Hospital experience. *J Plast Reconstr Aesthet Surg* 2014;67:725–8.
- [26] Ris HB, Krueger T, Gonzalez M, Ferrari E, Chollet-Rivier M, Marcucci C *et al.* Successful bilateral lung transplantation after previous pneumonectomy. *Ann Thorac Surg* 2011;91:1302–4.
- [27] Al-Adra DP, Hammel L, Roberts J, Woodle ES, Levine D, Mandelbrot D *et al.* Pretransplant solid organ malignancy and organ transplant candidacy: a consensus expert opinion statement. *Am J Transplant* 2021;21:460–74.