


REVIEW

Standardized 10-step approach for successfully performing a hysterectomy via vaginal natural orifice transluminal endoscopic surgery

Susanne Housmans^{1,2}  | Andrea Stuart^{3,4}  | Jan Bosteels^{1,5} | Jan Deprest^{1,2}  | Jan Baekelandt^{1,5}

¹Department of Development and Regeneration, Faculty of Medicine, Group Biomedical Sciences, KU Leuven, Leuven, Belgium

²Department of Obstetrics and Gynecology, University Hospitals Leuven, Leuven, Belgium

³Department of Obstetrics and Gynecology, Helsingborg Hospital, Helsingborg, Sweden

⁴Department of Clinical Sciences, Lund University, Malmö, Sweden

⁵Department of Obstetrics and Gynecology, Imelda Hospital, Bonheiden, Belgium

Correspondence

Andrea Stuart, Department of Clinical Sciences, Lund University, Malmö, Sweden.

Email: andrea.stuart80@gmail.com

Abstract

Vaginal natural orifice transluminal endoscopic surgery (NOTES) is a novel technique for minimally invasive gynecological surgery. Adequate training and standardization are key elements to patient safety and quality of care. Based on consensus statements and expert opinion; we report a step-by-step guidance for hysterectomy via natural orifice transluminal endoscopy. A detailed description is presented of pre- and postoperative care, and the instruments and equipment used, and surgical steps are illustrated by photographic images. This report can guide surgeons in their training to perform a hysterectomy via NOTES.

KEYWORDS

hysterectomy, natural orifice transluminal endoscopic surgery, NOTES, vaginal hysterectomy, vNOTES

1 | INTRODUCTION

Hysterectomy is one of the most frequently performed gynecological surgeries.^{1,2} Many different techniques have been described and the technique of choice is based on the surgical indication, patient characteristics, and surgeon's skills and preference. The Cochrane review by Aarts et al¹ on the surgical approach to hysterectomy for benign indications reports vaginal hysterectomy to be the procedure with the fastest convalescence. However, no difference was found between vaginal vs laparoscopic, and laparoscopic vs robot-assisted

hysterectomy for the main outcomes; return to normal activity, intra-operative visceral injury, and major long-term complications. Over the last 20 years, laparoscopic hysterectomy or laparoscopically assisted vaginal hysterectomy have gained importance, mainly resulting in a reduction in abdominal hysterectomies.^{3,4} A novel technique in the field of endoscopic surgery is natural orifice transluminal endoscopic surgery (NOTES), using the natural orifices of the body to enter the abdominal cavity. In gynecological surgery, the vagina is used as the natural orifice and denoted as vaginal NOTES or vNOTES, which was first described in 2012.⁵ A recent consensus paper has described

Abbreviations: NOTES, natural orifice transluminal endoscopic surgery; TVNH, total vaginal NOTES hysterectomy; USL(s), uterosacral ligament(s); VANH, vaginally assisted NOTES hysterectomy; vNOTES, vaginal natural orifice transluminal endoscopic surgery.

This is an open access article under the terms of the [Creative Commons Attribution-NonCommercial](https://creativecommons.org/licenses/by-nc/4.0/) License, which permits use, distribution and reproduction in any medium, provided the original work is properly cited and is not used for commercial purposes.

© 2022 The Authors. *Acta Obstetrica et Gynecologica Scandinavica* published by John Wiley & Sons Ltd on behalf of Nordic Federation of Societies of Obstetrics and Gynecology (NFOG).

standard terminology and the recommended training process and the need for standardization of the technique.⁶ Our group strongly recommends that surgeons proceed with vNOTES surgery by first learning vaginally assisted NOTES hysterectomies (VANH). We aim to describe and illustrate a standardized approach for vNOTES hysterectomy and the pre- and postoperative care. This manuscript is intended as guide for surgeons who are learning vNOTES.

2 | MATERIAL AND METHODS

The surgical approach for VANH and total vaginal NOTES hysterectomy (TVNH) described here is based on consensus statements for training⁶ and expert opinion. The instruments described in the paper are used in the international training courses, in which more than 1000 surgeons have been trained; alternative instrument selection is at every surgeon's discretion. This approach is in line with the training method provided by the international NOTES society (iNOTES, <http://notesurgery.org>). The last author has performed over 2000 surgeries in the last 10 years using the vNOTES technique. Ethical approval was not necessary for this manuscript as the photographic material used was approved earlier for educational and scientific publication purposes.

3 | RESULTS

3.1 | Setup of the operation room

- Operating table allowing lithotomy and Trendelenburg positions.
- Preventive measures to avoid cephalad sliding of the woman in Trendelenburg position.
- One or preferably two laparoscopic monitors on flexible arms. The main monitor is positioned centrally above the woman's abdomen during the procedure to allow for an ergonomic position of the surgeon and first assistant. When available, the second screen serves the scrub nurse.
- One instrument table.
- Two stools.

3.2 | Preparation and positioning

- The woman is under general anesthesia with muscular relaxation and gastric tube.
- Preoperative bowel preparation at the discretion of the surgeon. We generally do not perform any type of bowel preparation.
- Administration of prophylactic antibiotics according to your hospital's policy. We advise a single dose (5 g) of clindamycin vaginal cream (20 mg/g) 2 hours before the intervention and intravenous prophylaxis of 2 g of cefazolin and 1.5 g of metronidazole at induction of anesthesia. A repeat dose of 2 g of cefazolin is given 8 hours later.⁷

Key message

Vaginal natural orifice transluminal endoscopic surgery (vNOTES) is a novel technique in the field of endoscopic surgery. We propose a 10-step approach for hysterectomy via vNOTES.

- The woman is placed in dorsal lithotomy, legs abducted and hips 90° flexed. The legs are placed in boot stirrups.
- The buttocks are positioned at the edge of the table to allow vaginal instrument placement.
- One or both arms are positioned alongside the body to prevent brachial injury.
- Disinfection and draping of the perineal area as well as the abdomen, to be prepared for potential conversion to abdominal access.
- Placement of Foley catheter.

Table 1 represents a list of surgical equipment needed for a VANH.

3.3 | Surgical phases

The VANH procedure has three phases: A, B, and C. Phases A and C are vaginal and phase B is the laparoscopic phase.

3.3.1 | Phase A

This is the initial vaginal phase of the VANH procedure. The table is in a 0° position.

Step 1: Circumcision of the cervix

The medium (posterior) and short (anterior) Doyen's retractors are placed in the vagina and the cervix is grasped with two Pozzi tenacula. After infiltration of the cervix and paracervical tissue, the cervix is circumcised with a scalpel. A sponge-covered finger is then used for blunt dissection of the anterior and posterior vaginal wall (Video S1, Figures S1 and S3).

Step 2: Posterior colpotomy

With the medium Doyen's retractor placed posterior, and the tenacula pulled anterior, the cul-de-sac is opened using a forceps and scissors. The incision is stretched to about 4 cm and the medium Doyen's retractor is replaced by the long Doyen's retractor with the blade posterior of the uterus in the peritoneal cavity (Video S1).

Step 3: Anterior colpotomy

With the short Doyen's retractor pushing the vaginal wall anteriorly and the tenacula pulled posterior, the vesico-uterine peritoneal fold

TABLE 1 List of standard equipment for a vaginally assisted NOTES hysterectomy (VANH)

Conventional surgical instruments	<ul style="list-style-type: none"> • 1 scalpel • 1 anatomical forceps (long) • 2 toothed forceps (long and short) • 2 needle drivers • 2 Pozzi tenacula • 2 curved Heaney clamps • 2 ring forceps • 2 Péan clamps • 2 Mosquito forceps • 1 curved Roberts forceps • 1 Kocher clamp • 2 scissors (for dissection and sutures)
Vaginal retractors	<ul style="list-style-type: none"> • 1 6 × 3.5-cm Doyen retractor • 1 9 × 3.5-cm Doyen retractor • 1 12 × 3.5-cm Doyen retractor
Conventional laparoscopic instruments	<ul style="list-style-type: none"> • 1 5-mm or 10-mm endoscope^a • 1 5-mm vessel sealing instrument • 1–2 laparoscopic bipolar instruments • 2 endoscopic atraumatic graspers • (1 endoscopic scissors)
Specific for vNOTES	<ul style="list-style-type: none"> • vNOTES-port^b
Sutures	<ul style="list-style-type: none"> • 3 1 polyglactin braided sutures 90 cm long
Hydrodissection	<ul style="list-style-type: none"> • 1 21-gauge needle • 1 20-mL syringe • 40 mL hydrodissection mixture^c

Abbreviations: NOTES, natural orifice transluminal endoscopic surgery; vNOTES, vaginal natural orifice transluminal endoscopic surgery.

^aWe prefer a 10-mm, 30-degree, chip-on-the-tip endoscope as this minimizes collision with the other instruments.

^bWe use GelPOINT® V-Path medium (Applied Medical).

^cWe use a mixture of 40 mL of ropivacaine (2 mg/mL) with 0.2 mL of adrenaline (1 mg/mL).

is visualized and the anterior colpotomy is performed with forceps and scissors. If this step cannot be performed safely, eg, because of insufficient descent of the uterus, one could perform step 4 before step 3, bearing in mind not to damage the bladder, which should be dissected first. After the anterior colpotomy is performed, it is advised to check bladder integrity, and the short retractor is replaced by the medium Doyen's retractor with the blade anterior of the uterus in the peritoneal cavity (Video S1).

Step 4: Transection of the uterosacral ligaments

The medium and long Doyen retractors are placed respectively anterior and posterior to the uterus. Either after or before step 4, the uterosacral ligaments (USLs) are grasped with the Heaney clamps, cut, and tied off with one polyglactin 1 suture. The suture and needle are kept in a Mosquito clamp to the side of the operating field (Video S1).

Step 5: Preparation and placing of the vNOTES-port

The consensus paper⁶ reported that 94.9% of the participating surgeons use GelPOINT® V-Path medium (Applied Medical). The second most used port was a self-constructed glove-port. Our group prefers the GelPOINT® V-Path medium with three trocars inserted, positioned as an inverted triangle.⁸

The camera is inserted in the lower trocar and the two upper trocars are used for the endoscopic instruments. The tubing is connected (Video S1).

3.3.2 | Phase B

This is the endoscopic part of the procedure. The table is in a 20° Trendelenburg position. When the position of the port is verified, the abdomen can be insufflated. Usually, 10 mmHg pressure is sufficient. We prefer using multifunctional instruments so as to reduce the number of port changes of laparoscopic instruments. Our standard instruments are two fenestrated bipolar clamps, with a dual function (grasping and coagulation) and an advanced bipolar instrument used for sealing and cutting. Other instruments (eg, ultrasonic instruments, standard laparoscopic scissors) can be used at your own preference.

Step 6: Identification of the ureter and transection of the parametrium

Two fenestrated bipolar clamps are inserted in the upper trocars. Before the transection of the uterine artery and parametrium, the ureters are identified, bowel loops are mobilized out of the pelvis,

and the peritoneal cavity ventral and dorsal of the uterus is inspected for abnormalities (Figure S4). The steps of the procedure will be described as they are typically performed by a right-handed surgeon. Start at the left parametrium. The first structure encountered is the most caudal part of the parametrium containing the uterine artery. The left forceps grabs the cervix and pushes it cranially and medially, allowing the right (coagulating) instrument to be handled with minimal force. Use bipolar coagulation to coagulate the uterine artery and then change the instrument in the surgeon's right hand to the advanced bipolar instrument to seal and cut the structure (Figure 1). Meticulous coagulation is necessary, because the structures will retract behind the ring of the vNOTES-port in the pelvic sidewall after cutting, complicating the intervention if hemostasis is incomplete. While maintaining pressure on the uterus cranially and medially with the left forceps, the left parametrium is sealed and cut in a caudal to cranial direction until the left round ligament is transected. Do not transect the left infundibulopelvic ligament or ovarian ligament at this moment. If the left infundibulopelvic ligament or ovarian ligament is cut at this stage, it results in tilting of the uterus towards the right pelvic sidewall, making the transection of the right side more challenging. Now proceed to the right side of the uterus. After replacing the advanced bipolar instrument in the right hand with the bipolar forceps, the left instrument now pushes the right side of the cervix cranially and medially, and the caudal part of the right parametrium containing the uterine artery is coagulated, sealed, and cut (Figure 2). Note that the surgeon's right and left hand are crossed during this part of the procedure. To transect the upper part of the parametrium, the instruments are switched in the trocars, uncrossing the surgeon's hands, and allowing the right hand with the forceps to push the uterus cranially and medially, while the left hand operates the advanced bipolar instrument to transect the right parametrium in a caudal to cranial direction including the right round ligament (Figure 3, Video S1).

Step 7: Transection of the infundibulopelvic or ovarian ligament

One of the advantages of a VANH compared with a vaginal hysterectomy is the visibility and safety during the removal of the fallopian tubes or adnexa. Once the right round ligament is transected

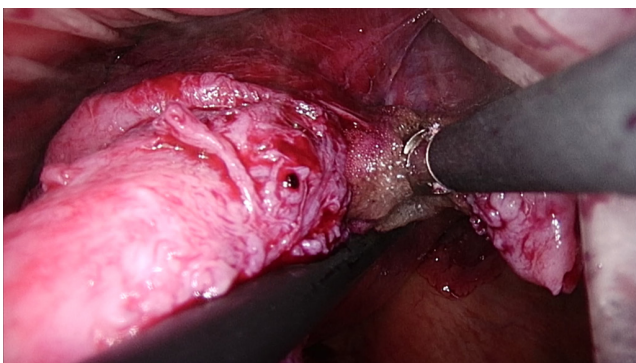


FIGURE 1 Step 6: coagulation of the left uterine artery

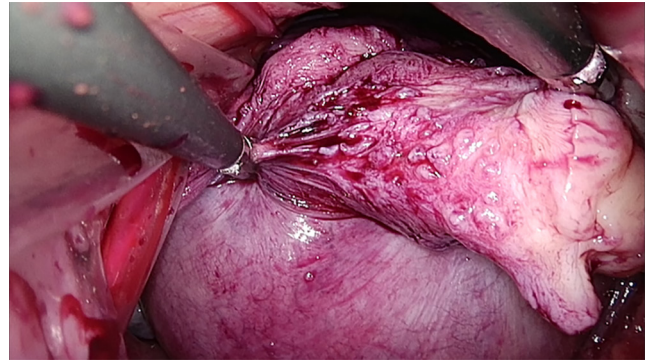


FIGURE 2 Step 6: coagulation of the right uterine artery

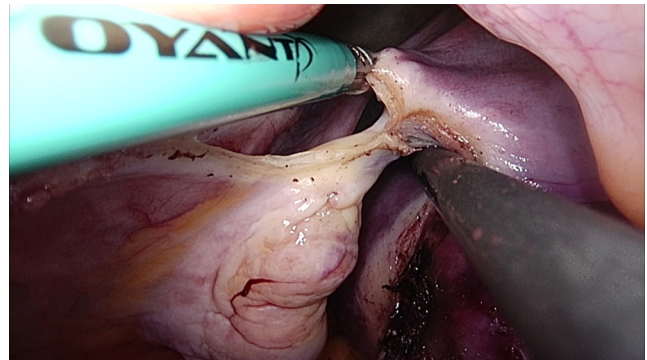


FIGURE 3 Step 6: transection of the right round ligament

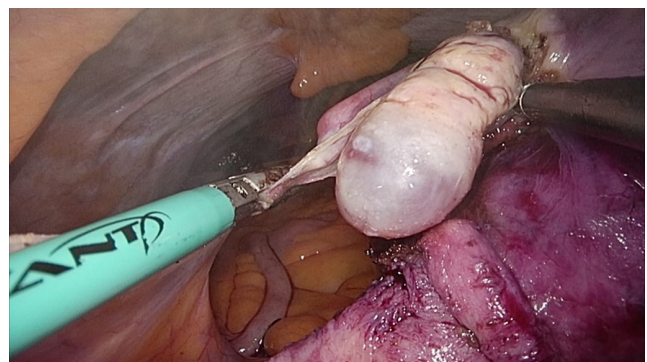


FIGURE 4 Step 7: transection of the right infundibulopelvic ligament

on the right side, the forceps (right hand) grabs the ampulla of the fallopian tube and pulls it medially, allowing the advanced bipolar instrument, held in the left hand, to transect the infundibulopelvic ligament (Figure 4, Video S1). In case of a salpingectomy, the ovarian ligament is transected first, while the forceps (right hand) pushes the uterus cranially and medially. Next, the distal part of the fallopian tube is grasped with the forceps and gently pulled medially and caudally, allowing the forceps to slide under the uterus and thus push the uterus cranially and medially at the same time. The fallopian tube can now be separated from the remaining ovary. As

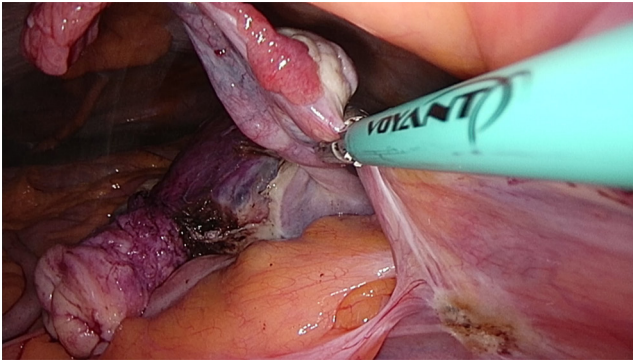


FIGURE 5 Step 7: transection of the left infundibulopelvic ligament

the ureter is usually easily visualized in the pelvic sidewall during this part of the procedure, the salpingectomy or adnexectomy can be performed safely.

After completion of the steps on the patient's right side, both instruments are changed to their original positions with the forceps in the left hand and the advanced bipolar instrument in the right hand. The same procedure for adnexectomy or salpingectomy is performed on the patient's left side (Figure 5, Video S1).

Step 8: Hemostasis and port removal

The uterus is now completely released. Before removing the vNOTES-port, the pelvic sidewalls are inspected for hemostasis. The specimen is grasped with the forceps and retracted into the vagina, the pneumoperitoneum is released, and the cap of the port is removed (Video S1, Figure S5).

3.3.3 | Phase C

For the third and final phase the table is in 10° Trendelenburg position.

Step 9: Specimen removal

For a benign, not enlarged uterus, pulling the specimen downward with the laparoscopic forceps allows placement of a tenaculum on the cervix and removal from the abdomen. If you wish to place the specimen in a bag before removal, eg, when morcellation is needed, the specimen-bag is inserted in the abdomen before releasing the pneumoperitoneum. The specimen is placed in the bag and the bag is pulled downward and out of the abdominal cavity. The specimen is manually morcellated in the bag through the wound protector-part of the port. After this the inner ring of the port is released from its position in the peritoneal cavity and the port can be removed completely (Video S1, Figure S6).

Step 10: Vault closure

The long and medium Doyen's retractors are placed in the vagina and blood collected above the vaginal opening is removed with

swabs. This allows for a second assessment of the hemostasis before closing the vault. The vault can be closed to your preference as you would at the end of a vaginal hysterectomy. We will describe the method performed at Imelda Hospital. First, one polyglactin 1 figure of eight suture is placed at 6 o'clock suturing the posterior peritoneum to the vaginal mucosa to reduce bleeding from this part of the vaginal wall. Next, the suture from the left USL is used to place a continuous, locked suture of the posterior vaginal wall to the parietal peritoneum. This suture is tied to the 6 o'clock suture and then continued to the right USL, where it is tied to the suture attached to the right USL. Second, the suture on the right USL is used to place a running suture on the anterior vaginal wall, picking up the bladder peritoneum centrally. This suture is tied to the suture attached to the left USL and then used to close the vaginal vault in two to three running sutures from the anterior to the posterior vaginal wall. During this last part, the assistant pulls the suture from the left USL to the right side. Finally, both USL sutures are tied together and cut (Video S1, Figure S7).

3.4 | Total vaginal NOTES hysterectomy

Performing an anterior and posterior colpotomy and transecting the SULs in a non-prolapsed uterus can be challenging. A TVNH can be used to tackle these difficulties.⁹ For this procedure a smaller vNOTES-port is used, reducing the range of movement. Experience with VANH is recommended. Table 2 represents a list of surgical equipment needed for a TVNH. Preparation and positioning during surgery, set-up of the operating room and postoperative management are similar to VANH.

Step 1: Circumcision of the cervix.

The vNOTES-port is placed in the vagina. Carbon dioxide is insufflated at 10 mm Hg to maintain an adequate pneumovagina. The use of an insufflation stabilization bag is advised to help prevent belching of the vaginal wall. A Manhes forceps is used to create traction on the cervix and the cervix is circumcised with a monopolar hook (preferable with built-in suction at the tip of the instrument) (Figure 6). At the anterior fornix the vaginal mucosa and bladder are pushed up, along the utero-cervical fascia with a swab in an atraumatic grasper while maintaining traction on the cervix. The same procedure is performed in the posterior fornix.

Step 2: Posterior colpotomy

When the peritoneum of the pouch of Douglas is visualized after blunt dissection, the posterior colpotomy is performed with cold scissors, using the Manhes forceps to pull the cervix caudally and ventrally (Figure S7).

Step 3: Anterior colpotomy

Once the peritoneum between bladder and uterus is identified after blunt dissection and transection of the vesico-cervical septum,

Conventional surgical instruments	<ul style="list-style-type: none"> • 1 anatomical forceps (long) • 2 toothed forceps (long and short) • 2 needle drivers • 2 Mosquito forceps • 1 curved Roberts forceps • 1 scissors
Vaginal retractors	<ul style="list-style-type: none"> • 1 6 × 3.5-cm Doyen retractor • 1 9 × 3.5-cm Doyen retractor • 1 12 × 3.5-cm Doyen retractor
Conventional laparoscopic instruments	<ul style="list-style-type: none"> • 1 5-mm or 10-mm endoscope^a • 1 Monopolar endoscopic hook (preferably with built-in suction at tip) • 1 5-mm vessel sealing instrument • 1-2 laparoscopic bipolar instruments • 1 Manhes forceps • 2 endoscopic atraumatic graspers • 1 endoscopic scissors
Specific for vNOTES	<ul style="list-style-type: none"> • vNOTES-port^b • Insufflation Stabilization Bag
Other	<ul style="list-style-type: none"> • 3 1 polyglactin braided sutures 90 cm long • Dissection swabs

TABLE 2 List of standard equipment for a total vaginal NOTES hysterectomy (TVNH)

^aWe prefer a 10-mm, 30-degree, chip-on-the-tip endoscope as this minimizes collision with the other instruments.

^bWe use GelPOINT® V-Path mini (Applied Medical); potentially also medium for phase B.

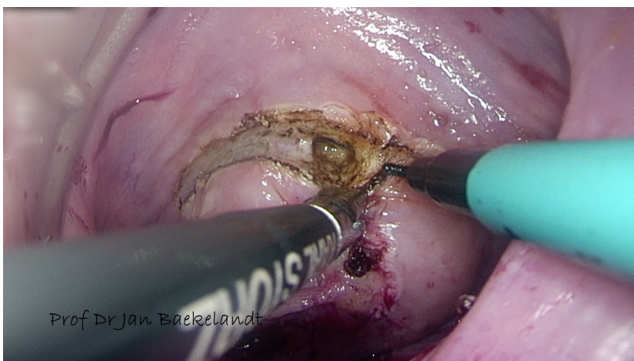


FIGURE 6 Step 1 of a total vaginal NOTES hysterectomy: circumcision of the cervix

the anterior colpotomy is performed using cold scissors, using the Manhes forceps to pull the cervix caudally and dorsally.

Step 4: Transection of the sacrouterine ligaments

The Manhes forceps pulls the cervix caudally and to the right to transect the left USL. This is done with bipolar coagulation and a cutting or sealing instrument. The same procedure is performed for the right USL.

Step 5: Preparation and placing of the vNOTES-port

In a small uterus, the entire procedure can be performed with the vNOTES-port intravaginally. With a larger uterus, replacing the port's inner ring into the peritoneal cavity after transection of the USLs, will improve visualization.

Steps 6–10 are similar to steps 6–10 described for VANH.

3.5 | Postoperative management

Whether you should maintain the indwelling catheter and use vaginal packing is debatable,^{10,11} but we propose to leave both for 4 hours after the surgery. Depending on the organization of the hospital's postoperative ward, women can be offered treatment in a daycare setting.¹²

4 | DISCUSSION

4.1 | Instruments and surgical approach

We have hereby described the 10 surgical steps of a VANH and/or TVNH as we routinely perform them. To promote a broad and safe implementation of this novel technique, we provide a standardized approach for surgeons learning vNOTES with the most commonly used vNOTES-port.⁶ This does not, of course, exclude the choice of alternative surgical approaches and different surgical instruments. The use of local infiltration of the cervix and an advanced bipolar instrument are supported by data that their use reduces blood loss and operation time.¹⁰ As the pressure of the pneumoperitoneum is lower than for conventional laparoscopic hysterectomy and no abdominal incision is made, women typically report lower pain scores compared with women undergoing a conventional laparoscopic approach.^{12,13} We found conflicting data in studies examining whether the addition of a local anesthetic in the peri-cervical infiltration at the beginning of a vaginal hysterectomy is of importance in postoperative pain.^{14,15} This factor has not been individually studied in vNOTES.

4.2 | Selecting your first cases

During the learning phase of VANH, careful case selection is advised. Similar to conventional gynecologic laparoscopic surgery, the woman must be fit to be placed in a steep Trendelenburg position with the peritoneal cavity inflated with CO₂. As reported in the consensus paper⁶ it is advised to select parous women that are not obese (body mass index <30 kg/m²), who have had no previous cesarean section or uterine surgery, nor conditions predisposing to pelvic adhesions (such as a history of endometriosis, pelvic inflammatory disease, or rectal surgery). As for vaginal surgery, uterine size up to the size comparable to 12 weeks of gestation or 280 g¹⁶ as well as the absence of a low-cervical myoma is preferred to avoid reduced operating space and visibility. More challenging cases can be tackled after the learning phase, although conditions predisposing to pelvic adhesions remain a contraindication.

4.3 | Perioperative antibiotics

The recommended regimen of antibiotics was developed in collaboration with microbiologists at Imelda Hospital, Belgium based on culture results from patients with postoperative infections. During the early developmental phase of the vNOTES technique by the same team, 2 g of cefazolin and 1.5 g of metronidazole were administered. However, an increased rate of surgical-site infections following vNOTES compared with conventional laparoscopic hysterectomy was observed and therefore the antibiotic regimen was changed. Since the change in antibiotic regimen, no increased risk of surgical-site infections has been observed in our complication database, nor demonstrated in our randomized controlled trial.¹² We speculate that the insufflation of the abdomen via the non-sterile vagina might be the reason for this early observation.

4.4 | Implementation and cost

When training in gynecologic surgery, the emphasis now is on laparoscopic surgery rather than vaginal surgery. The increasing choice of laparoscopic hysterectomy over vaginal hysterectomy will likely increase, as opportunistic bilateral salpingectomy to lower the risk of ovarian cancer is promoted.¹⁷ Although in the hands of skilled vaginal surgeons it is feasible to perform adnexal surgery at the time of vaginal hysterectomy, studies examining the feasibility of salpingectomy or adnexectomy during vaginal surgery showed failure to complete the intended removal in 25% or more.^{18,19} vNOTES allows the surgeon to perform uterine or adnexal surgery under direct vision without the need for abdominal incisions. We encourage the implementation of vNOTES as an alternative to conventional laparoscopy, not to replace conventional vaginal hysterectomy. There are currently no published studies comparing vNOTES hysterectomy with vaginal hysterectomy, and our group is planning a multicenter randomized controlled trial on

the subject. As with other new technologies, the use of specific instruments increases the direct cost, but to our knowledge there are no studies assessing the indirect and long-term costs comparing vNOTES hysterectomy and laparoscopic hysterectomy. Two studies have reported on costs as secondary outcome comparing vNOTES hysterectomy with laparoscopic hysterectomy.^{12,20} The first reported no difference in direct hospital costs, the latter reported an increased cost of vNOTES, which was attributed to the use of disposables.

5 | CONCLUSION

By proposing this standardized 10-step approach for successfully performing a VANH and TVNH, we aim to provide guidance to surgeons who are training in vNOTES surgery. Training and standardization are important factors in our scrutiny to evaluate this new technique for its effectiveness and long-term safety before the widespread implementation of vNOTES hysterectomy in daily clinical practice can be recommended. The reader must understand that complying with this 10-step approach proposal is by itself far from sufficient to start performing vNOTES hysterectomies. It is imperative to follow a vNOTES training program to guide a surgeon in the safe transition from being a laparoscopic or vaginal surgeon to becoming a skilled and safe vNOTES surgeon.

CONFLICT OF INTEREST

JBa discloses consultancy for Applied Medical and SH discloses honoraria for teaching from Applied Medical. The remaining authors have stated explicitly that there are no conflicts of interest in connection with this article.

AUTHOR CONTRIBUTIONS

SH contributed to writing—original draft preparation, review, and editing. AS contributed to writing, review, and editing. JBo and JD contributed to review and editing. JBa contributed to conceptualization, methodology, and writing—review and editing.

ORCID

Susanne Housmans  <https://orcid.org/0000-0001-5148-4883>

Andrea Stuart  <https://orcid.org/0000-0002-5131-6297>

Jan Deprest  <https://orcid.org/0000-0002-4920-945X>

REFERENCES

1. Aarts JW, Nieboer TE, Johnson N, T et al. Surgical approach to hysterectomy for benign gynaecological disease. *Cochrane Database Syst Rev* 2015;(8):CD003677.
2. European Union. Surgical operations and procedures statistics 2019 [2020 June 14]. <https://ec.europa.eu/eurostat/statistics-explained/pdfscache/37391.pdf>.
3. Healthcare RBNio Medical practice variations—Hysterectomy 2020.
4. Jorgensen EM, Modest AM, Hur HC, Hacker MR, Awtrey CS. Hysterectomy practice patterns in the Postmorcellation era. *Obstet Gynecol*. 2019;133:643-649.

5. Su H, Yen C-F, Wu K-Y, Han C-M, Lee C-L. Hysterectomy via transvaginal natural orifice transluminal endoscopic surgery (NOTES): feasibility of an innovative approach. *Taiwan J Obstet Gynecol.* 2012;51:217-221.
6. Kapurubandara S, Lowenstein L, Salvay H, Herijgers A, King J, Baekelandt J. Consensus on safe implementation of vaginal natural orifice transluminal endoscopic surgery (vNOTES). *Eur J Obstet Gynecol Reprod Biol.* 2021;263:216-222.
7. Till SR, Morgan DM, Bazzi AA, et al. Reducing surgical site infections after hysterectomy: metronidazole plus cefazolin compared with cephalosporin alone. *Am J Obstet Gynecol.* 2017;217(187):e1-e11.
8. Baekelandt J, Cavens D. GelPOINT (applied medical) is a suitable port for Transvaginal NOTES procedures. *J Gynecol Surg.* 2016;32:257-262.
9. Baekelandt J. Total vaginal NOTES hysterectomy: a new approach to hysterectomy. *J Minim Invasive Gynecol.* 2015;22:1088-1094.
10. Jeppson PC, Balgobin S, Rahn DD, et al. Comparison of vaginal hysterectomy techniques and interventions for benign indications: a systematic review. *Obstet Gynecol.* 2017;129:877-886.
11. Rachaneni S, Dua A. Interventions to reduce morbidity from vault hematoma following vaginal hysterectomy: a systematic review and meta-analysis. *Int Urogynecol J.* 2019;30:1061-1070.
12. Baekelandt JF, De Mulder PA, Le Roy I, et al. Hysterectomy by transvaginal natural orifice transluminal endoscopic surgery vs laparoscopy as a day-care procedure: a randomised controlled trial. *BJOG.* 2019;126:105-113.
13. Sao CH, Chan-Tiopianco M, Chung KC, et al. Pain after laparoscopic surgery: focus on shoulder-tip pain after gynecological laparoscopic surgery. *J Chin Med Assoc.* 2019;82:819-826.
14. Gluck O, Feldstein O, Barber E, et al. The effect of preemptive local anesthesia on postoperative pain following vaginal hysterectomy: a randomized controlled trial. *Eur J Obstet Gynecol Reprod Biol.* 2021;267:269-273.
15. Hristovska AM, Kristensen BB, Rasmussen MA, et al. Effect of systematic local infiltration analgesia on postoperative pain in vaginal hysterectomy: a randomized, placebo-controlled trial. *Acta Obstet Gynecol Scand.* 2014;93:233-238.
16. Chrysostomou A, Djokovic D, Edridge W, van Herendael BJ. Evidence-based guidelines for vaginal hysterectomy of the International Society for Gynecologic Endoscopy (ISGE). *Eur J Obstet Gynecol Reprod Biol.* 2018;231:262-267.
17. Kotsopoulos J, Narod SA. Prophylactic salpingectomy for the prevention of ovarian cancer: who should we target? *Int J Cancer.* 2020;147:1245-1251.
18. Antosh DD, High R, Brown HW, et al. Feasibility of prophylactic salpingectomy during vaginal hysterectomy. *Am J Obstet Gynecol.* 2017;217(605):e1-e5.
19. Lamblin G, Meysonnier C, Moret S, Nadaud B, Mellier G, Chene G. Opportunistic salpingectomy during vaginal hysterectomy for a benign pathological condition. *Int Urogynecol J.* 2018;29:715-721.
20. Wang C-J, Huang H-Y, Huang C-Y, Su H. Hysterectomy via transvaginal natural orifice transluminal endoscopic surgery for nonprolapsed uteri. *Surg Endosc.* 2015;29:100-107.

SUPPORTING INFORMATION

Additional supporting information may be found in the online version of the article at the publisher's website.

How to cite this article: Housmans S, Stuart A, Bosteels J, Deprest J, Baekelandt J. Standardized 10-step approach for successfully performing a hysterectomy via vaginal natural orifice transluminal endoscopic surgery. *Acta Obstet Gynecol Scand.* 2022;101:649-656. doi: [10.1111/aogs.14367](https://doi.org/10.1111/aogs.14367)