

History of the fascia iliaca compartment block

K. VERMEYLEN (*), I. VAN HERREWEGHE (**), I. LEUNEN (*), F. SOETENS (*), M. VAN DE VELDE (***)

Abstract : *Introduction* : Endeavours to block the lumbar plexus have led to the development of multiple techniques and approaches to reach its different branches. Over the years, because of the evolution of radiographic techniques (CT-scan and MRI) and the introduction of ultrasound (US) guidance, several of these techniques were compared, re-evaluated and re-appreciated.

Methods : In this paper, a review on different manners to block the lumbar plexus was performed. Systematic Search in PubMed, Medscape, and ResearchGate was done with the following MeSH terms: fascia iliaca, fascia iliaca compartment, fascia iliaca compartment block, plexus blocks, “3:1 block” and regional anesthesia.

Results : Recently, the fascia iliaca compartment block (FICB) has regained interest in blocking the different branches of the lumbar plexus. By performing a FICB, the goal is to block the femoral nerve (FN), the lateral femoral cutaneous nerve (LFCN) and the obturator nerve (ON). This block evolved from a blind para-vascular infra-inguinal technique to an US guided supra-inguinal technique. The history of the FICB is discussed in this paper.

Keywords : Fascia iliaca block ; fascia iliaca compartment ; lower extremity blocks ; “3:1 block”.

INTRODUCTION

To understand the emergence of the fascia iliaca compartment block (FICB), knowledge of the anatomy of the pelvic region is fundamental. The fascia iliaca (FI) is the fascia covering the iliacus muscle (IM) and the psoas muscle (PM). The PM is composed of a deep and superficial part. The deep part originates from the transverse processes of the first lumbar vertebra till the fifth lumbar vertebra. The superficial part originates from the lateral surfaces of the body of the last thoracic and the first 4 lumbar vertebrae and from neighbouring intervertebral discs. The IM originates from the iliac fossa and iliac crest, joins the PM and both insert on the lesser trochanter of the femur. The IM, the PM and the FI are the borders of a virtual space, called the FI compartment that extends from the lumbar vertebrae to the lesser trochanter. The femoral nerve

(FN), the lateral femoral cutaneous nerve (LFCN), and the obturator nerve (ON) originate from the lumbar plexus and pass through this virtual space. Theoretically, these 3 nerves can be blocked by injecting local anesthetic agents (LA) under the FI with a single needle insertion, and subsequently provide additional postoperative analgesia for major hip and knee surgery in an elegant and minimal invasive way.

The goal of this paper is to clarify the history of the different approaches of the FICB. The FICB evolved from a blind para-vascular infra-inguinal technique to an ultrasound (US)-guided supra-inguinal technique. An important landmark for these different approaches is the place of injection of the LA with regard to the inguinal ligament (IL). Recently, the supra-inguinal approach has gained popularity over the infra-inguinal approach.

METHODS

In this paper, a review on different manners to block the lumbar plexus was performed. Systematic Search in PubMed, Medscape, and ResearchGate was done with the following MeSH terms: fascia iliaca, fascia iliaca compartment, fascia iliaca compartment block, plexus blocks, “3:1 block” and regional anesthesia.

K. VERMEYLEN, MD, PHD ; I. VAN HERREWEGHE, MD ; I. LEUNEN, MD ; F. SOETENS, MD ; M. VAN DE VELDE, MD, PHD, EDRA. (*). Dept. of Anesthesia, AZ Turnhout, Turnhout, Belgium.

(**) Dept. of Anesthesiology, UZ Leuven, Katholieke Universiteit Leuven, Leuven, Belgium.

(***) Dept. of Cardiovascular Sciences, KU Leuven and Department of Anesthesiology, UZ Leuven, Katholieke Universiteit Leuven, Leuven, Belgium.

Corresponding author : Kris Vermeylen, AZ Turnhout, Steenweg op Merksplas 44, 2300 Turnhout. Tel. : +32 477655065. E-mail : Kris.vermeylen@gmail.com

Paper submitted on Nov 7, 2018 and accepted on June 19, 2019.

Conflict of interest : None.

RESULTS

More than 5.000 articles were retrieved using all MeSH terms. After removing duplicates and articles not related to lower extremity blocks, 186 articles were screened using these search criteria referring to the fascia iliaca (compartment) block. Case reports and non-relevant literature were excluded, leaving 32 articles assessed for eligibility and included in the review.

An increase in publications on the FICB is noticed since the 1980s, with exponential increase in the last 4 to 5 years. This increase is probably due to the introduction of US. Articles were categorized by approach and by date. Over the years, the FICB evolved from a landmark to an US guided technique.

Landmark techniques

The “3-in-1 block” of Winnie

In 1973, Winnie described a technique to block the lumbar plexus with an inguinal paravascular injection (1). He called this technique the “3-in-1 block” referring to the fact that he assumed to block the 3 nerves of the lumbar plexus with one single injection. At that time, the perivascular concept was already well established for the brachial plexus (the brachial plexus and vascular structures are enveloped within one sheet of fascia from the cervical vertebrae to the distal axilla) and was the basis for anesthesia of the arm with one injection. Before Winnie’s study, it was presumed that the different branches of the lumbar plexus were located too deep and were positioned too distant from each other to obtain an easy and complete anesthesia with one injection (2).

Winnie inserted a needle in a slide cephalad direction, just below the IL and lateral of the femoral artery, until a paresthesia was elicited in the FN territory (1). A remarkable detail is that during injection, firm pressure was applied distal from the needle in order to promote cephalad spread of the LA. Even after removal of the needle, pressure was maintained in combination with an upward massaging gesture of the area (1) (Fig. 1). Winnie studied the effects of different volumes of LA: 15, 20, 25 and 30 mL. All patients in the different groups had a block of the FN, LCFN and ON, except in the group that received 15 mL. In this group, only 3 out of 5 patients had a block of the 3 nerves, suggesting a volume effect (1). The mechanism at that time was not fully understood but a local effect on the FN and an overflow to the supra-inguinal part of the FI

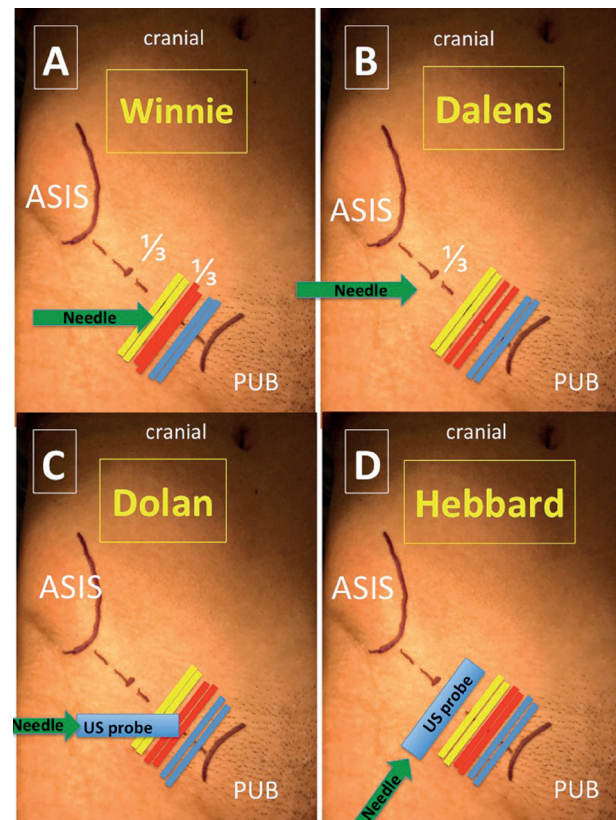


Fig. 1. — Comparison of the different approaches according to A) Winnie, B) Dalens, C) Dolan (first US-guided infra-inguinal approach) and D) Hebbard (first US-guided supra-inguinal approach).

Yellow stripe : femoral nerve ; red stripe : femoral artery ; blue stripe : femoral vein.
US : ultrasound. PUB : symphysis pubic. ASIS : anterior superior iliac spine.

(due to the pressure) are the most plausible reasons (Fig. 1).

Dalens’ modification of the “3-in-1 block”

In a number of patients, the “3-in-1 block” failed to provide adequate anesthesia in areas supplied by the LCFN and ON. On the other hand, several case reports described paresis of hip flexion, knee extension and adduction of the thigh, and absence of sensation in the FN and LCFN territories, after injection of LA inferomedial of the anterior superior iliac spine (ASIS) in an attempt to block only the LCFN (3). Sharrock concluded that it is possible to obtain lumbar plexus anesthesia by injecting into the interfascial plane at a site away from the FN and the femoral artery (3). In 1989, Dalens described this approach of the FICB in a pediatric population (4). He hypothesized that sufficient amounts of LA injected immediately posterior to the FI, could spread at the inner surface of this fascia and contact the FN, LCFN and ON that run, at least partly,

within this FI compartment. For this approach, the patient was positioned supine and a projection of the IL was drawn on the skin from the pubic tubercle to the ASIS and divided in 3 equal parts. The site of puncture was marked 0.5 cm caudal to the point where the lateral joined the medial 2 thirds of this line (Figure 1). The needle was inserted at a right angle to the skin and was advanced until two “plops”, corresponding to the puncture of the fascia lata and FI, were felt. Following negative aspiration, LA was injected with pressure exerted caudally to the puncture site to promote proximal spread of the LA as in Winnie’s approach. After needle withdrawal, a brief massage was performed to the region, in a distal to proximal direction, in order to promote proximal spread of the LA in the FI compartment.

Dalens compared this new approach with the “3-in-1 block” in 120 children. Instead of paresthesia, he used a nerve stimulator (NS) to elicit muscle twitches in the quadriceps muscle, which he thought was more objective in children. Compared to the group that received a “3-in-1 block”, the group that received a FICB had more adequate analgesia (20% vs >90%) and more sensory block of the LFCN and ON, but less motor block.

Capdevila compared the “3-in-1 block” of Winnie and the FICB of Dalens in 100 adult patients in 1998 (5). He performed both blocks with 35 mL of a mixture of LA and contrast. Sensory and motor block of the ON in the “3-in-1 block” was respectively 52% and 32%. Dalens’ FICB did even do worse with respectively 38% and 20%. Blockade of the FN, LFCN and the ON was achieved in 38% in the “3-in-1 block” and in 34% in the FICB. This is in sharp contrast with the 100% success in the study of Winnie and with the results of the study of Dalens. Due to a higher incidence of simultaneous block of the FN and the LFCN, Capdevila concluded that the Dalens’ FICB produced better results than Winnie’s “3-in-1 block”.

The spread of contrast on X-ray was significantly more medial into the pelvic region after the “3-in-1 block” than after a Dalens’ FICB, which spread more lateral towards the iliac crest (6). In a minority, there was spread of contrast to the roots of the lumbar plexus. At that time, these findings had no clinical consequences and no modifications were proposed.

Stevens’ modification of the FICB of Dalens

In 2007, Stevens modified the FICB as described by Dalens. The needle was advanced

through the skin at a right angle 1 cm above the IL, as opposed to 0.5 cm caudal of the IL in the classic Dalens’ method, at the junction of the middle. His hypothesis was that injecting 40 mL of LA above the IL would allow the LA to block the lumbar plexus at a higher level. He demonstrated a significant reduction in morphine consumption at 24 hours (37 mg vs 22 mg) when this technique was compared to a sham block (7).

US guided techniques

With the introduction of US, the targeted structures could be visualized, possibly leading to a better position of the needle and a better deposition of LA. Several authors compared the same approach using either the landmark technique/NS or US guided technique (with or without additional guidance technique).

US guided 3:1 block by Marhofer (8)

In 1997, Marhofer randomized 40 patients, scheduled for hip surgery after trauma, to undergo a “3-in-1 block”, as described by Winnie, with 20 mL bupivacaine 0.5%, by assistance of either a NS or US. His most important findings were that onset time with US was significantly shorter and that the quality of the sensory block also improved for all three nerves (FN, LFCN and ON) (80% for the NS technique versus 90% for the US guided technique). These last results are however in contrast with the MRI findings of his publication in 2000 (9). In that study, spread of LA on MRI was lateral, caudal and slightly medial with subsequent blockade of the FN, LFCN and the anterior branch of the ON. There was no cephalad spread and no block of the posterior branch of the ON. There is therefore no evidence of a complete block of the ON with the “3-in-1 block” as described by Winnie. No clear explanation for this discordance between those two studies was provided by the author. Different volumes were used in then different studies and strangely enough where the authors did use US in the 1997 study (and concluded that using US was superior to NS), they only used NS in the more recent MRI study.

US guided FICB by Dolan (10)

With the introduction of US, the FI could be visualised allowing a more accurate position of the needle and a better deposition of LA below the FI. The first US-guided technique of the FICB as described by Dalens, was published by Dolan in

2008 (10). He randomized 80 patients to undergo FICB, with 30 mL of LA, by either loss of resistance (double pop) or US guidance. In the US group, US was used throughout the procedure to identify the FI and to guide the needle to the correct plane in transverse axis view. LA was noted to flow in a medial and lateral direction under the FI (10) (Fig. 1). In the US group, there was a significant increase in the incidence of sensory loss in the medial aspect of the thigh (from 60% to 95%), of complete loss of sensation in the anterior, medial and lateral aspects of the thigh (from 47% to 82%) and of motor block of the FN and ON (10). The double pop technique can be misleading due to multiple fascial planes in the inguinal area, and thus lead to false pops. Using US, the right plane is clearly visualized and the spread within this plane can be appreciated.

Up until today this technique is still used as a part of analgesia after hip surgery (10).

In a study in 2013 using a slightly modified approach with 30 mL of LA, Shariat was not able to demonstrate an opioid sparing effect and a difference in pain intensity after total hip arthroplasty compared to a sham block (11). However, the incidence of sensory block in the lateral, anterior and medial thigh was very low (respectively 31, 38 and 25%), and in only 2 of the 16 patients all 3 nerves (FN, LCFN, ON) were blocked (11).

Multiple reasons can explain this result. First, Shariat performed his block after surgery, which might induce bias (11). Second, he only used 20 mL of LA that may have caused a suboptimal spread of LA. Finally, he placed his US probe in the femoral crease and inserted the needle in plane from lateral to medial to cross the FI at the level of the sartorius and the IM, which is more distal than in the approach of Dolan.

Hebbard's longitudinal supra-inguinal US-guided approach (S-FICB)

In 2011, Hebbard described a longitudinal supra-inguinal US-guided approach to the FI compartment, which he also examined in a human cadaver model (12). He hypothesized that it may be advantageous to deposit the LA above the IL in the FI compartment, because the LFCN leaves the FI plane at the IL, and branches of the FN to the IM and acetabulum leave proximal to the IL. Hebbard positioned the US probe perpendicular over the IL, close to the ASIS, in the para-sagittal plane (cranio-caudal orientation) (12). This probe position gives a clear view of the FI, SM, iliopsoas muscle (IPM) and abdominal internal oblique muscles. The probe

then was moved inferiorly and medially, along the line of the IL but remained lateral of the femoral artery and nerve. The deep circumflex iliac artery should be identified superficial to the FI 1-2 cm superior to the IL, as it forms a landmark for the needle placement (Fig. 2). Hebbard introduced the needle in plane 2-4 cm inferior to the IL and advanced the needle through the FI at the level of the IL. One mL of LA was injected, which should form a lens deep to the FI. The needle is advanced into this lens and further LA is injected. Through this process of hydro-dissection, the needle can be passed cranially, deep into the FI compartment and towards the iliac fossa (Fig. 1) (12). An injection was considered successful when there was a good cranial spread of LA underneath the FI. In 150 patients, 20 mL of LA reliably blocked both the FN and the LFCN. This was confirmed in 6 cadavers in which 12 S-FICB's were performed with 20 mL aniline blue. The FN was stained in all cases, the LFCN in 10 out of 12 cases and the ilioinguinal nerve in 7 out of 12 cases. A limitation of Hebbard's study was that the involvement of the ON was not examined nor clinically, nor in the cadavers.

Clinical implication by Desmet et al. of the S-FICB

Desmet et al. used this supra-inguinal fascia iliaca compartment block (S-FICB) for analgesia after total hip arthroplasty (13). They randomized 88 patients into a control group and a group receiving a S-FICB with 40 mL ropivacaine 0.5%. Compared with Hebbard's approach, they slightly modified the technique. The US probe was rotated in line with the umbilicus until a clear "bow-tie-sign" was identified. This "bow-tie-sign" is formed by the fasciae of the iliacus muscle, the Sartorius muscle and the muscles of the abdominal wall. The needle perforates the FI 1 cm above the IL and 40 mL of LA is injected. Although Hebbard et al named this approach supra-inguinal, the FI compartment was entered underneath the IL (Fig. 2) (13). Desmet demonstrated a reduction in morphine consumption of 45% at 24 and 48 hours, and lower pain scores in the first 4 hours and at 24 hours postoperatively in the S-FICB group. This study showed also sensory block of the ON in 86% of the patients. In 70% of the patients, the 3 target nerves (FN, LCFN and ON) were blocked. The hypothesis was that injecting a high volume of LA as proximal as possible in the FI compartment results in a more proximal block of the target nerves (13).

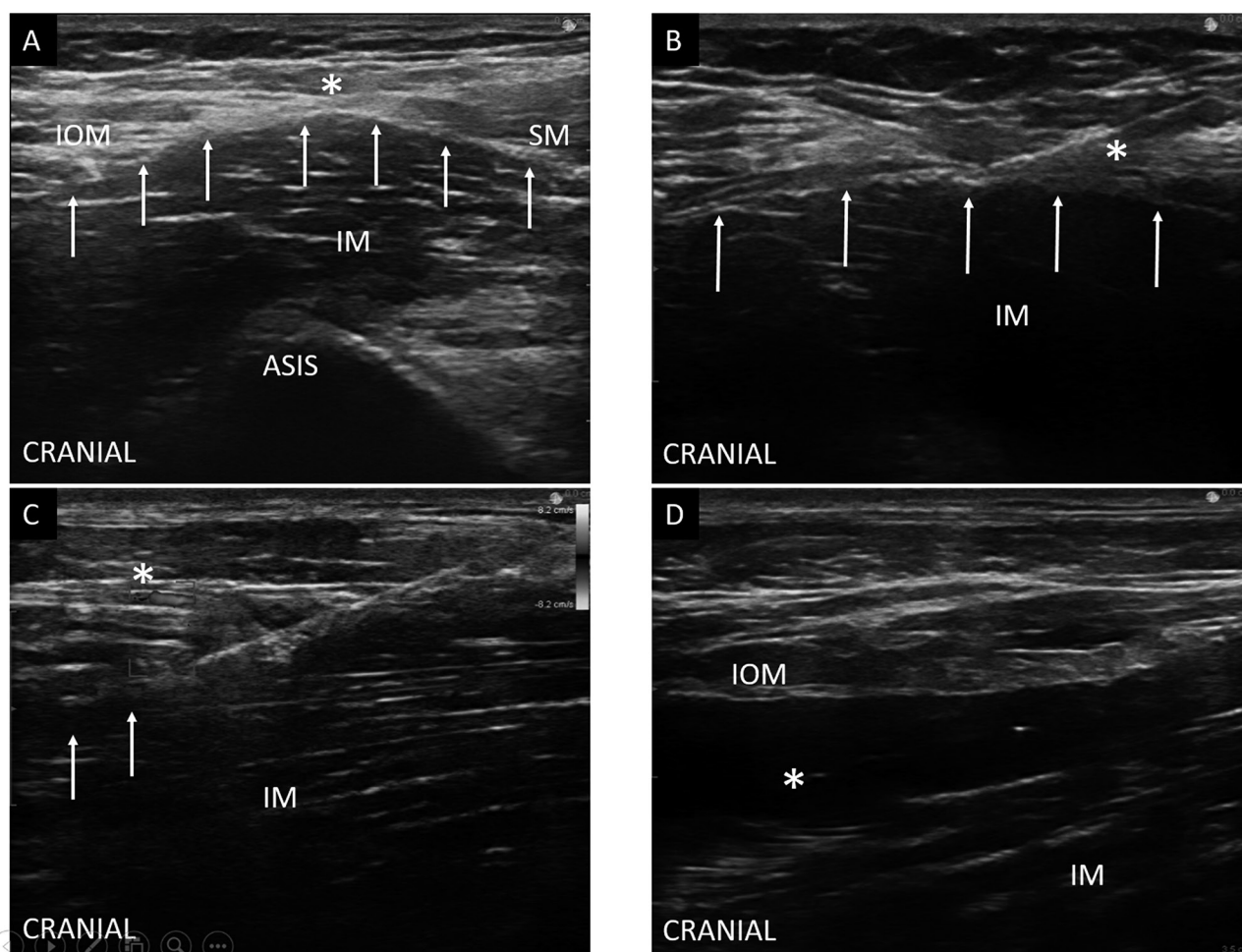


Fig. 2. — Ultrasound image of a longitudinal supra-inguinal FICB

Panel A : Ultrasound image with identification of relevant structures for FICB (*): Bow-tie sign.

Panel B : in plane needle introduction with the tip of the needle under the FI. White arrows: Fascia iliaca, (*): needle.

Panel C : injection of LA under the FI, note the position of the deep circumflex iliac artery superficial to the FI (*). White arrows : LA spreading under the FI

Panel D : US image after injection of 40 mL of LA with cranial spread of LA. (*): LA

IOM : internal oblique muscle, SM : sartorius muscle, IM : iliacus muscle, ASIS : anterior superior iliac spine, white arrows: fascia iliaca, (*): Bow-tie sign.

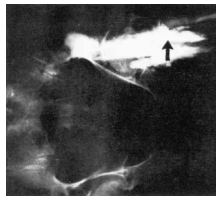
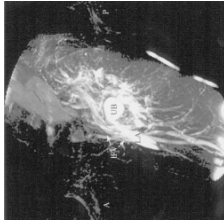
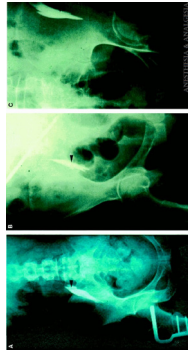
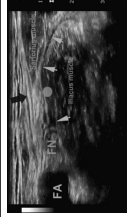
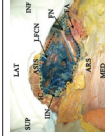
INDICATIONS AND CLINICAL USE

The FICB is commonly used for hip and knee surgery, since both are associated with significant postoperative pain (14, 15, 16). The opioid sparing effect of the FICB makes it especially suitable for elderly patients. Fewer opioid-related side effects such as nausea, urinary retention, and constipation result in higher patient satisfaction (17). Delirium causes significant morbidity and mortality in elderly patients following surgery for proximal femur fractures (17, 18). In one large prospective study, severe pain caused by proximal femur fractures was associated with a nine-fold increased risk of delirium (19). Postoperative analgesia with FICB may reduce the incidence of cognitive dysfunction up to 70% (20).

The efficacy and simplicity of the FICB has also been demonstrated outside the operating room. In several studies, the block was performed in the emergency department by non-anesthesiologists (junior doctors, paramedics, emergency physicians, junior registrars, nurses and orthopedic residents) with a high success rate and little complications (3, 21-26). Also in pediatric anesthesia, the FICB has gained popularity as an alternative to other regional anesthetic techniques. After Dalens' study in 1989, other FICB studies in the pediatric population were performed (27-29). The FICB is an alternative for caudal anesthesia in selected cases.

Few articles on continuous FICB were published (6, 20, 30). Especially in case of catheters, placed without US, the results were not consistent.

Table 1.

Block	Author	Type study	Local anesthetic / Volume	Guidance tool	Technique	Outcome	Remarks / Limitations	Picture
3-in-1 block	Winnie et al. ¹	Clinical, N=20	Not specified. Minimum 20mL	Blind	Inguinal paravascular technique	Lumbar plexus can be blocked. The minimum amount of local anesthetic should be at least 20mL.	Onset of anesthesia of the LFCN is slower and more absent compared to the ON.	
	Marhofer et al. ⁷	Clinical, N=7	Bupivacaine 0.5%, 30mL	Blind	Nerve stimulation	Lateral, medial, and caudal, spread of the local anesthetic effectively blocks the FN and LFCN, as well as the distal anterior branch of the ON.	MRI shows lateral, caudal, and slight medial spread of local anesthetic. No cephalad spread of the local anesthetic with blockade of the lumbar plexus.	
FICB	Capdevila et al. ⁴	Clinical, N=100	Bupivacaine 0.5%, 15mL and lidocaine 2% with 1:200,000 epinephrine, 15mL	Blind	Nerve stimulation	The quality of sensory and motor blockade after continuous 3-in-1 block depend on the location of the catheter tip under the fascia iliaca and influence initial pain.	Radiologic imaging showed that the direction of a catheter threaded under the fascia iliaca is unpredictable.	
	Foss et al. ²¹	Clinical, N=48	Mepivacaine 1% with 1:200,000 epinephrine, 40mL	Blind	Loss of resistance	Superior pain relief in FICB group compared to intramuscular morphine.	Emergency setting	
	Dolan et al. ⁸	Clinical, N=80	Lidocaine 2%, 15 mL and bupivacaine 0.5%, 15mL	USG and blind	Loss of resistance or ultrasound guidance	Ultrasound-guided FICB increased the frequency of sensory loss in the medial thigh and increased the frequency of femoral and obturator motor block.	Use of loss of resistance can be inaccurate to differentiate between fascia lata or fascia iliaca.	
	Shariat et al. ⁹	Clinical, N=32	Ropivacaine (0,5%) vs NaCl 0,9%, 30mL	USG	Transverse probe position/ injection	No analgesic effect of the FICB compared to a sham block group during the first 24 hours post-operatively.	FICB was performed after surgery when NRS>3. Higher volumes had been preferable?	
	Hebbard et al. ¹⁰	Cadaver, N=6	Aniline blue dye 0.25%, 20mL	USG	Longitudinal supra-inguinal approach	FN and LFCN were simultaneously stained and surrounded by dye in all cases it was present.	Supra-inguinal injection. LFCN could not be identified in one cadaver.	
	Stevens et al. ⁵	Clinical, N=44	Bupivacaine 0.5% with 1:200,000 epinephrine 30mL, clonidine 150µg 1mL, NaCl 0,9% 9mL vs. NaCl 0,9% 40mL	Blind	Loss of resistance technique, (modified)	Significant morphine sparing effect	Depositing admixture more cranially (modified FICB) blocks FN, LFCN, ON, genitofemoral and iliohypogastric nerve.	

	Dulaney-Cripe et al. ¹⁵	Clinical, N=42	Ropivacaine 0.5% 60 mL and ropivacaine 0.2% 10mL/h	USG	Probe position not specified.	Better pain score, less opioid consumption and shorter hospital stay.	Preoperatively performed by anesthesiologists at the emergency department.
	Perrier et al. ¹⁸	Clinical, N=65	Ropivacaine 0.5% 0.5mL/kg	Blind	Loss of resistance	FICB with catheter seems to decrease the incidence of POCD compared to pain relief with morphine.	Additional studies necessary to confirm findings.
	Hanna et al. ¹⁹	Clinical, N=104	Chirocaine (TBW<40kg: 20mL TBW 40-80kg: 30mL TBW>80kg: 40mL)	Blind	Loss of resistance	Safe and effective analgesia with less systemic analgesia requirements.	Performed by junior doctors. Success rate: 67%.
	McRae et al. ²⁰	Clinical, N=24	Lidocaine 2% with 1:200,000 epinephrine 20mL and NaCl 0.9% 20mL (TBW 50-70kg:30mL TBW>470kg: 40mL)	Blind	Loss of resistance technique	Lower pain scores, alternative to parenteral analgesia and no complications seen.	Performed by paramedics. Selection bias?
	Hogh et al. ²²	Clinical, N=187	Bupivacaine 0.25% 30mL and lidocaine 2% 10 mL (TBW<50 kg: 20mL)	Blind	Loss of resistance technique	Feasible, easy to learn technique with minimal risk. Efficient supplement for conventional pain-treatment.	Performed by junior registrars in the emergency department.
	Paut et al. ²⁷	Clinical, N=20	Bupivacaine 0.25% with 1:200,000 epinephrine bolus (cf. Dalens) and bupivacaine 0.1% at 0.5mL/h per year of age	Blind	Loss of resistance technique	Bupivacaine plasma levels were within safety margins.	FICB is well tolerated and seems an effective analgesic technique in pediatric population.
	Wathen et al. ²⁶	Clinical, N=55	Ropivacaine 0.5% (TBW<20kg: 0.75mL/kg TBW>20kg: 0.5mL/kg (max. 30mL))	Blind	Loss of resistance technique	Clinically superior pain management compared to opioids.	Unblinded study. Pediatric population.
	Kim et al. ²³	Clinical, N=64	Ropivacaine 0.25% with 1:200,000 epinephrine bolus (cf. Dalens)	Blind	Loss of resistance technique	FICB reduces emergence agitation and post-operative pain.	No entire postoperative follow-up, only 20 minutes immediate effect and agitation observation.
	Paut et al. ²⁷	Clinical, N=6	Ropivacaine 0.5% or 0.375% 0.7mL/kg	Blind	Loss of resistance technique	3.5mg/kg ropivacaine is associated with high plasma concentrations outside tolerable range.	Intramuscular injection possible. Safety 0.7mL/kg ropivacaine 0.375% still has to be demonstrated.
3:1 vs FICB	Dalens et al. ³	Clinical, N=120	Lidocaine 1% and bupivacaine 0.5% with 1:200,000 epinephrine (TBW<20kg: 0.7mL/kg, 20kg<TBW<30kg: 1.5mL, 30kg<TBW<40 kg: 20mL, 40kg<TBW<50 kg: 2.5mL, TBW>50kg: 27.5mL)	Blind	3-in-1: nerve stimulation FICB: loss of resistance technique	Distribution of analgesia was significantly improved by using the FICB technique. Easy and effective block of LFCN, FN and ON.	Pediatric population
	Capdevila et al. ⁴	Clinical, N=100	Lidocaine 2% with 1:200,000 epinephrine, 15mL. Bupivacaine 0.5%, 15mL. Iopamidol (contrast), 5mL.	Blind	3-in-1: nerve stimulation FICB: loss of resistance	FICB provides faster and more consistent simultaneous blockade of the LFCN and FN. Both blocks provide effective postoperative analgesia.	Spread of local anesthetic to all three nerves (LFCN, FN and ON) is difficult to obtain and unpredictable.

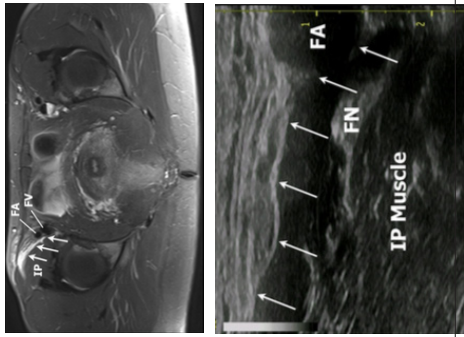
	Kong et al. ²⁹	Clinical, N=50	Ropivacaine 0.375% 20mL and ropivacaine 0.15% 5mL/h	USG	Transverse in-plane technique	Continuous FICB and continuous FNB are equally effective after patella surgery.	FICB was found safer and easier to perform.	
	Swenson et al. ³²	Clinical, N=10	Bupivacaine 0.25% with 1:200,000 epinephrine, 30mL	USG	3-in-1: US FICB; US	US and MRI showed consistent superior extension of local anesthetic to the level of the retroperitoneum for both techniques. There was reliable clinical effect on the FN and LFCN. No evidence of ON block.	Ultrasound to guide needle position and magnetic resonance imaging (MRI) to define local anesthetic distribution.	
	Deniz et al. ³¹	Clinical, N=70	Bupivacaine 0.25% 30mL	USG	FICB: USG 3-in-1; USG and nerve stimulation	No difference was found in analgesic effect between both groups. They significantly decreased VAS scores compared to control group.	These techniques should be used for analgesia after hip prosthesis. ACTH levels are lower in regional anesthesia group compared to control group.	
FICB vs FNB	Brisbane Orthopaedic & Sports Medicine writing Committee et al. ¹⁹	Clinical, N=98	Ropivacaine 0.2%, 60mL. Followed by 8mL/h	Blind	FNB: nerve stimulation FICB: loss of resistance	Fentanyl PCA consumption in FICB is not significantly different to FNB.	FICB is a safe and effective alternative to FNB.	
	Farid et al. ²⁸	Clinical, N=23	Ropivacaine 0.2%, 0.5mL/kg to a maximum of 40mL.	Blind	FNB: nerve stimulation FICB: loss of resistance	No statistical significant difference in morphine consumption.	Pediatric population	

Table 1 gives an overview of studies regarding the FICB and its predecessors.

DISCUSSION, RECOMMENDATIONS AND FUTURE OF THE FICB

Over the years, the FICB block evolved from a blind “3-in-1 block” to a US-guided supra-inguinal technique. For years, the true value of the “3-in-1 block” has been doubtful. Blocking the FN, LFCN and ON with one landmark-based injection inferior of the IL is anatomically unlikely. Although there is still doubt about the anatomical rationale of the FICB, numerous studies have shown its positive clinical impact on patient outcome and opioid consumption (Table 1) (10, 12, 17).

There is a consensus on the use of US as a guidance tool and the positive effect of it on block characteristics. As it has been proven for many other regional block techniques, US guidance has had a big impact on block characteristics and some studies have compared the blind technique to the US guided technique (10, 31). It is however difficult to compare these studies due to different approaches. Some studies used a blind technique and others used a US guided technique. To complicate it even more, different landmark-based procedures and also different US-guided techniques are described (1, 4, 10, 32). Recently, the positive effects of a supra-inguinal approach in comparison with infra-inguinal approaches, leads to gaining popularity of this block.

A lot of controversies still exists. First, there is no consensus on the injection volume or the concentration of LA. Second, the evaluation of the involvement of the ON remains a weakness in FICB studies. Most studies used sensory block to investigate the ON. However, sensory innervation of the ON is variable and thus unreliable. Evaluation of the motor block of the ON in clinical settings is hampered due to the postoperative immobilization. Besides block characteristic studies, CT scan or MRI were used to investigate the involvement of the ON in the FICB (Table 1). Marhofer et al evaluated the spread on MRI of LA/contrast after a “3-in-1 block” to determine if, as suggested by Winnie (1), a cephalad spread is achieved and thus causes a blockade of the lumbar plexus (9). He showed that there was a direct spread towards the FN, an indirect lateral spread to the LFCN, and a spread to the anterior branch of the ON. No involvement of the proximal ON or the posterior branch of the ON was observed nor was there any cephalad spread that could have resulted in a lumbar

plexus blockade using a LA volume of 30 mL (9). In another MRI study, Swenson et al. showed the distribution of 30 mL of injectate, after both an US-guided “3-in-1 block” and a classic US-guided “transverse” infra-inguinal approach (10), over the surface of the IM and PM to the level of the retroperitoneum (32). For both approaches, there was a reliable clinical effect on the FN and LFCN. However, none of the injections produced evidence that the ON was blocked. The fact that Desmet et al. did demonstrate a blockade of the ON suggests that, besides the approach, the injected volume might be of importance (13).

More research is necessary to recommend the ideal volume and concentration of LA for the FICB, although it is clear that a sufficient amount of LA is needed. The ideal volume and concentration is characterized by sufficient analgesia but minimal motor block to allow early mobilization.

Limitations

This review is a synthesis of the literature concerning the different approaches and techniques of the fascia iliaca (compartment) block over the years. This is not a meta-analysis but an overview in order to distinguish the different approaches.

CONCLUSIONS

The FICB is characterized by a vast history. Over the years, many have tried to optimize this regional anesthesia technique, by attempting different approaches. Due to variations in block success, the most optimal approach and LA volume/concentration is still to be determined. Preliminary reports show that the supra-inguinal US-guided approach with 40 mL LA seems to produce the most optimal results.

References

1. Winnie AP, Ramamurthy S, and Durrani Z. 1973. The inguinal paravascular technic of lumbar plexus anesthesia: the “3-in-1 block”. *Anesth Analg*; 52:989-996.
2. Dogliotti AM. In *Narcosis-local-regional-spinal*. 1939 Chicago, SB Debour.
3. Sharrock NE. 1980. Inadvertent “3-in-1 block” following injection of the lateral cutaneous nerve of the thigh. *Anesth Analg* ;59(11):887-8.
4. Dalens B, Vanneuville G, and Tanguy A. 1989. Comparison of the fascia iliaca compartment block with the 3-in-1 block in children. *Anesth Analg* 69:705-713.
5. Capdevila X, Biboulet P, Bouregba M, Barthelet Y, Rubenovitch J, and d’Athis F. 1998. Comparison of the three-in-one and fascia iliaca compartment blocks in adults: clinical and radiographic analysis. *Anesth Analg* 86:1039-1044.

6. Capdevila X, Biboulet P, Morau D, Bernard N, Deschodt J, and Lopez S et al. 2002. Continuous three-in-one block for postoperative pain after lower limb orthopedic surgery: where do the catheters go? *Anesth Analg* 94:1001-1006
7. Stevens M, Harrison G, and McGrail M. 2007. A modified fascia iliaca compartment block has significant morphine-sparing effect after total hip arthroplasty. *Anaesth Intensive Care* 35:949-952.
8. Marhofer P, Schrogendorfer K, Koinig H, Kapral S, Weinstabl C, and Mayer N. 1997. Ultrasonographic guidance improves sensory block and onset time of three-in-one blocks. *Anesth Analg* 85:854-857.
9. Marhofer P, Nasel C, Sitzwohl C, and Kapral S. 2000. Magnetic resonance imaging of the distribution of local anesthetic during the three-in-one block. *Anesth Analgesia*; 90:119-124.
10. Dolan J, Williams A, Murney E, Smith M, and Kenny GN. 2008. Ultrasound guided fascia iliaca block: a comparison with the loss of resistance technique. *Reg Anesth Pain Med* 33:526-531.
11. Shariat AN, Hadzic A, Xu D, Shastri U, Kwofie K, and Gandhi K et al. 2013. Fascia iliaca block for analgesia after hip arthroplasty: a randomized double-blind, placebo-controlled trial. *Reg Anesth Pain Med* 38:201-205.
12. Hebbard P, Ivanusic J, and Sha S. 2011. Ultrasound-guided supra-inguinal fascia iliaca block: a cadaveric evaluation of a novel approach. *Anaesthesia* 66:300-305.
13. Desmet M, Vermeyleen K, Van Herreweghe I, Carlier L, Soetens F, and Lambrecht S et al. 2017. A Longitudinal Supra-Inguinal Fascia Iliaca Compartment Block Reduces Morphine Consumption After Total Hip Arthroplasty. *Reg Anesth Pain Med* 32: 327-333.
14. Fujihara Y, Fukunishi S, Nishio S, Miura J, Koyanagi S, and Yoshiya S. 2013. Fascia iliaca compartment block: its efficacy in pain control for patients with proximal femoral fracture. *J Orthop Sci* 18:793-797.
15. Morrison RS, Dickman E, Hwang U, Akhtar S, Ferguson T, and Huang J et al. 2016. Regional Nerve Blocks Improve Pain and Functional Outcomes in Hip Fracture: A Randomized Controlled Trial. *J Am Geriatr Soc.* 64:2433-2439.
16. Nie H, Yang YX, Wang Y, Liu Y, Zhao B, and Luan B. 2015. Effects of continuous fascia iliaca compartment blocks for postoperative analgesia in hip fracture patients. *Pain Res Manag* 20: 210-212.
17. Dulaney-Cripe E, Hadaway S, Bauman R, Trame C, Smith C, and Sillaman B et al. 2012. A continuous infusion fascia iliaca compartment block in hip fracture patients: a pilot study. *J Clin Med Res* 4: 45-48.
18. Marcantonio ER, Flacker JM, Wright RJ, and Resnick NM. 2001. Reducing delirium after hip fracture: a randomized trial. *J Am Geriatr Soc.* 49:516-22
19. Morrison RS, Magaziner J, Gilbert M, Koval KJ, McLaughlin MA, and Orosz G et al. 2003. Relationship between pain and opioid analgesics on the development of delirium following hip fracture. *J Gerontol A Biol Sci Med Sci.* 58:76-81.
20. Perrier V, Julliac B, Lelias A, Morel N, Dabadie P, and Sztark F. 2010. (Influence of the fascia iliaca compartment block on postoperative cognitive status in the elderly). *Annales francaises d'anesthesie et de reanimation*; 29:283-288.
21. Foss NB, Kristensen BB, Bundgaard M, Bak M, Heiring C, and Virkelyst C et al. 2007. Fascia iliaca compartment blockade for acute pain control in hip fracture patients: a randomized, placebo-controlled trial. *Anesthesiology* 106:773-778.
22. Godoy Monzon D, Iserson KV, and Vazquez JA. 2007. Single fascia iliaca compartment block for post-hip fracture pain relief. *J Emerg Med* 32:257-262.
23. Hanna L, Gulati A, and Graham A. 2014. The role of fascia iliaca blocks in hip fractures: a prospective case-control study and feasibility assessment of a junior-doctor-delivered service. *ISRN orthopedics*: 191306.
24. Hogh A, Dremstrup L, Jensen SS, and Lindholt J. 2008. Fascia iliaca compartment block performed by junior registrars as a supplement to pre-operative analgesia for patients with hip fracture. *Strategies Trauma Limb Reconstr* 3:65-70.
25. Kim HS, Kim CS, Kim SD, and Lee JR. 2011. Fascia iliaca compartment block reduces emergence agitation by providing effective analgesic properties in children. *J Clin Anesth* 23:119-123.
26. McRae PJ, Bendall JC, Madigan V, Middleton PM. 2015. Paramedic-performed Fascia Iliaca Compartment Block for Femoral Fractures: A Controlled Trial. *J of Emerg Med* 48:581-589.
27. Farid IS, Heiner EJ, and Fleissner PR. 2010. Comparison of femoral nerve block and fascia iliaca block for analgesia following reconstructive knee surgery in adolescents. *J Clin Anesth* 22:256-259.
28. Paut O, Schreiber E, Lacroix F, Meyrieux V, Simon N, and Lavrut T et al. 2004. High plasma ropivacaine concentrations after fascia iliaca compartment block in children. *Br J Anaesth* 92:416-418.
29. Wathen JE, Gao D, Merritt G, Georgopoulos G, and Battan FK. 2007. A randomized controlled trial comparing a fascia iliaca compartment nerve block to a traditional systemic analgesic for femur fractures in a pediatric emergency department. *Ann Emerg Med*; 50:162-171.
30. Kong M, Guo R, Chen J, Li P, and Wu Z. 2015. A Randomized Study to Compare the Analgesic Efficacy of Ultrasound-Guided Block of Fascia Iliaca Compartment or Femoral Nerve After Patella Fracture Surgery. *Cell Biochem Biophys.* 72:567-70.
31. Deniz S, Atim A, Kurklu M, Cayci T, and Kurt E. 2014. Comparison of the postoperative analgesic efficacy of an ultrasound-guided fascia iliaca compartment block versus 3 in 1 block in hip prosthesis surgery. *Agri* 26:151-157.
32. Swenson JD, Davis JJ, Stream JO, Crim JR, Burks RT, and Greis PE. 2015. Local anesthetic injection deep to the fascia iliaca at the level of the inguinal ligament: the pattern of distribution and effects on the obturator nerve. *J Clin Anesth.* 27:652-657.