



Early View

Task force report

ERS Statement on Chronic Thromboembolic Pulmonary Hypertension

Marion Delcroix, Adam Torbicki, Deepa Gopalan, Olivier Sitbon, Frederikus A. Klok, Irene Lang, David Jenkins, Nick H. Kim, Marc Humbert, Xavier Jais, Anton Vonk Noordegraaf, Joanna Pepke-Zaba, Philippe Brénot, Peter Dorfmueller, Elie Fadel, Hossein-Ardeschir Ghofrani, Marius M. Hoeper, Pavel Jansa, Michael Madani, Hiromi Matsubara, Takeshi Ogo, Ekkehard Grünig, Andrea D'Armini, Nazzareno Galie, Bernhard Meyer, Patrick Corkery, Gergely Meszaros, Eckhard Mayer, Gérald Simonneau

Please cite this article as: Delcroix M, Torbicki A, Gopalan D, *et al.* ERS Statement on Chronic Thromboembolic Pulmonary Hypertension. *Eur Respir J* 2020; in press (<https://doi.org/10.1183/13993003.02828-2020>).

This manuscript has recently been accepted for publication in the *European Respiratory Journal*. It is published here in its accepted form prior to copyediting and typesetting by our production team. After these production processes are complete and the authors have approved the resulting proofs, the article will move to the latest issue of the ERJ online.

ERS Statement on Chronic Thromboembolic Pulmonary Hypertension

Marion Delcroix¹ (co-chair), Adam Torbicki^{2*}, Deepa Gopalan^{3*}, Olivier Sitbon^{4*}, Frederikus A. Klok^{5*}, Irene Lang^{6*}, David Jenkins^{7*}, Nick H. Kim^{8*}, Marc Humbert^{4*}, Xavier Jais^{4*}, Anton Vonk Noordegraaf^{9*}, Joanna Pepke-Zaba^{7*}, Philippe Brénot¹⁰, Peter Dorfmüller¹¹, Elie Fadel¹², Hossein-Ardeschir Ghofrani¹¹, Marius M. Hoeper¹², Pavel Jansa¹³, Michael Madani¹⁴, Hiromi Matsubara¹⁵, Takeshi Ogo¹⁶, Ekkehard Grünig¹⁷, Andrea D'Armini¹⁸, Nazzareno Galie¹⁹, Bernhard Meyer²⁰, Patrick Corkery²¹ (patient representative), Gergely Meszaros²² (patient representative), Eckhard Mayer (co-chair)^{23°}, and Gérald Simonneau (co-chair)^{4°}

1. Clinical department of Respiratory Diseases, Pulmonary Hypertension Center, UZ Leuven; BREATHE, department CHROMETA, KU Leuven, Leuven, Belgium
2. Department of Pulmonary Circulation, Thrombo-embolic Diseases and Cardiology, Center of Postgraduate Medical Education, ECZ-Otwock, Otwock, Poland
3. Department of Radiology, Imperial College Hospitals NHS Trusts, London, UK
4. Université Paris-Saclay; Inserm UMR_S 999, Service de Pneumologie, Hôpital Bicêtre (AP-HP), Le Kremlin-Bicêtre, France
5. Department of Medicine – Thrombosis and Hemostasis, Leiden University Medical Center, Leiden, the Netherlands
6. Medical University of Vienna, Vienna, Austria
7. Royal Papworth Hospital, Cambridge University Hospital, Cambridge, UK
8. Division of Pulmonary, Critical Care, and Sleep Medicine; University of California, San Diego; La Jolla, California, USA
9. Department of Pulmonary Medicine, Amsterdam UMC, Vrije Universiteit Amsterdam, Amsterdam Cardiovascular Sciences, Amsterdam, the Netherlands
10. Marie Lannelongue Hospital, Paris-South University, Le Plessis Robinson, France
11. University of Giessen and Marburg Lung Center, German Center of Lung Research (DZL), Giessen, Germany. Department of Medicine, Imperial College London, London, UK. Department of Pneumology, Kerckhoff-Clinic Bad Nauheim, Germany
12. Hannover Medical School, Hannover, Germany
13. 2nd Department of Medicine - Department of Cardiovascular Medicine, First Faculty of Medicine, Charles University and General University Hospital in Prague, Czech Republic
14. Sulpizio Cardiovascular Centre - University of California, San Diego, USA
15. National Hospital Organization Okayama Medical Center, Okayama, Japan
16. National Cerebral and Cardiovascular Centre, Osaka, Japan
17. Thoraxklinik Heidelberg gGmbH at Heidelberg University Hospital, Heidelberg, Germany
18. Unit of Cardiac Surgery, Intrathoracic Transplantation and Pulmonary Hypertension, University of Pavia School of Medicine, Foundation I.R.C.C.S. Policlinico San Matteo, Pavia, Italy
19. University of Bologna, Bologna, Italy
20. Institute for Diagnostic and Interventional Radiology, Hannover Medical School, Hannover, Germany
21. PHA Ireland, Dublin, Ireland
22. PHA Europe, Hungary
23. Department of Thoracic Surgery, Kerckhoff Clinic Bad Nauheim, Germany

* Section editors; ° equal contribution

The following institutions and patient representatives are part of the European Reference Network for rare lung diseases (ERN-lung): 1-4, 7, 9, 11-13, 19-22

Author for correspondence: Marion Delcroix, Department of Respiratory Diseases, University Hospitals of Leuven, Herestraat 49, 3000 Leuven, Belgium; email marion.delcroix@uzleuven.be; Tel +32 16 346833

Running Title: Chronic Thromboembolic Pulmonary Hypertension

Word count text: 13806 (ERJ chief editor is already aware of the extensive document)

Number of figures and tables: 16/15

Number of references: 210/250

Supplement: 8 tables

Take home message: (/117 characters).

ABSTRACT (208/250)	5
LIST OF ABBREVIATIONS	6
SUMMARY OF STATEMENTS	8
SCOPE OF DOCUMENT	12
METHODS	12
1. DEFINITIONS	13
1.1 CURRENT DEFINITIONS - IS THERE A NEED TO CHANGE IT IN VIEW OF NEW DIAGNOSTIC METHODS AND THE PROPOSED REDUCED MPAP THRESHOLD FOR PH? HOW TO BEST DEFINE SYMPTOMATIC PATIENTS WITH POST-THROMBOTIC DEPOSITS BUT WITHOUT PH AT REST?	13
1.2. SHOULD CPET AND EX-RHC BE INCLUDED IN THE DEFINITION AND WITH WHAT THRESHOLDS?	13
1.3. CAN A PATIENT BE CURED OF CTEPH?.....	14
2. DIAGNOSIS	15
2.1. SHOULD SPECT REPLACE PLANAR VQ?	15
2.2. ARE DECT OR MR PERFUSION PRACTICAL ALTERNATIVES TO VQ FOR CTEPH DIAGNOSIS?	15
2.3. IS HIGH QUALITY CTPA ADEQUATE FOR DIAGNOSIS OR IS THERE A NEED FOR DIGITAL SUBTRACTION ANGIOGRAPHY (DSA)? .	17
2.4. ROLE OF NEW CT ADVANCES SUCH AS CBCT AND ADCT.....	17
2.5. WHAT IS THE UTILITY OF CARDIAC MRI IN THE DIAGNOSTIC ALGORITHM?	18
<i>MR angiography for diagnosis</i>	18
<i>RV function in evaluating PH severity at the time of diagnosis</i>	19
<i>Is non-invasive (MR based metrics) measurement of haemodynamic parameters prime time? i.e can we replace RHC by MR based data</i>	19
2.6. DIAGNOSTIC ALGORITHM	19
3. EPIDEMIOLOGY	22
3.1. INCIDENCE AND PREVALENCE OF CTEPH. IS CTEPH A COMPLICATION OF ACUTE PE, OR IS CTEPH OFTEN MISCLASSIFIED AS PE?	22
3.2. HOW MANY PATIENTS WITH PERSISTENT PERFUSION DEFECTS AFTER ACUTE PE HAVE CTEPD?	22
3.3. IS CTEPD WITHOUT PH AN EARLY STAGE OF CTEPH?.....	23
3.4. COULD CTEPD INCIDENCE BE DIFFERENT IN PATIENTS TREATED WITH VKAs AND NOACs? - COULD IT BE DIFFERENT IN PATIENTS TREATED WITH DIFFERENT NOACs? - COULD THE INCIDENCE BE INFLUENCED BY DOSING STRATEGY IN NOACs?	23
3.5. SHOULD THE INCIDENCE AND PREVALENCE OF CTEPD BE ANALYSED IN SPECIFIC SUBPOPULATIONS? COULD THIS INFORMATION BE USEFUL FOR THE SCREENING RECOMMENDATION?	23
4. FOLLOW UP AFTER ACUTE PE	25
4.1. IS EARLIER DETECTION OF CTEPH RELEVANT FOR OUTCOME?.....	25
4.2. HOW CAN A PATIENT AT HIGH RISK OF CTEPH AFTER ACUTE PE BE IDENTIFIED, AND HOW CAN WE BETTER IDENTIFY PATIENTS WHO ALREADY HAVE CTEPH WHILE PRESENTING WITH WHAT APPEARS TO BE ACUTE PE?	25
4.3. WHICH PE PATIENTS SHOULD BE SYSTEMATICALLY ASSESSED FOR THE PRESENCE OF CTEPH AND BY WHICH PRIMARY DIAGNOSTIC TEST?.....	27
4.4. WHAT IS THE OPTIMAL TIMING OF A DIAGNOSTIC STRATEGY FOR EARLY CTEPH DETECTION AFTER PE?	27
5. PATHOPHYSIOLOGY	29
5.1. VASCULAR LESION CHARACTERISTICS AND MECHANISMS OF INCREASED RESISTANCE IN CTEPH	29
<i>Obstruction of the pulmonary arteries by unresolved fibrotic clots</i>	29

<i>Secondary microvasculopathy</i>	30
<i>Impact of proximal obstructive fibrotic clots and secondary microvasculopathy on haemodynamic severity</i>	31
<i>Clinical consequences of microvasculopathy</i>	31
5.2. IMAGING OF THE PULMONARY AND BRONCHIAL CIRCULATIONS	31
<i>Computed Tomography Pulmonary Angiography (CTPA)</i>	31
<i>Magnetic Resonance Imaging (MRI)</i>	32
5.3. THE RV IN CTEPH	33
6. PULMONARY ENDARTERECTOMY (PEA).....	34
6.1. WHAT ARE THE REQUIREMENTS FOR A PEA CENTRE AND SURGEON?	34
6.2. HOW MUCH ANATOMICAL OVERLAP BETWEEN PEA AND BPA AND WHICH IS THE BEST TREATMENT FOR SEGMENTAL DISEASE?	35
6.3. WHAT IS A SUCCESSFUL OUTCOME AFTER PEA SURGERY?.....	35
6.4. HOW TO MANAGE RESIDUAL/RECURRENT DISEASE?.....	36
7. BALLOON PULMONARY ANGIOPLASTY (BPA)	38
7.1. WHAT TYPE OF CTEPH PATIENTS ARE CANDIDATES FOR BPA? WHAT IS THE ROLE OF PRE-TREATMENT WITH PH-TARGETED THERAPY PRIOR TO BPA?.....	38
7.2. WHAT ARE THE CLINICAL OUTCOMES AND EXPECTATIONS OF BPA FOR CTEPH?.....	38
7.3. WHAT ARE THE IMPORTANT COMPLICATIONS ASSOCIATED WITH BPA AND THEIR ACCEPTABLE RATES FOR AN EXPERT CENTRE?	39
7.4. WHAT ARE THE REQUIREMENTS TO ESTABLISH A BPA CENTRE? WHAT CRITERIA AND PARAMETERS DEFINE AN EXPERT BPA CENTRE?.....	40
8. MEDICAL TREATMENT.....	42
8.1. LONG-TERM ANTICOAGULATION: WHAT IS THE CURRENT STANDARD OF CARE IN CTEPH (VKAs VERSUS NOACs)?	42
8.2. PH MEDICATION: WHAT IS THE AVAILABLE EVIDENCE ON APPROVED AND NOT (YET) APPROVED PH MEDICATIONS IN CTEPH?	42
8.3. COMBINATION THERAPY: IS THERE A ROLE FOR INITIAL OR SEQUENTIAL COMBINATION THERAPY IN CTEPH?.....	43
8.4. DE-ESCALATION: WHEN AND HOW TO STOP/REDUCE PH DRUGS AFTER SUCCESSFUL BPA/PEA?	43
9. MULTIMODALITY TREATMENT	45
9.1. WHAT ARE THE CRITERIA FOR SELECTING CANDIDATES?	45
9.2. IS THERE A POTENTIAL ROLE FOR PH-TARGETED MEDICAL THERAPY PRIOR TO PEA IN PATIENTS WITH OPERABLE CTEPH? ...	45
9.3. IS THERE A ROLE FOR COMBINED PEA AND BPA IN PATIENTS WITH CTEPH?.....	45
9.4. IS THERE A ROLE FOR COMBINED USE OF PH-TARGETED THERAPY AND BPA IN PATIENTS WITH INOPERABLE CTEPH?.....	46
10. REHABILITATION	48
10.1. WHAT IS THE CAUSE OF EXERCISE LIMITATION IN CTEPH?	48
10.2. IS REHABILITATION SAFE IN CTEPH?	48
10.3 WHAT ARE THE REQUIREMENTS FOR REHABILITATION IN CTEPH?.....	48
10.4. IS REHABILITATION CLINICALLY RELEVANT AND SAFE IN PRE AND POST PEA AND BPA?	48
10.5. IS THERE A POTENTIAL ROLE FOR REHABILITATION IN CTEPH PATIENTS WITHOUT PH?	48
11. GLOBAL RESEARCH LINES	50
11.1. BIOBANK AND BASIC SCIENCE	50
11.2. PAEDIATRIC CTEPH.....	50
ACKNOWLEDGEMENTS.....	51
REFERENCES	52

Abstract (208/250)

Chronic thromboembolic pulmonary hypertension (CTEPH) is a rare complication of acute pulmonary embolism, either symptomatic or not. The occlusion of proximal pulmonary arteries by fibrotic intravascular material, in combination with a secondary microvasculopathy of vessels less than 500 μm , leads to increased pulmonary vascular resistance and progressive right heart failure. The mechanism responsible for the transformation of red clots into fibrotic material remnants has not yet been elucidated. In patients with pulmonary hypertension, the diagnosis is suspected when a ventilation/perfusion lung scan shows mismatched perfusion defects and confirmed by right heart catheterisation and vascular imaging. Today, in addition to lifelong anticoagulation, treatment modalities include surgery, angioplasty and medical treatment according to the localisation and characteristics of the lesions.

This Statement outlines a review of the literature and current practice concerning diagnosis and management of CTEPH. It covers the definitions, diagnosis, epidemiology, follow up after acute pulmonary embolism, pathophysiology, treatment by pulmonary endarterectomy, balloon pulmonary angioplasty, drugs and their combination, rehabilitation and new lines of research in CTEPH.

It represents the first collaboration of the European Respiratory Society (ERS), the International CTEPH Association (ICA) and the European Reference Network (ERN)-Lung in the pulmonary hypertension domain. The Statement summarises current knowledge but does not make formal recommendations for clinical practice.

List of Abbreviations

6MWD: 6-minute walk distance	36
ADCT: area detector computed tomography	8
BPA: balloon pulmonary angioplasty	8, 20
CBCT: cone beam computed tomography	8, 20
CE-MRA: contrast enhanced MR pulmonary angiography	18
CPB: cardiopulmonary bypass	34
CPET: cardiopulmonary exercise test	8, 14
CT: computed tomography	15
CTEPD: chronic thromboembolic pulmonary disease	8, 14
CTEPH: chronic thromboembolic pulmonary hypertension	8, 14
CTPA: computed tomography pulmonary angiography	8, 20
CTS: Canadian Thoracic Society	27
DCE-MR: dynamic contrast enhanced MR	16
DECT: dual energy computed tomography	8, 20
DHCA: deep hypothermic circulatory arrest	34
DSA: digital subtraction angiography	17
ECG: electrocardiogram	25
ECMO: extra corporeal membrane oxygenation	34
ERA: endothelin receptor antagonist	43
ERN: European Reference Network	12
ERS: European Respiratory Society	12
ESC: European Society of Cardiology	12
ex-RHC: exercise right heart catheterisation	8, 14
ICA: International CTEPH Association	12
LGE: late gadolinium enhancement	19
LV: left ventricle	14
MIP: maximum intensity projections	18
mPAP: mean pulmonary arterial pressure	8, 14
MR: magnetic resonance	8, 20
NOAC: non-vitamin K antagonist oral anticoagulant	9, 44
NT-proBNP: N-terminal pro-brain natriuretic peptide	27
PAH: pulmonary arterial hypertension	9
PAWP: pulmonary artery wedge pressure	13
PBV: pulmonary perfused blood volume	16
PDE5i: phosphodiesterase type 5 inhibitor	43
PE: pulmonary embolism	8
PEA: pulmonary endarterectomy	9, 33
PETCO ₂ : end-tidal CO ₂ tension	13
PH: pulmonary hypertension	8, 14
PVR: pulmonary vascular resistance	10, 46
RCT: randomized controlled trial	23
RHC: right heart catheterisation	13
RV: right ventricle	9, 33
sGC: guanylate cyclase stimulator	43
sPAP: systolic pulmonary arterial pressure	25
SPECT: single photon emission computed tomography	8, 20
TF: task force	12

TPR: total pulmonary resistance	45
TPVR: Total pulmonary vascular resistance	13
VA: ventriculo-atrial	23
VE/CO ₂ : ventilatory equivalent for CO ₂	13
VKA: vitamin K antagonist	9, 44
VQ: ventilation/perfusion	8, 20
VTE: venous thromboembolism	9, 24

Summary of statements

1	Definitions
1.1	All patients in whom symptoms can be attributed to post-thrombotic deposits within pulmonary arteries could be considered to have chronic thromboembolic pulmonary disease (CTEPD) with or without pulmonary hypertension (PH). Chronic thromboembolic pulmonary hypertension (CTEPH) remains the preferred term in patients <i>with</i> PH.
1.2	Cardiopulmonary exercise testing (CPET) and exercise right heart catheterisation (ex-RHC) could contribute to the definition of CTEPD helping to identify the main cause of exercise limitation in the presence of comorbidities and in patients <i>without</i> resting PH.
1.3	In many patients with CTEPH, resting mean pulmonary arterial pressure (mPAP) is normalised by surgical or multimodality treatment and patients feel healthy, but it is unlikely to return all pulmonary vessels back to normal.
2	Diagnosis
2.1	Ventilation/perfusion (VQ) scintigraphy remains the most effective screening tool to exclude CTEPD. VQ single photon emission computed tomography (SPECT) has been shown to be superior to planar imaging and is the methodology of choice. Because the transition from planar to SPECT may not be easy for clinicians unfamiliar with the three-dimensional anatomy, two-dimensional planar images can be reprojected from SPECT without losing diagnostic accuracy.
2.2	Alternative perfusion techniques such as dual energy computed tomography (DECT) and magnetic resonance (MR) perfusion have numerous theoretical advantages over VQ but are more technically challenging, expensive, with limited availability and lack multicentre validation. Hence, they are not replacing VQ in current clinical practice.
2.3	High quality CT pulmonary angiography (CTPA) is adequate for diagnosis of proximal CTEPH but a negative CTPA, even if high quality, does not exclude CTEPH as distal disease can be missed.
2.4	Cone beam (CBCT) and area detector CT (ADCT) allow for more accurate visualisation of subsegmental vasculature and have been shown to be useful for procedural guidance for balloon pulmonary angioplasty (BPA). The benefits of the technology require validation in prospective trials before recommendation for routine clinical use.
2.5	MR imaging is not yet fully integrated into the CTEPH diagnostic algorithm because its use is heavily dependent on local practice and is routinely implemented only in a few high-volume institutions where there is clustering of expertise.
3	Epidemiology
3.1	CTEPH is a rare and underdiagnosed complication of pulmonary embolism and, upon first presentation, may be misclassified as acute pulmonary embolism (PE).
3.2	Persistent perfusion defects after acute PE are common, but have highly variable clinical relevance, ranging from completely asymptomatic to established CTEPH.
3.3	We have no evidence to suggest that CTEPD without PH is an early stage of CTEPH because of lack of data on its natural history.

3.4	Current literature could not demonstrate any difference in CTEPH incidence in patients with VTE treated with vitamin K antagonists (VKAs) and non-vitamin K antagonist oral anticoagulants (NOACs), but rigorous studies have not been done.
3.5	Screening for CTEPH in asymptomatic patients with specific risk factors could be effective but is not supported by any data.
4	Follow up after acute PE
4.1	Earlier diagnosis of CTEPH may be relevant for patient outcomes. It can be achieved by targeting patients with acute PE with risk factors for CTEPH or with radiological findings suggesting CTEPH.
4.2	Patients at risk of CTEPH can be identified by accurate assessment of the CTPA images used to diagnose PE, individual risk factors for CTEPH, and symptoms of functional limitations and/or right heart failure in the course of PE.
4.3	Echocardiography is the test of choice in patients with suspected CTEPH. Other tests such as Leiden CTEPH rule-out criteria, VQ scan or CPET could be used to exclude the presence of CTEPH and/or to establish an alternative diagnosis.
4.4	The optimal timing for considering CTEPH in patients with PE is at the routine 3-month follow-up visit; but earlier work-up may be necessary in highly symptomatic or deteriorating patients.
5	Pathophysiology
5.1	Current knowledge suggests that two types of vascular lesions exist in CTEPH: proximal fibrotic obstruction in large elastic pulmonary arteries and a secondary microvasculopathy in pulmonary vessels < 500 µm.
5.2	Morphological delineation of pulmonary and bronchial circulation is possible with CTPA whilst MR imaging (MRI) permits both anatomical visualisation and semi-quantitative analysis of the extent of broncho-pulmonary shunting. None of these techniques can quantify the microvasculopathy.
5.3	RV is less adapted in CTEPH than in idiopathic pulmonary arterial hypertension (PAH), but recovers largely after successful pulmonary endarterectomy (PEA).
6	PEA
6.1	Requirements for a PEA centre are based on expert opinion only, but ≥50 cases as centre annual volume, and a properly trained surgeon have been proposed.
6.2	There is likely considerable anatomical overlap between BPA and PEA, but segmental and subsegmental disease are suitable for surgery in expert, high volume centres.
6.3	Successful outcome after PEA is multifactorial and assumes in-hospital mortality < 5%, survival of 90% at 3 years, improved functional class and quality of life.
6.4	Residual PH after PEA presents in about 50% and represents a target for recently introduced medical therapies and BPA. There is some evidence for their use if post-PEA mPAP remains above 30 mmHg in the presence of symptoms.
7	BPA
7.1	Inoperable CTEPH patients can benefit from BPA. Optimal CTEPH treatment requires a multidisciplinary team approach considering PEA, medical therapy, and BPA.

7.2	Long-term results after BPA are available out to 8 years after the procedure. Safety and efficacy of BPA correlate with centre experience.
7.3	Vascular injury rather than reperfusion pulmonary oedema is the likely cause of any severity of lung injury after BPA.
7.4	Similar to PEA, proper training in a high-volume centre is critical for BPA.
8	Medical treatment
8.1	According to current guidelines, CTEPH patients should be treated with lifelong anticoagulation; VKAs are the mainstay of anticoagulant treatment in CTEPH, but NOACs are increasingly used with no safety issues reported yet. Antiphospholipid syndrome is a contraindication to NOACs.
8.2	Riociguat, an oral guanylate cyclase stimulator, and treprostinil, a subcutaneous prostacyclin analogue, are approved for patients with inoperable CTEPH or persistent/recurrent PH after PEA; other PH medications have been tested in CTEPH and are used off-label.
8.3	Oral combination therapy is a common practice in CTEPH patients with severe haemodynamic compromise.
8.4	Withdrawal of PH medications is usually considered after successful BPA and/or PEA.
9	Multimodality treatment
9.1	There is no consensus on eligibility criteria for multimodal therapy, which is dependent on the expertise and judgement of each individual CTEPH centre. Patient selection for multimodal therapy is performed in expert centres through a multidisciplinary team approach.
9.2	There is no convincing evidence that preoperative pharmacological treatment is beneficial in patients with operable CTEPH. Nevertheless, PH-targeted drugs as bridging therapy to PEA is sometimes considered in selected high-risk patients (with high preoperative pulmonary vascular resistance, PVR) after multidisciplinary team assessment in expert centres.
9.3	The role of BPA as bridging therapy prior to PEA in patients with mixed surgically accessible and inaccessible lesions needs to be explored. The potential benefit of hybrid procedures simultaneously combining PEA and BPA in such patients needs to be confirmed by further studies. There is insufficient evidence to support the use of BPA as a rescue procedure for early failure of PEA. Additional BPA most often in combination with PH-targeted medical therapy is common practice for patients with persistent symptomatic PH after PEA.
9.4	Most task force members use PH-targeted therapy prior to BPA to improve the safety of BPA although there have been no clinical trials investigating the benefit of this approach on the rate of BPA-related complications. Some data suggest that the combination of PH-targeted therapy and BPA provides better results than medical therapy alone.
10	Rehabilitation
10.1	Although exercise physiology is slightly different in CTEPH in comparison to PAH, it is reasonable to believe that the positive effects of rehabilitation are similar for both conditions.
10.2	Rehabilitation seems effective and safe in inoperable CTEPH patients.
10.3	Although most of the pivotal trials on rehabilitation in CTEPH and PAH were based on in-hospital training in tertiary referral set-ups, small non-randomised studies showed that home-based rehabilitation might also be an effective and safe option.

10.4	A carefully monitored, low dose rehabilitation program of CTEPH patients after PEA or BPA might be considered standard of care.
11	Global research lines
11.1	To achieve new genetic insights and basic science progress, international collaboration through biobanking should be established to allow researchers access to the data which represents a large number of patients. Integration of clinical and -omic measurements will identify clinically valuable diagnostic signatures and pathways for potential future interventions.
11.2	There is a need to address CTEPH in paediatric patients by a prospective global registry.

Scope of Document

Since the publication of the 2015 European Society of Cardiology (ESC)/ European Respiratory Society (ERS) guidelines for the diagnosis and treatment of PH [1], considerable advances have been made in the understanding, diagnosis and management of CTEPH. Thus, the ERS considered a statement paper was required in order to take into account recent developments in the field. A multidisciplinary task force (TF), with members from the European Respiratory Society (ERS), the International CTEPH Association (ICA) and the European Reference Network (ERN)-lung, including specialists in pneumology, cardiology, cardio-thoracic surgery, radiology, pathology, together with representatives of patients, defined and answered key questions related to the management of CTEPH. The TF searched for a clear definition, reviewed imaging techniques, epidemiology, follow up of acute PE, microvasculopathy, indications of PEA, BPA and medical treatment, the multimodality approach, and defined research questions and priorities.

Methods

Task force chairs, supported by the ICA board members, compiled a list of 11 topics that they considered important and relevant to the diagnosis and management of CTEPH. Task force members (27 experts + 2 patient representatives) were divided into subgroups targeting these topics (**Table S1: TF composition per topic**). Each group identified 3-4 key focused questions relevant for their topic. These were discussed in a first face-to-face meeting in March 2019. Once the key questions were agreed on, the subgroups prepared individual subsections which were then presented and discussed in a second face-to-face meeting during the ERS congress in Madrid (September 2019) and subsequently revised until consent among all co-authors was reached (February 2020). All co-authors critically revised and approved the final statement (March 2020). The manuscript was finalised and submitted to the European Respiratory Journal after approval by the ERS Guidelines Committee (April-May 2020). The statement will be presented at the ERS virtual International Congress (September 2020).

The present ERS statement combines an evidence-based approach with the clinical expertise of the TF members, based on both literature search and discussions during face-to-face meetings. The TF members reviewed current knowledge and new scientific advances through identifying relevant individual studies and reviews from systematic searches in MEDLINE (via PubMed) and EMBASE (via Ovid), performed by subgroup members, mostly with no date limits. Last search was performed in February 2020; however, TF members also tracked any relevant citation which appeared beyond this date and until submission in April 2020. The search was limited to English literature with no date limitations. Literature search was conducted using “chronic thromboembolic pulmonary hypertension” and the relevant key words for each respective section (**Table S2: Search strategies for each topic/question**). Additionally, manual searches of articles mentioned in the reference lists were performed.

All members of the TF disclosed their conflicts of interest before initiation of the project and upon submission of the manuscript.

1. Definitions

1.1 Current definitions - Is there a need to change it in view of new diagnostic methods and the proposed reduced mPAP threshold for PH? How to best define symptomatic patients with post-thrombotic deposits but without PH at rest?

Two terms are currently used to describe symptomatic patients with chronic thromboembolic occlusions of pulmonary arteries according to the presence or the absence of PH at rest: chronic thromboembolic pulmonary hypertension (CTEPH) and chronic thromboembolic disease (CTED).

The definition provided in the 2015 ESC/ERS guidelines for the diagnosis and treatment of pulmonary hypertension [1] stated that “*The diagnosis of CTEPH is based on findings obtained after at least 3 months of effective anticoagulation in order to discriminate this condition from ‘subacute’ PE. These findings are mPAP \geq 25 mmHg with pulmonary artery wedge pressure (PAWP) \leq 15 mmHg, mismatched perfusion defects on lung scan and specific diagnostic signs for CTEPH seen by multidetector CTPA, MRI or conventional pulmonary cineangiography, such as ring-like stenoses, webs/slits and chronic total occlusions (pouch lesions or tapered lesions)*”. More recently, cohorts of symptomatic patients, with exercise limitation, have been described showing similar obstructive lesions as CTEPH but no resting PH [2, 3]. They may however benefit from the same treatment, including lifelong anticoagulation, PEA and BPA. The reporting authors proposed the term “chronic thromboembolic disease (CTED)”, which is unclear because of not specifying that it concerns pulmonary vessels.

The only difference between CTEPH and CTED is the presence or not of PH at rest. However, based on scientific evidence, a change in the definition of PH has been proposed with a decrease of the threshold mPAP from 25 to 21 mmHg, and in the definition of pre-capillary PH with a decrease of the threshold PVR from 3 to 2 WU [4]. Lowering these thresholds may influence the designation of former CTED patients as CTEPH patients [2, 5-9] (**Table S3: Haemodynamic characteristics in CTEPD patient cohorts**).

To solve this terminology dilemma, a survey was conducted among the TF members. After collation of all propositions for names of the overarching disease and the subentities with or without PH, a 3 round- voting was conducted until consensus was reached. For all symptomatic patients who present mismatched perfusion defects on VQ scan and specific signs of organised fibrotic clots on CTPA, MRI or conventional pulmonary cineangiography, such as ring-like stenoses, webs/slits and chronic total occlusions (pouch lesions or tapered lesions), after at least 3 months of effective anticoagulation, the TF chose the general term **chronic thromboembolic pulmonary disease (CTEPD)**. Some of these patients have no PH at rest whatever the definition accepted. For the others, the term **chronic thromboembolic pulmonary hypertension (CTEPH)** was maintained. The presence of PH at rest in this setting is not only the consequence of proximal vessel obstruction by organised thrombi but can also be related to a secondary microvasculopathy, as well as to the presence of underlying lung or left heart disease.

1.2. Should CPET and ex-RHC be included in the definition and with what thresholds?

Since symptoms in CTEPH appear during exercise, the tests performed at rest - including RHC - may lack sensitivity. Long awaited recently formulated criteria for exercise PH are not optimal for detection of “exercise CTEPH”, as they take into account total (TPVR, = mPAP/cardiac output) and not PVR, ignoring PAWP changes at exercise [10]. However, reliable measurement of PAWP at peak exercise may be difficult due to large respiratory shifts in intrathoracic pressure. Recently much attention is given to CPET performed not only for prognostic purposes but for differential diagnosis of dyspnea in patients with suspected pulmonary vascular disease [11-15]. The candidate CPET diagnostic parameters are reflecting inefficient ventilation and include high ventilatory equivalent for CO₂ (VE/CO₂) slope and low end-tidal CO₂ tension (PETCO₂), further decreasing at exercise [16].

Both are promising for the differential diagnosis of symptomatic patients without or with only mild PH who have imaging results that may suggest CTEPD. In addition, it is not clear whether CTEPH can be diagnosed in the presence of suggestive intravascular changes at imaging but in a patient who also has increased left ventricular (LV) filling pressures. Whether treatment removing precapillary obstruction would lead to pulmonary congestion or – on the contrary – would improve cardio-respiratory reserve by restoring flow through ventilated, but under-perfused lung areas, remains unclear.

New imaging tools and increasing experience of radiologists in CTEPH referral centres make it possible to identify patients with chronic thromboembolic obstructions clinically presenting as acute PE or with long-standing progressive exercise limitation. The definition of CTEPH required 3 months of anticoagulation. This is certainly still reasonable in haemodynamically stable patients and those that clearly improve during initial anticoagulant therapy. However, in individual, severely compromised cases with significant contribution of unequivocal chronic intravascular changes the diagnosis and specific treatment for CTEPH could be considered by experienced CTEPH teams, regardless of the duration of anticoagulant therapy.

1.3. Can a patient be cured of CTEPH?

Despite optimal, and apparently successful, surgical, interventional and medical treatment, pulmonary circulation does not return entirely to normal, which can be seen at VQ scans performed during follow-up. Thus, treatment may make patients with CTEPH feel healthy but is unlikely to completely cure all the affected pulmonary vessels - arteries, veins and systemic collaterals [17, 18]. Furthermore, the possibility to restore normal life expectancy is somewhat limited by potential complications related to life-long anticoagulation.

Statements

- 1.1 *All patients in whom symptoms can be attributed to post-thrombotic deposits within pulmonary arteries could be considered to have chronic thromboembolic pulmonary disease (CTEPD) with or without pulmonary hypertension (PH). Chronic thromboembolic pulmonary hypertension (CTEPH) remains the preferred term in patients with PH.*
- 1.2 *Cardiopulmonary exercise testing (CPET) and exercise right heart catheterisation (ex-RHC) could contribute to the definition of CTEPD helping to identify the main cause of exercise limitation in the presence of comorbidities and in patients without resting PH.*
- 1.3 *In many patients with CTEPH, resting mean pulmonary arterial pressure (mPAP) is normalised by surgical or multimodality treatment and patients feel healthy, but it is unlikely to return all pulmonary vessels back to normal.*

Proposal for future research in CTEPH definition

- a) *Both ex-RHC as well as CPET still require establishing and validation of thresholds which could be incorporated into CTEPD definition*
 - b) *Research on definition of CTEPD and CTEPH in patients with concomitant significant left heart and/or lung disease*
-

2. Diagnosis

In patients with PH, the diagnosis of CTEPH is suspected when VQ scan shows mismatched perfusion defects, and confirmed by RHC and pulmonary vascular imaging [1, 19, 20]. Considering major advances in imaging technologies, the following aspects were discussed:

2.1. Should SPECT replace planar VQ?

VQ scintigraphy is consistently acknowledged to be the most effective screening tool in the CTEPH diagnostic algorithm [1]. There is an emerging trend in clinical practice to replace planar VQ with SPECT VQ. Whilst most of the systematic reviews and meta-analysis professing the superiority of SPECT over planar imaging are based on acute PE [21-23], the higher sensitivity of VQ SPECT for CTEPH detection has also been demonstrated [24]. VQ SPECT imparts lower doses of isotopes per correct diagnosis [22]. The addition of low-dose CT to VQ SPECT improves specificity by identifying concomitant parenchymal lung disease [19]. SPECT quantitation can provide a measure of CTEPH disease severity [25]. Based on the review of the available literature [19, 23-27] as well as clinical practice (**Table S4: Survey on VQ SPECT, DECT and MR for CTEPH**), most TF members use VQ SPECT as the methodology of choice where possible, with adherence to the simplified dichotomous interpretation criteria. The authors acknowledge that the transition from planar to SPECT may not be easy, particularly for clinicians who may not be familiar with the three-dimensional anatomy. This could be overcome by generating two-dimensional planar images reprojected from SPECT data without losing diagnostic accuracy [26] (**Fig 1**).

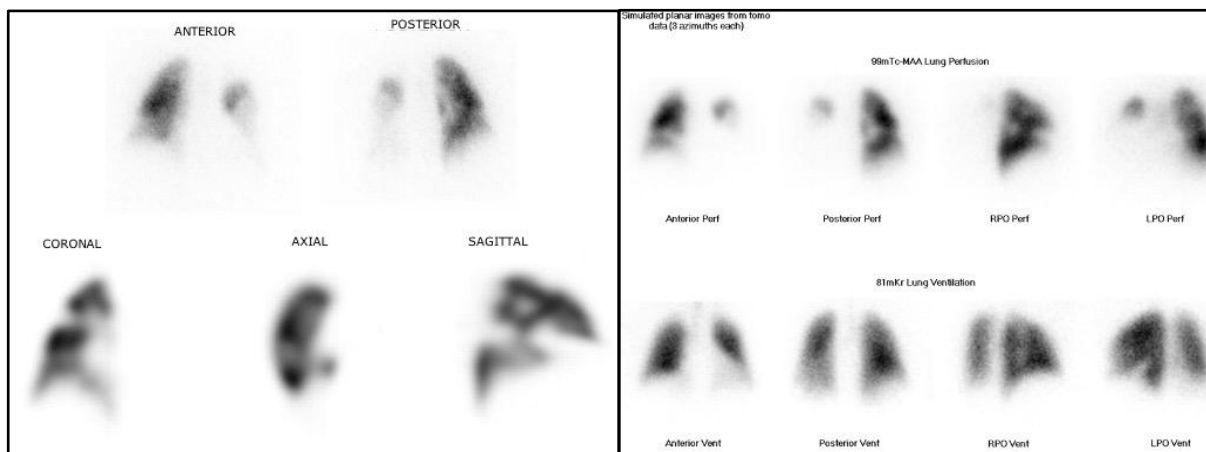


Fig 1: VQ. Left panel: Anterior and posterior views from a planar VQ perfusion scan (top) and selected coronal, axial and sagittal perfusion images of the right lung from the corresponding SPECT (bottom) show bilateral perfusion defects in a 60-year-old female with CTEPH. Most of the left lung is non-perfused. The perfusion defects in the right lung are much better delineated on the SPECT series compared to the planar images. Right panel: Simulated planar images generated from the SPECT data in the same patient for perfusion (top) and ventilation (bottom)

2.2. Are DECT or MR perfusion practical alternatives to VQ for CTEPH diagnosis?

Over the last decade since its introduction, the role of DECT in CTEPH has evolved in its ability to detect parenchymal arterial perfusion and measure pulmonary vascular reserve. DECT iodine maps visualise parenchymal iodine distribution and are surrogate markers of lung perfusion [28]. DECT appearances in CTEPH is significantly different from PAH [29] (**Fig 2**). DECT can be useful to differentiate acute PE and CTEPH based on the attenuation value of emboli [30]. Detection of distal CTEPH is also improved as perfusion defects are demonstrated even in the absence of visible morphological arterial abnormalities [31]. Automated quantification of pulmonary perfused blood

volume (PBV) maps can provide objective measure of CTEPH severity [32, 33]. There are several small volume studies comparing PBV maps to planar and VQ SPECT imaging with modest to good correlation [29, 34-37]. The lack of complete concordance is not surprising as the two techniques are not physiologically equivalent.

The TF members acknowledge the advantages of DECT and its ability to provide anatomic and functional information for CTEPH in a single test but do not currently replace VQ as a screening test for various reasons in their practice (**Table S4: Survey on VQ SPECT, DECT and MR for CTEPH**). The main limitation is the availability of CT systems capable of performing DECT and the attendant cost implications. There is also a lack of standardised protocols for acquisition of PBV images that are consistent and reproducible. Further studies are required to overcome such limitations and validate the role of DECT in CTEPH.

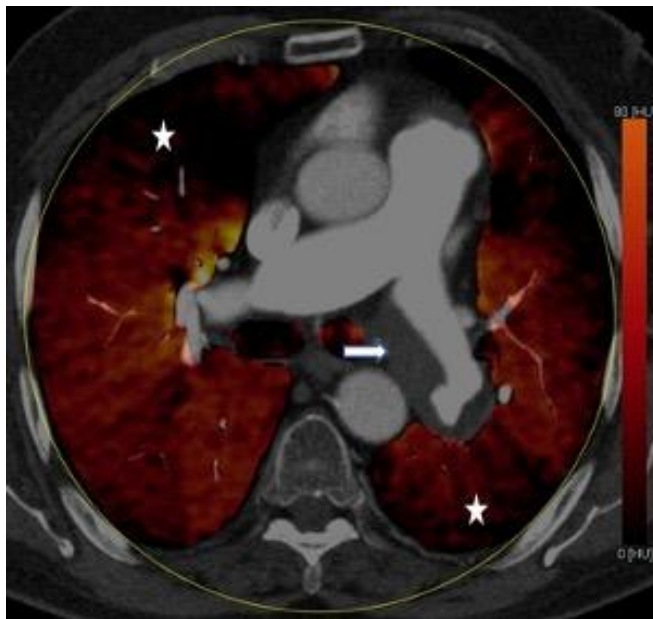

Fig 2: DECT. Axial view of a DECT image from a 50-year-old male with CTEPH demonstrates eccentric thrombus (arrow) in the left main pulmonary artery extending into the lower lobe artery with corresponding perfusion defect in the left lower lobe (star). Also note the perfusion defect in the right lung (star)

Dynamic contrast enhanced MR (DCE-MR) perfusion is a 3D breath-hold acquisition during first pass of gadolinium with a comparable sensitivity to planar and increased sensitivity to VQ SPECT for CTEPH detection [38, 39] (**Fig 3**). A crucial factor limiting the use of DCE-MR as a screening tool is the lack of widespread availability of both equipment as well as expertise. Other issues such as the technical demands and challenges involved in the evaluation of the lung parenchyma need to be surmounted before routine implementation of MR as a single imaging test in CTEPH.

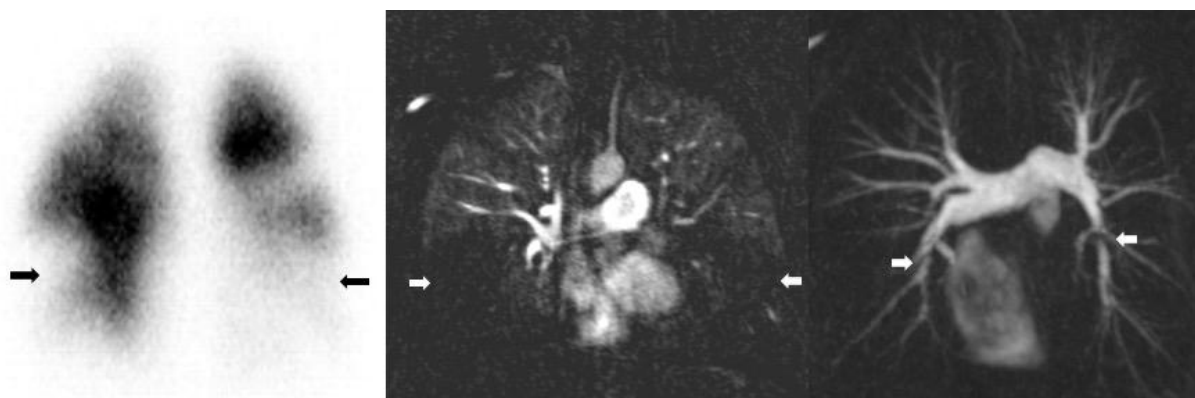

Fig 3: MR perfusion and angiography. 70-year-old male with CTEPH with large bilateral perfusion defects in both lower lobes on the MR perfusion (mid panel). The corresponding MR angiography (right panel) demonstrates significant trifurcation webs in both lower lobes. There is good concordance with VQ scintigraphy (perfusion component, anterior view, left panel).

2.3. Is high quality CTPA adequate for diagnosis or is there a need for digital subtraction angiography (DSA)?

On-going technological advances are continuing to refine the role of CT in the CTEPH diagnostic algorithm. Modern CTPA may be non-inferior to VQ in diagnosing CTEPH [40] but a fundamental reservation is that a negative CTPA cannot exclude CTEPH as small vessel disease can be missed. CTPA technical quality is a significant contributor to the variation in its usage as is the inconsistency in CT interpretation in non-CTEPH expert centres [41]. A recent meta-analysis demonstrated that high-quality CT studies had a pooled sensitivity of 99% and specificity of 97% for CTEPH detection on a vessel-based analysis [42]. Some high-volume CTEPH expert centres use CT data to provide a roadmap of the location and extent of disease for operability assessment.

Most TF members use a high quality CTPA (**Table S5: What makes a high-quality CTPA?**) as a good non-invasive substitute for diagnosis of proximal CTEPH. Experienced operators also use CTPA for evaluation of suitability for pulmonary endarterectomy in selected cases where the disease distribution is proximal.

2.4. Role of new CT advances such as CBCT and ADCT

Digital flat-panel detector CBCT is a recent innovation that can be used in conjunction with C-arm systems to provide projection radiography, fluoroscopy, DSA, and volumetric CT. CBCT has the ability to provide better delineation of distal lesions in CTEPH (**Fig 4**). In comparison to DSA and conventional CT, CBCT is more sensitive in depicting sub-segmental arterial abnormalities, and more accurate in detection and characterisation of these lesions compared to selective angiography [43-46]. CBCT is a useful tool for BPA procedure guidance as it helps to obtain appropriate working projections and allows for targeted selective imaging and treatment. BPA guided by CBCT [47, 48] or ECG-gated ADCT (320-row) [49] is effective and remarkably safe. These advantages must be balanced against the invasive nature of CBCT. There is limited literature on the radiation dosimetry of CBCT in CTEPH patients, but it is clear that the dose will vary depending on the protocol used and is on average around 3mSv [43].

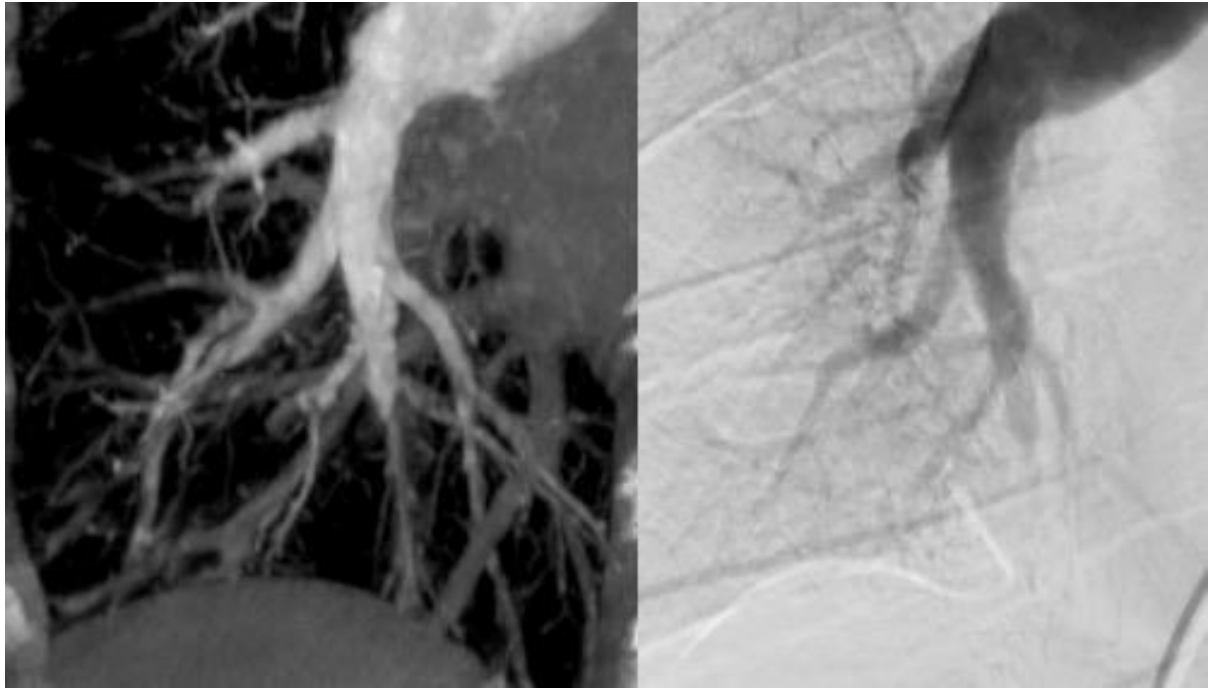


Fig 4: CBCT. Selected images from a CBCT (left) and corresponding conventional catheter pulmonary angiography (right) in a 45-year-old male with CTEPH to illustrate the superior depiction of the pulmonary arterial abnormalities at the segmental and the subsegmental level on the CBCT

In summary, these are high-end techniques that provide better anatomical definition for CTEPH diagnosis and treatment but are expensive and are not widely available. As they are still in evolution, there is no standardisation of the protocol for their usage. The benefits of the technology require validation with prospective trials before recommendation for routine clinical use.

2.5. What is the utility of cardiac MRI in the diagnostic algorithm?

Although well suited for CTEPH diagnosis and follow-up, MRI is not yet fully integrated into the CTEPH diagnostic algorithm. Its use is heavily dependent on local practice with routine implementation only in a few high-volume institutions where there is clustering of expertise.

MR angiography for diagnosis

A comprehensive stepwise protocol of MR perfusion followed by high-spatial resolution MR angiography improves the diagnostic performance of MR. It is essential to review the source images and use multiplanar reformations to evaluate the complex vascular anatomy. MR angiography maximum intensity projections (MIP) provide an overview of the pulmonary arterial tree in a format that is comparable to DSA.

Perfusion MRI has sensitivity of 97%, specificity 92%, positive predictive value 95% and negative predictive value 96% for detecting CTEPH, a performance comparable to VQ scintigraphy and CTPA [39]. In a study comparing the efficacy of contrast enhanced MR pulmonary angiography (CE-MRA), CTPA and DSA, CE-MRA demonstrated a sensitivity and specificity of 83.1% and 98.6% at the main/lobar level and 87.7% and 98.1% at segmental level for diagnosing CTEPH but was outperformed by DSA for depiction of subsegmental arteries [50]. Besides, CE-MRA was demonstrated to identify proximal and distal CTEPH with a high sensitivity and specificity of 98% and 94% respectively [51].

RV function in evaluating PH severity at the time of diagnosis

Cardiac MR is the reference standard for the assessment of RV size and systolic function [52] and is well equipped to consistently provide accurate evaluation of RV function in the diagnostic work-up and follow-up of patients with CTEPH. MRI has been used to non-invasively demonstrate the technical success of PEA as evidenced by the RV reverse remodelling and improvement in the interventricular septal dyssynchrony and pulmonary clearance [53-55]. BPA induced RV reverse remodelling has also been demonstrated using cardiac MR in patients with inoperable disease [56]. Late gadolinium enhancement (LGE) at the RV insertion points is strongly associated with elevated PAP but its prevalence in CTEPH is not clearly defined, and its prognostic significance remains uncertain. In a subset of 39 patients with CTEPH from the ASPIRE registry [51], 97% had RV hinge point enhancement, leading the authors to conclude that its presence is highly sensitive for the detection of severe increases in RV afterload. Parametric mapping techniques have shown that native T1 values in the septum are elevated in CTEPH even in the absence of LGE [57]. Larger trials are needed to understand the potential of quantification of septal fibrosis as a prognostication and therapy-monitoring tool in the future.

Is non-invasive (MR based metrics) measurement of haemodynamic parameters prime time? i.e can we replace RHC by MR based data

Attempts to correlate MR based haemodynamic parameters with RHC data have thus far met with limited success [51, 58-63]. Various multiparametric models have been introduced to estimate mPAP and PVR from cardiac MR data but validation is challenged by the small number of comparable studies and paucity of prospective clinical cohorts. However, it is likely that advances such as strain imaging, parametric mapping and 4D flow MR hold great potential in providing key metrics for CTEPH screening and monitoring.

MRI has the potential to offer a non-invasive holistic approach to CTEPH diagnosis and follow-up but there is widespread lack of acceptance in the clinical community due to perceived as well as genuine issues regarding access to the technique, bias about protracted acquisition times and lack of expertise in interpretation. Multi-centre prospective trials and focused training are required to make a paradigm shift before MR can be routinely integrated into the CTEPH diagnostic algorithm.

2.6. Diagnostic algorithm

Summarizing recent data, the diagnostic algorithm for CTEPH that TF members use in their practice is shown in **Fig 5**.

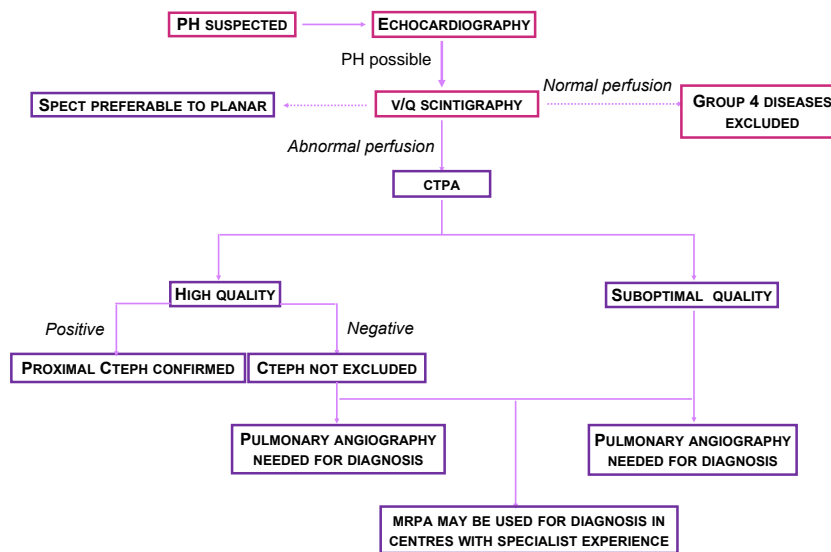


Fig 5: CTEPH diagnostic algorithm used by TF members. The figure describes the current practice of how the members of the Task Force diagnose CTEPH and is not intended as a general recommendation.

Statements

- 2.1 Ventilation/perfusion (VQ) scintigraphy remains the most effective screening tool to exclude CTEPD. VQ single photon emission computed tomography (SPECT) has been shown to be superior to planar imaging and is the methodology of choice. Because the transition from planar to SPECT may not be easy for clinicians unfamiliar with the three-dimensional anatomy, two-dimensional planar images can be reprojected from SPECT without losing diagnostic accuracy.
- 2.2 Alternative perfusion techniques such as dual energy computed tomography (DECT) and magnetic resonance (MR) perfusion have numerous theoretical advantages over VQ but are more technically challenging, expensive, with limited availability and lack multicentre validation. Hence, they are not replacing VQ in current clinical practice.
- 2.3 High quality CT pulmonary angiography (CTPA) is adequate for diagnosis of proximal CTEPH but a negative CTPA, even if high quality, does not exclude CTEPH as distal disease can be missed.
- 2.4 Cone beam (CBCT) and area detector CT (ADCT) allow for more accurate visualisation of subsegmental vasculature and have been shown to be useful for procedural guidance for balloon pulmonary angioplasty (BPA). The benefits of the technology require validation in prospective trials before recommendation for routine clinical use.
- 2.5 MR imaging is not yet fully integrated into the CTEPH diagnostic algorithm because its use is heavily dependent on local practice and is routinely implemented only in a few high-volume institutions where there is clustering of expertise.

Proposal for future research in CTEPH diagnosis

- c) Prospective multi-centre validation of DECT for screening and diagnosis of CTEPH

d) Prospective multi-centre validation of MR (perfusion, angiography & parametric models) for CTEPH screening, diagnosis and evaluation of disease severity

3. Epidemiology

3.1. Incidence and prevalence of CTEPH. Is CTEPH a complication of acute PE, or is CTEPH often misclassified as PE?

The **prevalence of CTEPH in the general population** is difficult to evaluate since the disease is rare and may be underdiagnosed. Some information can be derived from national PH registries in whom CTEPH represents about 20% of patients referred to main PH centres [64]. Estimated CTEPH prevalence from registries is ranging from 3.2 per million in the Spanish Registry to 38 per million in the UK National Audit of PH [65, 66]. An epidemiological analysis of the burden of CTEPH in different countries estimated its prevalence ranging from 19 per million in Japan to 30-50 per million in the US and Europe [67]. A recent study estimated the prevalence of CTEPH based on a case ascertainment algorithm within the French exhaustive hospital discharge database (PMSI) [68]. Based on 3,138 patients hospitalised for CTEPH in 2015 in France, and assuming that patients were hospitalised at least once a year, the prevalence of CTEPH was estimated 47 cases per million (range 43 to 50 cases per million).

CTEPH is usually considered as **a complication of acute PE**, with 50-75% of the patients with CTEPH having a documented history of acute PE [69-71]. In Japanese patients, only 15% have a history of acute PE [72], supporting the hypothesis of a different phenotype of CTEPH in the Japanese population, together with the observed female preponderance, a lower proportion of coagulopathies [71], and less proximal thrombus and fresh red thrombus components in PEA specimens [73].

The **cumulative incidence of CTEPH after acute PE** is not exactly known and is reported ranging from 0.1% to 11.8% in the first two years after symptomatic PE [74-78]. This wide range could be explained by referral bias, the paucity of early symptoms and the difficulty to differentiate acute PE symptoms from pre-existing CTEPH [76-78]. A systematic review and meta-analysis of studies including consecutive PE patients followed for CTEPH (16 studies including 4047 PE patients who were followed up for >2 years), showed a CTEPH incidence of 0.56% (95%; CI, 0.1–1.0) in all comers. In survivors of PE and in survivors without major comorbidities, incidence of CTEPH was 3.2% (95%; CI, 2.0–4.4), and 2.8% (95%; CI, 1.5–4.1), respectively [78]. The authors suggested that the ~3% incidences in the survivor categories may be more relevant for daily clinical practice. They emphasised that studies that assessed CTEPH diagnosis by tests other than RHC provided an overestimated incidence of CTEPH, underscoring the need of an accurate workup in patients who remain symptomatic after an acute PE. However, in a more recent multicentre observational screening survey for the detection of CTEPH following PE (screening performed at 6, 12 and 24 months using a stepwise algorithm including dyspnoea phone-based survey, echocardiography, RHC and radiological confirmation of CTEPH), the CTEPH incidence was estimated 3.7 per 1000 patient-years with 2-year cumulative incidence of 0.79% [79].

Finally, there are very strong arguments for frequent **misclassification of CTEPH as PE** [74, 76, 78]. In a prospective multicentre study conducted in three centres in France, 146 patients with an acute PE were followed up for a median time of 26 months. Among the 7 patients diagnosed with CTEPH (incidence 4.8%; 95% CI, 2.3–9.6), echocardiography and CT performed at the time of the acute PE suggest that a majority of them had previously unknown PH, indicating that a first clinical presentation of CTEPH may mimic acute PE [76].

3.2. How many patients with persistent perfusion defects after acute PE have CTEPH?

According to VQ scan studies, up to 50% of patients have persistent perfusion defects after an acute PE [80-82], with discrepant clinical relevance. Some studies reported an impact of residual

obstruction on pulmonary haemodynamics, functional class, exercise capacity and outcome [82, 83], while the more recent ELOPE study showed no correlation with exercise capacity [84]. Some of these “persistent perfusion defects” could also be pre-existent to the acute PE precluding any clear conclusion. Considering the ‘pyramid’ of complications [64], CTEPD without PH likely occurs more often than CTEPH. So, if the prevalence of CTEPH after PE in survivors is 2-3% [78], the prevalence of CTEPD is probably higher than that.

3.3. Is CTEPD without PH an early stage of CTEPH?

There is no definitive answer to that question. Our limited knowledge of the natural history of CTEPH is based on historical data prior to the current treatment era. Patients with mild PH (mPAP <30 mmHg) and “borderline PH” (mPAP 21–24 mmHg) were thought to have a good prognosis, with low probability of progressing to severe PH when treated solely with anticoagulation [85, 86], although these studies lack information on the severity of the thrombotic burden. According to clinical experience, some patients remain stable while others experience a rapid unexplained deterioration. When focusing on CTEPD patients without PH but extensive thromboembolic disease who underwent surgery, PEA specimens are no different from CTEPH patients [2].

3.4. Could CTEPD incidence be different in patients treated with VKAs and NOACs? - Could it be different in patients treated with different NOACs? - Could the incidence be influenced by dosing strategy in NOACs?

Current literature does not suggest any difference in CTEPD incidence in patients with VTE treated with VKAs and NOACs. Previous studies have shown that persistent perfusion defects occur despite adequate anticoagulation (mostly with VKA; in up to 50% of patients) [80-82]. In the literature on thrombus resolution in DVT, some industry sponsored studies have suggested that rivaroxaban may lead to better venous patency than VKA [87, 88], however more recent independent studies did not confirm this [89, 90]. The fact that the risk of early recurrent VTE is no different between NOAC vs VKA treated patients in randomised controlled trials (RCT) is a strong argument to say that the choice of anticoagulant drug should not influence the risk of CTEPH. By preventing recurrent VTE, due to more patients getting lifelong treatment, it may lower the prevalence of CTEPH (half or full dose NOAC has same efficacy in reducing the risk of recurrent VTE).

However in some specific situations, treatment with NOACs, which is recommended by current ESC guidelines for diagnosis and treatment of acute PE in preference to VKA, due to their ease of use and better tolerability [91, 92], could be associated with higher risk of recurrent thromboembolic events than VKA therapy (recurrent PE is a risk factor associated with CTEPH [64]). It was confirmed in patients with high risk antiphospholipid syndrome (lupus anticoagulant, anticardiolipin antibodies, and anti-beta 2-glycoprotein I antibodies) [93]. In other specific clinical situations (e.g., obesity with a body mass index >40 kg/m² or a body weight >120 kg, concomitant medication with proton pump inhibitors or H₂- antagonists which can reduce gastrointestinal absorption of dabigatran) pharmacokinetic aspects of NOACs have to be carefully taken into account to optimise the risk-benefit profile of these drugs in prevention of recurrent thromboembolic events and perhaps CTEPD [94, 95].

3.5. Should the incidence and prevalence of CTEPD be analysed in specific subpopulations? Could this information be useful for the screening recommendation?

Clinical conditions such as permanent intravascular devices (pacemaker, infusion chamber, VA shunts), inflammatory bowel diseases and essential thrombocythaemia have been identified as risk factors of CTEPH [96, 97]. Prevalence of CTEPH in this population of patients is not sufficiently described [67], precluding recommendations for screening in non-symptomatic patients.

Statements

- 3.1 *CTEPH is a rare and underdiagnosed complication of pulmonary embolism and, upon first presentation, may be misclassified as acute pulmonary embolism (PE).*
- 3.2 *Persistent perfusion defects after acute PE are common, but have highly variable clinical relevance, ranging from completely asymptomatic to established CTEPH.*
- 3.3 *We have no evidence to suggest that CTEPD without PH is an early stage of CTEPH because of lack of data on its natural history.*
- 3.4 *Current literature could not demonstrate any difference in CTEPH incidence in patients with VTE treated with VKAs and NOACs, but rigorous studies have not been done.*
- 3.5 *Screening for CTEPH in asymptomatic patients with specific risk factors could be effective but is not supported by any data.*

4. Follow up after acute PE

4.1. Is earlier detection of CTEPH relevant for outcome?

In daily practice, it may take 14-24 months from symptom onset for CTEPH to be diagnosed [70, 98-100]. Although this diagnostic delay was not associated with operability in the European CTEPH registry, longer delay was shown to correlate to higher systolic pulmonary arterial pressure (sPAP) at diagnosis and increased risk of death [70, 98, 101]. Even in the relatively short time elapsed between diagnosis of CTEPH and referral to a surgical centre (mean 4.4 months), it was observed that cardiac output decreased and mPAP increased slightly [102]. Progressive increases of PAP and PVR were also observed 1-15 years after diagnosis in patients with initial mPAP >30 mmHg [85]. This can be attributed to the natural course of CTEPH involving the development of a secondary microvasculopathy, further discussed in section 5, and confirms that a timely diagnosis of CTEPH is important.

4.2. How can a patient at high risk of CTEPH after acute PE be identified, and how can we better identify patients who already have CTEPH while presenting with what appears to be acute PE?

CTEPH is usually considered at 2 time points: 1) when presenting with acute PE, if radiological signs suggest CTEPH on the CTPA performed to diagnose PE (**Fig 6 and 7; Table S6: CTPA features of acute PE and CTEPH**), and/or if estimated sPAP >60mmHg [76, 103-106]; and 2) more classically, when dyspnoea or functional limitations persist in the clinical course of PE [107-110]. A third condition could concern asymptomatic patients with risk factors for CTEPH or a high pre-test probability [111] (**Table S7: Known risk factors for CTEPH**).

Clearly, the presence of CTEPH characteristics on a CTPA performed in the setting of acute PE prompts the suspicion of CTEPH as primary diagnosis. CTPA signs of CTEPH include eccentric wall-adherent filling defect, abrupt tapering and truncation, complete occlusion and pouch defects, intimal irregularity, intravascular webs and bands, stenosis, post-stenotic dilatation and vascular tortuosity [92]. It has been shown that most patients with CTEPH after PE had several signs of CTEPH on the index CTPA, indicating acute-on-chronic events rather than acute PE [76, 105]. If evaluated by experts, the presence of ≥ 3 radiological characteristics of CTEPH on CTPA for suspected PE was virtually diagnostic (specificity 96%), although less experienced radiologists may be less likely to recognise this [41, 105].

Notably, CTPA protocols are largely dependent on the available hardware and vary according to patient age, size, motion and cardiac function. Their fundamental goal is to achieve adequate pulmonary arterial enhancement such that thrombus can be distinguished from intraluminal contrast medium. The theoretic minimum intraluminal attenuation of blood required to visualise acute and chronic pulmonary thromboemboli are 93 and 211 HU respectively [112]. CTPA performed for diagnosing acute PE does not involve ECG gating. Considering the above and especially in the acute setting of haemodynamic and respiratory compromise, standard CTPA PE protocols may therefore be less optimal for recognising signs of CTEPH than dedicated protocols for diagnosing CTEPH. Development and validation of artificial intelligence-based software to detect CTEPH on standard CTPA images could help improve diagnostic accuracy in clinical practice.

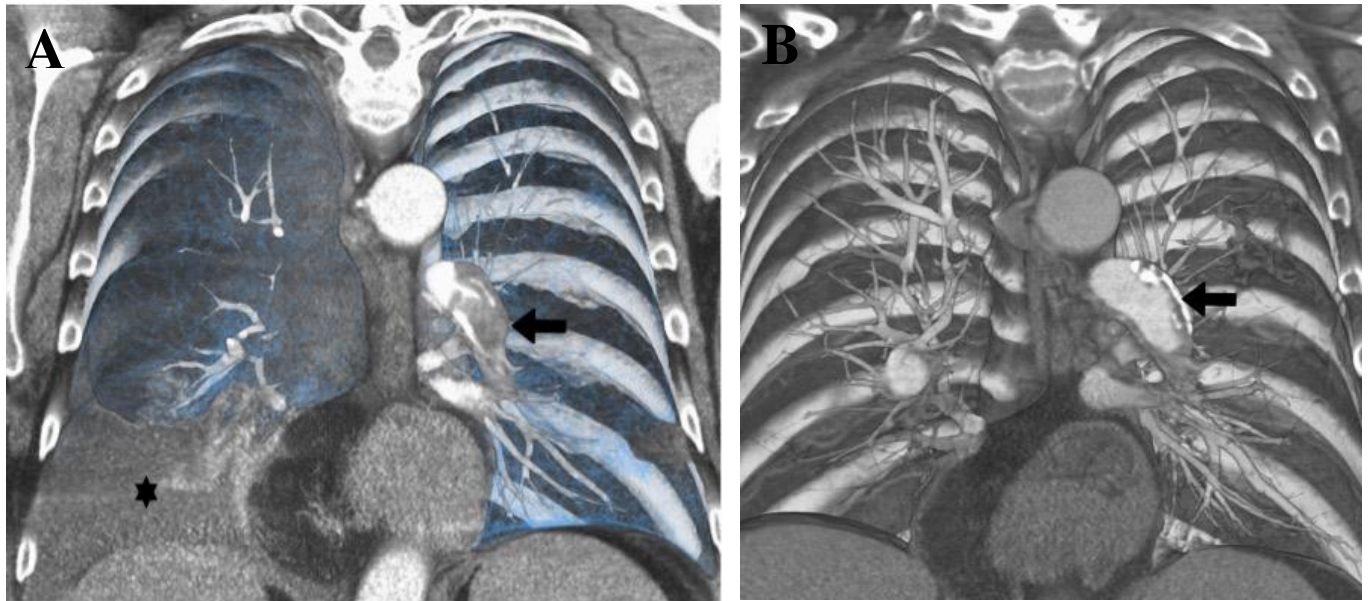


Figure 6: *A. Coronal volume rendered CTPA images demonstrate acute PE in the left lower lobe (black arrow; black star indicated right pleural effusion). B. Two years later, this has evolved into CTEPH with eccentric calcific clot (black arrow)*

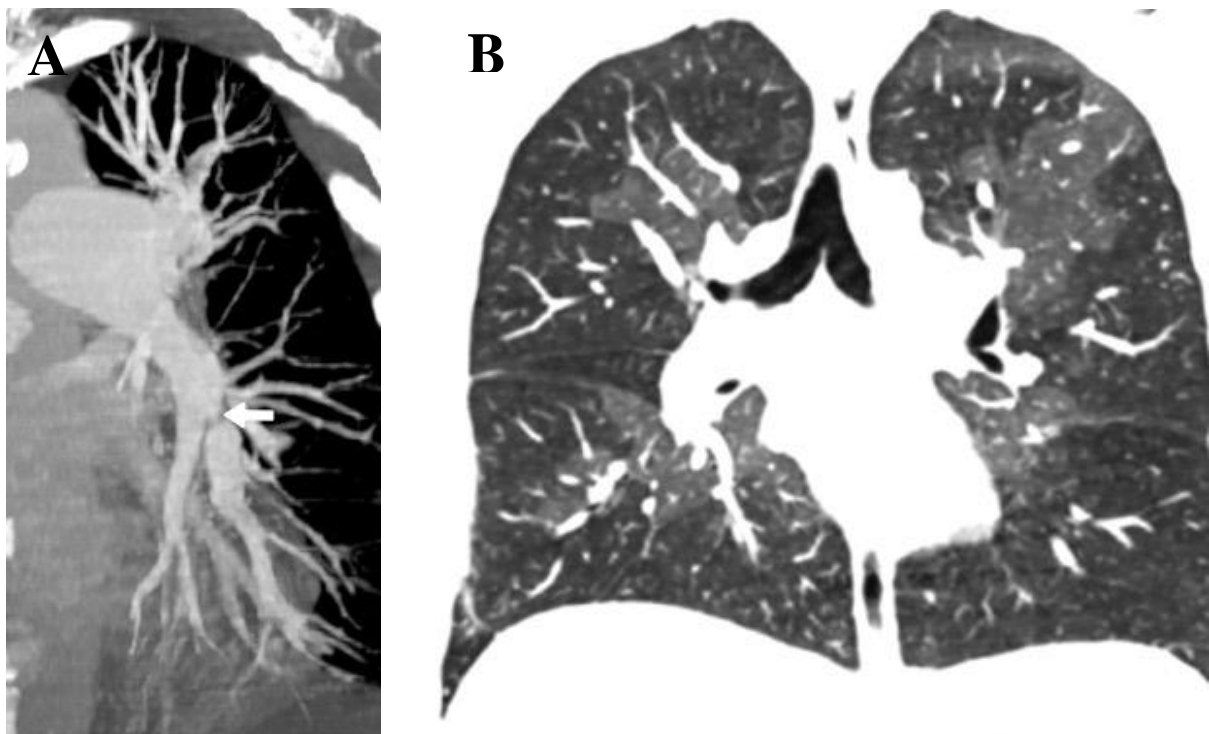


Figure 7: *A. Coronal CTPA reconstruction to show segmental stenosis and post stenotic dilatation in left lower lobe in a CTEPH case (white arrow). B. Coronal CTPA lung window demonstrates mosaic attenuation.*

4.3. Which PE patients should be systematically assessed for the presence of CTEPH and by which primary diagnostic test?

The ESC/ERS guidelines recommend against routine echocardiography in all PE survivors because of the low yield and to prevent overdiagnosis [92]. Similarly, the Canadian Thoracic Society (CTS), after a formal clinical practice guideline development process, involving systematic literature searches and evaluation of the evidence according to GRADE approach, recommended against routine screening after acute PE [113]. In patients with persistent or new onset dyspnoea after PE, the diagnostic work-up starts with echocardiography, followed by VQ scintigraphy and RHC with pulmonary angiography [1], as discussed in section 2.

Alternative tests may also provide diagnostic clues to CTEPH or leave this diagnosis very unlikely (**Table S8: Overview and accuracy of diagnostic tests**). They could be applied to patients with a low CTEPH prevalence, i.e. to rule out CTEPH rather than to confirm the disease, and/or establish an alternative diagnosis for the clinical presentation, since the majority of post-PE functional limitations will be caused by deconditioning [12, 110, 114-116]. CPET, VQ scanning or the combination of ECG and N-terminal pro-brain natriuretic peptide (NT-proBNP) in the Leiden CTEPH rule-out criteria may be useful in this setting [111].

Concerning asymptomatic post PE patients with risk factors for CTEPH (**Table S7: Known risk factors for CTEPH**), common sense needs to be used in the absence of evidence.

4.4. What is the optimal timing of a diagnostic strategy for early CTEPH detection after PE?

The optimal timing of diagnostic tests for CTEPH may be three to six months after the acute PE, coinciding with the moment of routine evaluation of the duration and intensity of anticoagulant treatment [92]. This timeframe can also be used to evaluate if patients tolerate anticoagulant treatment, which is essential after PEA to prevent recurrent pulmonary emboli. Of course, patients with signs of severe PH or overt right heart failure need to be referred earlier to a CTEPH expertise centre to determine the need for immediate treatment. Improving education of PE caretakers, higher awareness for CTEPH and validation of clinical/radiological algorithms for earlier CTEPH diagnosis will likely help ensure earlier referral and improved prognosis.

Statements

- 4.1 *Earlier diagnosis of CTEPH may be relevant for patient outcomes. It can be achieved by targeting patients with acute PE with risk factors for CTEPH or with radiological findings suggesting CTEPH.*
- 4.2 *Patients at risk of CTEPH can be identified by accurate assessment of the CTPA images used to diagnose PE, individual risk factors for CTEPH, and symptoms of functional limitations and/or right heart failure in the course of PE.*
- 4.3 *Echocardiography is the test of choice in patients with suspected CTEPH. Other tests such as Leiden CTEPH rule-out criteria, VQ scan or CPET could be used to exclude the presence of CTEPH and/or to establish an alternative diagnosis.*
- 4.4 *The optimal timing for considering CTEPH in patients with PE is at the routine 3-month follow-up visit; but earlier work-up may be necessary in highly symptomatic or deteriorating patients.*

Recommendations for future research and training

- e) Prospective validation of algorithms for early diagnosis of CTEPH after PE*
 - f) Dedicated training of radiologists to increase awareness for, and skills to detect, CTEPH on routine CTPA scans performed in the setting of suspected acute PE.*
 - g) Development and validation of artificial intelligence-based software to detect CTEPH on standard CTPA images, to improve diagnostic accuracy of dedicated CTPA reading for signs of CTEPH in clinical practice.*
-

5. Pathophysiology

5.1. Vascular lesion characteristics and mechanisms of increased resistance in CTEPH

Anatomically, two different vascular lesions participate in the increase of PVR in CTEPH patients: obstruction of pulmonary arteries by unresolved organised fibrotic clots and a secondary microvasculopathy (**Fig 8**).

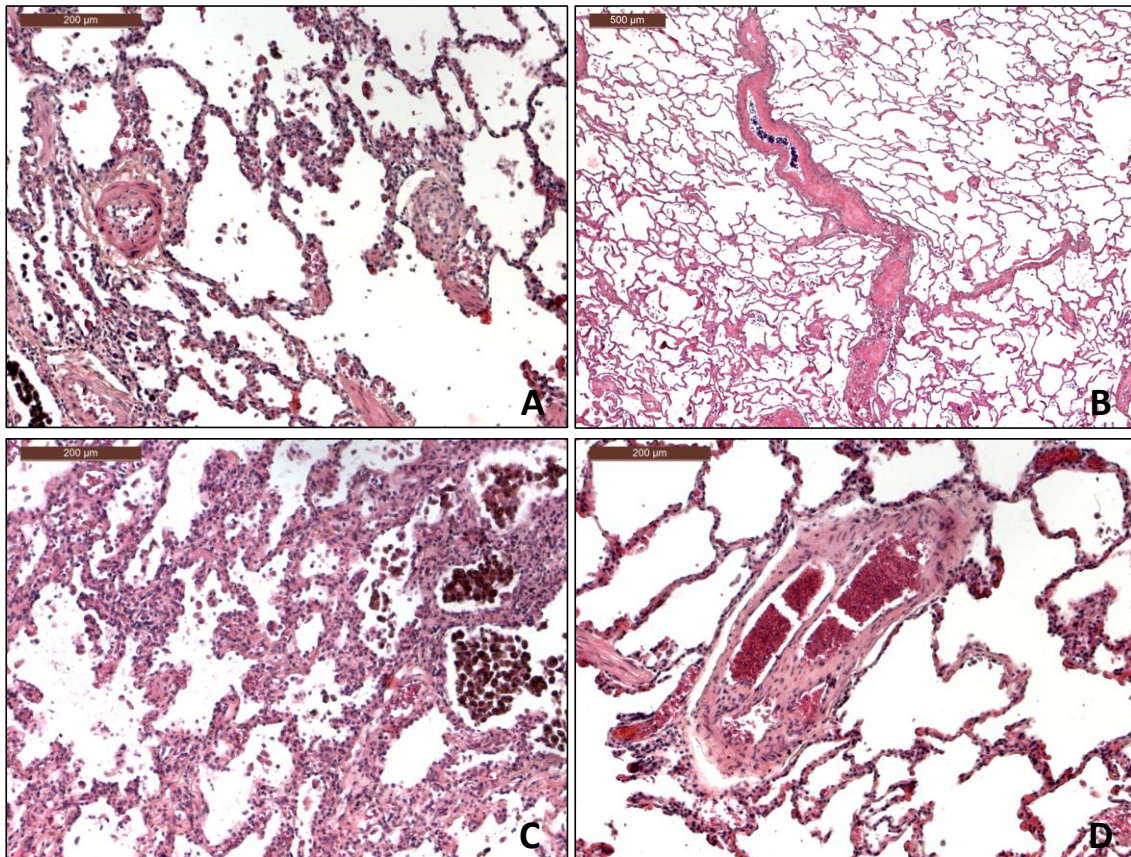


Fig 8: Pulmonary vascular lesions from explanted lungs of patients suffering from CTEPH. **A.** proliferative, fibromuscular lesions of microvessels (centre left and centre right, arterioles / venules) of beneath 100 μm in diameter. Note the concentric wall thickening. **B.** Intimal fibrosis and partial occlusion of a septal vein and preseptal venules in its vicinity. **C.** capillary proliferation within the alveolar septa, reminiscent of pulmonary capillary hemangiomas (PCH); note the numerous packed hemosiderin-laden macrophages within the alveoli (top right). **D.** Colander-like lesion in a small pulmonary artery, corresponding to a partially recanalized thromboembolic lesion

Obstruction of the pulmonary arteries by unresolved fibrotic clots

Major vessel pulmonary artery obstructions are partially recanalized, collagen-rich, wall-adherent clots within the elastic type main pulmonary arteries, reaching down to distal pulmonary arteries at the intra-acinar level (**Fig 8A,D**). Proximally, these lesions appear to be the histologic counterpart to what is known as slits, webs, stenoses or pouching on vascular imaging. In addition, large, elastic-type pulmonary arteries that are subject to long-standing increased PAP lead to atheromatous lesions with increased wall stiffness [117], resembling aortic wall changes in patients with systemic hypertension. Distally, typical obstructive chronic thromboembolic lesions appear as occluded vessels with recanalization and occasionally multiple secondary lumina called colander-like lesions [118, 119].

Secondary microvasculopathy

Secondary microvasculopathy has been first described by Moser and Bloor in human lung tissue obtained by biopsy or at autopsy [120]. These lesions involve the wall of muscular pulmonary arteries (50-500 μm in diameter) and resemble PAH arteriopathy. In human disease [120, 121] as well as in animal models [17, 122], these PAH-like lesions predominate in lung regions non-obstructed by proximal clots (**Fig 8A**). The proposed physiopathological mechanism is that, in the presence of an obstruction of proximal pulmonary arteries, the pulmonary blood flow is redistributed to non-obstructed lung areas leading to high flow and pressure, as well as increased endothelial shear stress [120]. However, Moser in his initial report recognised that this hypothesis does not explain a microvasculopathy that can also be observed in lung areas downstream to completely or partially obstructed proximal vessels.

The microvasculopathy is characterised by remodelling at the level of pre-capillary arteries, capillaries (pulmonary hemangiomatosis-like areas in severe cases) and pulmonary venules (pulmonary veno-occlusive-like). These venous microvascular changes have been observed in lung territories distal to completely or partially obstructed proximal pulmonary arteries, both in humans and in animal models [17, 18, 120, 121] (**Fig 8A-C**). A possible physiopathological mechanism is the development and hypertrophy of systemic bronchial arteries and anastomoses between bronchial arteries and the pulmonary circulation downstream of pulmonary artery stenoses and occlusions [123] (**Fig 9**). In CTEPH patients and in chronic experimental obstruction of the pulmonary arteries in animals, the systemic bronchial arteries are significantly enlarged anatomically and are proliferating (bronchial artery arterio-/angiogenesis, [124]). In addition, substantial bronchopulmonary anastomoses on the pre- and the post-capillary side lead to transmission of systemic blood pressure to the pulmonary circulation [17, 18]. Bronchopulmonary shunting can also be observed within the core of the organising clot, where proliferating vasa vasorum (being the equivalent to bronchial arteries) drain blood into bronchial veins, which, in turn, feed into the pulmonary veins.

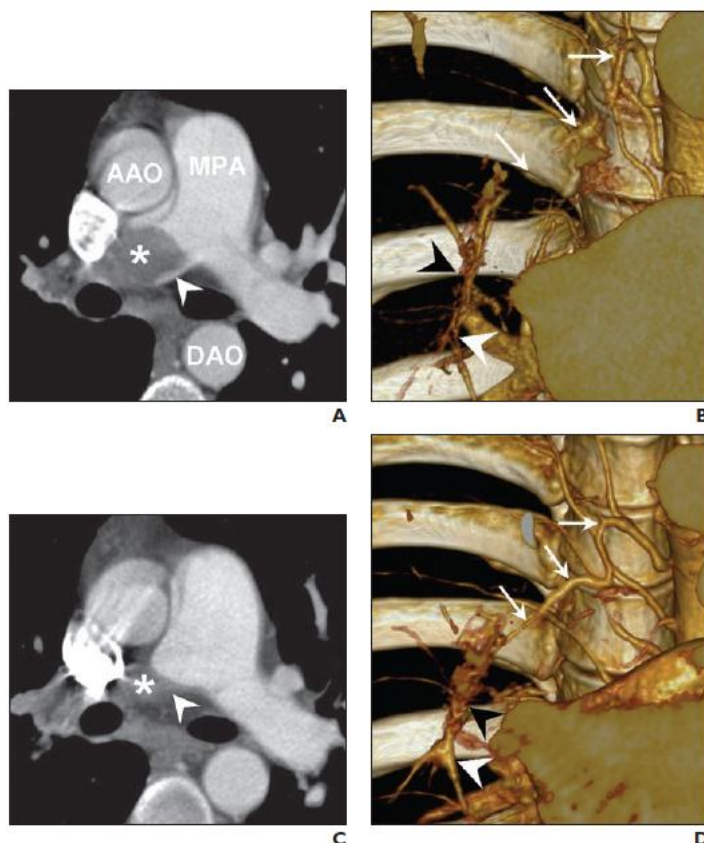


Fig 9: *A*, CTPA shows complete obstruction of right central pulmonary artery due to acute emboli (asterisk). AAO = ascending aorta, MPA = main pulmonary artery, DAO = descending aorta. **B**, Slab volume-rendering image shows normal size of bronchial artery (arrows). Distal pulmonary arteries (white arrowhead) are small in calibre. **C**, follow-up CTPA obtained 16-months later clearly shows CTEPH. **D**, Slab volume-rendering image shows hypertrophy of right bronchial artery (arrows), which connects with vasa vasorum (black arrowhead) to supply distal pulmonary arteries (white arrowhead). Reproduced with permission from [123].

In a piglet model [125], ligation of the left main pulmonary artery associated with progressive embolisation of the right lower lobe artery leads to hypertrophy of the systemic lung vasculature locally, but not in the unobstructed territory (right upper lobe). To summarise, the connection of high-pressure systemic blood flow to the low-pressure pulmonary circulation is suspected to lead to muscular and fibrotic remodelling of pre-capillary arteries, capillaries and venules in obstructed vascular beds of human CTEPH [18], while pulmonary arterial overflow is held responsible for changes in small arteries and arterioles in unobstructed territories. In this piglet model of CTEPH, 6 weeks after surgical reperfusion of occluded left PA, secondary microvasculopathy regressed both in previously occluded and non-occluded territories [17].

While Moser described plexiform lesions in lungs from CTEPH patients [120, 126], others have not observed these lesions that are typical for severe PAH [18]. Interestingly, recent reports suggest that plexiform lesions in PAH might represent broncho-pulmonary shunts through abnormally developed anastomoses [127, 128].

Impact of proximal obstructive fibrotic clots and secondary microvasculopathy on haemodynamic severity

The presence of a severe microvasculopathy in a patient with CTEPH is usually suspected when the extent of mechanical obstruction by fibrotic organised clots does not correlate with the haemodynamic severity assessed by PVR. Some patients with CTEPH have very high PVR despite limited perfusion defects on lung scintigraphy, suggesting the presence of extensive microvasculopathy [129]. The haemodynamic impact of secondary microvasculopathy may also be evaluated with the pulmonary occlusion technique used to partition PVR into upstream resistance (due to proximal fibrotic organised clots) and downstream resistance (due to microvasculopathy). A lower pre-operative upstream resistance, suggesting extensive microvasculopathy, has been associated with a worse outcome after PEA and non-operability [121, 130, 131]. The method, however, is technically challenging and may lack discrimination power; it has not been incorporated in routine assessment.

Clinical consequences of microvasculopathy

The presence of a secondary microvasculopathy downstream of non-occluded proximal pulmonary arteries may play a role in the progressive clinical deterioration of some patients in the absence of PE recurrence. Timing of the development of CTEPH microvasculopathy is unknown [120], but probably highly variable. The presence of a secondary microvasculopathy in CTEPH may explain persistence/recurrence of PH and poor outcome after PEA [132], and provides a rationale for the use of drugs approved for PAH.

Hypothetically, the occurrence of pulmonary oedema after PEA and BPA may be related to the restoration of normal flow to a previously occluded lung region with a microvasculopathy similar to pulmonary veno-occlusive disease and pulmonary capillary hemangiomatosis.

5.2. Imaging of the pulmonary and bronchial circulations

Whilst CT can help in the visualisation of bronchial collaterals, MR can be used for both morphological evaluation as well as quantification of systemic to pulmonary shunt flow.

Computed Tomography Pulmonary Angiography (CTPA)

As standard CTPA is optimised for pulmonary opacification, a longer delay from the injection of contrast medium to image acquisition is necessary for depicting bronchial collaterals (**Fig 10**). ECG gating will permit sharper delineation of all vascular territories without pulsation artefacts. Limiting the acquisition to a single cardiac phase with prospective triggering can yield radiation doses that are comparable to non-ECG gated acquisition.

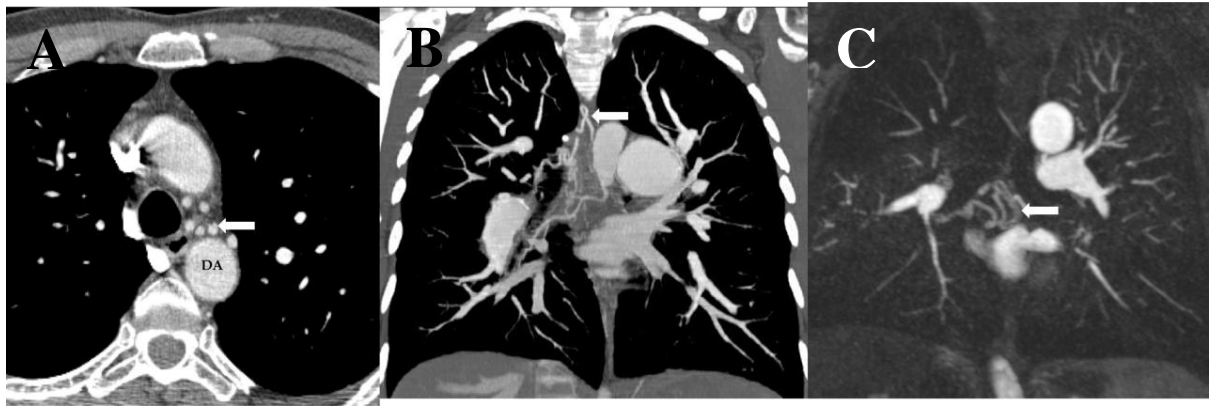


Fig 10: A. and B. Axial and coronal C, and C. MR pulmonary angiography images show the enlarged bronchial arteries (arrows) in a CTEPH patient. DA: Descending thoracic aorta.

DECT improves vascular enhancement allowing assessment of pulmonary arterial perfusion including that of the collateral circulation; the latter is most conspicuous in the low kilovoltage component. PBV maps calculate the iodine distribution in the lung parenchyma and can be a surrogate marker of the underlying vascular reserve (**Fig 11**).

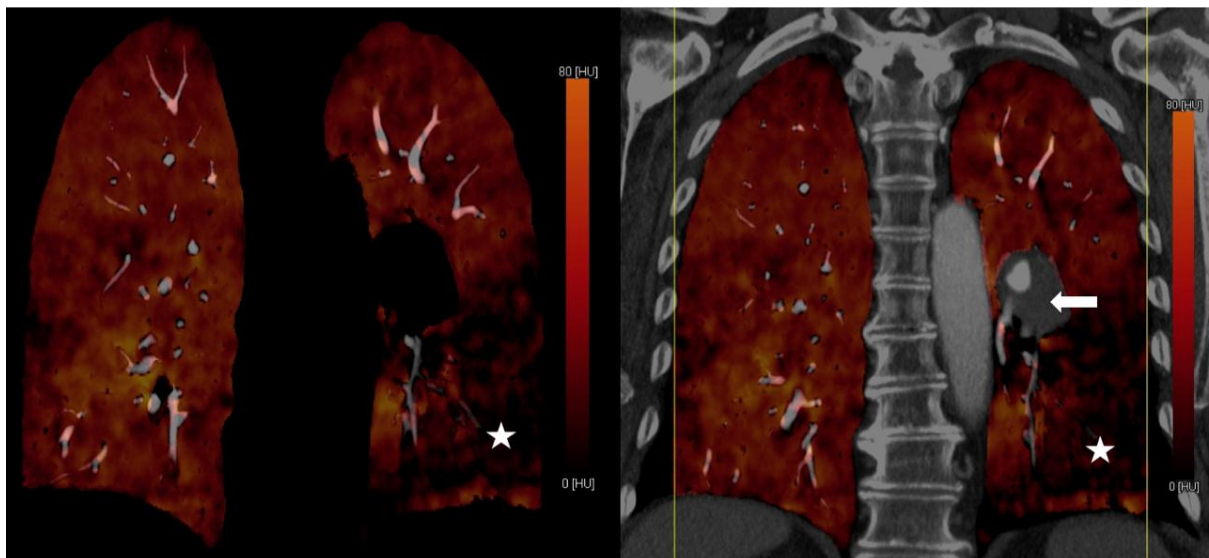


Fig 11: Coronal DECT images with colour-coded PBV map in a CTEPH case with left lower lobe occlusion (arrow) and corresponding large perfusion defect (star).

Magnetic Resonance Imaging (MRI)

MR based phase-contrast measurements can be regarded as a link between macro- and microcirculation. High temporal resolution phase-contrast MRI allows for the calculation of bronchopulmonary shunting by measuring the flow difference between the pulmonary and systemic arterial circulation. The differential flow has been correlated with bronchial artery enlargement on CT, and the shunt size decreases in proportion to the technical success of PEA [133, 134].

4D flow MRI is a time-resolved tridirectional velocity encoded cine sequence that can provide comprehensive assessment of blood flow with colour-coded multiplanar reformations, streamlines and velocity vectors. Using this technique, it has been established that in contrast to the normal central laminar flow along the main PA, patients with PH have a vortical blood flow longer than 14.3% of the

cardiac interval with a positive correlation between the duration of vortices and mPAP [135]. Diastolic vorticity was indicative of mild PH whilst systolic vorticity was seen in severe PH. Small CTEPH case series have shown improvement in flow vortices in the main PA following successful BPA [136].

5.3. The RV in CTEPH

If exposed to similar loading conditions, the RV in patients with CTEPH is on average less adapted than in patients with PAH. This becomes clear by comparing haemodynamic data from CTEPH patients with PAH patients [137, 138]. At a similar PVR, PAP is lower in CTEPH, indicative of a less adapted RV in comparison to PAH [138, 139]. In comparison to PAH, mPAP is less in CTEPH patients. Several factors might contribute to this difference. First, patients with CTEPH are usually older than PAH patients. Second, the time course of increase in RV load may be different in CTEPH and PAH over time. CTEPH is thought to start with an acute episode of pressure overload at the time of acute PE, which may have an impact on RV remodelling. Finally, even when PVR is similar in a CTEPH and a PAH patient, the load for the RV may be different due to differences in wave reflection patterns [140].

Restoring the load of the RV in CTEPH by successful PEA brings a profound reduction of ventricular size and a recovery of systolic function, for the RV and LV [141]. What remains, is an abnormal response to exercise [7, 142].

Statements

- 5.1 *Current knowledge suggests that two types of vascular lesions exist in CTEPH: proximal fibrotic obstruction in large elastic pulmonary arteries and a secondary microvasculopathy in pulmonary vessels < 500 μ m.*
- 5.2 *Morphological delineation of pulmonary and bronchial circulation is possible with CTPA whilst MRI permits both anatomical visualisation and semi-quantitative analysis of the extent of broncho-pulmonary shunting. None of these techniques can quantify the microvasculopathy.*
- 5.3 *RV is less adapted in CTEPH than in idiopathic pulmonary arterial hypertension (PAH), but recovers largely after successful pulmonary endarterectomy (PEA).*

Proposal for future research in CTEPH pathophysiology

- h) Search for biomarkers of fibrotic thrombus transformation*
 - i) Explore modifiers of the transforming-growth factor beta pathway in thrombosis*
-

6. Pulmonary endarterectomy (PEA)

PEA (**Fig 12**) is the treatment of choice for operable patients, inducing major haemodynamic and clinical improvements with a low early mortality (< 3 %) in expert centres.

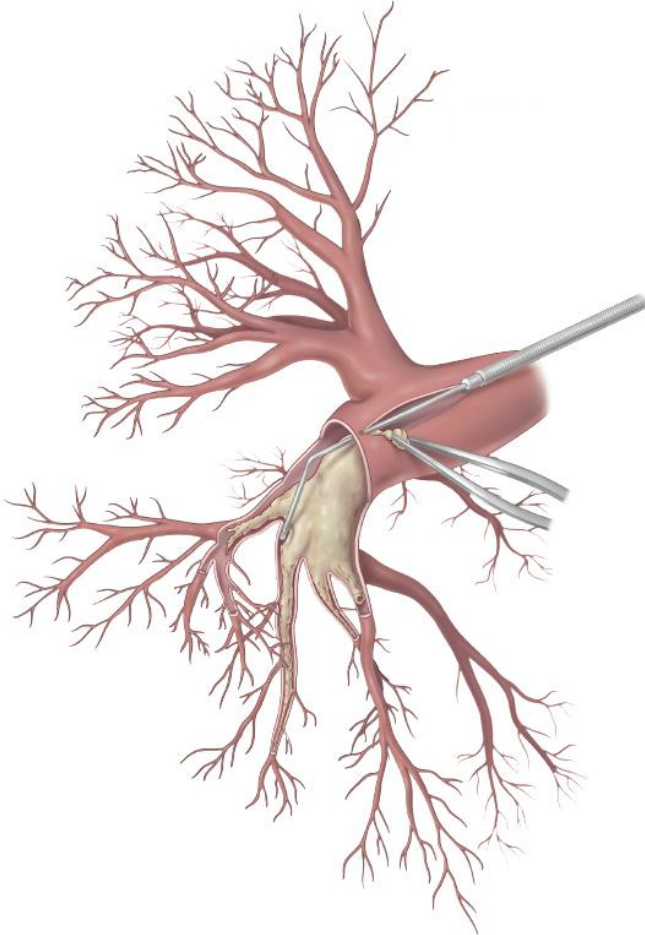


Fig 12: Pulmonary endarterectomy (PEA). The right pulmonary artery is opened, and the suction dissector is introduced between the artery wall and the fibrosis. Following the inside of the artery down to segmental and subsegmental level, the fibrotic material is subsequently freed from the wall and removed with forceps. Reproduced with permission from Maren Hötten Master Thesis in Scientific Design (Maastricht 2016)

6.1. What are the requirements for a PEA centre and surgeon?

The 2015 ERS guidelines recommend that patients with CTEPH should be treated at an expert centre [1], with Jenkins et al. attempting to define the characteristics of an expert centre in 2017 [143]. There should be experience of cardiothoracic surgery, including procedures requiring deep hypothermic circulatory arrest (DHCA), a PH service, expert diagnostic imaging, and an expert multidisciplinary team including surgeons, radiologists, anaesthetists, intensivists, nurses, perfusionists, respiratory therapists and interventionalists able to provide BPA. This publication reiterated the expert consensus view that ideally there should be a limited number of PEA centres serving a population with a case volume of > 50 procedures per annum, based on mortality data in small, intermediate and large centres participating to the International CTEPH registry [146], and at least 5 years' experience, with the highest quality centres achieving in-hospital mortality of <5% and having the ability to perform distal endarterectomy and offer all three modalities of treatment. However, it is appreciated that this may not be possible for smaller countries. At the 2013 WSPH, the CTEPH task force recommended that PEA centres should have extracorporeal membrane oxygenation (ECMO) available to deal with the potential complications of surgery that can be unpredictable [144]. One of the largest experiences with ECMO has indicated that 3.7% of 829 patients required support with an in-hospital survival of 48.4% [145]. Surgeons should be experienced and trained either in cardiac or thoracic surgery. There is no data to suggest that one discipline is superior to the other, as long as thoracic surgeons are

confident with the use of cardiopulmonary bypass (CPB). Most of the surgeons currently working in the largest PEA centres also have a background in intra-thoracic transplantation. For a starting PEA program, clinical practice suggests that mentored operating for one year and experience of at least 50 procedures in a high-volume centre allows selected PEA surgery without any increase in morbidity or mortality. Adequate training of anaesthetists and intensivists is also mandated.

6.2. How much anatomical overlap between PEA and BPA and which is the best treatment for segmental disease?

The degree of anatomical overlap between what disease is accessible to PEA and BPA is thought to be considerable, although there is little published data and there are no RCTs comparing both techniques [147] (**Fig 13**). There is no published data to indicate a threshold of accessibility from pre-operative imaging. Clinical experience indicates that both techniques can access subsegmental disease and both are viable treatment options for disease confined to segmental level. The surgical technique usually relies on traction of the wall lining more proximally and can therefore progressively advance the dissection plane into very small distal vessels until the specimen breaks away, beyond the point that can be visualized and instrumentation can directly reach. The type of lesion, as well as the location, is probably more important for BPA than PEA surgery. In an angiographic classification from Japan, it was found that outcomes were superior, and complications lower, for ring like stenosis and web lesions compared with total occlusions [148]. Only PEA surgery can reliably tackle disease in the main PA and its lobar branches as this more proximal disease usually includes organised thrombus and/or more bulky fibrotic webs. The intra-operative surgical classification has been recently revised to recognise the level at which disease starts and separate segmental and subsegmental disease (levels III and IV) to reflect modern surgical practice [147]. One series has specifically investigated the outcome of PEA surgery for more distal disease [149]. In this series of 331 patients operated by a single surgeon between 2008-13, PEA for Jamieson type 3 disease (segmental) was performed without an increase in operative mortality or morbidity. There were equivalent haemodynamic results at discharge, and importantly at 1 year, to those achieved for patients with more proximal disease.

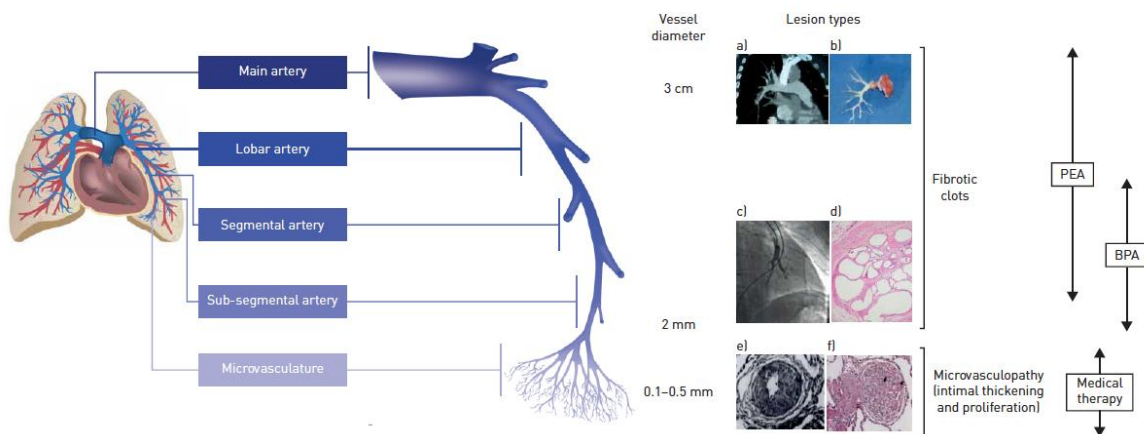


Fig 13: Respective targets for PEA and BPA. Reproduced with permission of the © ERS 2020: *European Respiratory Review* 2017 26: 170105; DOI: 10.1183/16000617.0105-2017 [147]

6.3. What is a successful outcome after PEA surgery?

There is no definition of success after PEA surgery, but patients would expect to survive the operation without cognitive dysfunction or major morbidity and recover with reduced PAP to gain improved

functioning and quality of life that is sustained to prolong lifespan. It is the most effective treatment for CTEPH with the largest reduction in PAP and PVR, by 21 mmHg and 561 dynes/s/cm⁻⁵ in a recent meta-analysis [150]. The benchmark of postoperative mortality below 5% was set by the International CTEPH registry that included 386 patients from 17 surgical centres [146]. A larger series from an experienced centre reported a mortality of 2.2% for a cohort of 500 patients [151]. More recently the International CTEPH registry reported 3 year survival of 89% for the cohort of 404 operated patients compared with 70% for 275 patients who did not undergo surgery [98]. The longest complete follow up is from the UK national series of 880 patients demonstrating 72% survival at 10 years for a mean age of 57 years. During extended follow up, 49% of deaths were unrelated to CTEPH [152]. Despite the need for DHCA to perform PEA surgery, cognitive function was shown to improve at 3 months and 1 year following surgery in a blinded randomised controlled trial [153]. The same study also reported improved quality of life using the specific PH CAMPHOR score. The longest follow up of functional class post-surgery is in a series of 157 patients from the Pavia centre, with improvement in functional class from 97% in class III/IV before surgery to 74% in class I at 4 years [154].

6.4. How to manage residual/recurrent disease?

There is no generally accepted definition of residual PH post PEA. Different publications have used different criteria, with an overall estimate of 25% in a meta-analysis [150]. True recurrent CTEPH (i.e., evidence of improvement after PEA, followed by new symptoms and changes on imaging) is much rarer, only 6 of 356 patients suffered from new PE after PEA in the UK series [152].

Management of significant residual PH can be challenging in the early postoperative period, and it is the most common cause of in-hospital mortality. ECMO can successfully help salvage selected patients with severe residual PH and haemodynamic collapse and allow bridging to lung transplantation, but experience is limited [145]. Medical therapy has not proven helpful in the early phase, with only one small randomised controlled trial demonstrating reduced PVR with inhaled iloprost in the immediate postoperative period [155].

Patient long-term outcome after PEA is also affected by residual PH, with data showing that mPAP ≥ 38 mmHg and PVR ≥ 425 dynes·s⁻¹·cm⁻⁵ at reassessment predict CTEPH-related deaths [152]. A suggested threshold to initiate drug therapy was a mPAP >30 mmHg [152]. In operated patients with postoperative PVR >300 dynes·s⁻¹·cm⁻⁵, there is evidence for reduced PVR and improved 6-minute walk distance (6MWD) with riociguat in the CHEST-1 study [156]. There is now some experience with the use of BPA to treat residual distal lesions post PEA [157]. A further alternative in specialised centres is to consider redo PEA and contemporary results in selected patients are satisfactory [158]. The 2018 WSPH treatment algorithm recommended the use of medical therapy and consideration of BPA or redo PEA in patients with persistent symptomatic PH following PEA [20].

Statements

- 6.1 *Requirements for a PEA centre are based on expert opinion only, but ≥ 50 cases as centre annual volume, and a properly trained surgeon have been proposed.*
- 6.2 *There is likely considerable anatomical overlap between BPA and PEA, but segmental and subsegmental disease are suitable for surgery in expert, high volume centres.*
- 6.3 *Successful outcome after PEA is multifactorial and assumes in-hospital mortality $< 5\%$, survival of 90% at 3 years, improved functional class and quality of life.*
- 6.4 *Residual PH after PEA presents in about 50% and represents a target for recently introduced medical therapies and BPA. There is some evidence for their use if post-PEA mPAP remains above 30 mmHg in the presence of symptoms.*

Proposal for future research on PEA

- j) Evaluation of the impact of pre-operative treatment (drug or interventional) on the outcome of PEA surgery*
 - k) Comparison of the efficacy, risk and long-term outcome of PEA with BPA for segmental disease*
-

7. Balloon pulmonary angioplasty (BPA)

7.1. What type of CTEPH patients are candidates for BPA? What is the role of pre-treatment with PH-targeted therapy prior to BPA?

For CTEPH patients deemed technically inoperable, percutaneous BPA (**Fig 14**) has had a recent renaissance sparked by technical refinements introduced from Japan [159-161]. With now growing worldwide experience with BPA, and together with advances both in PEA and medical therapy as overviewed in this series, there has been a major reset on how CTEPH cases are evaluated and treated.

BPA is not a replacement for PEA or targeted medical therapy in CTEPH. Instead, BPA fills an intervention gap for those CTEPH cases not eligible for PEA and/or may be considered in conjunction with either therapies as a complementary treatment modality [147, 162, 163]. Accordingly, the determination to proceed with BPA in any CTEPH case must not be made in isolation of these other established therapies [1]. The 2015 ESC/ERS Guidelines had determined that BPA at the time garnered a *IIB-C* recommendation, meaning that it may be considered according to expert opinion

and/or small studies [1]. This will likely require updating in the next guidelines as the intervention and our understanding of its role in CTEPH treatment have evolved at a rapid pace.

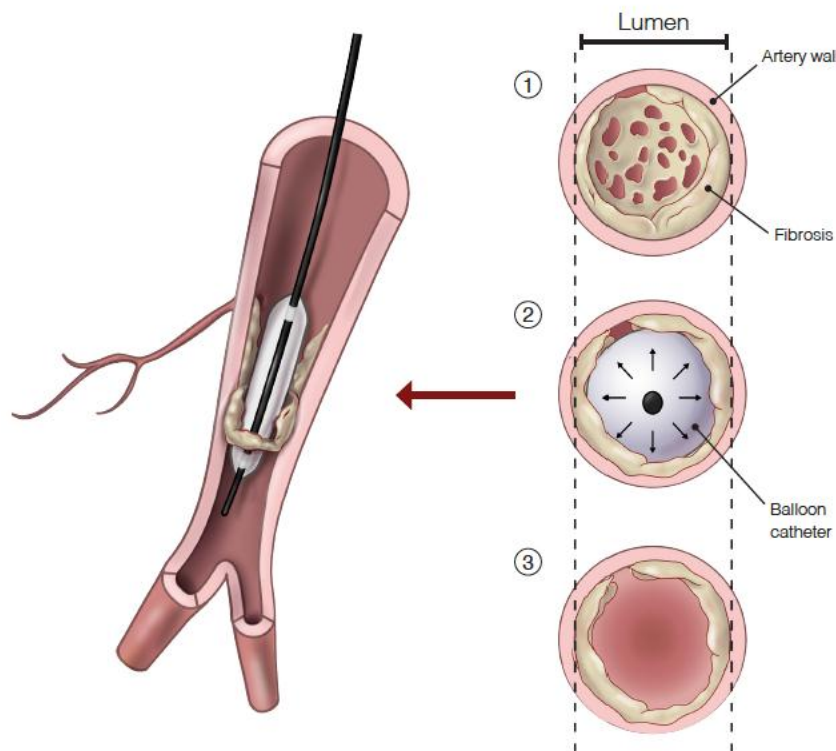


Fig 14. Balloon pulmonary angioplasty (BPA). A web-lesion in a subsegmental branch of the pulmonary artery. The wire is introduced between the fibrotic material and the balloon is inflated, leading to a rupture of the web. Fibrotic

material is connected to the vessel wall. Reproduced with permission from Maren Hötten Master Thesis in Scientific Design (Maastricht 2016)

7.2. What are the clinical outcomes and expectations of BPA for CTEPH?

In experienced settings, BPA has produced improvements in pulmonary haemodynamics, 6MWD, functional class, and quality of life [162, 164-166] by improving flow through the pulmonary circulation (**Fig 15**). Additional improvements following BPA have been demonstrated with RV function by cardiac MR and in ventilatory efficiency by CPET [56, 167]. The early reports of BPA

benefit were initially from Japan – which raised the question of reproducibility and applicability to other populations or regions with active PEA programs. The subsequent national BPA series published from Germany and France have reinforced support of BPA for CTEPH cases deemed inoperable [168, 169]. The German series was the first major BPA report from a region with high volume PEA experience [168]. They reported BPA improvements in 6MWD by +33 meters and reductions by 18% and 26% in mPAP and PVR, respectively. The subsequent French report represented the largest single centre consecutive BPA series since program initiation with 1006 interventions [169]. They reported 26% and 43% reduction in mPAP and PVR, respectively with BPA. When they compared results between cases from the early programmatic period to the more recent cohort, the latter group had relatively larger magnitude of haemodynamic benefit. They also observed lower complication rates in the more recent BPA cohort – supporting the recognition of a learning-curve and the value of experience impacting on outcomes. Overall 6MWD improvement was +45 meters in this series. Accordingly, even from centres performing high volume of PEA surgeries – which may have influence on the types of cases selected for BPA – the results of BPA have been encouraging.

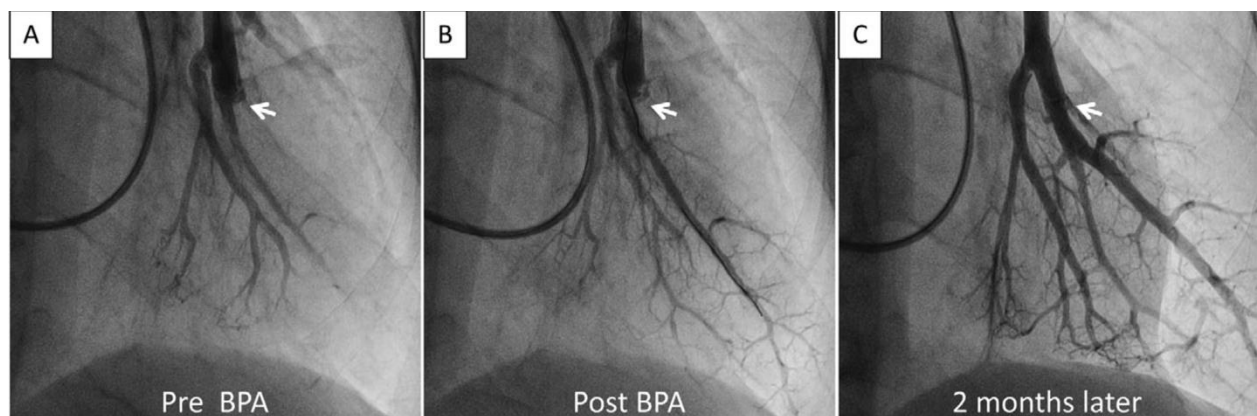


Fig 15: Pulmonary angiogram before and two time periods after BPA treatment. Reproduced with permission from [170].

7.3. What are the important complications associated with BPA and their acceptable rates for an expert centre?

Early pivotal experience with BPA reported in 2001 was notable for high complication rates with 61.1% lung injury, 16.7% of patients in need of mechanical ventilatory support, and 1 procedure related mortality among the 18 patients [171]. In contrast, the new era of BPA has yielded safer results [164] [165]. Main contributors to this improved safety include, 1) a better understanding of the mechanisms of BPA complications, 2) application of technical refinements introduced from expert centres, and 3) appreciation of the BPA learning-curve and team experience (starting with patient selection) as critical factors in reducing and better managing the complications when they occur [148, 169, 172]. Contrary to earlier reports describing BPA associated injury as reperfusion pulmonary oedema (as observed after PEA), there is now general consensus that the lung injury associated with BPA (**Fig 16**) is instead from mechanical vascular injury during wire manipulation or balloon over-dilation [172]. With such knowledge and with greater volume of procedures adding to experience level, BPA complications can be reduced to manageable rates [169, 172]. From the German and French BPA series, the overall complication rates were 9.4% and 11.2% per procedure, respectively [168, 169]. In the more recent cohort of 562 consecutive procedures from the French series – period described as being after the initial learning-curve – the rate of complications had halved from initial

15.8% to just 7.7% per procedure [169]. Results from different cohorts suggest that the rate of complication after BPA is closely related to the severity of PH at the time of BPA [169, 172, 173].

BPA procedures still carry a risk of mortality. The two largest published series, the French report and the multicentre Japanese registry, the BPA mortality rates were 3.8% and 3.9%, respectively [72, 169]. Currently, there is an ongoing International BPA Registry which aims to better define and compare results and complications in a prospective fashion from established BPA centres across Japan, Europe, and USA (NCT03245268). This registry has potential to shed some valuable light on the heterogeneity in current BPA practices across regions and among centres.

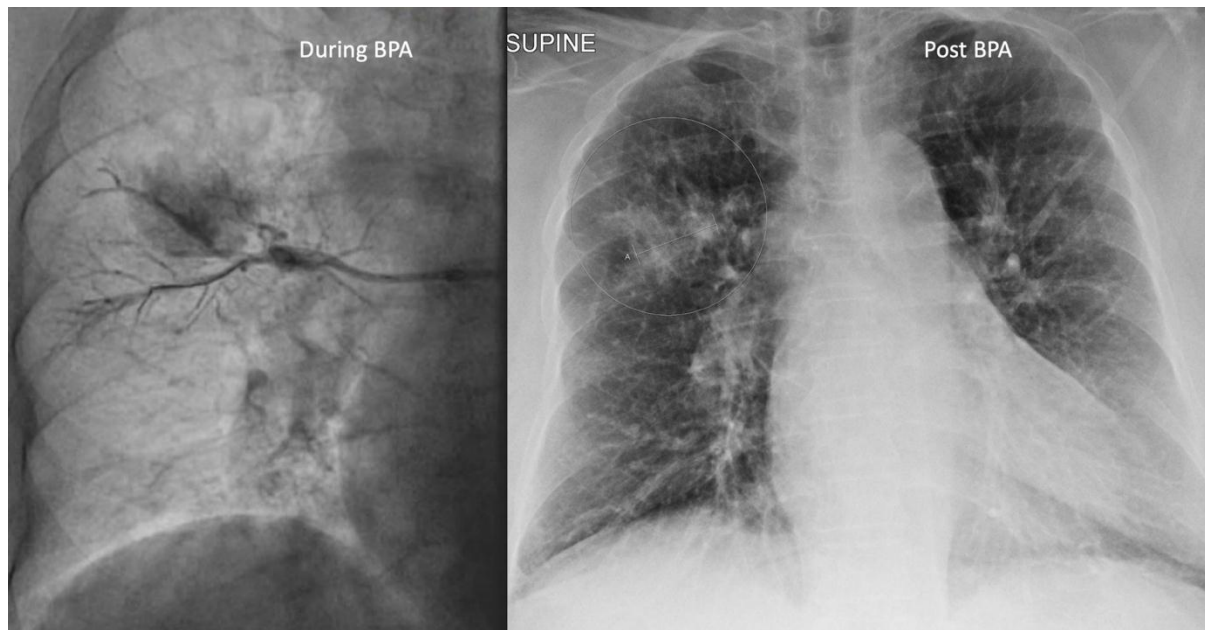


Fig 16: Vascular injury during BPA signalled with new cough followed by haemoptysis resulting in temporary reversal of anticoagulation and end of BPA session. (from N Kim, UCSD)

7.4. What are the requirements to establish a BPA centre? What criteria and parameters define an expert BPA centre?

There are numerous key limitations regarding BPA and its treatment of CTEPH. The reported safety and efficacy of BPA come from expert centres performing these and other CTEPH treatment modalities on a routine basis. Since success of BPA starts with proper patient selection and centre BPA experience, the observed results may not be applicable to all centres. The procedure remains risky even in experienced hands and should be confined to expert centres [147]. Furthermore, the benefits of BPA need to be interpreted with some caution since there is still paucity of long-term results beyond 5 years [174, 175]. Although there are some encouraging early observations on improved survival with BPA in the inoperable CTEPH population [176], whether BPA treated patients sustain an excellent long-term survival similar to that observed following successful PEA remains unknown [98, 152]. Furthermore, unlike PEA, BPA requires multiple sessions. There is no consensus or guidelines on treatment endpoint or continuation of BPA efforts. Lastly, the addition of BPA provides a more complex treatment decision for any individual CTEPH patient. The ideal sequence and timing of combination or stepwise approach incorporating all available treatment modalities is yet to be determined and may need to take into consideration centre or region-specific factors.

Although the 2015 ESC/ERS guidelines proposed preliminary definitions of an expert PH referral centre [1], and the topic was deliberated within the 2018 WSPH TF on CTEPH in the context of PEA and BPA centres [20], we currently do not have adequate evidence to define expertise based solely on procedural volume. Nevertheless, and similar to PEA surgery [146, 151], there is consensus and demonstrable correlation between BPA outcomes with level of BPA experience [169]. Of note, percutaneous non-BPA interventional experience, while helpful, does not ensure success with BPA given the differences between the systemic and pulmonary vasculature, nature of complications, and targeted pathology [170]. Furthermore, and worth re-emphasising, aside from technical proficiency that comes with procedural volume, success of BPA and individual case outcome also relies importantly on proper patient selection within the context of a multidisciplinary CTEPH team considering all current and available treatment modalities [1, 170]. For a starting BPA program, clinical practice suggests that direct mentorship from a high-volume centre followed by experience of at least 50 procedures allows results without excessive morbidity or mortality.

Within a relatively short period of time, BPA has evolved from an experimental modality to becoming an established treatment option for inoperable CTEPH. Looking ahead, thresholds for successful BPA outcomes, acceptable rates of complications, and optimal incorporation with the other treatment modalities need to be investigated and established. This will require concerted effort and collaborations among CTEPH centres.

Statements

- 7.1 *Inoperable CTEPH patients can benefit from BPA. Optimal CTEPH treatment requires a multidisciplinary team approach considering PEA, medical therapy, and BPA.*
- 7.2 *Long-term results after BPA are available out to 8 years after the procedure. Safety and efficacy of BPA correlate with centre experience.*
- 7.3 *Vascular injury rather than reperfusion pulmonary oedema is the likely cause of any severity of lung injury after BPA.*
- 7.4 *Similar to PEA, proper training in a high-volume centre is critical for BPA.*

Recommendations for research and training

- l) Define the role of PH targeted medical therapy in relation to BPA*
 - m) Identify treatment goals and key endpoints for completing BPA interventions per individual patient*
 - n) Create standardised definitions of BPA complications*
 - o) Establish criteria or expected outcome thresholds to be recognised as an expert BPA centre*
-

8. Medical treatment

8.1. Long-term anticoagulation: what is the current standard of care in CTEPH (VKAs versus NOACs)?

Besides lifelong anticoagulation, CTEPH basic therapy includes diuretics in case of right heart failure and oxygen in hypoxemic patients [91, 92]. Traditionally, VKAs have been the mainstay of anticoagulant treatment in PAH and CTEPH, but NOACs are increasingly used [89, 91, 92, 177]. There is no strong data on the efficacy and safety of NOACs in CTEPH. In addition, robust information is needed on drug-drug interaction between NOACs and pulmonary vasodilators used in CTEPH. Because NOACs are regularly used in some centres, registry-based information has been recently released [89, 177].

Consecutive CTEPH patients undergoing PEA between 2007 and 2018 at Royal Papworth Hospital have been included in a retrospective analysis (794 patients were treated with VKAs and 206 with NOACs following PEA) [89]. Haemodynamic and functional improvements were observed in both groups following PEA. In terms of safety, major bleeding events were equivalent in those treated with VKAs and NOACs (0.7%/person-year), but the VTE recurrence rate was proportionately higher with NOACs (4.62%/person-year) than VKAs (0.76%/person-year), although survival did not differ [89]. Additionally, in a retrospective analysis of 405 consecutive PEA cases, CTEPH patients on NOAC were twice as likely to have associated acute or subacute thrombi removed at the time of surgery compared with those on conventional anticoagulant therapies [178].

In the setting of BPA continued VKA treatments without interruptions appear to be practiced by the majority of expert centres.

EXPERT, an international, multicentre, prospective, non-interventional registry study, assessing riociguat safety in clinical practice (NCT02092818) has recently released data from PAH/CTEPH patients who received riociguat with either concomitant NOACs (n=227) or VKAs (n=617) at baseline [177]. In terms of adverse events, haemorrhages were reported in 26 (11%) patients in the NOACs group and 81 (13%) patients in the VKAs group, and thromboembolic events were reported in 9 (4%) and 24 (4%), respectively. In terms of serious adverse events, haemorrhages were reported in 13 (6%) patients in the NOACs group and 39 (6%) patients in the VKAs group, fatal haemorrhages in 1 (0.4%) and 6 (1%), respectively, and thromboembolic events were reported in 8 (4%) and 23 (4%), respectively. Thus, serious bleeding/thrombotic events were uncommon, and their frequency was similar between PAH/CTEPH patients receiving concomitant NOACs or VKAs at baseline. Rates of serious haemorrhage or thromboembolic serious adverse events were similar with baseline NOACs or VKAs for PAH and CTEPH, separately [177].

A subgroup of CTEPH patients present with antiphospholipid syndrome. In that setting, VKAs (INR target 2.5) have been demonstrated as carrying more benefit and less risk than NOACs in high-risk patients with thrombotic antiphospholipid syndrome (triple positive for lupus anticoagulant, anticardiolipin, and anti- β_2 -glycoprotein I antibodies of the same isotype) [93].

8.2. PH medication: what is the available evidence on approved and not (yet) approved PH medications in CTEPH?

Acute pulmonary vasodilator testing is not recommended in CTEPH, even if PH reversibility could be a predictor of residual PH after PEA [179], and there is no indication of calcium channel blockers use in this condition [180]. In CTEPH, there is evidence of small pulmonary vessels disease indistinguishable from that of PAH, and similar treatment targeting the endothelin-1, nitric oxide and prostacyclin pathways have been studied [119].

In the CHEST-1 RCT of 261 patients with inoperable CTEPH or persistent/recurrent PH after PEA, an oral guanylate cyclase stimulator (sGC, riociguat, targeting the nitric oxide pathway) significantly increased 6MWD and reduced PVR, as compared to placebo [156]. These data led to the approval of riociguat for patients with inoperable CTEPH or persistent/recurrent PH after PEA. Currently, riociguat is being tested in RCT, addressing its efficacy and safety as bridging therapy for patients scheduled to undergo PEA (NCT 03273257). Another study compares riociguat to BPA in inoperable patients (NCT 02634203).

Sildenafil, a phosphodiesterase type 5 inhibitor (PDE5i), has been tested in a small RCT in inoperable CTEPH [181]. Sildenafil (40 mg tid) or matching placebo was given to 9 and 10 inoperable CTEPH patients, respectively. At 12 weeks, no improvement was seen in the primary endpoint (6MWD) despite a positive effect on PVR [181]. This pilot study was insufficiently powered to test the primary endpoint, and larger-scale trials of sildenafil in inoperable CTEPH have not been performed since then. Sildenafil is thus not approved for CTEPH.

The dual endothelin receptor antagonist (ERA) bosentan showed no improvement in 6MWD (despite a positive effect on PVR) in a RCT of 157 patients with inoperable CTEPH or persistent/recurrent PH after PEA (BENEFIT study) [182]. Bosentan is thus not approved for CTEPH. Safety and efficacy of dual ERA macitentan was assessed in a phase 2 RCT, showing significantly improved 6MWD and PVR compared to placebo in 80 CTEPH patients adjudicated as inoperable (MERIT-1) [183]. Interestingly, this was the first RCT in CTEPH assessing the combination of an ERA with other medications approved for PAH but excluding riociguat (61% of patients received off-label PDE5i or oral/inhaled prostanoids).

Besides off-label use, there is a single RCT studying prostacyclin analogues in inoperable CTEPH (CTREPH study) [184]. This RCT showed that long-term subcutaneous treprostinil is safe and effective in 105 severe inoperable CTEPH patients, with improvements of 6MWD, PVR, functional class, and NT-proBNP. In this study, 30% of patients received other pulmonary vasodilator therapies. These data led to the marketing authorisation of treprostinil for patients with inoperable CTEPH or persistent/recurrent PH after PEA.

8.3. Combination therapy: is there a role for initial or sequential combination therapy in CTEPH?

Sequential combination therapy of PH medications was allowed in CTEPH RCT such as MERIT-1 [183] and CTREPH [184]. By analogy with PAH [177], initial dual oral combination therapy is currently considered in expert centres for patients with severe CTEPH. This is particularly true in inoperable CTEPH prior to BPA, in order to perform BPA in patients with less severe haemodynamic impairment and presumably at lower risk of procedure-related complications. Recent single-centre registry data of initial dual oral combination therapy using an ERA in association with either a PDE5i or riociguat in inoperable CTEPH patients have been reported [185]. These data indicate that initial oral dual combination therapy resulted in more pronounced reduction in PVR, when compared to monotherapy.

8.4. De-escalation: when and how to stop/reduce PH drugs after successful BPA/PEA?

Most CTEPH patients improve markedly clinically and haemodynamically after BPA and/or PEA [72, 169]. Lifelong anticoagulation is mandatory even if PEA and/or BPA have normalised pulmonary haemodynamics at rest, while the use of diuretics and oxygen is often no longer needed. Similarly, stopping or de-escalating PH medications may be considered after successful BPA and/or PEA. The Japanese multicentre registry for BPA indicates that PH medications were used in 72% of 308 cases before BPA, and 45% of 196 cases at last-follow-up (at a mean of 425 ± 281 days after the final BPA procedures) [72]. In the French experience, 62% of 181 patients undergoing BPA received PH medications prior to BPA (26.6% monotherapy, 28.3% double combination, and 7.1% triple combination therapy) [169]. An ongoing international BPA registry will provide long-term

information on this procedure and more details on the use of PH medications before and after BPA (NCT03245268).

Statements

- 8.1 *According to current guidelines, CTEPH patients should be treated with lifelong anticoagulation; vitamin K antagonists (VKAs) are the mainstay of anticoagulant treatment in CTEPH, but non-vitamin K antagonist oral anticoagulants (NOACs) are increasingly used with no safety issues reported yet. Antiphospholipid syndrome is a contraindication to NOACs.*
- 8.2 *Riociguat, an oral guanylate cyclase stimulator, and treprostinil, a subcutaneous prostacyclin analogue, are approved for patients with inoperable CTEPH or persistent/recurrent PH after PEA; other PH medications have been tested in CTEPH and are used off-label.*
- 8.3 *Oral combination therapy is a common practice in CTEPH patients with severe haemodynamic compromise.*
- 8.4 *Withdrawal of PH medications is usually considered after successful BPA and/or PEA.*

Proposal for future research on medical therapy for CTEPH

- p) *Prospective registry data and/or studies to evaluate the safety of NOACs in CTEPH are encouraged*
 - q) *Studies testing the efficacy and safety of initial dual oral combination therapy are needed in CTEPH patients with severe haemodynamic compromise*
 - r) *A dedicated trial of carefully monitored withdrawal of PH medications should be considered after successful BPA and/or PEA*
-

9. Multimodality treatment

9.1. What are the criteria for selecting candidates?

Many patients may have mixed anatomical lesions with lobar, segmental and microvascular lesions. With three effective treatments now available, the current treatment paradigm has evolved to include a multimodal approach to management. Such an approach involves employing combinations of PEA, BPA and pharmacological therapy to target proximal lesions, distal lesions and microvasculopathy, respectively. Currently, there is no guidance or standardisation regarding assessment of suitability for multimodal therapy and patient selection is performed on a case-by-case basis in expert centres through a multidisciplinary team approach.

Given the various treatment options for CTEPH, lung transplantation is now rarely considered in this group of patients.

9.2. Is there a potential role for PH-targeted medical therapy prior to PEA in patients with operable CTEPH?

The preoperative PVR has been shown to be a predictor of postoperative mortality [146, 151, 186]. In the International CTEPH registry, including 386 operated patients, an almost linear relationship between preoperative PVR and in-hospital mortality was observed [146]. The use of PH-targeted therapy in patients with high preoperative PVR may improve pulmonary haemodynamics before surgery and potentially reduce the morbidity and mortality associated with PEA. Two case series examined a total of 21 patients treated with intravenous epoprostenol prior to PEA. An improvement in pre-PEA haemodynamics, but no change in post-PEA haemodynamics was observed compared to controls [187, 188]. In a randomised, controlled single-blind study including 25 patients with total pulmonary resistance (TPR) $> 900 \text{ dyn.s.cm}^{-5}$, pretreatment with bosentan for 16 weeks demonstrated a reduction in pre-PEA TPR and mPAP but no difference in post-PEA haemodynamics compared to controls [189]. In this study, four patients died during or after PEA (1 patient in the bosentan group (7.6%) and 3 patients in the control group (25%)). In a retrospective analysis of CTEPH patients referred to the University of California at San Diego, Jensen et al. assessed the effects of pre-PEA PH-targeted therapy on pre-PEA haemodynamics and post-PEA outcomes [102]. For this analysis, the subjects were divided into 2 groups: those on PH-targeted therapy before referral for PEA and those who were not (control group). The authors showed that the use of PH medications delayed the time to referral for PEA with only a minimal improvement in preoperative mPAP. In addition, their use did not result in any differences in post-PEA haemodynamics or outcomes [102]. In the International CTEPH registry mentioned above, 29% of operated CTEPH patients had received PH-targeted therapy prior to PEA. These patients had more severe haemodynamic profile than those who did not receive bridging therapy, while no significant difference was observed in either postoperative PVR or postoperative complications between the 2 groups. More interestingly, the authors found that bridging therapy with PH-targeted drugs was associated with an increased risk of death [98].

Whether PH-targeted therapies before surgery in patients with operable CTEPH may result in better survival cannot be currently determined on the basis of the present results. The ongoing randomised, placebo-controlled, multicentre PEA bridging study is looking at safety and efficacy of riociguat prior to PEA in patients with operable CTEPH and high preoperative PVR ($> 800 \text{ dyn.s.cm}^{-5}$) (NCT0327357).

9.3. Is there a role for combined PEA and BPA in patients with CTEPH?

Some CTEPH patients may have mixed anatomical lesions with surgically accessible lesions for one lung and inoperable lesions affecting the contralateral lung. Depending on the severity of PH, low-risk patients with mixed anatomical lesions may undergo PEA, and if necessary, BPA during follow-up after surgery. High-risk patients (with high preoperative PVR) might benefit from a combined therapy

with BPA (prior to or at the same time as surgery) and PEA to decrease the surgical risk and improve the final result. However, data regarding the impact of this strategy on postoperative outcome are very limited so far and further studies are needed to confirm its clinical relevance [163, 190].

In large PEA cohorts, it has been shown that a significant proportion of patients may have residual or recurrent PH following PEA, that can adversely affect their quality of life and outcome [146, 151, 152, 186]. Three case series, including a total of 34 patients, have specifically investigated the safety and efficacy of additional BPA for the treatment of residual or recurrent PH after PEA [157, 191, 192]. The majority of patients were treated with PH-targeted drugs before BPA and the time between PEA and first BPA session ranged from a few months to several years. In these case series, BPA improved haemodynamics and exercise capacity with a rate of complication that was similar to that observed in inoperable CTEPH patients treated with BPA.

BPA has also been reported as a rescue treatment for early failure of PEA without producing convincing results [193, 194].

9.4. Is there a role for combined use of PH-targeted therapy and BPA in patients with inoperable CTEPH?

Most BPA series reported to date included a high proportion of patients who were treated with PH-targeted therapy prior to BPA. In initial Japanese reports, PH-targeted drugs were initiated to improve the safety of BPA by optimising pre-BPA haemodynamics [159, 161]. This strategy was based on the finding of Feinstein et al. who first showed that a pre-BPA mPAP greater than 35 mmHg was correlated with the occurrence of lung injury known as one of the main complications related to BPA [171].

This approach has been applied in more recent studies although there have been no clinical trials specifically designed to investigate its effectiveness [48, 72, 168, 169, 172, 175]. In two of these studies the relationship between high pre-BPA mPAP and occurrence of lung injury was also demonstrated, thus supporting the use of pharmacological treatments prior to BPA [169, 172]. The effects of this strategy in inoperable CTEPH have been examined in two studies. In a single-centre study, consecutive patients with inoperable CTEPH were treated with medical therapy prior to BPA, which resulted in improved cardiac index, PVR, and exercise capacity but little change in mPAP [175]. The patients then underwent BPA and had significant further reductions in mPAP and PVR and further improvement in symptoms and exercise capacity. In an observational cohort study, Wiedenroth et al. investigated more specifically the effects of a sequential treatment with riociguat and BPA [195]. The authors showed that riociguat improved haemodynamics in patients eligible for BPA and that BPA led to further improvement in exercise capacity and haemodynamics. These data suggest that medical therapy combined with BPA may have an advantage over medical therapy alone, although larger prospective studies are needed to confirm this finding.

Statements

- 9.1 *There is no consensus on eligibility criteria for multimodal therapy, which is dependent on the expertise and judgement of each individual CTEPH centre. Patient selection for multimodal therapy is performed in expert centres through a multidisciplinary team approach.*
- 9.2 *There is no convincing evidence that preoperative pharmacological treatment is beneficial in patients with operable CTEPH. Nevertheless, PH-targeted drugs as bridging therapy to PEA is sometimes considered in selected high-risk patients (with high preoperative PVR) after multidisciplinary team assessment in expert centres.*
- 9.3 *The role of BPA as bridging therapy prior to PEA in patients with mixed surgically accessible and inaccessible lesions needs to be explored. The potential benefit of hybrid procedures*

simultaneously combining PEA and BPA in such patients needs to be confirmed by further studies. There is insufficient evidence to support the use of BPA as a rescue procedure for early failure of PEA. Additional BPA most often in combination with PH-targeted medical therapy is common practice for patients with persistent symptomatic PH after PEA.

- 9.4 *Most task force members use PH-targeted therapy prior to BPA to improve the safety of BPA although there have been no clinical trials investigating the benefit of this approach on the rate of BPA-related complications. Some data suggest that the combination of PH-targeted therapy and BPA provides better results than medical therapy alone.*

Proposal for future research in multimodality treatment

- s) *Studies are needed to investigate the most appropriate approach to combination of BPA and PEA*
-

10. Rehabilitation

10.1. What is the cause of exercise limitation in CTEPH?

The role of rehabilitation in PAH and CTEPH has been well established [196, 197]. Despite the fact that the beneficial effects of rehabilitation are not fully understood, increased capillarisation of the skeletal muscles as well as improvement in RV function as a consequence of rehabilitation have been measured in both, animal models of pulmonary hypertension and PAH patients [197, 198]. Although exercise physiology is slightly different in CTEPH in comparison to PAH [199], it is reasonable to believe that the positive effects of rehabilitation are similar for both conditions. Indeed, in the first randomised large trials showing the beneficial effects of rehabilitation, PAH and inoperable CTEPH patients were grouped together [196, 197].

10.2. Is rehabilitation safe in CTEPH?

In a further study, Nagel et al. showed that rehabilitation was effective and safe in a group consisting of inoperable CTEPH patients [200].

10.3 What are the requirements for rehabilitation in CTEPH?

Most of the pivotal trials on rehabilitation in CTEPH and PAH were based on in-hospital training in tertiary referral set ups. Small non-randomised studies showed that home-based rehabilitation might also be an effective and safe option [201]. However, exercise training in PH should be individually adjusted and closely supervised by both PH experts and physiatrists who are experienced in the rehabilitation of severely compromised patients. Patients should be on optimised targeted treatment and in a stable clinical condition before performing a supervised rehabilitation program [1].

10.4. Is rehabilitation clinically relevant and safe in pre and post PEA and BPA?

Another potential role of rehabilitation is in the recovery phase after PEA and BPA. Until now, the potential role of rehabilitation after PEA has only been studied in a small non-randomised retrospective study [202]. Although significant changes in 6MWD were observed during the 3-month rehabilitation period, it remains unclear whether these beneficial effects were the sole consequence of rehabilitation. In a recent prospective randomised study Fukui et al. studied the impact of rehabilitation directly after BPA [203]. Although the patient number was small, results showed that the combined approach of BPA and rehabilitation program was more successful than BPA alone. Based on these studies a carefully monitored, low dose rehabilitation program after surgical or BPA of CTEPH patients might be considered standard of care.

10.5. Is there a potential role for rehabilitation in CTEPD patients without PH?

Finally, although of interest, the role of rehabilitation in symptomatic CTEPD patients has not been studied so far.

Statements

- 10.1 *Although exercise physiology is slightly different in CTEPH in comparison to pulmonary arterial hypertension (PAH), it is reasonable to believe that the positive effects of rehabilitation are similar for both conditions.*
- 10.2 *Rehabilitation seems effective and safe in inoperable CTEPH patients.*
- 10.3 *Although most of the pivotal trials on rehabilitation in CTEPH and PAH were based on in-hospital training in tertiary referral set-ups, small non-randomised studies showed that home-based rehabilitation might also be an effective and safe option.*

10.4 *A carefully monitored, low dose rehabilitation program of CTEPH patients after PEA or BPA might be considered standard of care.*

Proposal for future research in CTEPH rehabilitation

- t) Larger scaled RCTs are needed to define the optimal training methodology and point in time (e.g. time after PEA) of exercise training in CTEPH*
 - u) Studies on mechanisms of action of exercise training after PEA are needed*
-

11. Global research lines

11.1. Biobank and basic science

Studies investigating the underlying molecular and genetic alterations responsible or contributing to the development of CTEPH are sparse, have included small numbers of patients, and mostly lack the inclusion of independent validation cohorts [204]. In rare conditions such as CTEPH, new genetic insights and basic science progress can be achieved only by international collaboration and establishing biobanks/biorepositories allowing researchers access to data representing a large number of patients. Currently there is no established international CTEPH biobank, however CTEPH patients have been included into PH projects such as PVDOMICS [205]. International collaborations/biobanks between PAH centres which have been successful in establishing genetic insight into PAH have been extended looking into CTEPH through GWAS and circulating -omics studies [206].

Treatment with PEA/BPA offers a unique opportunity to study the reversibility of disease-associated phenotypes. Changes in metabolic and proteomic profiles in response to PEA/BPA, improvement in pulmonary haemodynamics, linking with clinical outcomes and therefore tracking -omic changes in response to therapeutic interventions could be a valuable outcome measure. Integration of clinical and -omic measurements and examining for clusters that identify subgroups of CTEPH may identify clinically valuable diagnostic signatures [207].

11.2. Paediatric CTEPH

While CTEPH is a rare disease in adults, it is quite exceptional in the paediatric population. There are very little data published on chronic thromboembolism and only few case reports/series with CTEPH [208-210]. This important knowledge gap should be addressed by international prospective registries.

Statements

- 11.1 *To achieve new genetic insights and basic science progress, international collaboration through biobanking should be established to allow researchers access to the data which represents a large number of patients. Integration of clinical and -omic measurements will identify clinically valuable diagnostic signatures and pathways for potential future interventions.*
- 11.2 *There is a need to address CTEPH in paediatric patients by a prospective global registry.*

Acknowledgements

We thank Thomy Tonia, ERS Senior Methodologist, for her methodological overview and Valérie Vaccaro, ERS Scientific Activities Project Lead, for organizing the task force meetings.

With thanks to Patrick Corkery, PHA Ireland and Gergely Meszaros, PHA Europe who provided input on patient views and preferences via teleconferences, attendance at face to face meetings, and in writing. Mr Corkery and Mr. Meszaros contributed to formulating and prioritising the key questions, identifying aspects important to patients, and in reviewing the final manuscript. Patrick Corkery underwent PEA surgery in Royal Papworth Hospital in January 2016, recovered and swam the English Channel in September 2017.

Travel support was provided by the International CTEPH Association (ICA) for its board members: M. Delcroix, E. Fadel, D. Jenkins, N. Kim, I. Lang, M. Madani, E. Mayer, H. Matsubara, J. Pepke-Zaba, and G. Simonneau.

MH was supported by the Agence Nationale de la Recherche (18-RHUS-0006).

References

1. Galiè N, Humbert M, Vachiéry J-L, Gibbs S, Lang I, Torbicki A, Simonneau G, Peacock A, Vonk-Noordegraaf A, Beghetti M, Ghofrani A, Gomez-Sanchez MA, Hansmann G, Klepetko W, Lancellotti P, Matucci M, McDonagh T, Pierard LA, Trindade PT, Zompatori M, Hoeper MM. 2015 ESC/ERS Guidelines for the diagnosis and treatment of pulmonary hypertension: The Joint Task Force for the Diagnosis and Treatment of Pulmonary Hypertension of the European Society of Cardiology (ESC) and the European Respiratory Society (ERS): Endorsed by: Association for European Paediatric and Congenital Cardiology (AEPC), International Society for Heart and Lung Transplantation (ISHLT). *Eur Respir J* 2015; 46: 903–975.
2. Taboada D, Pepke-Zaba J, Jenkins DP, Berman M, Treacy CM, Cannon JE, Toshner M, Dunning JJ, Ng C, Tsui SS, Sheares KK. Outcome of pulmonary endarterectomy in symptomatic chronic thromboembolic disease. *Eur Respir J* 2014; 44: 1635–1645.
3. de Perrot M, Mayer E. Chronic thromboembolic pulmonary hypertension: do we need a new definition? *Eur Respir J* 2014; 44: 1401–1403.
4. Simonneau G, Montani D, Celermajer DS, Denton CP, Gatzoulis MA, Krowka M, Williams PG, Souza R. Haemodynamic definitions and updated clinical classification of pulmonary hypertension. *Eur Respir J* 2019; 53: 1801913.
5. van Kan C, van der Plas MN, Reesink HJ, van Steenwijk RP, Kloek JJ, Tepaske R, Bonta PI, Bresser P. Hemodynamic and ventilatory responses during exercise in chronic thromboembolic disease. *J Thorac Cardiovasc Surg* 2016; 152: 763–771.
6. Held M, Kolb P, Grün M, Jany B, Hübner G, Grgic A, Holl R, Schaefers H-J, Wilkens H. Functional Characterization of Patients with Chronic Thromboembolic Disease. *Respiration* 2016; 91: 503–509.
7. Claeys M, Claessen G, La Gerche A, Petit T, Belge C, Meyns B, Bogaert J, Willems R, Claus P, Delcroix M. Impaired Cardiac Reserve and Abnormal Vascular Load Limit Exercise Capacity in Chronic Thromboembolic Disease. *JACC Cardiovasc Imaging* 2019; 12: 1444–1456.
8. Guth S, Wiedenroth CB, Rieth A, Richter MJ, Gruenig E, Ghofrani HA, Arlt M, Liebetrau C, Prüfer D, Rolf A, Hamm CW, Mayer E. Exercise right heart catheterisation before and after pulmonary endarterectomy in patients with chronic thromboembolic disease. *Eur Respir J* 2018; 52: 1800458.
9. Swietlik EM, Ruggiero A, Fletcher AJ, Taboada D, Knightbridge E, Harlow L, Harvey I, Screatton N, Cannon JE, Sheares KKK, Ng C, Jenkins DP, Pepke-Zaba J, Toshner MR. Limitations of resting haemodynamics in chronic thromboembolic disease without pulmonary hypertension. *Eur Respir J* 2019; 53: 1801787.
10. Kovacs G, Herve P, Barbera JA, Chaouat A, Chemla D, Condliffe R, Garcia G, Grünig E, Howard L, Humbert M, Lau E, Laveneziana P, Lewis GD, Naeije R, Peacock A, Rosenkranz S, Saggat R, Ulrich S, Vizza D, Vonk-Noordegraaf A, Olschewski H. An official European Respiratory Society statement: pulmonary haemodynamics during exercise. *Eur Respir J* 2017; 50: 1700578.
11. Schwaiblmair M, Faul C, Scheidt von W, Berghaus TM. Detection of exercise-induced pulmonary arterial hypertension by cardiopulmonary exercise testing. *Clin Cardiol* 2012; 35: 548–553.

12. Held M, Grün M, Holl R, Hübner G, Kaiser R, Karl S, Kolb M, Schäfers H-J, Wilkens H, Jany B. Cardiopulmonary exercise testing to detect chronic thromboembolic pulmonary hypertension in patients with normal echocardiography. *Respiration* 2014; 87: 379–387.
13. Quezada CA, Jimenez D. Cardiopulmonary exercise testing with ventilatory gas analysis for evaluation of chronic thromboembolic pulmonary hypertension: Unmasking its role after a therapeutic intervention. *Int J Cardiol* 2019; 296: 155–156.
14. Weatherald J, Farina S, Bruno N, Laveneziana P. Cardiopulmonary Exercise Testing in Pulmonary Hypertension. *Annals ATS* 2017; 14: S84–S92.
15. Zhao Q-H, Wang L, Pudasaini B, Jiang R, Yuan P, Gong S-G, Guo J, Xiao Q, Liu H, Wu C, Jing Z-C, Liu J-M. Cardiopulmonary exercise testing improves diagnostic specificity in patients with echocardiography-suspected pulmonary hypertension. *Clin Cardiol* 2017; 40: 95–101.
16. Pinkstaff SO, Burger CD, Daugherty J, Bond S, Arena R. Cardiopulmonary exercise testing in patients with pulmonary hypertension: clinical recommendations based on a review of the evidence. *Expert Rev Respir Med* 2016; 10: 279–295.
17. Boulate D, Perros F, Dorfmueller P, Arthur-Ataam J, Guihaire J, Lamrani L, Decante B, Humbert M, Eddahibi S, Darteville P, Fadel E, Mercier O. Pulmonary microvascular lesions regress in reperfused chronic thromboembolic pulmonary hypertension. *J Heart Lung Transplant* 2015; 34: 457–467.
18. Dorfmueller P, Günther S, Ghigna M-R, Thomas de Montpréville V, Boulate D, Paul J-F, Jais X, Decante B, Simonneau G, Darteville P, Humbert M, Fadel E, Mercier O. Microvascular disease in chronic thromboembolic pulmonary hypertension: a role for pulmonary veins and systemic vasculature. *Eur Respir J* 2014; 44: 1275–1288.
19. Simanek M, Koranda P. The benefit of personalized hybrid SPECT/CT pulmonary imaging. *Am J Nucl Med Mol Imaging* 2016; 6: 215–222.
20. Kim NH, Delcroix M, Jais X, Madani MM, Matsubara H, Mayer E, Ogo T, Tapson VF, Ghofrani HA, Jenkins DP. Chronic thromboembolic pulmonary hypertension. *Eur Respir J* 2019; 53: 1801915.
21. Kan Y, Yuan L, Meeks JK, Li C, Liu W, Yang J. The accuracy of V/Q SPECT in the diagnosis of pulmonary embolism: a meta-analysis. *Acta Radiol* 2015; 56: 565–572.
22. Phillips JJ, Straiton J, Staff RT. Planar and SPECT ventilation/perfusion imaging and computed tomography for the diagnosis of pulmonary embolism: A systematic review and meta-analysis of the literature, and cost and dose comparison. *Eur J Radiol* 2015; 84: 1392–1400.
23. Hess S, Frary E, Gerke O, Madsen P. State-of-the-Art Imaging in Pulmonary Embolism: Ventilation/Perfusion Single-Photon Emission Computed Tomography versus Computed Tomography Angiography — Controversies, Results, and Recommendations from a Systematic Review. *Semin Thromb Hemost* 2016; 42: 833–845.
24. Soler X, Hoh CK, Test VJ, Kerr KM, Marsh JJ, Morris TA. Single photon emission computed tomography in chronic thromboembolic pulmonary hypertension. *Respirology* 2011; 16: 131–137.

25. Derlin T, Kelting C, Hueper K, Weiberg D, Meyer K, Olsson KM, Thackeray JT, Welte T, Bengel FM, Hoepfer MM. Quantitation of Perfused Lung Volume Using Hybrid SPECT/CT Allows Refining the Assessment of Lung Perfusion and Estimating Disease Extent in Chronic Thromboembolic Pulmonary Hypertension. *Clin Nucl Med* 2018; 43: e170–e177.
26. Roach PJ, Bailey DL, Schembri GP, Thomas PA. Transition from Planar to SPECT V/Q Scintigraphy: Rationale, Practicalities, and Challenges. *Semin Nucl Med* 2010; 40: 397–407.
27. Bajc M, Neilly JB, Miniati M, Schuemichen C, Meignan M, Jonson B, EANM Committee. EANM guidelines for ventilation/perfusion scintigraphy: Part 1. Pulmonary imaging with ventilation/perfusion single photon emission tomography. *Eur J Nucl Med Mol Imaging* 2009; 36: 1356–1370.
28. Fuld MK, Halaweish AF, Haynes SE, Divekar AA, Guo J, Hoffman EA. Pulmonary Perfused Blood Volume with Dual-Energy CT as Surrogate for Pulmonary Perfusion Assessed with Dynamic Multidetector CT. *Radiology* 2013; 267: 747–756.
29. Giordano J, Khung S, Duhamel A, Hossein-Foucher C, Bellèvre D, Lamblin N, Remy J, Remy-Jardin M. Lung perfusion characteristics in pulmonary arterial hypertension (PAH) and peripheral forms of chronic thromboembolic pulmonary hypertension (pCTEPH): Dual-energy CT experience in 31 patients. *Eur Radiol* 2016; 27: 1631–1639.
30. Kim S-S, Hur J, Kim YJ, Lee H-J, Hong YJ, Choi BW. Dual-energy CT for differentiating acute and chronic pulmonary thromboembolism: an initial experience. *Int J Cardiovasc Imaging* 2014; 30: 113–120.
31. Le Faivre J, Duhamel A, Khung S, Faivre J-B, Lamblin N, Remy J, Remy-Jardin M. Impact of CT perfusion imaging on the assessment of peripheral chronic pulmonary thromboembolism: clinical experience in 62 patients. *Eur Radiol* 2016; 26: 4011–4020.
32. Takagi H, Ota H, Sugimura K, Otani K, Tominaga J, Aoki T, Tatebe S, Miura M, Yamamoto S, Sato H, Yaoita N, Suzuki H, Shimokawa H, Takase K. Dual-energy CT to estimate clinical severity of chronic thromboembolic pulmonary hypertension: Comparison with invasive right heart catheterization. *Eur J Radiol* 2016; 85: 1574–1580.
33. Meinel F, Graef A, Thierfelder K, Armbruster M, Schild C, Neurohr C, Reiser M, Johnson T. Automated Quantification of Pulmonary Perfused Blood Volume by Dual-Energy CTPA in Chronic Thromboembolic Pulmonary Hypertension. *Fortschr Röntgenstr* 2014; 186: 151–156.
34. Renapurkar RD, Bolen MA, Shrikanthan S, Bullen J, Karim W, Primak A, Heresi GA. Comparative assessment of qualitative and quantitative perfusion with dual-energy CT and planar and SPECT-CT V/Q scanning in patients with chronic thromboembolic pulmonary hypertension. *Cardiovasc. Diagn. Ther.* 2018; 8: 414–422.
35. Nakazawa T, Watanabe Y, Hori Y, Kiso K, Higashi M, Itoh T, Naito H. Lung Perfused Blood Volume Images With Dual-Energy Computed Tomography for Chronic Thromboembolic Pulmonary Hypertension. *J Comput Assist Tomogr* 2011; 35: 590–595.

36. Masy M, Giordano J, Petyt G, Hossein-Foucher C, Duhamel A, Kyheng M, de Groote P, Fertin M, Lamblin N, Bervar JF, Remy J, Remy-Jardin M. Dual-energy CT (DECT) lung perfusion in pulmonary hypertension: concordance rate with V/Q scintigraphy in diagnosing chronic thromboembolic pulmonary hypertension (CTEPH). *Eur Radiol* 2018; 28: 5100–5110.
37. Dournes G, Verdier D, Montaudon M, Bullier E, Rivière A, Dromer C, Picard F, Billes M-A, Corneloup O, Laurent F, Lederlin M. Dual-energy CT perfusion and angiography in chronic thromboembolic pulmonary hypertension: diagnostic accuracy and concordance with radionuclide scintigraphy. *Eur Radiol* 2014; 24: 42–51.
38. Johns CS, Swift AJ, Rajaram S, Hughes PJC, Capener DJ, Kiely DG, Wild JM. Lung perfusion: MRI vs. SPECT for screening in suspected chronic thromboembolic pulmonary hypertension. *J Magn Reson Imaging* 2017; 46: 1693–1697.
39. Rajaram S, Rajaram S, Swift AJ, Swift AJ, Telfer A, Telfer A, Hurdman J, Hurdman J, Marshall H, Marshall H, Lorenz E, Lorenz E, Capener D, Capener D, Davies C, Davies C, Hill C, Hill C, Elliot C, Elliot C, Condliffe R, Condliffe R, Wild JM, Wild JM, Kiely DG. 3D contrast-enhanced lung perfusion MRI is an effective screening tool for chronic thromboembolic pulmonary hypertension: results from the ASPIRE Registry. *Thorax* 2013.
40. He J, Fang W, Lv B, He J-G, Xiong C-M, Liu Z-H, He Z-X. Diagnosis of chronic thromboembolic pulmonary hypertension. *Nucl Med Commun* 2012; 33: 459–463.
41. Rogberg AN, Gopalan D, Westerlund E, Lindholm P. Do radiologists detect chronic thromboembolic disease on computed tomography? *Acta Radiol* 2019; 60: 1576–1583.
42. Dong C, Zhou M, Liu D, Long X, Guo T, Kong X. Diagnostic accuracy of computed tomography for chronic thromboembolic pulmonary hypertension: a systematic review and meta-analysis. *PLoS ONE* 2015; 10: e0126985.
43. Hinrichs J, Werncke T, Kaireit T, Hoepfer MM, Olsson K, Kamp J-C, Wacker F, Bengel F, Falck von C, Schatka I, Meyer B. C-Arm Computed Tomography Adds Diagnostic Information in Patients with Chronic Thromboembolic Pulmonary Hypertension and a Positive V/Q SPECT. *Fortschr Röntgenstr* 2016; 189: 49–56.
44. Hinrichs JB, Falck von C, Hoepfer MM, Olsson KM, Wacker FK, Meyer BC, Renne J. Pulmonary Artery Imaging in Patients with Chronic Thromboembolic Pulmonary Hypertension: Comparison of Cone-Beam CT and 64-Row Multidetector CT. *J Vasc Interv Radiol* 2016; 27: 361–368.e362.
45. Fukuda T, Ogo T, Nakanishi N, Ueda J, Sanda Y, Morita Y, Sugiyama M, Fukui S, Tsuji A, Naito H. Evaluation of organized thrombus in distal pulmonary arteries in patients with chronic thromboembolic pulmonary hypertension using cone-beam computed tomography. *Jpn J Radiol* 2016; 34: 423–431.
46. Sugiyama M, Fukuda T, Sanda Y, Morita Y, Higashi M, Ogo T, Tsuji A, Demachi J, Nakanishi N, Naito H. Organized thrombus in pulmonary arteries in patients with chronic thromboembolic pulmonary hypertension; imaging with cone beam computed tomography. *Jpn J Radiol* 2014.
47. Hinrichs JB, Renne J, Hoepfer MM, Olsson KM, Wacker FK, Meyer BC. Balloon pulmonary angioplasty: applicability of C-Arm CT for procedure guidance. *Eur Radiol* 2016; 26: 4064–4071.

48. Ogo T, Fukuda T, Tsuji A, Fukui S, Ueda J, Sanda Y, Morita Y, Asano R, Konagai N, Yasuda S. Efficacy and safety of balloon pulmonary angioplasty for chronic thromboembolic pulmonary hypertension guided by cone-beam computed tomography and electrocardiogram-gated area detector computed tomography. *Eur J Radiol* 2017; 89: 270–276.
49. Maschke SK, Hinrichs JB, Renne J, Werncke T, Winther HMB, Ringe KI, Olsson KM, Hoepfer MM, Wacker FK, Meyer BC. C-Arm computed tomography (CACT)-guided balloon pulmonary angioplasty (BPA): Evaluation of patient safety and peri- and post-procedural complications. *Eur Radiol* 2018; 29: 1276–1284.
50. Ley S, Ley-Zaporozhan J, Pitton MB, Schneider J, Wirth GM, Mayer E, Düber C, Kreitner K-F. Diagnostic performance of state-of-the-art imaging techniques for morphological assessment of vascular abnormalities in patients with chronic thromboembolic pulmonary hypertension (CTEPH). *Eur Radiol* 2012; 22: 607–616.
51. Rajaram S, Swift AJ, Capener D, Telfer A, Davies C, Hill C, Condliffe R, Elliot C, Hurdman J, Wild JM. Diagnostic accuracy of contrast-enhanced MR angiography and unenhanced proton MR imaging compared with CT pulmonary angiography in chronic thromboembolic pulmonary hypertension. *Eur Radiol* 2012; 22: 310–317.
52. Grothues F, Moon JC, Bellenger NG, Smith GS, Klein HU, Pennell DJ. Interstudy reproducibility of right ventricular volumes, function, and mass with cardiovascular magnetic resonance. *Am Heart J* 2004; 147: 218–223.
53. Kreitner K-FJ, Ley S, Kauczor H-U, Mayer E, Kramm T, Pitton MB, Krummenauer F, Thelen M. Chronic Thromboembolic Pulmonary Hypertension: Pre- and Postoperative Assessment with Breath-hold MR Imaging Techniques¹. *Radiology* 2004; 232: 535–543.
54. Mauritz GJ, Vonk-Noordegraaf A, Kind T. Pulmonary endarterectomy normalizes interventricular dyssynchrony and right ventricular systolic wall stress. *J Cardiovasc Magn Reson* 2012; 14: 5.
55. Berman M, Gopalan D, Sharples L, Screatton N, Maccan C, Sheares K, Pepke-Zaba J, Dunning J, Tsui S, Jenkins DP. Right Ventricular Reverse Remodeling after Pulmonary Endarterectomy: Magnetic Resonance Imaging and Clinical and Right Heart Catheterization Assessment. *Pulm Circ* 2014; 4: 36–44.
56. Fukui S, Ogo T, Morita Y, Tsuji A, Tateishi E, Ozaki K, Sanda Y, Fukuda T, Yasuda S, Ogawa H, Nakanishi N. Right ventricular reverse remodelling after balloon pulmonary angioplasty. *Eur Respir J* 2014; 43: 1394–1402.
57. Roller FC, Wiedenroth C, Breithecker A, Liebetrau C, Mayer E, Schneider C, Rolf A, Hamm C, Krombach GA. Native T1 mapping and extracellular volume fraction measurement for assessment of right ventricular insertion point and septal fibrosis in chronic thromboembolic pulmonary hypertension. *Eur Radiol* 2017; 27: 1980–1991.
58. Roeleveld RJ, Marcus JT, Faes TJC, Gan T-J, Boonstra A, Postmus PE, Vonk-Noordegraaf A. Interventricular Septal Configuration at MR Imaging and Pulmonary Arterial Pressure in Pulmonary Hypertension¹. *Radiology* 2005; 234: 710–717.
59. Sanz J, Kuschnir P, Rius T, Salguero R, Sulica R, Einstein AJ, Dellegrottaglie S, Fuster V, Rajagopalan S, Poon M. Pulmonary arterial hypertension: noninvasive detection with phase-contrast MR imaging. *Radiology* 2007; 243: 70–79.

60. Kreitner K-F, Wirth GM, Krummenauer F, Weber S, Pitton MB, Schneider J, Mayer E, Dueber C. Non-invasive Assessment of Pulmonary Hemodynamics in Patients with Chronic Thromboembolic Pulmonary Hypertension (CTEPH) by High Temporal Resolution Phase-contrast MR Imaging: Correlation with Simultaneous Invasive Pressure Recordings. *Circ Cardiovasc Imaging* 2013.
61. García-Alvarez A, Fernández-Friera L, Mirelis JG, Sawit S, Nair A, Kallman J, Fuster V, Sanz J. Non-invasive estimation of pulmonary vascular resistance with cardiac magnetic resonance. *Eur Heart J* 2011; 32: 2438–2445.
62. Reiter G, Reiter U, Kovacs G, Olschewski H, Fuchsjäger M. Blood Flow Vortices along the Main Pulmonary Artery Measured with MR Imaging for Diagnosis of Pulmonary Hypertension. *Radiology* 2015; 275: 71–79.
63. Reiter G, Reiter U, Kovacs G, Kainz B, Schmidt K, Maier R, Olschewski H, Rienmueller R. Magnetic Resonance–Derived 3-Dimensional Blood Flow Patterns in the Main Pulmonary Artery as a Marker of Pulmonary Hypertension and a Measure of Elevated Mean Pulmonary Arterial Pressure. *Circ Cardiovasc Imaging* 2008; 1: 23–30.
64. Delcroix M, Kerr K, Fedullo P. Chronic Thromboembolic Pulmonary Hypertension. Epidemiology and Risk Factors. *Annals ATS* 2016; 13 Suppl 3: S201–S206.
65. Escribano-Subias P, Blanco I, López-Meseguer M, Lopez-Guarch CJ, Roman A, Morales P, Castillo-Palma MJ, Segovia J, Gómez-Sanchez MA, Barberà JA, REHAP investigators. Survival in pulmonary hypertension in Spain: insights from the Spanish registry. *Eur Respir J* 2012; 40: 596–603.
66. Gibbs S. National Audit of Pulmonary Hypertension, Great Britain, 2018-19 [Internet]. 2019 [cited 2020 Feb 24]. p. 1–102 Available from: <https://digital.nhs.uk/data-and-information/publications/statistical/national-pulmonary-hypertension-audit/2019>.
67. Gall H, Hoepfer MM, Richter MJ, Cacheris W, Hinzmann B, Mayer E. An epidemiological analysis of the burden of chronic thromboembolic pulmonary hypertension in the USA, Europe and Japan. *Eur Respir Rev* 2017; 26: 160121.
68. Cottin V, Avot D, Lévy-Bachelot L, Baxter CA, Ramey DR, Catella L, Bénard S, Sitbon O, Teal S. Identifying chronic thromboembolic pulmonary hypertension through the French national hospital discharge database. *PLoS ONE* 2019; 14: e0214649.
69. Moser KM, Auger WR, Fedullo PF, Jamieson SW. Chronic thromboembolic pulmonary hypertension: clinical picture and surgical treatment. *Eur Respir J* 1992; 5: 334–342.
70. Pepke-Zaba J, Delcroix M, Lang I, Mayer E, Jansa P, Ambroz D, Treacy C, D'Armini AM, Morsolini M, Snijder R, Bresser P, Torbicki A, Kristensen B, Lewczuk J, Simkova I, Barberà JA, de Perrot M, Hoepfer MM, Gaine S, Speich R, Gómez-Sánchez MA, Kovacs G, Hamid AM, Jais X, Simonneau G. Chronic thromboembolic pulmonary hypertension (CTEPH): results from an international prospective registry. *Circulation* 2011; 124: 1973–1981.
71. Lang IM, Madani M. Update on chronic thromboembolic pulmonary hypertension. *Circulation* 2014; 130: 508–518.
72. Ogawa A, Satoh T, Fukuda T, Sugimura K, Fukumoto Y, Emoto N, Yamada N, Yao A, Ando M, Ogino H, Tanabe N, Tsujino I, Hanaoka M, Minatoya K, Ito H, Matsubara H. Balloon Pulmonary Angioplasty for Chronic Thromboembolic Pulmonary

Hypertension: Results of a Multicenter Registry. *Circ Cardiovasc Qual Outcomes* 2017; 10: e004029.

73. Chausheva S, Naito A, Ogawa A, Seidl V, Winter M-P, Sharma S, Sadushi-Koliçi R, Campean I-A, Taghavi S, Moser B, Klepetko W, Ishida K, Matsubara H, Sakao S, Lang IM. Chronic thromboembolic pulmonary hypertension in Austria and Japan. *J Thorac Cardiovasc Surg* 2019; 158: 604–614.e2.
74. Pengo V, Lensing AWA, Prins MH, Marchiori A, Davidson BL, Tiozzo F, Albanese P, Biasiolo A, Pegoraro C, Iliceto S, Prandoni P, Thromboembolic Pulmonary Hypertension Study Group. Incidence of chronic thromboembolic pulmonary hypertension after pulmonary embolism. *N Engl J Med* 2004; 350: 2257–2264.
75. Golpe R, Pérez-de-Llano LA, Castro-Añón O, Vázquez-Caruncho M, González-Juanatey C, Veres-Racamonde A, Iglesias-Moreira C, Fariñas MC. Right ventricle dysfunction and pulmonary hypertension in hemodynamically stable pulmonary embolism. *Respir Med* 2010; 104: 1370–1376.
76. Guerin L, Couturaud F, Parent F, Revel M-P, Gillaizeau F, Planquette B, Pontal D, Guegan M, Simonneau G, Meyer G, Sanchez O. Prevalence of chronic thromboembolic pulmonary hypertension after acute pulmonary embolism. Prevalence of CTEPH after pulmonary embolism. *Thromb Haemost* 2014; 112: 598–605.
77. Simonneau G, Hoeper MM. Evaluation of the incidence of rare diseases: difficulties and uncertainties, the example of chronic thromboembolic pulmonary hypertension. *Eur Respir J* 2017; 49.
78. Ende-Verhaar YM, Cannegieter SC, Vonk-Noordegraaf A, Delcroix M, Pruszczyk P, Mairuhu ATA, Huisman MV, Klok FA. Incidence of chronic thromboembolic pulmonary hypertension after acute pulmonary embolism: a contemporary view of the published literature. *Eur Respir J* 2017; 49: 1601792.
79. Coquoz N, Weilenmann D, Stolz D, Popov V, Azzola A, Fellrath J-M, Stricker H, Pagnamenta A, Ott S, Ulrich S, Györik S, Pasquier J, Aubert J-D. Multicentre observational screening survey for the detection of CTEPH following pulmonary embolism. *Eur Respir J* 2018; 51: 1702505.
80. Wartski M, Collignon M-A. Incomplete recovery of lung perfusion after 3 months in patients with acute pulmonary embolism treated with antithrombotic agents. THESEE Study Group. Tinzaparin ou Heparin Standard: Evaluation dans l'Embolie Pulmonaire Study. *J Nucl Med* 2000; 41: 1043–1048.
81. Nijkeuter M, Hovens MMC, Davidson BL, Huisman MV. Resolution of thromboemboli in patients with acute pulmonary embolism: a systematic review. *Chest* 2006; 129: 192–197.
82. Sanchez O, Helley D, Couchon S, Roux A, Delaval A, Trinquart L, Collignon M-A, Fischer A-M, Meyer G. Perfusion defects after pulmonary embolism: risk factors and clinical significance. *J Thromb Haemost* 2010; 8: 1248–1255.
83. Meneveau N, Ider O, Seronde M-F, Chopard R, Davani S, Bernard Y, Schiele F. Long-term prognostic value of residual pulmonary vascular obstruction at discharge in patients with intermediate- to high-risk pulmonary embolism. *Eur Heart J* 2013; 34: 693–701.

84. Ma KA, Kahn SR, Akaberi A, Dennie C, Rush C, Granton JT, Anderson D, Wells PS, Rodger MA, Solymoss S, Kovacs MJ, Rudski L, Shimony A, Hernandez P, Aaron SD, Pena E, Abikhzer G, Hirsch AM, ELOPE Study group. Serial imaging after pulmonary embolism and correlation with functional limitation at 12 months: Results of the ELOPE Study. *Res Pract Thromb Haemost* 2018; 2: 670–677.
85. Riedel M, Stanek V, Widimsky J, Prerovsky I. Longterm follow-up of patients with pulmonary thromboembolism. Late prognosis and evolution of hemodynamic and respiratory data. *Chest* 1982; 81: 151–158.
86. Lewczuk J, Piszko P, Jagas J, Porada A, Wójciak S, Sobkowicz B, Wrabec K. Prognostic factors in medically treated patients with chronic pulmonary embolism. *Chest* 2001; 119: 818–823.
87. Prandoni P, Ageno W, Mumoli N, Zanatta N, Imberti D, Visonà A, Ciammaichella M, Simioni L, Cappelli R, Bucherini E, Di Nisio M, Avruscio G, Camporese G, Parisi R, Cuppini S, Turatti G, Noventa F, Sarolo L. Recanalization rate in patients with proximal vein thrombosis treated with the direct oral anticoagulants. *Thromb Res* 2017; 153: 97–100.
88. Piazza G, Mani V, Goldhaber SZ, Grosso MA, Mercuri M, Lanz HJ, Schussler S, Hsu C, Chinigo A, Ritchie B, Nadar V, Cannon K, Pullman J, Concha M, Schul M, Fayad ZA, edoxaban Thrombus Reduction Imaging Study (eTRIS) Investigators. Magnetic resonance venography to assess thrombus resolution with edoxaban monotherapy versus parenteral anticoagulation/warfarin for symptomatic deep vein thrombosis: A multicenter feasibility study. *Vasc Med* 2016; 21: 361–368.
89. Bunclark K, Newnham M, Chiu Y-D, Ruggiero A, Villar SS, Cannon JE, Coghlan G, Corris PA, Howard L, Jenkins D, Johnson M, Kiely DG, Ng C, Screatton N, Sheares K, Taboada D, Tsui S, Wort SJ, Pepke-Zaba J, Toshner M. A multicenter study of anticoagulation in operable chronic thromboembolic pulmonary hypertension. *J Thromb Haemost* 2020; 18: 114–122.
90. Houghton DE, Lekah A, Macedo TA, Hodge D, Saadiq RA, Little Y, Casanegra AI, McBane RD, Wysokinski WE. Resolution of acute lower extremity deep vein thrombosis with rivaroxaban compared to warfarin. *J. Thromb Thrombolysis* 2020; 49: 199–205.
91. Konstantinides SV, Meyer G, Becattini C, Bueno H, Geersing G-J, Harjola V-P, Huisman MV, Humbert M, Jennings CS, Jimenez D, Kucher N, Lang IM, Lankeit M, Lorusso R, Mazzolai L, Meneveau N, Áinle FN, Prandoni P, Pruszczyk P, Righini M, Torbicki A, Van Belle E, Zamorano JL, The Task Force for the diagnosis and management of acute pulmonary embolism of the European Society of Cardiology (ESC). 2019 ESC Guidelines for the diagnosis and management of acute pulmonary embolism developed in collaboration with the European Respiratory Society (ERS): The Task Force for the diagnosis and management of acute pulmonary embolism of the European Society of Cardiology (ESC). *Eur Respir J* 2019; 54.
92. Konstantinides SV, Meyer G, Becattini C, Bueno H, Geersing G-J, Harjola V-P, Huisman MV, Humbert M, Jennings CS, Jimenez D, Kucher N, Lang IM, Lankeit M, Lorusso R, Mazzolai L, Meneveau N, Ní Áinle F, Prandoni P, Pruszczyk P, Righini M, Torbicki A, Van Belle E, Zamorano JL, ESC Scientific Document Group. 2019 ESC Guidelines for the diagnosis and management of acute pulmonary embolism developed in collaboration with the European Respiratory Society (ERS). *Eur Heart J* 2020; 41: 543–603.

93. Pengo V, Denas G, Zoppellaro G, Jose SP, Hoxha A, Ruffatti A, Andreoli L, Tincani A, Cenci C, Prisco D, Fierro T, Gresele P, Cafolla A, De Micheli V, Ghirarduzzi A, Tosetto A, Falanga A, Martinelli I, Testa S, Barcellona D, Gerosa M, Banzato A. Rivaroxaban vs warfarin in high-risk patients with antiphospholipid syndrome. *Blood* 2018; 132: 1365–1371.
94. Moll S, Crona DJ, Martin K. Direct oral anticoagulants in extremely obese patients: OK to use? *Res Pract Thromb Haemost* 2019; 3: 152–155.
95. Ingrasciotta Y, Crisafulli S, Pizzimenti V, Marcianò I, Mancuso A, Andò G, Corrao S, Capranzano P, Trifirò G. Pharmacokinetics of new oral anticoagulants: implications for use in routine care. *Expert Opin. Drug Metab. Toxicol.* 2018; 14: 1057–1069.
96. Bonderman D, Jakowitsch J, Adlbrecht C, Schemper M, Kyrle PA, Schönauer V, Exner M, Klepetko W, Kneussl MP, Maurer G, Lang I. Medical conditions increasing the risk of chronic thromboembolic pulmonary hypertension. *Thromb Haemost* 2005; 93: 512–516.
97. Lang I, Simonneau G, Pepke-Zaba J, Mayer E, Ambroz D, Blanco I, Torbicki A, Mellekjaer S, Yaïci A, Delcroix M. Factors associated with diagnosis and operability of chronic thromboembolic pulmonary hypertension. *Thromb Haemost* 2017; 110: 83–91.
98. Delcroix M, Lang I, Pepke-Zaba J, Jansa P, D'Armini AM, Snijder R, Bresser P, Torbicki A, Mellekjaer S, Lewczuk J, Simkova I, Barberà JA, de Perrot M, Hoepfer MM, Gaine S, Speich R, Gómez-Sánchez MA, Kovacs G, Jais X, Ambroz D, Treacy C, Morsolini M, Jenkins D, Lindner J, Darteville P, Mayer E, Simonneau G. Long-Term Outcome of Patients With Chronic Thromboembolic Pulmonary Hypertension: Results From an International Prospective Registry. *Circulation* 2016; 133: 859–871.
99. Ende-Verhaar YM, Huisman MV, Klok FA. To screen or not to screen for chronic thromboembolic pulmonary hypertension after acute pulmonary embolism. *Thromb Res* 2017; 151: 1–7.
100. Ende-Verhaar YM, van den Hout WB, Bogaard H-J, Meijboom LJ, Huisman MV, Symersky P, Vonk-Noordegraaf A, Klok FA. Healthcare utilization in chronic thromboembolic pulmonary hypertension after acute pulmonary embolism. *J Thromb Haemost* 2018; 16: 2168–2174.
101. Klok FA, Barco S, Konstantinides SV, Darteville P, Fadel E, Jenkins D, Kim NH, Madani M, Matsubara H, Mayer E, Pepke-Zaba J, Delcroix M, Lang IM. Determinants of diagnostic delay in chronic thromboembolic pulmonary hypertension: results from the European CTEPH Registry. *Eur Respir J* 2018; 52: 1801687.
102. Jensen KW, Kerr KM, Fedullo PF, Kim NH, Test VJ, Ben-Yehuda O, Auger WR. Pulmonary hypertensive medical therapy in chronic thromboembolic pulmonary hypertension before pulmonary thromboendarterectomy. *Circulation* 2009; 120: 1248–1254.
103. Nishiyama KH, Saboo SS, Tanabe Y, Jasinowodolinski D, Landay MJ, Kay FU. Chronic pulmonary embolism: diagnosis. *Cardiovasc Diagn Ther* 2018; 8: 253–271.
104. Rajaram S, Swift AJ, Condliffe R, Johns C, Elliot CA, Hill C, Davies C, Hurdman J, Sabroe I, Wild JM, Kiely DG. CT features of pulmonary arterial hypertension and its

major subtypes: a systematic CT evaluation of 292 patients from the ASPIRE Registry. *Thorax* 2015; 70: 382–387.

105. Ende-Verhaar YM, Meijboom LJ, Kroft LJM, Beenen LFM, Boon GJAM, Middeldorp S, Nossent EJ, Symersky P, Huisman MV, Bogaard HJ, Vonk-Noordegraaf A, Klok FA. Usefulness of standard computed tomography pulmonary angiography performed for acute pulmonary embolism for identification of chronic thromboembolic pulmonary hypertension: results of the InShape III study. *J Heart Lung Transplant* 2019; 38: 731–738.
106. McIntyre KM, Sasahara AA. The hemodynamic response to pulmonary embolism in patients without prior cardiopulmonary disease. *AJC* 1971; 28: 288–294.
107. Klok FA, Delcroix M, Bogaard H-J. Chronic thromboembolic pulmonary hypertension from the perspective of patients with pulmonary embolism. *J Thromb Haemost* 2018; 16: 1040–1051.
108. Sista AK, Klok FA. Late outcomes of pulmonary embolism: The post-PE syndrome. *Thromb Res* 2018; 164: 157–162.
109. Sista AK, Miller LE, Kahn SR, Kline JA. Persistent right ventricular dysfunction, functional capacity limitation, exercise intolerance, and quality of life impairment following pulmonary embolism: Systematic review with meta-analysis. *Vasc Med* 2017; 22: 37–43.
110. Klok FA, van der Hulle T, Exter den PL, Lankeit M, Huisman MV, Konstantinides S. The post-PE syndrome: a new concept for chronic complications of pulmonary embolism. *Blood Reviews* 2014; 28: 221–226.
111. Klok FA, Dzikowska-Diduch O, Kostrubiec M, Vliegen HW, Pruszczyk P, Hasenfuss G, Huisman MV, Konstantinides S, Lankeit M. Derivation of a clinical prediction score for chronic thromboembolic pulmonary hypertension after acute pulmonary embolism. *J Thromb Haemost* 2016; 14: 121–128.
112. Wittram C. How I do it: CT pulmonary angiography. *Am J Roentgenol* 2007; 188: 1255–1261.
113. Helmersen D, Provencher S, Hirsch AM, Van Dam Anne, Dennie C, de Perrot M, Mielniczuk L, Hirani N, Chandy G, Swiston J, Lien D, Kim NH, Delcroix M, Mehta S. Diagnosis of chronic thromboembolic pulmonary hypertension: A Canadian Thoracic Society clinical practice guideline update. *Canadian Journal of Respiratory, Critical Care, and Sleep Medicine* [Internet] Taylor & Francis; 2019; 0: 1–22 Available from: <https://doi.org/10.1080/24745332.2019.1631663>.
114. Klok FA, Van Kralingen KW, Van Dijk APJ, Heyning FH, Vliegen HW, Huisman MV. Prevalence and potential determinants of exertional dyspnea after acute pulmonary embolism. *Respir Med* 2010; 104: 1744–1749.
115. Kahn SR, Akaberi A, Granton JT, Anderson DR, Wells PS, Rodger MA, Solymoss S, Kovacs MJ, Rudski L, Shimony A, Dennie C, Rush C, Hernandez P, Aaron SD, Hirsch AM. Quality of Life, Dyspnea, and Functional Exercise Capacity Following a First Episode of Pulmonary Embolism: Results of the ELOPE Cohort Study. *Am J Med* 2017; 130: 990.e9–990.e21.

116. Kahn SR, Hirsch AM, Akaberi A, Hernandez P, Anderson DR, Wells PS, Rodger MA, Solymoss S, Kovacs MJ, Rudski L, Shimony A, Dennie C, Rush C, Geerts WH, Aaron SD, Granton JT. Functional and Exercise Limitations After a First Episode of Pulmonary Embolism: Results of the ELOPE Prospective Cohort Study. *Chest* 2017; 151: 1058–1068.
117. Sznajder M, Dzikowska-Diduch O, Kurnicka K, Roik M, Wretowski D, Pruszczyk P, Kostrubiec M. Increased systemic arterial stiffness in patients with chronic thromboembolic pulmonary hypertension. *Cardiol J* 2018.
118. Pietra GG, Capron F, Stewart S, Leone O, Humbert M, Robbins IM, Reid LM, Tuder RM. Pathologic assessment of vasculopathies in pulmonary hypertension. *J Am Coll Cardiol* 2004; 43: 25S–32S.
119. Humbert M, Guignabert C, Bonnet S, Dorfmüller P, Klinger JR, Nicolls MR, Olschewski AJ, Pullamsetti SS, Schermuly RT, Stenmark KR, Rabinovitch M. Pathology and pathobiology of pulmonary hypertension: state of the art and research perspectives. *Eur Respir J* 2019; 53: 1801887.
120. Moser KM, Bloor CM. Pulmonary vascular lesions occurring in patients with chronic major vessel thromboembolic pulmonary hypertension. *Chest* 1993; 103: 685–692.
121. Gerges C, Gerges M, Friewald R, Fesler P, Dorfmüller P, Sharma S, Karlócai K, Skoro-Sajer N, Jakowitsch J, Moser B, Taghavi S, Klepetko W, Lang IM. Microvascular Disease in Chronic Thromboembolic Pulmonary Hypertension: Hemodynamic Phenotyping and Histomorphometric Assessment. *Circulation* 2020; 141: 376–386.
122. Noly P-E, Guihaire J, Coblence M, Dorfmüller P, Fadel E, Mercier O. Chronic Thromboembolic Pulmonary Hypertension and Assessment of Right Ventricular Function in the Piglet. *J Vis Exp* 2015; 105: e53133.
123. Tsai H-Y, Chin C-S, Tsai I-C. Imaging as a biomarker in Behçet disease: prognostic and therapeutic implications of serial pulmonary CT angiography. *Am J Roentgenol* 2011; 196: W105–W106.
124. Perino MG, Moldobaeva A, Jenkins J, Wagner EM. Chemokine localization in bronchial angiogenesis. *PLoS ONE* 2013; 8: e66432.
125. Mercier O, Fadel E. Chronic thromboembolic pulmonary hypertension: animal models. *Eur Respir J* 2013; 41: 1200–1206.
126. Yi ES, Kim H, Ahn H, Strother J, Morris T, Masliah E, Hansen LA, Park K, Friedman PJ. Distribution of obstructive intimal lesions and their cellular phenotypes in chronic pulmonary hypertension. A morphometric and immunohistochemical study. *Am J Respir Crit Care Med* 2000; 162: 1577–1586.
127. Galambos C, Sims-Lucas S, Abman SH, Cool CD. Intrapulmonary Bronchopulmonary Anastomoses and Plexiform Lesions in Idiopathic Pulmonary Arterial Hypertension. *Am J Respir Crit Care Med* 2016; 193: 574–576.
128. Ghigna M-R, Guignabert C, Montani D, Girerd B, Jais X, Savale L, Herve P, Thomas de Montpréville V, Mercier O, Sitbon O, Soubrier F, Fadel E, Simonneau G, Humbert M, Dorfmüller P. BMPR2 mutation status influences bronchial vascular changes in pulmonary arterial hypertension. *Eur Respir J* 2016; 48: 1668–1681.

129. Azarian R, Wartski M, Collignon MA, Parent F, Hervé P, Sors H, Simonneau G. Lung perfusion scans and hemodynamics in acute and chronic pulmonary embolism. *J Nucl Med* 1997; 38: 980–983.
130. Kim NHS, Fesler P, Channick RN, Knowlton KU, Ben-Yehuda O, Lee SH, Naeije R, Rubin LJ. Preoperative partitioning of pulmonary vascular resistance correlates with early outcome after thromboendarterectomy for chronic thromboembolic pulmonary hypertension. *Circulation* 2004; 109: 18–22.
131. Toshner M, Suntharalingam J, Fesler P, Soon E, Sheares KK, Jenkins D, White P, Morrell NW, Naeije R, Pepke-Zaba J. Occlusion pressure analysis role in partitioning of pulmonary vascular resistance in CTEPH. *Eur Respir J* 2012; 40: 612–617.
132. Simonneau G, Torbicki A, Dorfmüller P, Kim N. The pathophysiology of chronic thromboembolic pulmonary hypertension. *Eur Respir Rev* 2017; 26: 160112.
133. Ley S, Kreitner K-F, Morgenstern I, Thelen M, Kauczor H-U. Bronchopulmonary shunts in patients with chronic thromboembolic pulmonary hypertension: evaluation with helical CT and MR imaging. *Am J Roentgenol* 2002; 179: 1209–1215.
134. Miller F, Coulden RA, Sonnex E, Pepke-Zaba J, Dunning J. The Use of MR Flow Mapping in the Assessment of Pulmonary Artery Blood Flow Following Pulmonary Thrombo-Endarterectomy. *RSNA* 2003. p. 426P.
135. Reiter U, Reiter G, Kovacs G, Stalder AF, Gulsun MA, Greiser A, Olschewski H, Fuchsjäger M. Evaluation of elevated mean pulmonary arterial pressure based on magnetic resonance 4D velocity mapping: comparison of visualization techniques. *PLoS* 2013; 8: e82212.
136. Ota H, Sugimura K, Miura M, Shimokawa H. Four-dimensional flow magnetic resonance imaging visualizes drastic change in vortex flow in the main pulmonary artery after percutaneous transluminal pulmonary angioplasty in a patient with chronic thromboembolic pulmonary hypertension. *Eur Heart J* 2015; 36: 1630.
137. Polanowski T, Kurzyna M, Kuca P, Tomkowski W, Fijałkowska A, Kober J, Torbicki A. [Differences in hemodynamics of thromboembolic and primary pulmonary hypertension]. *Pol Arch Med Wewn* 2000; 104: 741–745.
138. Quarck R, Nawrot T, Meyns B, Delcroix M. C-reactive protein: a new predictor of adverse outcome in pulmonary arterial hypertension. *J Am Coll Cardiol* 2009; 53: 1211–1218.
139. Axell RG, Messer SJ, White PA, McCabe C, Priest A, Statopoulou T, Drozdzyńska M, Viscasillas J, Hinchey EC, Hampton-Till J, Alibhai HI, Morrell N, Pepke-Zaba J, Large SR, Hoole SP. Ventriculo-arterial coupling detects occult RV dysfunction in chronic thromboembolic pulmonary vascular disease. *Physiol Rep* 2017; 5: e13227.
140. MacKenzie Ross RV, Toshner MR, Soon E, Naeije R, Pepke-Zaba J. Decreased time constant of the pulmonary circulation in chronic thromboembolic pulmonary hypertension. *Am J Physiol Heart Circ Physiol* 2013; 305: H259–H264.
141. Menzel T, Wagner S, Kramm T, Mohr-Kahaly S, Mayer E, Braeuninger S, Meyer J. Pathophysiology of impaired right and left ventricular function in chronic embolic pulmonary hypertension: changes after pulmonary thromboendarterectomy. *Chest* 2000; 118: 897–903.

142. Bonderman D, Martischnig AM, Vonbank K, Nikfardjam M, Meyer B, Heinz G, Klepetko W, Naeije R, Lang IM. Right ventricular load at exercise is a cause of persistent exercise limitation in patients with normal resting pulmonary vascular resistance after pulmonary endarterectomy. *Chest* 2011; 139: 122–127.
143. Jenkins D, Madani M, Fadel E, D'Armini AM, Mayer E. Pulmonary endarterectomy in the management of chronic thromboembolic pulmonary hypertension. *Eur Respir Rev* 2017; 26: 160111.
144. Kim NH, Delcroix M, Jenkins DP, Channick R, Darteville P, Jansa P, Lang I, Madani MM, Ogino H, Pengo V, Mayer E. Chronic thromboembolic pulmonary hypertension. *J Am Coll Cardiol* 2013; 62: D92–D99.
145. Boulate D, Mercier O, Mussot S, Fabre D, Stephan F, Haddad F, Jais X, Darteville P, Fadel E. Extracorporeal Life Support After Pulmonary Endarterectomy as a Bridge to Recovery or Transplantation: Lessons From 31 Consecutive Patients. *Ann Thorac Surg* 2016; 102: 260–268.
146. Mayer E, Jenkins D, Lindner J, D'Armini A, Kloek J, Meyns B, Ilkjaer LB, Klepetko W, Delcroix M, Lang I, Pepke-Zaba J, Simonneau G, Darteville P. Surgical management and outcome of patients with chronic thromboembolic pulmonary hypertension: results from an international prospective registry. *J Thorac Cardiovasc Surg* 2011; 141: 702–710.
147. Madani M, Ogo T, Simonneau G. The changing landscape of chronic thromboembolic pulmonary hypertension management. *Eur Respir Rev* 2017; 26: 170105.
148. Kawakami T, Ogawa A, Miyaji K, Mizoguchi H, Shimokawahara H, Naito T, Oka T, Yunoki K, Munemasa M, Matsubara H. Novel Angiographic Classification of Each Vascular Lesion in Chronic Thromboembolic Pulmonary Hypertension Based on Selective Angiogram and Results of Balloon Pulmonary Angioplasty. *Circ Cardiovasc Interv* 2016; 9: e003318.
149. D'Armini AM, Morsolini M, Mattiucci G, Grazioli V, Pin M, Valentini A, Silvaggio G, Klersy C, Dore R. Pulmonary endarterectomy for distal chronic thromboembolic pulmonary hypertension. *J Thorac Cardiovasc Surg* 2014; 148: 1005–11–1012.e1–2–discussion1011–2.
150. Hsieh WC, Jansa P, Huang WC, Nižnanský M, Omara M, Lindner J. Residual pulmonary hypertension after pulmonary endarterectomy: A meta-analysis. *J Thorac Cardiovasc Surg* 2018; 156: 1275–1287.
151. Madani MM, Auger WR, Pretorius V, Sakakibara N, Kerr KM, Kim NH, Fedullo PF, Jamieson SW. Pulmonary endarterectomy: recent changes in a single institution's experience of more than 2,700 patients. *Ann Thorac Surg* 2012; 94: 97–103–discussion103.
152. Cannon JE, Su L, Kiely DG, Page K, Toshner M, Swietlik E, Treacy C, Ponnaberanam A, Condliffe R, Sheares K, Taboada D, Dunning J, Tsui S, Ng C, Gopalan D, Sreaton N, Elliot C, Gibbs S, Howard L, Corris P, Lordan J, Johnson M, Peacock A, MacKenzie Ross R, Coghlan G, Schreiber B, Dimopoulos K, Wort J, Gaine S, Moledina S, et al. Dynamic Risk Stratification of Patient Long-Term Outcome After Pulmonary Endarterectomy: Results From the UK National Cohort. *Circulation* 2016; 133: 1761–71.

153. Vuylsteke A, Sharples L, Charman G, Kneeshaw J, Tsui S, Dunning J, Wheaton E, Klein A, Arrowsmith J, Hall R, Jenkins D. Circulatory arrest versus cerebral perfusion during pulmonary endarterectomy surgery (PEACOG): a randomised controlled trial. *Lancet* 2011; 378: 1379–1387.
154. Corsico AG, D'Armini AM, Cerveri I, Klersy C, Ansaldo E, Niniano R, Gatto E, Monterosso C, Morsolini M, Nicolardi S, Tramontin C, Pozzi E, Viganò M. Long-term outcome after pulmonary endarterectomy. *Am J Respir Crit Care Med* 2008; 178: 419–424.
155. Kramm T, Eberle B, Guth S, Mayer E. Inhaled iloprost to control residual pulmonary hypertension following pulmonary endarterectomy. *Eur J Cardiothorac Surg* 2005; 28: 882–888.
156. Ghofrani HA, D'Armini AM, Grimminger F, Hoeper MM, Jansa P, Kim NH, Mayer E, Simonneau G, Wilkins MR, Fritsch A, Neuser D, Weimann G, Wang C, CHEST-1 Study Group. Riociguat for the treatment of chronic thromboembolic pulmonary hypertension. *N Engl J Med* 2013; 369: 319–329.
157. Shimura N, Kataoka M, Inami T, Yanagisawa R, Ishiguro H, Kawakami T, Higuchi Y, Ando M, Fukuda K, Yoshino H, Satoh T. Additional percutaneous transluminal pulmonary angioplasty for residual or recurrent pulmonary hypertension after pulmonary endarterectomy. *Int J Cardiol* 2015; 183: 138–142.
158. Ali JM, Dunning J, Ng C, Tsui S, Cannon JE, Sheares KK, Taboada D, Toshner M, Screatton N, Pepke-Zaba J, Jenkins DP. The outcome of reoperative pulmonary endarterectomy surgery. *Interact Cardiovasc Thorac Surg* 2018; 26: 932–937.
159. Mizoguchi H, Ogawa A, Munemasa M, Mikouchi H, Ito H, Matsubara H. Refined Balloon Pulmonary Angioplasty for Inoperable Patients with Chronic Thromboembolic Pulmonary Hypertension. *Circ Cardiovasc Interv* 2012; 5: 748–755.
160. Kataoka M, Inami T, Hayashida K, Shimura N, Ishiguro H, Abe T, Tamura Y, Ando M, Fukuda K, Yoshino H, Satoh T. Percutaneous transluminal pulmonary angioplasty for the treatment of chronic thromboembolic pulmonary hypertension. *Circ Cardiovasc Interv* 2012; 5: 756–762.
161. Sugimura K, Fukumoto Y, Satoh K, Nochioka K, Miura Y, Aoki T, Tatebe S, Miyamichi-Yamamoto S, Shimokawa H. Percutaneous transluminal pulmonary angioplasty markedly improves pulmonary hemodynamics and long-term prognosis in patients with chronic thromboembolic pulmonary hypertension. *Circ J* 2012; 76: 485–488.
162. Lang I, Meyer BC, Ogo T, Matsubara H, Kurzyna M, Ghofrani HA, Mayer E, Brenot P. Balloon pulmonary angioplasty in chronic thromboembolic pulmonary hypertension. *Eur Respir Rev* 2017; 26.
163. Wiedenroth CB, Liebetrau C, Breithecker A, Guth S, Lautze H-JF, Ortmann E, Arlt M, Krombach GA, Bandorski D, Hamm CW, Möllmann H, Mayer E. Combined pulmonary endarterectomy and balloon pulmonary angioplasty in patients with chronic thromboembolic pulmonary hypertension. *J Heart Lung Transplant* 2016; 35: 591–596.
164. Ogo T. Balloon pulmonary angioplasty for inoperable chronic thromboembolic pulmonary hypertension. *Curr Opin Pulm Med* 2015; 21: 425–431.

165. Zoppellaro G, Badawy MR, Squizzato A, Denas G, Tarantini G, Pengo V. Balloon Pulmonary Angioplasty in Patients With Chronic Thromboembolic Pulmonary Hypertension - A Systematic Review and Meta-Analysis. *Circ J* 2019; 83: 1660–1667.
166. Darocha S, Pietura R, Pietrasik A, Norwa J, Dobosiewicz A, Piłka M, Florczyk M, Biederman A, Torbicki A, Kurzyna M. Improvement in Quality of Life and Hemodynamics in Chronic Thromboembolic Pulmonary Hypertension Treated With Balloon Pulmonary Angioplasty. *Circ J* 2017; 81: 552–557.
167. Fukui S, Ogo T, Goto Y, Ueda J, Tsuji A, Sanda Y, Kumasaka R, Arakawa T, Nakanishi M, Fukuda T, Takaki H, Yasuda S, Ogawa H, Nakanishi N. Exercise intolerance and ventilatory inefficiency improve early after balloon pulmonary angioplasty in patients with inoperable chronic thromboembolic pulmonary hypertension. *Int J Cardiol* 2015; 180: 66–68.
168. Olsson KM, Wiedenroth CB, Kamp J-C, Breithecker A, Fuge J, Krombach GA, Haas M, Hamm C, Kramm T, Guth S, Ghofrani HA, Hinrichs JB, Cebotari S, Meyer K, Hoeper MM, Mayer E, Liebetau C, Meyer BC. Balloon pulmonary angioplasty for inoperable patients with chronic thromboembolic pulmonary hypertension: the initial German experience. *Eur Respir J* 2017; 49: 1602409.
169. Brenot P, Jais X, Taniguchi Y, Garcia Alonso C, Gerardin B, Mussot S, Mercier O, Fabre D, Parent F, Jevnikar M, Montani D, Savale L, Sitbon O, Fadel E, Humbert M, Simonneau G. French experience of balloon pulmonary angioplasty for chronic thromboembolic pulmonary hypertension. *Eur Respir J* 2019; 53: 1802095.
170. Ogawa A, Matsubara H. After the Dawn - Balloon Pulmonary Angioplasty for Patients With Chronic Thromboembolic Pulmonary Hypertension. *Circ J* 2018; 82: 1222–1230.
171. Feinstein JA, Goldhaber SZ, Lock JE, Ferndandes SM, Landzberg MJ. Balloon pulmonary angioplasty for treatment of chronic thromboembolic pulmonary hypertension. *Circulation* 2001; 103: 10–13.
172. Ejiri K, Ogawa A, Fujii S, Ito H, Matsubara H. Vascular Injury Is a Major Cause of Lung Injury After Balloon Pulmonary Angioplasty in Patients With Chronic Thromboembolic Pulmonary Hypertension. *Circ Cardiovasc Interv* 2018; 11: e005884.
173. Inami T, Kataoka M, Shimura N, Ishiguro H, Yanagisawa R, Kawakami T, Fukuda K, Yoshino H, Satoh T. Incidence, avoidance, and management of pulmonary artery injuries in percutaneous transluminal pulmonary angioplasty. *Int J Cardiol* 2015; 201: 35–37.
174. Inami T, Kataoka M, Yanagisawa R, Ishiguro H, Shimura N, Fukuda K, Yoshino H, Satoh T. Long-Term Outcomes After Percutaneous Transluminal Pulmonary Angioplasty for Chronic Thromboembolic Pulmonary Hypertension. *Circulation* 2016; 134: 2030–2032.
175. Aoki T, Sugimura K, Tatebe S, Miura M, Yamamoto S, Yaoita N, Suzuki H, Sato H, Kozu K, Konno R, Miyata S, Nochioka K, Satoh K, Shimokawa H. Comprehensive evaluation of the effectiveness and safety of balloon pulmonary angioplasty for inoperable chronic thrombo-embolic pulmonary hypertension: long-term effects and procedure-related complications. *Eur Heart J* 2017; 38: 3152–3159.

176. Taniguchi Y, Jais X, Jevnikar M, Boucly A, Weatherald J, Brenot P, Planche O, Parent F, Savale L, Fadel E, Montani D, Humbert M, Sitbon O, Simonneau G. Predictors of survival in patients with not-operated chronic thromboembolic pulmonary hypertension. *J Heart Lung Transplant* 2019; 38: 833–842.
177. Humbert M, Simonneau G, Pittrow D, Delcroix M, Pepke-Zaba J, Langleben D, Mielnizcuk LM, Escribano-Subias P, Klotsche J, Williams E, Meier C, Hoeper M. Safety of Riociguat in Patients with Pulmonary Arterial Hypertension and Chronic Thromboembolic Pulmonary Hypertension with Concomitant Novel Oral Anticoagulants or Vitamin K Antagonist Use: Data from the EXPERT Registry (Abstract). *Am J Respir Crit Care Med* 2020.
178. Jeong I, Fernandes T, Alotaibi M, Kim NH. Direct oral anticoagulant use and thrombus detection in patients with chronic thromboembolic pulmonary hypertension referred for pulmonary thromboendarterectomy. *Eur Respir J* 2019; 54: OA5161.
179. Skoro-Sajer N, Hack N, Sadushi-Koliçi R, Bonderman D, Jakowitsch J, Klepetko W, Hoda MAR, Kneussl MP, Fedullo P, Lang IM. Pulmonary vascular reactivity and prognosis in patients with chronic thromboembolic pulmonary hypertension: a pilot study. *Circulation* 2009; 119: 298–305.
180. Suntharalingam J, Hughes RJ, Goldsmith K, Doughty N, George P, Toshner M, Sheares KK, Pepke-Zaba J. Acute haemodynamic responses to inhaled nitric oxide and intravenous sildenafil in distal chronic thromboembolic pulmonary hypertension (CTEPH). *Vascul. Pharmacol.* 2007; 46: 449–455.
181. Suntharalingam J, Treacy CM, Doughty NJ, Goldsmith K, Soon E, Toshner MR, Sheares KK, Hughes R, Morrell NW, Pepke-Zaba J. Long-term Use of Sildenafil in Inoperable Chronic Thromboembolic Pulmonary Hypertension. *Chest* 2008; 134: 229–236.
182. Jais X, D'Armini AM, Jansa P, Torbicki A, Delcroix M, Ghofrani HA, Hoeper MM, Lang IM, Mayer E, Pepke-Zaba J, Perchenet L, Morganti A, Simonneau G, Rubin LJ, Bosentan Effects in iNopErable Forms of chronIc Thromboembolic pulmonary hypertension Study Group. Bosentan for treatment of inoperable chronic thromboembolic pulmonary hypertension: BENEFiT (Bosentan Effects in iNopErable Forms of chronIc Thromboembolic pulmonary hypertension), a randomized, placebo-controlled trial. *J Am Coll Cardiol* 2008; 52: 2127–2134.
183. Ghofrani HA, Simonneau G, D'Armini AM, Fedullo P, Howard LS, Jais X, Jenkins DP, Jing Z-C, Madani MM, Martin N, Mayer E, Papadakis K, Richard D, Kim NH, MERIT study investigators. Macitentan for the treatment of inoperable chronic thromboembolic pulmonary hypertension (MERIT-1): results from the multicentre, phase 2, randomised, double-blind, placebo-controlled study. *Lancet Respir Med* 2017; 5: 785–794.
184. Sadushi-Koliçi R, Jansa P, Kopeć G, Torbicki A, Skoro-Sajer N, Campean I-A, Halank M, Simkova I, Karlócai K, Steringer-Mascherbauer R, Samarzija M, Salobir B, Klepetko W, Lindner J, Lang IM. Subcutaneous treprostinil for the treatment of severe non-operable chronic thromboembolic pulmonary hypertension (CTREPH): a double-blind, phase 3, randomised controlled trial. *Lancet Respir Med* 2019; 7: 239–248.
185. Gabrielly M, Bourlier D, Taniguchi Y, Jevnikar M, Sekine A, Boucly A, Jutant E-M, Parent F, Savale L, Montani D, Simonneau G, Humbert M, Sitbon O, Jais X. Initial dual oral combination therapy in inoperable chronic thromboembolic pulmonary hypertension (CTEPH). *Eur Respir J* 2018; 52: PA3053.

186. Tromeur C, Jais X, Mercier O, Couturaud F, Montani D, Savale L, Jevnikar M, Weatherald J, Sitbon O, Parent F, Fabre D, Mussot S, Dartevielle P, Humbert M, Simonneau G, Fadel E. Factors predicting outcome after pulmonary endarterectomy. *PLoS ONE* 2018; 13: e0198198.
187. Nagaya N, Sasaki N, Ando M, Ogino H, Sakamaki F, Kyotani S, Nakanishi N. Prostacyclin therapy before pulmonary thromboendarterectomy in patients with chronic thromboembolic pulmonary hypertension. *Chest* 2003; 123: 338–343.
188. Bresser P, Fedullo PF, Auger WR, Channick RN, Robbins IM, Kerr KM, Jamieson SW, Rubin LJ. Continuous intravenous epoprostenol for chronic thromboembolic pulmonary hypertension. *Eur Respir J* 2004; 23: 595–600.
189. Reesink HJ, Surie S, Kloek JJ, Tan HL, Tepaske R, Fedullo PF, Bresser P. Bosentan as a bridge to pulmonary endarterectomy for chronic thromboembolic pulmonary hypertension. *J Thorac Cardiovasc Surg* 2010; 139: 85–91.
190. Kawashima T, Yoshitake A, Kawakami T, Shimizu H. Two-stage Treatment Using Balloon Pulmonary Angioplasty and Pulmonary Endarterectomy in a Patient with Chronic Thromboembolic Pulmonary Hypertension. *Ann Vasc Surg* 2018; 49: 315.e5–315.e7.
191. Yanaka K, Nakayama K, Shinke T, Shinkura Y, Taniguchi Y, Kinutani H, Tamada N, Onishi H, Tsuboi Y, Satomi Kobayashi S, Otake H, Tanaka H, Okita Y, Emoto N, Hirata KI. Sequential Hybrid Therapy With Pulmonary Endarterectomy and Additional Balloon Pulmonary Angioplasty for Chronic Thromboembolic Pulmonary Hypertension. *J Am Heart Assoc* 2018; 7. DOI: 10.1161/JAHA.118.008838.
192. Araszkievicz A, Darocha S, Pietrasik A, Pietura R, Jankiewicz S, Banaszkievicz M, Sławek-Szmyt S, Biederman A, Mularek-Kubzdela T, Lesiak M, Torbicki A, Kurzyna M. Balloon pulmonary angioplasty for the treatment of residual or recurrent pulmonary hypertension after pulmonary endarterectomy. *Int J Cardiol* 2019; 278: 232–237.
193. Nakamura M, Sunagawa O, Tsuchiya H, Miyara T, Taba Y, Touma T, Munakata H, Kugai T, Okita Y. Rescue balloon pulmonary angioplasty under veno-arterial extracorporeal membrane oxygenation in a patient with acute exacerbation of chronic thromboembolic pulmonary hypertension. *Int Heart J* 2015; 56: 116–120.
194. Collaud S, Brenot P, Mercier O, Fadel E. Rescue balloon pulmonary angioplasty for early failure of pulmonary endarterectomy: The earlier the better? *Int J Cardiol* 2016; 222: 39–40.
195. Wiedenroth CB, Ghofrani HA, Adameit MSD, Breithecker A, Haas M, Kriechbaum S, Rieth A, Hamm CW, Mayer E, Guth S, Liebetrau C. Sequential treatment with riociguat and balloon pulmonary angioplasty for patients with inoperable chronic thromboembolic pulmonary hypertension. *Pulm Circ* 2018; 8: 2045894018783996.
196. Mereles D, Ehlken N, Kreuzer S, Ghofrani S, Hoeper MM, Halank M, Meyer FJ, Karger G, Buss J, Juenger J, Holzapfel N, Opitz C, Winkler J, Herth FFJ, Wilkens H, Katus HA, Olschewski H, Grünig E. Exercise and respiratory training improve exercise capacity and quality of life in patients with severe chronic pulmonary hypertension. *Circulation* 2006; 114: 1482–1489.
197. Ehlken N, Lichtblau M, Klose H, Weidenhammer J, Fischer C, Nechwatal R, Uiker S, Halank M, Olsson K, Seeger W, Gall H, Rosenkranz S, Wilkens H, Mertens D, Seyfarth

- H-J, Opitz C, Ulrich S, Egenlauf B, Grünig E. Exercise training improves peak oxygen consumption and haemodynamics in patients with severe pulmonary arterial hypertension and inoperable chronic thrombo-embolic pulmonary hypertension: a prospective, randomized, controlled trial. *Eur Heart J* 2016; 37: 35–44.
198. Handoko ML, De Man FS, Happé CM, Schaliij I, Musters RJP, Westerhof N, Postmus PE, Paulus WJ, van der Laarse WJ, Vonk-Noordegraaf A. Opposite effects of training in rats with stable and progressive pulmonary hypertension. *Circulation* 2009; 120: 42–49.
199. Zhai Z, Murphy K, Tighe H, Wang C, Wilkins MR, Gibbs JSR, Howard LS. Differences in ventilatory inefficiency between pulmonary arterial hypertension and chronic thromboembolic pulmonary hypertension. *Chest* 2011; 140: 1284–1291.
200. Nagel C, Prange F, Guth S, Herb J, Ehlken N, Fischer C, Reichenberger F, Rosenkranz S, Seyfarth H-J, Mayer E, Halank M, Grünig E. Exercise training improves exercise capacity and quality of life in patients with inoperable or residual chronic thromboembolic pulmonary hypertension. *PLoS ONE* 2012; 7: e41603.
201. Inagaki T, Terada J, Tanabe N, Kawata N, Kasai H, Sugiura T, Shigeta A, Asano Y, Murata A, Tsushima K, Tada Y, Sakao S, Tatsumi K. Home-based pulmonary rehabilitation in patients with inoperable or residual chronic thromboembolic pulmonary hypertension: a preliminary study. *Respir Investig* 2014; 52: 357–364.
202. La Rovere MT, Pinna GD, Pin M, Bruschi C, Callegari G, Zanotti E, D'Armini A, Ambrosino N. Exercise Training After Pulmonary Endarterectomy for Patients with Chronic Thromboembolic Pulmonary Hypertension. *Respiration*; 2019; 97: 234-241.
203. Fukui S, Ogo T, Takaki H, Ueda J, Tsuji A, Morita Y, Kumasaka R, Arakawa T, Nakanishi M, Fukuda T, Yasuda S, Ogawa H, Nakanishi N, Goto Y. Efficacy of cardiac rehabilitation after balloon pulmonary angioplasty for chronic thromboembolic pulmonary hypertension. *Heart* 2016; 102: 1403–1409.
204. Opitz I, Kirschner MB. Molecular Research in Chronic Thromboembolic Pulmonary Hypertension. *Int J Mol Sci* 2019; 20: 784.
205. Hemnes AR, Beck GJ, Newman JH, Abidov A, Aldred MA, Barnard J, Berman Rosenzweig E, Borlaug BA, Chung WK, Comhair SAA, Erzurum SC, Frantz RP, Gray MP, Grünig G, Hassoun PM, Hill NS, Horn EM, Hu B, Lempel JK, Maron BA, Mathai SC, Olman MA, Rischard FP, Systrom DM, Tang WHW, Waxman AB, Xiao L, Yuan JX-J, Leopold JA, PVDOMICS Study Group. PVDOMICS: A Multi-Center Study to Improve Understanding of Pulmonary Vascular Disease Through Phenomics. *Circ Res* 2017; 121: 1136–1139.
206. Newnham M, South K, Bleda M, Auger WR, Barberà JA, Bogaard H, Bunclark K, Cannon JE, Delcroix M, Hadinnapola C, Howard LS, Jenkins D, Mayer E, Ng C, Rhodes CJ, Srean N, Sheares K, Simpson MA, Southwood M, Su L, Taboada D, Traylor M, Trembath RC, Villar SS, Wilkins MR, Wharton J, Gräf S, Pepke-Zaba J, Laffan M, Lane DA, et al. The ADAMTS13-VWF axis is dysregulated in chronic thromboembolic pulmonary hypertension. *Eur Respir J* 2019; 53: 1801805.
207. Heresi GA, Mey JT, Bartholomew JR, Haddadin IS, Tonelli AR, Dweik RA, Kirwan JP, Kalhan SC. Plasma metabolomic profile in chronic thromboembolic pulmonary hypertension. *Pulm Circ* 2020; 10: 2045894019890553.

208. Madani MM, Wittine LM, Auger WR, Fedullo PF, Kerr KM, Kim NH, Test VJ, Kriett JM, Jamieson SW. Chronic thromboembolic pulmonary hypertension in pediatric patients. *J Thorac Cardiovasc Surg* 2011; 141: 624–630.
209. Kumbasar U, Aypar E, Karagöz T, Demircin M, Doğan R. Pulmonary thromboendarterectomy in pediatric patients: Report of three cases. *Turk J Pediatr* 2018; 60: 604–607.
210. Verbelen T, Cools B, Fejzic Z, Van Den Eynde R, Maleux G, Delcroix M, Meyns B. Pulmonary endarterectomy in a 12-year-old boy with multiple comorbidities. *Pulm Circ* 2019; 9: 204589401988624.

Supplement

Table S1: TF composition per topic

1. **Definitions:** Torbicki, Lang, Pepke-Zaba, Dorfmuller, Madani + Corkery
2. **Diagnosis:** Gopalan, Hoeper, Ogo, Meyer, Jais + Meszaros
3. **Epidemiology:** Sitbon, Matsubara, Klok, Jansa, Dorfmuller, D'Armini
4. **Acute PE:** Klok, Torbicki, Hoeper, Vonk Noordegraaf, Gopalan + Meszaros
5. **Pathophysiology:** Lang, Humbert, Vonk Noordegraaf, Gopalan, Dorfmuller, Fadel
6. **PEA:** Jenkins, D'Armini, Fadel, Madani, Brenot, Ghofrani, Kim
7. **BPA:** Kim, Ogo, Lang, Brenot, Meyer, Matsubara, Galie, Madani
8. **Medical treatment:** Humbert, Ogo, Hoeper, Sitbon, Ghofrani, Galie, Pepke-Zaba, Fadel
9. **Multimodality:** Jais, Brenot, Mayer, Matsubara, Torbicki, Jansa, D'Armini, Jenkins + Corkery
10. **Rehabilitation in CTEPH:** Vonk Noordegraaf, Gruenig, Klok, Jais, Jansa + Corkery
11. **Global research lines:** Pepke-Zaba, Humbert, Sitbon, Ghofrani, Galie, Kim, Gopalan, Jenkins + Meszaros

Table S2: Search strategies for each topic/question

	Topic	Database searched	Search terms
1	Definition	MEDLINE (via PubMed) without date limits	chronic thromboembolic pulmonary hypertension AND definition Chronic Thromboembolic Disease (CTED) AND definition
2	Diagnosis	MEDLINE (via PubMed), EMBASE (via Ovid), and Cochrane Library (Wiley) Years Covered: 1980-2019	Chronic Thromboembolic Pulmonary Hypertension OR CTEPH AND imaging Chronic Thromboembolic Disease OR CTED AND imaging
3	Epidemiology	MEDLINE (via PubMed) without date limits	- First of all: "chronic thromboembolic pulmonary hypertension" OR "CTEPH" AND "Epidemiology" - Then: "Frequency", "surveillance", "occurrence", "incidence", "prevalence", "pulmonary embolism", "venous thromboembolism", "perfusion defect", "lung scan", "anticoagulation", "oral anticoagulant", "vitamin K antagonist", "Non-Vitamin K antagonist oral anticoagulants"
3	PE to CTEPH	MEDLINE (via PubMed) without date limits	For Table S7: Publication range from 1990-2019 (the 1st paper from 1992 by Bill Auger for description of CTEPH findings was baseline). MeSH Terms: pulmonary embolism; thromboembolism; hypertension, pulmonary; tomography, x-ray computed. Subheading: diagnosis For table S8: ("risk factors"[MeSH Terms] OR ("risk"[All Fields] AND "factors"[All Fields]) OR "risk factors"[All Fields]) AND "chronic thromboembolic pulmonary hypertension"[All Fields] For table X3: ("diagnosis"[Subheading] OR "diagnosis"[All Fields] OR "diagnosis"[MeSH Terms]) AND "chronic thromboembolic pulmonary hypertension"[All Fields]
5	Pathophysiology	MEDLINE (via PubMed) without date limits	chronic thromboembolic pulmonary hypertension, pulmonary arterial hypertension, bronchial arteries, systemic vessels, microvascular, anastomoses, shunt, pathology, histology, small vessel disease, right ventricle, maladaptation, wave reflection patterns, CTPA, MRI, ECG gating, blood volume maps
6	PEA	MEDLINE (via PubMed), EMBASE (via Ovid), and Cochrane Library (Wiley) until Sept 2019	CTED OR CTEPH OR chronic thromboembolic disease OR chronic thromboembolic pulmonary hypertension AND pulmonary endarterectomy OR pulmonary thromboendarterectomy AND surg OR thorax surgery
7	BPA	MEDLINE (via PubMed) without date limits	"balloon pulmonary angioplasty" AND "percutaneous transluminal pulmonary angioplasty"; Balloon pulmonary angioplasty: 2363 citations Percutaneous transluminal pulmonary angioplasty: 458 citations
8	Medical therapy	MEDLINE (via PubMed)	chronic thromboembolic pulmonary hypertension AND medical treatment

			<p>chronic thromboembolic pulmonary hypertension AND pulmonary vasodilators</p> <p>chronic thromboembolic pulmonary hypertension AND anticoagulation</p> <p>chronic thromboembolic pulmonary hypertension AND riociguat</p> <p>chronic thromboembolic pulmonary hypertension AND guanylate cyclase stimulators</p> <p>chronic thromboembolic pulmonary hypertension AND phosphodiesterase type 5 inhibitors</p> <p>chronic thromboembolic pulmonary hypertension AND prostacyclin</p> <p>chronic thromboembolic pulmonary hypertension AND prostacyclin receptor agonist</p>
9	Multimodality	MEDLINE (via PubMed) without date limits	<p>multimodality[MeSH Terms] OR multimodality[Text Word] OR multimodal[MeSH Terms] OR multimodal[Text Word] OR combination[MeSH Terms] OR combination[Text Word] OR hybrid[MeSH Terms] OR hybrid[Text Word] OR additional[MeSH Terms] OR additional[Text Word] OR sequential[MeSH Terms] OR sequential[Text Word] OR combined[MeSH Terms] OR combined[Text Word] OR bridge[MeSH Terms] OR bridge[Text Word] OR bridging[MeSH Terms] OR bridging[Text Word] OR therapy[MeSH Terms] OR therapy[Text Word] OR angioplasty[MeSH Terms] OR angioplasty[Text Word] OR endarterectomy[MeSH Terms] OR endarterectomy[Text Word] OR thromboendarterectomy[MeSH Terms] OR thromboendarterectomy[Text Word] AND chronic thromboembolic pulmonary hypertension[MeSH Terms] OR chronic thromboembolic pulmonary hypertension[Text Word]</p>
10	Rehabilitation	MEDLINE (via PubMed) without date limits	<p>("Cardiac Rehabilitation"[Mesh] OR "cardiopulmonary rehabilitation"[tw] OR "cardiovascular rehabilitation"[tw] OR "cardiac rehabilitation"[tw] OR "pulmonary rehabilitation"[tw] OR "Rehabilitation"[Mesh] OR "rehabilitation"[Subheading] OR "rehabilitation"[tw] OR rehabilit*[tw] OR "Early Ambulation"[mesh] OR "Exercise Therapy"[mesh] OR "Endurance Training"[mesh] OR "Motion Therapy, Continuous Passive"[mesh] OR "Muscle Stretching Exercises"[mesh] OR "Plyometric Exercise"[mesh] OR "Resistance Training"[mesh] OR "Early Ambulation"[tw] OR "Exercise Therapy"[tw] OR "Endurance Training"[tw] OR "Continuous Passive Motion Therapy"[tw] OR "Muscle Stretching Exercises"[tw] OR "Plyometric Exercise"[tw] OR "Resistance Training"[tw] OR "Muscle Stretching Exercise"[tw] OR "Plyometric Exercises"[tw]) AND ("chronic thromboembolic"[tw] OR "chronic thromboembolic disease"[tw] OR "chronic thromboembolism"[tw] OR "chronic thrombo embolic pulmonary"[tw] OR "Pulmonary Embolism"[Mesh] OR "Pulmonary Embolism"[tw] OR "Pulmonary Embolisms"[tw] OR "Pulmonary Embolism"[tw] OR "Pulmonary Embolisms"[tw] OR "Pulmonary Thromboembolism"[tw] OR "Pulmonary Thromboembolisms"[tw] OR "Pulmonary Thromboembolism"[tw]))</p>
11	Research	MEDLINE (via PubMed), EMBASE (via Ovid)	<p>*"CLINICAL TRIALS AS TOPIC"/ AND ((CTEPH).ti,ab OR exp *"HYPERTENSION, PULMONARY"/ OR ("chronic thromboembolic pulmonary hypertension").ti,ab)) [DT 2009-2019]</p> <p>((CTEPH).ti,ab OR exp *"HYPERTENSION, PULMONARY"/ OR ("chronic thromboembolic pulmonary hypertension").ti,ab) AND exp *"DRUG THERAPY, COMBINATION"/21</p> <p>exp REGISTRIES/ AND ((CTEPH).ti,ab OR ("chronic thromboembolic pulmonary hypertension").ti,ab) 32</p>

			<p>((CTEPH).ti,ab OR exp *"HYPERTENSION, PULMONARY"/ OR ("chronic thromboembolic pulmonary hypertension").ti,ab) AND(("biobank" OR "biorepository" OR "biological samples").ti,ab OR exp "DATABASES, GENETIC"/ OR exp "BIOLOGICAL SPECIMENBANKS"/ OR exp PHENOTYPE/)) [DT 2009-2019] [Humans] 147</p>
--	--	--	---

Table S3: Hemodynamic characteristics in cohorts of CTEPD patients without PH at rest

	Taboada 2014 [1]	Van Kan 2016 [2]	Held 2016 [3]	Guth 2018 [4]	Claeys 2019 [5]	Swietlik 2019 [6]
n	42	14	10	12	14	34
age	49 ± 16	48 ± 16	62 ± 14	51 (34-65)	47 ± 16	53±17
mPAP, mmHg	21 (5)	19 ± 3	20.5 (4.3)	20 ± 3	20.5 (17.5 – 23.3)	20 (18–22)
PVR, dyn.s.cm-5	164 (104)	147 ± 34	244 (151)	3.4 (2.8-4.4)	154 ± 48.9	1.9 (1.4–2.4)
PQ slope, mmHg.min.L-1	-	2.7 ± 1.2	-	3.6 ± 1.0	3.48 (2.24 – 4.36)	1.6 (1.1–3.4)

Mean ± SD, median (IQR)

Table S4: Survey on VQ SPECT, DECT and MR for CTEPH

Commentor	Does your institution offer SPECT VQ routinely	Does your institution offer the possibility of extracting Planar images from SPECT data	would you as clinicians like to have access to these planar images as add-on to SPECT to be made available on your PACS system
DG (UK)	Yes	Yes	Yes
JP-Z (UK)	Yes	Yes	Yes
EM (Germany)	No Patients referred for PEA or BPA usually had a SPECT VQ before admission	No	Yes
FK (Netherlands)	No	No	Yes
EG (Germany)	Yes	Yes	Yes
MMH (Germany)	Yes	Yes	Yes
NK (USA)	Yes	Yes	Yes
PJ (Czech Republic)	No	N/A	Not filled in
PB (France)	Yes	Yes	Yes
TO (Japan)	Yes	No	Yes
XJ (France)	Yes	Yes	Yes
IL (Austria)	Yes	Yes	Yes
AT (Poland)	Yes (done in a contracted separate nuclear medicine laboratory)	Yes	Yes
MD (Belgium)	Yes	Yes	Yes
AD (Italy)	Yes	Yes	Yes

15 respondents.

12/15 institutions do VQ SPECT. Of these, the clinicians working in the 11 of the 12 that do VQ SPECT would like planar reconstructions from SPECT to be made available for review.

Commentor	Is the CT scanner in your institution capable of doing dual energy (DECT)?	If yes to above, do you do DECT as routine rather than conventional CTPA	Is Cardiac MR routinely done as a part of PH/CTEPH workup in your institution?	If Yes to above, which of the following do you use MR for? 1. MRA (+/- perfusion) 2. Rotating MIP 3. RV function baseline 4. RV function post-Rx
DG (UK)	Yes	Yes	Yes	ALL
JP-Z (UK)	Yes	Yes	Yes	ALL
EM (Germany)	Yes	No We use DECT for additional information	No only in selected cases for RV assessment	N/A
FK (Netherlands)	No	N/A	No	N/A
EG (Germany)	Yes	Yes	Yes	3,4
MMH (Germany)	Yes	Not filled-in	Yes Regularly done, but not as part of clinical routine but as research tool (Change MRI study)	
NK (USA)	Yes	No. Only On request	No. Only on request	
PJ (Czech Republic)	No	N/A	No	
PB (France)	Yes	Yes	No	Angio DSA used regularly and occasionally cone beam CT during BPA sessions
TO (Japan)	Yes	Yes	Yes	3,4
XJ (France)	No	N/A	No	
IL (Austria)	Yes	No	Yes	N/A
AT (Poland)	No	N/A	No	N/A
MD (Belgium)	Yes	Yes	No	
AD (Italy)	Yes	Yes	Yes	3,4

15 respondents.

DECT: 11/15 have access but only 7 are routinely doing DECT over standard CTPA. 2/15 do DECT on request

MRI: 7/15 routinely have access to MRI and 2/15 perform MRI on request. Out of the 7 institution that had routine access to MRI, only 2 are using all components of MR (assessment of pulmonary vasculature and evaluation of RV function). Three centres use MRI only for RV function evaluation at baseline & post treatment. One institution does MRI routinely as it is part of a study protocol.

Table S5: What makes a high-quality CTPA?

Image quality determines the diagnostic value of a CTPA but is a complex entity for which there is no single objective measure. Current generation of CT systems of 64 slices and higher are consistently capable of producing high spatial resolution images that are of high quality but the CTPA protocols vary according to the available hardware as well as technical and patient related factors such as body habitus, motion and cardiac function. It is beyond the scope of this paper to address all aspects of CTPA protocols, but the fundamentals are outlined below.

The basic principle is to acquire a movement-free volumetric dataset of the thorax during peak enhancement of the pulmonary circulation with reduced venous contamination. High temporal resolution to ensure fast coverage of the thorax using the shortest acquisition time can be achieved by increasing detector size and anatomic coverage per rotation. This is of particular importance in dyspneic patients to avoid breathing-related artefacts. Caudocranial direction of acquisition will also provide the best chance of motion free imaging of the lower lobes. ECG gating can diminish motion artifacts arising from cardiac pulsation and result in sharper outlines of the vessel contour and can be facilitated without increasing the breath-hold time, an important consideration in pulmonary hypertension patients but is not routinely implemented in standard CTPA protocols.

High injections rate (eg, 4-5 mL/sec) and iodine concentrations of 350 or 370 mgI/mL will provide improved enhancement that is necessary to distinguish thrombus from intraluminal contrast material. The injection duration is approximately equal to the sum of the scan duration and the delay time. As the standard CTPA protocol is optimised for pulmonary arterial opacification, a longer delay from the injection of contrast medium to image acquisition is necessary for depicting bronchial collaterals. The volume of contrast medium is individually tailored for each patient taking in to account the patient size, cardiac and renal function. A saline chaser at the same injection rate can help in minimising streak artifacts by improving the washout of contrast medium from the superior vena cava and innominate veins. Prior to the acquisition, patients are also instructed to avoid inadvertent Valsalva manoeuvre as it can cause sudden influx of un-opacified blood from the inferior vena cava.

Pulmonary artery attenuations of 300 to 350 HU (ie, 250–300 HU net contrast enhancement) is considered as the preferred level of CTPA contrast enhancement {Bae:2010er}. The theoretic minimum attenuation of pulmonary artery required to detect acute and chronic emboli is computed as 211 HU {Wittram:2007fh}. Thinnest possible collimation will improve detection in the subsegmental level.

Images are reconstructed at minimum of 1mm slice thickness using a soft tissue kernel in the axial plane. An elemental advantage of the CT volumetric datasets is the possibility to perform multiplanar reformats through the longitudinal axis of a vessel. This can be of immense benefit in the interrogation of the complex vascular anatomy and aid in the differentiation of factors that mimic pulmonary thromboembolism. It is also mandatory to adjust the display window widths and levels (soft tissue window 400 /30 to 40 HU; pulmonary parenchyma 1500/ -800 to -600 HU; pulmonary embolism–specific setting 700/100 HU) in order to improve the conspicuity of the abnormalities. Maximum Intensity Projection (MIP) is a widely used rendering tool that involves projecting the highest attenuation voxels on every view throughout the volume onto a 2D image. MIP's can be adjusted to variable thickness and is very useful for creation of a vascular map for display. [7, 8]

Table S6: CTPA features of acute PE and CTEPH [9]

	Acute PE	CTEPH
Pulmonary vasculature	<ul style="list-style-type: none"> - Dilatation of main pulmonary artery (in severe PE) - Central or eccentric filling defect surrounded by contrast material forming acute angles with the arterial wall [“polo mint” when orthogonal or “railway track” sign when parallel to long axis of the vessel] - Distension of completely occluded vessel - Normal calibre segmental vessels 	<ul style="list-style-type: none"> - Asymmetric enlargement of central pulmonary arteries - Eccentric thrombus (may or may not be calcified) forming obtuse angles with the vessel wall - Intimal thickening/irregularities - Reduced calibre of occluded vessel with absent flow distal to the total obstruction - Small segmental and subsegmental vessels with abrupt cut-offs - Intravascular webs and bands - Stenosis with or without post-stenotic dilatation - Tortuous vessels - Atherosclerotic calcification of vessel wall
Systemic vasculature		<ul style="list-style-type: none"> - Enlarged bronchial and non-bronchial collaterals
Cardiovascular	<ul style="list-style-type: none"> - Right ventricular dilatation (in severe PE) - Retrograde flow of contrast material into distended azygos vein, inferior vena cava and intrahepatic veins (in severe PE) 	<ul style="list-style-type: none"> - Right ventricular dilatation and hypertrophy - Retrograde flow of contrast material into distended azygos vein, inferior vena cava and intrahepatic veins
Lung parenchyma	<ul style="list-style-type: none"> - Wedge-shaped peripheral areas of hyper-attenuation - Opacities with central ground glass and a rim of consolidation [“reverse-halo” sign] 	<ul style="list-style-type: none"> - Mosaic attenuation - Focal ground glass opacities - Parenchymal bands - Subpleural scars - Cavitating infarcts - Pleural thickening - Cylindrical bronchial airway dilatation - Air trapping

Table S7: Known risk factors for CTEPH compared to patients with IPAH, and their prevalence in patients with PE

	Reported Odds Ratio CTEPH versus IPAH (95%CI) [10]	Estimated prevalence among patients with acute pulmonary embolism [11]
Thyroid replacement therapy	6.1 (2.7–15)	5-7%
Malignancy	3.8 (1.5–10)	10-25%
Recurrent venous thromboembolism	15 (5.4–43)	20-30%
(Sub)-massive pulmonary embolism	13 (not provided)	30-60%
Anti-phospholipid antibodies	4.2 (1.6–12)	2-5%
Factor VIII >230 IU/dl	2.5 (not provided)	10-30%
Non-O blood group	2.1 (1.2–3.9)	60-80%
Ventriculoatrial shunt or (infected) pacemaker	76 (7.7–10,350)	<1%
Splenectomy	18 (1.6–2.4)	1-2%

Table S8: Overview and accuracy of diagnostic tests that provide clues to the presence/absence of CTEPH, as derived from studies in patients with a history of acute PE and/or suspected CTEPH

Diagnostic test	Sensitivity	Specificity	Remarks
“Leiden CTEPH prediction score” [11] [12]	85-91%	75%	<ul style="list-style-type: none"> - Score based on the following factors: Unprovoked PE (+6 points), hypothyroidism (+3 points), symptom onset >2 weeks before PE diagnosis (+3 points), RV dysfunction at index CTPA (+2 points), diabetes mellitus (-3 points) and thrombolytic/surgical therapy (-3 points); a total score >6 points denotes patients at high risk of CTEPH. - Not developed to serve as single diagnostic test but to identify 25% of patients with highest pre-test probability.
Cardiopulmonary exercise testing (CPET) [9, 13]	83%	92%	<ul style="list-style-type: none"> - Typically appears as ineffective ventilation with elevated alveolar–capillary gradients of oxygen and carbon dioxide; <ul style="list-style-type: none"> ○ Elevated slope of minute ventilation (V'_E)/carbon dioxide output (V'_{CO_2}) ratio. ○ Elevated ventilator equivalents for oxygen (EQ_{O_2}) and carbon dioxide (EQ_{CO_2}). ○ Low and decreasing end-tidal carbon dioxide tension (P_{ETCO_2}), elevated alveolar–arterial oxygen tension gradient (P_{A-aO_2}) and elevated arterial–end-tidal carbon dioxide gradient (P_{A-ETCO_2}).
BNP/NT-proBNP [14, 15]	82%	70%	<ul style="list-style-type: none"> - Applied threshold was age and sex normal value as determined by the manufacturer.

ECG [16, 17] [14]	77%	89%	<ul style="list-style-type: none"> - Generally, ECG signs of right heart strain include P-pulmonale, right bundle branch block, T-wave abnormalities in the chest leads and right-axis deviation. - Specifically, an ECG is indicative of CTEPH in case of either 1) rSR' or rSr' pattern in lead V1, 2) R:S >1 in lead V1 with R >0.5 mV, or 3) QRS axis >90°.
ECG and BNP/NT-proBNP combined ('CTEPH rule-out criteria') [11, 12] [14]	91-96%	65%	<ul style="list-style-type: none"> - Not prospectively evaluated in management study (trial ongoing NCT02555137, results expected in 2020).
Echo [9, 18-20]	70-100%	72-89%	<ul style="list-style-type: none"> - Evaluations include estimating peak velocity of tricuspid valve regurgitation, calculation of atrioventricular pressure gradients and detection of indirect signs of pulmonary hypertension such as right atrial and right ventricular dilatation, reduced right ventricular contractility and Doppler flow abnormalities in the right ventricular outflow tract. - Conclusions derived from an echocardiographic examination should aim to assign a level of probability of pulmonary hypertension.
V/Q scintigraphy (planar) [9, 18, 21, 22]	90-100%	51-100%	<ul style="list-style-type: none"> - In CTEPH, at least one but more commonly several, segmental or larger mismatched perfusion defects are present. - Small peripheral unmatched and non-segmental defects in perfusion can also be present in patients with PAH. - Larger unmatched perfusion defects may also be seen in other pulmonary vascular disease such as PVOD.
V/Q SPECT [23]	97%	81%	<ul style="list-style-type: none"> - Data for V/Q SPECT in CTEPH are still sparse.
CTPA [24]	76%	96%	<ul style="list-style-type: none"> - Specific CTPA characteristics of CTEPH are summarized in Table S7. - Sensitivity was 99% and specificity was 97%, when only high quality CT scans

			including DECT were included.
Dual-energy CT (DECT) [9]	97%	86%	<ul style="list-style-type: none"> - Data for V/Q SPECT in CTEPH are still sparse. - The calculation of iodine distribution in the lung parenchym offers qualitative and quantitative insights into pulmonary haemodynamics (correlates with mPAP and PVR measurements on right heart catheterisation) and helps differentiation between small airway disease from pulmonary artery vascular disease.
Contrast-enhanced/perfusion MRI [9, 23, 25]	83-100%	81-99%	<ul style="list-style-type: none"> - MRA is superior to DSA in depicting the precise proximal beginning of the thromboembolic material, with accuracy lower at the subsegmental level - MRI scanning will also allow for accurate assessment of the RV function and morphology

References

1. Taboada D, Pepke-Zaba J, Jenkins DP, Berman M, Treacy CM, Cannon JE, Toshner M, Dunning JJ, Ng C, Tsui SS, Sheares KK. Outcome of pulmonary endarterectomy in symptomatic chronic thromboembolic disease. *Eur Respir J* 2014; 44: 1635–1645.
2. van Kan C, van der Plas MN, Reesink HJ, van Steenwijk RP, Kloek JJ, Tepaske R, Bonta PI, Bresser P. Hemodynamic and ventilatory responses during exercise in chronic thromboembolic disease. *J Thorac Cardiovasc Surg* 2016; 152: 763–771.
3. Held M, Kolb P, Grün M, Jany B, Hübner G, Grgic A, Holl R, Schaefers H-J, Wilkens H. Functional Characterization of Patients with Chronic Thromboembolic Disease. *Respiration* Karger Publishers; 2016; 91: 503–509.
4. Guth S, Wiedenroth CB, Rieth A, Richter MJ, Gruenig E, Ghofrani HA, Arlt M, Liebetrau C, Prüfer D, Rolf A, Hamm CW, Mayer E. Exercise right heart catheterisation before and after pulmonary endarterectomy in patients with chronic thromboembolic disease. *Eur Respir J* 2018; 52: 1800458.
5. Claeys M, Claessen G, La Gerche A, Petit T, Belge C, Meyns B, Bogaert J, Willems R, Claus P, Delcroix M. Impaired Cardiac Reserve and Abnormal Vascular Load Limit Exercise Capacity in Chronic Thromboembolic Disease. *JACC Cardiovasc Imaging* 2019; 12: 1444–1456.
6. Swietlik EM, Ruggiero A, Fletcher AJ, Taboada D, Knightbridge E, Harlow L, Harvey I, Screatton N, Cannon JE, Sheares KKK, Ng C, Jenkins DP, Pepke-Zaba J, Toshner MR. Limitations of resting haemodynamics in chronic thromboembolic disease without pulmonary hypertension. *Eur Respir J* European Respiratory Society; 2019; 53: 1801787.
7. Bae KT. Optimization of contrast enhancement in thoracic MDCT. *Radiol. Clin. North Am.* 2010; 48: 9–29.
8. Wittram C. How I do it: CT pulmonary angiography. *AJR Am J Roentgenol* 2007; 188: 1255–1261.
9. Gopalan D, Delcroix M, Held M. Diagnosis of chronic thromboembolic pulmonary hypertension. *Eur Respir Rev* European Respiratory Society; 2017; 26: 160108.
10. Delcroix M, Kerr K, Fedullo P. Chronic Thromboembolic Pulmonary Hypertension. Epidemiology and Risk Factors. *Annals ATS* 2016; 13 Suppl 3: S201–S206.
11. Klok FA, Dzikowska-Diduch O, Kostrubiec M, Vliegen HW, Pruszczyk P, Hasenfuss G, Huisman MV, Konstantinides S, Lankeit M. Derivation of a clinical prediction score for chronic thromboembolic pulmonary hypertension after acute pulmonary embolism. *J Thromb Haemost* 2016; 14: 121–128.

12. Ende-Verhaar YM, Ruigrok D, Bogaard HJ, Huisman MV, Meijboom LJ, Vonk-Noordegraaf A, Klok FA. Sensitivity of a Simple Noninvasive Screening Algorithm for Chronic Thromboembolic Pulmonary Hypertension after Acute Pulmonary Embolism. *TH Open* Georg Thieme Verlag KG; 2018; 2: e89–e95.
13. Held M, Grün M, Holl R, Hübner G, Kaiser R, Karl S, Kolb M, Schäfers H-J, Wilkens H, Jany B. Cardiopulmonary exercise testing to detect chronic thromboembolic pulmonary hypertension in patients with normal echocardiography. *Respiration* 2014; 87: 379–387.
14. Klok FA, Surie S, Kempf T, Eikenboom J, van Straalen JP, Van Kralingen KW, Van Dijk APJ, Vliegen HW, Bresser P, Wollert KC, Huisman MV. A simple non-invasive diagnostic algorithm for ruling out chronic thromboembolic pulmonary hypertension in patients after acute pulmonary embolism. *Thromb Res* 2011; 128: 21–26.
15. Klok FA, Tesche C, Rappold L, Dellas C, Hasenfuss G, Huisman MV, Konstantinides S, Lankeit M. External validation of a simple non-invasive algorithm to rule out chronic thromboembolic pulmonary hypertension after acute pulmonary embolism. *Thromb Res* 2015; 135: 796–801.
16. Ende-Verhaar YM, Huisman MV, Klok FA. To screen or not to screen for chronic thromboembolic pulmonary hypertension after acute pulmonary embolism. *Thromb Res* Elsevier Ltd; 2017; 151: 1–7.
17. Henkens IR, Mouchaers KTB, Vonk-Noordegraaf A, Boonstra A, Swenne CA, Maan AC, Man S-C, Twisk JWR, van der Wall EE, Schalij MJ, Vliegen HW. Improved ECG detection of presence and severity of right ventricular pressure load validated with cardiac magnetic resonance imaging. *Am J Physiol Heart Circ Physiol* 2008; 294: H2150–H2157.
18. Galiè N, Humbert M, Vachiéry J-L, Gibbs S, Lang I, Torbicki A, Simonneau G, Peacock A, Vonk-Noordegraaf A, Beghetti M, Ghofrani A, Gomez-Sanchez MA, Hansmann G, Klepetko W, Lancellotti P, Matucci M, McDonagh T, Pierard LA, Trindade PT, Zompatori M, Hoeper MM. 2015 ESC/ERS Guidelines for the diagnosis and treatment of pulmonary hypertension: The Joint Task Force for the Diagnosis and Treatment of Pulmonary Hypertension of the European Society of Cardiology (ESC) and the European Respiratory Society (ERS): Endorsed by: Association for European Paediatric and Congenital Cardiology (AEPC), International Society for Heart and Lung Transplantation (ISHLT). *Eur Respir J* 2015; 46: 903–975.
19. Janda S, Shahidi N, Gin K, Swiston J. Diagnostic accuracy of echocardiography for pulmonary hypertension: a systematic review and meta-analysis. *Heart* BMJ Publishing Group Ltd; 2011; 97: 612–622.
20. Habib G, Torbicki A. The role of echocardiography in the diagnosis and management of patients with pulmonary hypertension. *Eur Respir Rev* European Respiratory Society; 2010; 19: 288–299.
21. Pesavento R, Filippi L, Palla A, Visonà A, Bova C, Marzolo M, Porro F, Villalta S, Ciammaichella M, Bucherini E, Nante G, Battistelli S, Muiesan ML, Beltramello G, Prisco D, Casazza F, Ageno W, Palareti G, Quintavalla R, Monti S, Mumoli N,

- Zanatta N, Cappelli R, Cattaneo M, Moretti V, Corà F, Bazzan M, Ghirarduzzi A, Frigo AC, Miniati M, et al. Impact of residual pulmonary obstruction on the long-term outcome of patients with pulmonary embolism. *Eur Respir J* European Respiratory Society; 2017; 49: 1601980.
22. Bajc M, Neilly JB, Miniati M, Schuemichen C, Meignan M, Jonson B, EANM Committee. EANM guidelines for ventilation/perfusion scintigraphy : Part 1. Pulmonary imaging with ventilation/perfusion single photon emission tomography. *Eur. J. Nucl. Med. Mol. Imaging* 2009. p. 1356–1370.
 23. Johns CS, Swift AJ, Rajaram S, Hughes PJC, Capener DJ, Kiely DG, Wild JM. Lung perfusion: MRI vs. SPECT for screening in suspected chronic thromboembolic pulmonary hypertension. *J Magn Reson Imaging* 2017; 46: 1693–1697.
 24. Dong C, Zhou M, Liu D, Long X, Guo T, Kong X. Diagnostic accuracy of computed tomography for chronic thromboembolic pulmonary hypertension: a systematic review and meta-analysis. *PLoS ONE* Public Library of Science; 2015; 10: e0126985.
 25. Ley S, Ley-Zaporozhan J, Pitton MB, Schneider J, Wirth GM, Mayer E, Düber C, Kreitner K-F. Diagnostic performance of state-of-the-art imaging techniques for morphological assessment of vascular abnormalities in patients with chronic thromboembolic pulmonary hypertension (CTEPH). *Eur Radiol* Springer-Verlag; 2012; 22: 607–616.