Journal Pre-proof



Navigation assisted removal of a broken cannulated sacroiliac screw: a technical note

Michiel HERTELEER

PII: S0020-1383(23)00109-2
DOI: https://doi.org/10.1016/j.injury.2023.02.012
Reference: JINJ 10629

To appear in: *Injury*

Accepted date: 5 February 2023

Please cite this article as: Michiel HERTELEER , Navigation assisted removal of a broken cannulated sacroiliac screw: a technical note, *Injury* (2023), doi: https://doi.org/10.1016/j.injury.2023.02.012

This is a PDF file of an article that has undergone enhancements after acceptance, such as the addition of a cover page and metadata, and formatting for readability, but it is not yet the definitive version of record. This version will undergo additional copyediting, typesetting and review before it is published in its final form, but we are providing this version to give early visibility of the article. Please note that, during the production process, errors may be discovered which could affect the content, and all legal disclaimers that apply to the journal pertain.

© 2023 Published by Elsevier Ltd.

Journal Pre-proof

Navigation assisted removal of a broken cannulated sacroiliac screw: a technical note.

Author:

Michiel HERTELEER, MD PhD FEBS

Department of Trauma Surgery, University Hospitals Leuven, Herestraat 49, 3000 Leuven, Belgium

Michiel.herteleer@uzleuven.be

This is the corresponding author

Keywords: Navigation, screw removal, failure, sacroiliac screw, non-union, pelvic fracture

Summary

Non-union of displaced pelvic ring injuries are challenging to treat. In cases where a previous osteosynthesis has failed it can be challenging to remove the previous implant. This technical note presents a technique for the removal of a broken SI screw in the sacrum. It is a navigation assisted technique that allows for minimal invasive screw remnant removal so that the sacral corridors remain available for later reconstruction.

Introduction

Between 6 and 11% of high energy pelvic ring injuries are vertical shear injuries.[1,2] Fixation failure is not uncommon after these injuries and this especially the case in patients with vertical sacral fractures. [3] Even when solitary transsacral screws are used, screw bending and fixation failure is not uncommon. [4] Further conservative management of these failures have a high risk of leading to non-union and remaining pelvic ring deformities. Treatment of these complications can result in pain relief as much as 93% and a patient satisfaction of 79%. [5] These reconstructions are challenging and can be complicated by broken screws. Broken screws in the sacral region are rare but can hypothecate revision strategies when the sacral corridors are blocked, especially when the revision strategy consists of using transsacral fixation methods.[6–8] Navigation allows to precisely drill holes in the sacral region.[9] In this article we describe a technique to remove a remnant of a broken iliosacral screw that is positioned in de S1 corridor with the tip in the sacral promontorium.

Patient and methods

Our patient is a 69 year old man with a non-union of a vertical shear injury. The injury occurred after a fall from height and was stabilized elsewhere with a single sacro-iliac screw posterior and an external fixator anteriorly. The patient was referred 2 years after the initial stabilization to our clinic with severe pain in the left hemipelvis. The pain was predominantly present in the left sacral region and he could walk short distances with a cane. There were no urological or neurological abnormalities. A conventional X-ray confirmed the diagnosis of a non-union with screw failure and

the CT scan showed that the distal part of the SI screw blocked the transsacral corridor at the level of S1. (Figures 1 & 2).

Surgical Technique

After general anesthesia the patient was positioned prone on a radiolucent table and fluoroscopic imaging was performed from the contralateral side. A 1cm skin incision was made over the contralateral side at the level of the posterior superior iliac spine (PSIS) and dissection was done until there was direct bone contact. The navigation star (Pulse, NuVasive, San Diego, CA, USA) was placed in to the PSIS and a cone beam CT using the Cios Spin fluoroscopy (Siemens Healthineers, Erlangen, Germany) was made of the sacral region.

The proximal part of the cannulated screw and washer were removed using the conventional screw and washer removal technique.

The navigated instruments (pointer and navigated drill) are calibrated with the CT images and the correct calibration was verified. When placing the tip of the pointer or navigated in the field we get an axial-like and coronal-like CT image that is dependent on the position and orientation of the pointer. This allows us to align to pointer in such a way that the entire length of the screw remnant can be seen in both planes. This means that the pointer or navigated drill is perfectly in line with the navigated screw. Furthermore, the navigation has to option to simulate the drill trajectory and direction on the axial-like and coronal-like images to make sure that the orientation is correctly. The orientation and position was verified by taking a fluoroscopy view with the navigated drill positioned against the bone and oriented along the screw axis.

For the removal of the broken screw part that was positioned in the promontorium of the sacrum we placed a navigated pointer on the skin until the pointer trajectory was in line with the broken screw part. This was done to determine the skin incision site. Then, a 4.0 mm, navigated drill (Nuvasive) was positioned so that it was perfectly aligned with the broken screw part. A 4.0 mm hole was drilled until there was contact with the broken screw. (Figure 3) The drill was removed and through this trajectory a conventional 2,8mm threaded guide wire (DePuy Synthes, Raynham, MA, USA) was placed and advanced in to the 7,3mm screw remnant. Then, the threaded guide wire was overdrilled using a 5.0mm canulated drill bit. The 2,8mm threaded guide wire was removed and replaced by a 3.0 mm stainless steel Steinman pin. A first attempt was made to cold weld the Steinmann pin into the cannulated screw by gently hammering the pin in to the cannulated hole. This was done under a conventional fluoroscopic inlet view to make sure that there was no ventral migration of the cannulated screw. A universal chuck was mounted on the end of the Steinmann pin and an attempt was made to extract the screw by turning it counter clockwise. This was unsuccessful and the Steinman pin came loose.

During the second attempt the Steinman pin was repositioned in the exact same manner in the cannulated screw and gently hammered in under a fluoroscopic pelvic inlet view. The screw was then turned clockwise under fluoroscopic guidance and it was noted that screw slightly progressed ventrally. Using the Monoblock flexible reamers (Depuy Synthes) the 3.0 Steinman pin was overdrilled and the canal was reamed until a diameter of 7,5mm. The canulated screw could then be removed by turning it counter clockwise.

Journal Pre-proof

Using this technique the broken, the displaced cannulated screw could be removed successfully in a safe and minimally invasive manner. The pelvic reconstructive surgery was continued with the use of transiliac-transsacral bar and SI screw at the level of S1.

Discussion

Hardware removal can be challenging and different techniques have been described to deal with this.[10] To our knowledge this is de first description of a minimally invasive technique to remove broken cannulated screws from a sacrum.

The technique described in this article is a modification of the Steinmann pin technique as described by Moehring et al.[11] In its original article it is described for the removal of cannulated screws with a broken screw head that were placed in the proximal femur. There are some important differences between the described technique by Moehring and our technique in the sacrum.

The original technique was described for intact screws, this makes the cold welding when progressing the Steinman Pin in to the screw slightly less dangerous as the screwhead still keeps contact on the outer cortex of the bone which could prevent progression of the screw.

We chose to use a navigated drill to create a trajectory that was perfectly in-line with the broken screw trajectory. We considered this as mandatory given the need to gently cold-weld the Steinman pin in the screw and prevent further ventral screw migration. As the screw broke at the level of the non-union and was flush with the sclerotic border of the non-united sacrum we assumed it could be difficult to place a threaded guide pin in to the screw. We assume that it was also this sclerotic border that made it difficult to return the screw counter-clockwise as the back and of the screw has no cutting properties, unlike the screw tip. This sclerotic border was removed after progressing the screw anteriorly in a clockwise fashion with the Stineman pin and using the monoblock flexible reamers that allow for narrow diameter reaming past the sclerotic border.

Although we had an uneventful screw removal we could imagine that there are some risks related to this technique. First, the navigated screw trajectory that needs to be drilled needs to perfectly in line with the screw remnant. If it is not, it could be impossible to place a Steinmann pin in the screw. We would therefore recommend that if a procedure like this would be repeated by one of our readers, that it needs to be done by someone who is experienced with the conventional use of navigated drills in for example spine surgery. Secondly, the cold welding of the Steinmann pin in to the cannulated screw is potentially dangerous as it might progress the screw forward, through the Promontorium in to the abdomen or sacral nerve roots. It could become unretrievable and positioned in a harmful location. This is why we carefully monitored this under fluoroscopy while hammering the Steinmann pin in. Third, the use of the monobloc flexible reamer allowed us to make just-large-enough trajectory. A conventional reamer for the tibia or femur would have potentially destroyed to much bone in the sacrum or damaged the sacral nerve roots. And lastly, in case the screw remnant could not be removed it is important to have a back-up plan. Our back-up plan was to do a lumbo-pelvic fixation in which case we would no need to place a transsacral fixation.

To our knowledge, this is the first description of the removal of broken sacro-iliac screws. The use of navigated drills allow us to improve minimally invasive surgical techniques. Due the removal of the screw, the transsacral corridor in S1 was available and could be used for screw or transsacral bar placement after during the reduction and fixation of the non-union.

Journal Pre-proof

Figures



Figure 1: Convential AP X-ray of the pelvis showing a non-union of a vertical shear fracture. The screw is broken and the distal part of the screw is positioned in the promontorium.

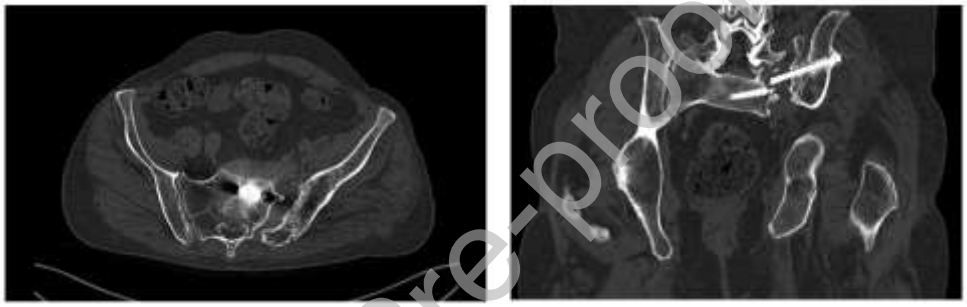

Figure 2: CT scan of the pelvis showing the position of the screw in relation to the S1 corridor. The screw blocks the S1 corridor in both the axial and coronal CT images. Both screw parts are not aligned with each other.

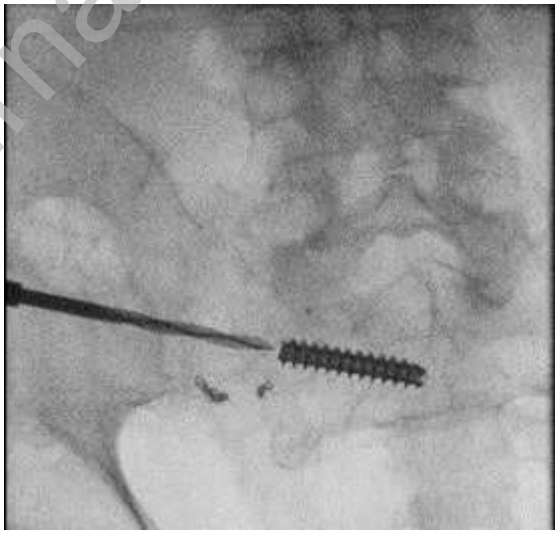

Figure 3: The navigated 4.0mm navigated drill is placed perfectly in line with the broken screw remnant and a hole is drilled in line with the screw.

Journal Pre-proof

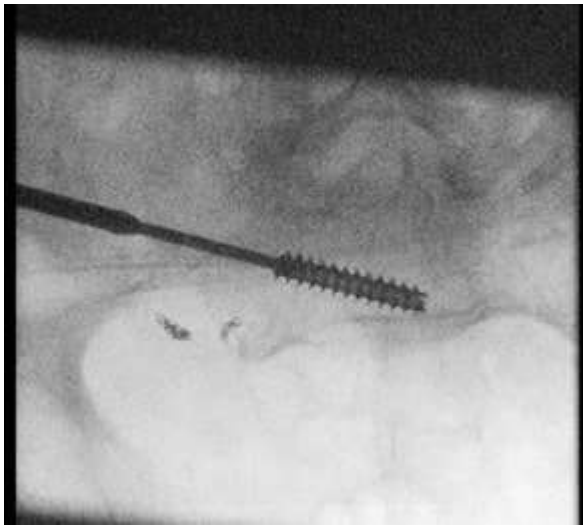

Figure 4: The screw remnant with the 3.0mm Steinman pin cold-welded into it and the Monoblock flexible reamer that is used to ream a 7,5mm canal over the trajectory.



Figure 5: The extracted screw on the 3.0mm Steinman pin on the universal T-handle chuck.

References

[1] Young JWR, Burgess AR, Brumback RJ, Poka A. Pelvic fractures: Value of plain radiography in early assessment and management. Radiology 1986;160:445–51. https://doi.org/10.1148/radiology.160.2.3726125.

[2] Villiger K, Meier MK, Hasler RM, Bastian JD, Tannast M, Exadaktylos AK, et al. Demographic changes in pelvic fracture patterns at a Swiss academic trauma center from 2007 to 2017. J Trauma Acute Care Surg 2022;92:862–72. https://doi.org/10.1097/TA.0000000000003398.

[3] Griffin DR, Starr AJ, Reinert CM, Jones AL, Whitlock S. Vertically unstable pelvic fractures fixed with percutaneous iliosacral screws: does posterior injury pattern predict fixation failure? J Orthop Trauma 2003;17:399–405. https://doi.org/10.1097/00005131-200307000-00001.

[4] Tisano BK, Kelly DP, Starr AJ, Sathy AK. Vertical shear pelvic ring injuries: do transsacral screws prevent fixation failure? OTA Int 2020;3:e084. https://doi.org/10.1097/OI9.0000000000000084.

[5] Kanakaris NK, Angoules AG, Nikolaou VS, Kontakis G, Giannoudis P v. Treatment and outcomes of pelvic malunions and nonunions: A systematic review. Clin Orthop Relat Res 2009;467:2112–24. https://doi.org/10.1007/s11999-009-0712-2.

[6] Gautier E, Rommens PM, Matta JM. Late reconstruction after pelvic ring injuries. Injury 1996;27:39–46. https://doi.org/10.1016/S0002-9378(15)33151-3.

[7] Wagner D, Kamer L, Rommens PM, Sawaguchi T, Richards RG, Noser H. 3D statistical modeling techniques to investigate the anatomy of the sacrum, its bone mass distribution, and the trans-sacral corridors. J Orthop Res 2014;32:1543–8. https://doi.org/10.1002/jor.22667.

Journal Pre-proof

[8] Vanderschot P, Daenens K, Broos P. Surgical treatment of post-traumatic pelvic deformities. Injury 1998;29:19–22. https://doi.org/10.1016/s0020-1383(97)00111-3.

[9] Boudissa M, Carmagnac D, Kerschbaumer G, Ruatti S, Tonetti J. Screw misplacement in percutaneous posterior pelvic iliosacral screwing with and without navigation: A prospective clinical study of 174 screws in 127 patients. Orthop Traumatol Surg Res 2022;108. https://doi.org/10.1016/J.OTSR.2022.103213.

[10] Hak DJ, McElvany M. Removal of broken hardware. J Am Acad Orthop Surg 2008;16:113–20. https://doi.org/10.5435/00124635-200802000-00009.

[11] Moehring HD, Althausen PL, Lindholm SR. Technique for removal of cannulated screws. J Orthop Trauma 2005;19:280–1. https://doi.org/10.1097/01.bot.0000137865.02582.c3.

Journal Pre-proof