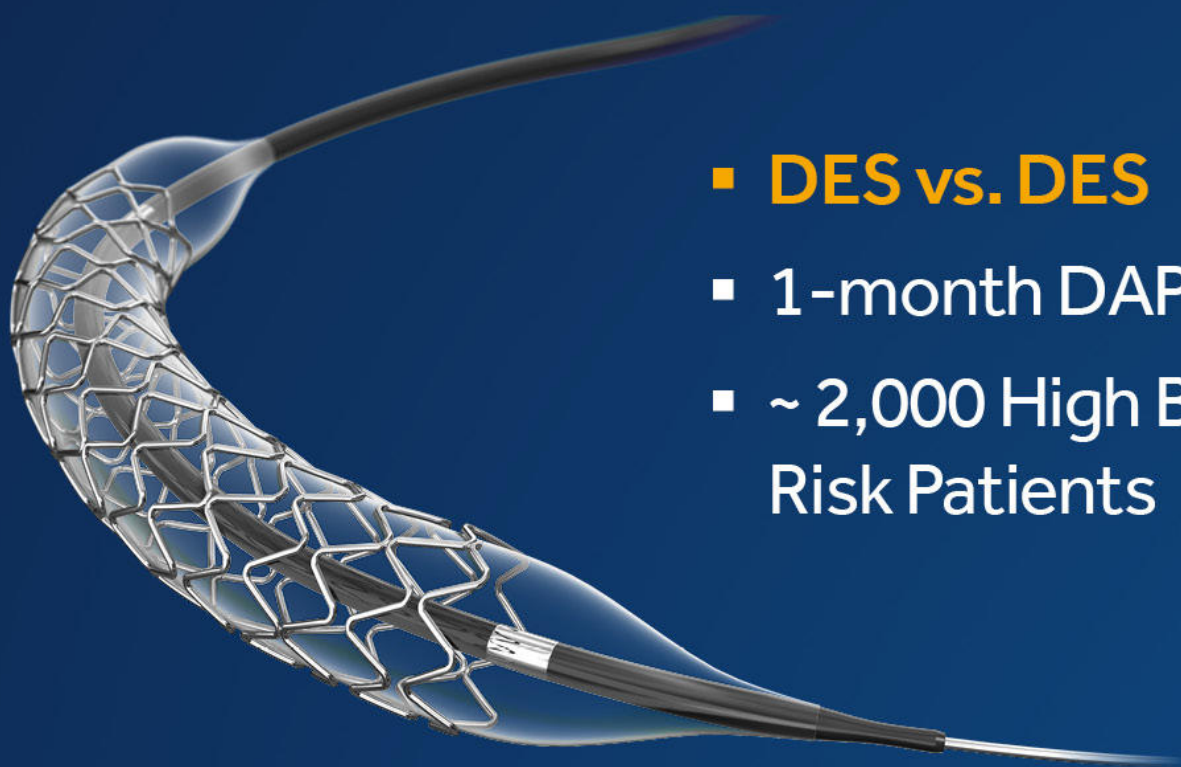

ONYX ONE GLOBAL STUDY



- **DES vs. DES**
- 1-month DAPT
- ~ 2,000 High Bleeding Risk Patients

[VIEW THE RESULTS](#)

Medtronic

Transventricular Balloon Dilation and Stenting of the RVOT in Small Infants With Tetralogy of Fallot With Pulmonary Atresia

Bjorn Cools,¹ MD, Derize Boshoff,¹ MD, PhD, Ruth Heying,¹ MD, PhD, Filip Rega,² MD, PhD, Bart Meyns,² MD, PhD, and Marc Gewillig,^{1*} MD, PhD

Introduction: The management of small infants with tetralogy of Fallot (TOF) with pulmonary atresia (PA) and hypoplastic pulmonary arteries can be very challenging. **Methods:** In three small infants (weight range 2,200–3,600 g, pulmonary trunk 2.0–3.2 mm), initial palliation consisted of sternotomy, transventricular puncture of the right ventricular outflow tract and atretic pulmonary valve, followed by balloon dilation ($n = 1$) or stent deployment ($n = 2$) from the right ventricle into the pulmonary trunk (stent diameter 5–6 mm, length 16 mm). **Results:** The procedure resulted in adequate palliation with good anterograde flow to the pulmonary arteries and near normal saturations in all three patients (>92%); there was no associated morbidity. Additional transvenous stenting was required in all patients because of progressive muscular infundibular stenosis after a median of 3 months. Two patients evolved to full repair at the age of 5 months and one patient with multiple hilar stenoses requires additional percutaneous procedures through the stented RV outflow tract. **Conclusion:** Transventricular balloon dilation and stenting of the RVOT through medial sternotomy as initial palliation strategy appears a safe and well tolerated alternative treatment in small infants with TOF with PA and a hypoplastic pulmonary trunk. © 2013 Wiley Periodicals, Inc.

Key words: congenital heart disease; hybrid procedure; palliation; stenting; transventricular; perventricular; tetralogy of Fallot; pulmonary atresia; premature infant; small infant

INTRODUCTION

Patients with tetralogy of Fallot (TOF) with pulmonary atresia (PA) and severely hypoplastic pulmonary arteries need an intervention in the neonatal period to relieve cyanosis and to enhance catch-up growth of the pulmonary arteries. In case of an adequate weight and pulmonary artery size, primary surgical correction is the preferred option [1–6]. Neonatal surgical correction with a transannular patch or a right ventricular to pulmonary artery conduit can be associated with high morbidity [7–9]. These techniques require cardiopulmonary bypass which is poorly tolerated by premature and very small infants.

In many cases, the pulmonary arteries are diminutive and therefore a staged approach is preferable [1–6]. For years, a surgical aorto-pulmonary shunt was the first palliative step in these patients [10]. Stenting of the arterial duct and radiofrequency perforation of the atretic segment are non-surgical alternatives, but may be particularly challenging [11–13].

The evolution of hybrid techniques has broadened the horizon in treating patients with complex congeni-

tal heart disease. We report hybrid interventions in three small infants using a combination of two techniques: a controlled and safe perforation of the atretic outflow tract by transventricular puncture, followed by transluminal balloon dilation in 1 patient and stenting of the RVOT in two patients.

¹Paediatric and Congenital Cardiology, UZ Leuven, Herestraat 49, 3000 Leuven, Belgium

²Paediatric and Congenital Cardiothoracic Surgery, UZ Leuven, Herestraat 49, 3000 Leuven, Belgium

Conflict of interest: Nothing to report.

*Correspondence to: Marc Gewillig, MD, PhD, Paediatric and Congenital Cardiology, UZ Leuven, Herestraat 49, 3000 Leuven, Belgium. E-mail: marc.gewillig@uzleuven.be

Received 14 October 2011; Revision accepted 27 June 2012

DOI 10.1002/ccd.24548

Published online 5 April 2013 in Wiley Online Library (wileyonlinelibrary.com)

PATIENTS

Three low birth weight infants with TOF, PA, and severely hypoplastic pulmonary arteries were selected for hybrid intervention (Table I). Patient 1 (2,660 g, gestation 37 weeks) underwent catheterization postnatally on day 3. Angiography revealed absence of any arterial duct, complex pulmonary perfusion via atypical aorto-pulmonary collaterals and minute, but confluent central pulmonary arteries (trunk: 2 mm). Patient 2 (1,620 g, gestation 33 weeks) and 3 (2,190 g, gestation 39 weeks) presented with duct dependent flow to hypoplastic, confluent central pulmonary arteries (trunk 2.5 and 3.2 mm measured on echography). Prostaglandines were maintained for 43 and 22 days, respectively. In all three patients, the infundibular atresia was discrete and theoretically allowed direct “intracardiac” connection between the RV infundibulum and the pulmonary trunk. The weight at procedure varied from 2,200 to 3,600 g.

METHODS

All procedures were performed according to the guidelines of the local ethics committee; informed consent was obtained from the parents. The procedures were performed in a hybrid surgical suite with high resolution single plane fluoroscopy. Access was provided through medial sternotomy. In order to minimize the intravascular procedure time, all materials were prepared: a 4 French (F) introducer sheath, 2 identical needles: 21 Gauge, 4 cm length (COOK® Medical Europe, Denmark), a 0.014" short tipped stiff coronary guide wire shortened to about 100 cm, a coronary stent (2 mm larger than the pulmonary trunk, length from 2 mm above the valve until well within the right ventricular lumen), an inflator, 10 cc syringes with flush-saline and contrast, vascular clips, 6.0 prolene. The puncture site on the right ventricular anterior wall was determined by laying the premounted stent on the epicardium (Fig. 1A); a purse string with 6.0 prolene was created as apical as possible in order to deploy the stent from just above the pulmonary valve until well within the right ventricle; options are however limited due to the coronary anatomy. Two vascular clips were placed: one at the pulmonary valve annulus, and one at the puncture site within the purse string.

Three operators or five coordinated hands are required to perform the procedure: one hand (with radioprotective glove) must stabilize the sheath throughout the procedure, the second pair of hands performs the puncture and leads the manipulations at the level of the sheath and contrast hand injections, and

TABLE I. Patients and Procedure Characteristics

	Patient 1	Patient 2	Patient 3
Birth weight (g)	2630	1620	2190
Gestational age (weeks)	37	33	39
Saturation (%)	85	80	90
No. days prostaglandin	–	43	22
Pulmonary trunc diameter (mm)	2,0	2,5	3,2
PA branches diameter L–R (mm)	2–2	3–3	3.0–3.5
distance RVOT	5	6	5
Age at procedure (days)	59	43	22
Weight at procedure (g)	3,600	2,460	2,200
Fluoro time (min)	4	4	4
Radiation dose (cGy/cm ²)	220	250	200
stent diameter/length	7/19	5.5/16	5.3/16
age at 2nd stent (days)	184	57	99
2 nd stent type	12/29 mm	5/16 mm	7/18 mm
Age at full repair (months)	–	5	5
Weight at full repair (g)	–	5.4	5.6

the third pair controls the wire, mounts the stent on the wire and inflates the balloon.

Two identical 21 gauge needles were used. One needle was used as a reference adjacent on the surface of the RVOT to determine precise puncture depth and direction; the other needle was used to perform the puncture. The puncture was performed under direct vision in two motions: first access perpendicular to the surface for 10–15 mm into the right ventricular cavity with free blood, second angulation of the needle toward and advancement through the atretic outflow tract into the pulmonary trunk. A 0.014" coronary guide wire was advanced blindly through the needle into the pulmonary artery. At that point, the C-arm was positioned above the thorax, and wire position was confirmed with fluoroscopy; the wire was repositioned if required (Fig. 1B). The C-arm was tilted about 20° cranially to “open” the surgical field and to create a view perpendicular to the RV outflow tract. The needle was exchanged for a 4 French introducer sheath. The dilator of the sheath was used to further dilate the valve (position revealed by the vascular clip), with subsequent advancement of the sheath just into the pulmonary arterial trunk. The dilator was removed, and a hand angiogram was performed through the sheath (Fig. 1C) to confirm wire position distally in the pulmonary artery and to determine the exact projection relationship of the vascular clip to the atretic pulmonary valve (clip typically just cranial of the atretic valve). The stent was subsequently advanced with the distal end just reaching the pulmonary trunk (typically projecting at the level of the vascular clip), leaving most of the stent in the right ventricle (Fig. 1D). When uncovering the stent, the 2nd vascular clip at the entry point allowed assessment of residual sheath depth

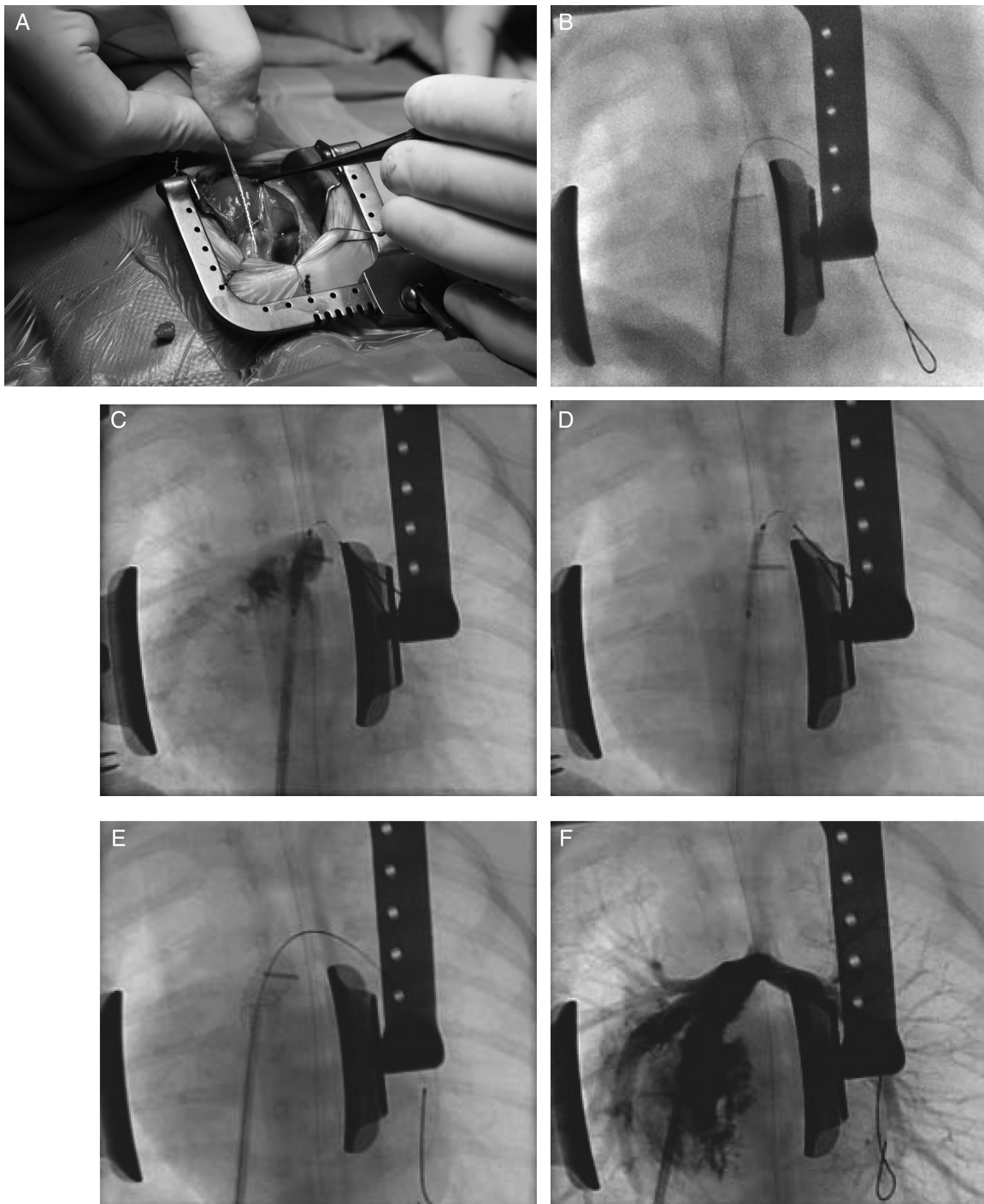


Fig. 1. A: Open sternum, vascular clip at PV annulus. Pre-mounted stent projecting along the RVOT for determining entry point in the RV cavity. B: Radioscopic view, mild cranial tilt. Vascular clip at level of atretic pulmonary valve. Needle in RVOT with 0.014" wire into the left pulmonary artery. C: 4 Fr sheath in RVOT over 0.014" wire, positioning pre-mounted coronary stent. Observe relationship between clip and atretic

valve. D: Withdrawal of sheath to uncover stent, distal end of stent at the vascular clip; stent too distal and was withdrawn before inflation. E: Stent deployed in RVOT with distal part just across the pulmonary valve (vascular clip). F: Angiogram through 4Fr sheath in RV outflow: nice antegrade flow to pulmonary branches.

within the right ventricle. The stent was dilated up to at least nominal pressure using an inflator (Fig. 1E). In case of insufficient increase of arterial saturation or

suboptimal stenting angiographically (Fig. 1F), additional dilation or stenting could be performed. The sheath was removed and the purse string closed.

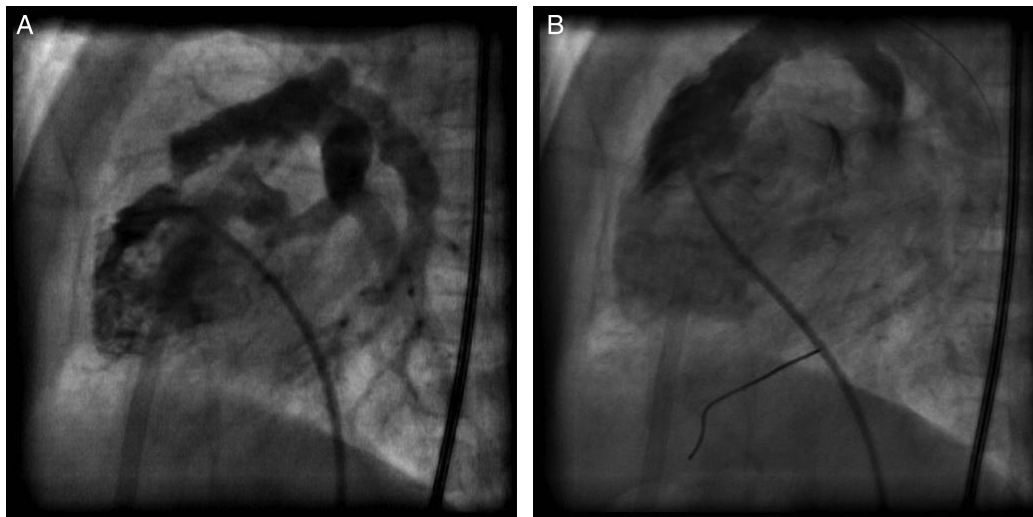

Fig. 2. Percutaneous restent procedure in patient 3 at 3 months. **A:** RV angiogram showing severe dynamic muscular stenosis proximal of stent in RVOT; **(B)** RV angiogram showing relief of the infundibular stenosis after restenting.

Prostaglandin infusion was discontinued, if given. The vascular clips were removed and the sternum was closed.

RESULTS

All punctures from the right ventricle into the pulmonary trunk were successful from a single ventricular puncture; no “fausse route” was created in any patient. In the first patient we initially only performed a balloon dilation (4mm Tyshak® Mini, NuMed, USA) as this was believed to be sufficient (type Brock procedure). However, restenosis occurred and a PG1910 Cordis Genesis® stent (Europe, Roden, The Netherlands) was implanted transvenously through a 6F sheath 4 months later. In patients 2 and 3, a 5/16 mm coronary stent (Liberté Monorail®, Nanterre Cedex, France) was successfully implanted. Time from puncture to sheath withdrawal was less than 10 min. Blood loss was minimal; none of the patients required a transfusion. No ECG changes suggestive for coronary compression were observed. All patients had an increase in saturation above 92%.

The patients remained hemodynamically stable throughout the procedure and could be extubated within 48 hr.

Complications: Early

Patient 2 suffered a sudden desaturation while advancing the needle; immediate completion of the procedure with deployment of stent resolved the problem (lowest saturation level was 55%, comparable to that of a difficult surgical shunt). An angiogram

showed spasm of the arterial duct and the proximal left pulmonary artery, probably triggered by the needle which in retrospect was inserted too deep; this illustrates the need for the “double needle technique.”

Complications: Late

No stent fracture or stent recompression was observed. All three patients developed a progressive infundibular (muscular) stenosis at the proximal end of the stent for which reintervention was indicated (15 months after transvenous stent implantation in patient 1; 1 week and 2 months after stent implantation in patients 2 and 3, respectively). The muscular stenosis was treated by restenting the outflow tract, with the stent covering the muscular band proximally and extending telescopically well into the prior stent [patient 1: Advanta® 12/29 mm covered stent inflated manually at valvular level up to 9 mm (Atrium Europe, Mijdrecht, The Netherlands); patient 2: 5/16 mm Liberté Monorail® (Nanterre Cedex, France); patient 3: 7/18 mm (Cordis® Europe, Roden, The Netherlands)] (Fig. 2). In all three patients saturations increased to above 92%.

Late Outcome

The central pulmonary arteries in patient 1 have shown substantial growth since birth, but peripheral multiple hilar stenoses persist, despite good pulsatile antegrade flow. This patient is planned in due course for multiple transvenous interventions with high pressure balloons, cutting balloons and stenting if indicated. The muscular stenosis was treated with a covered stent as “tearing” of the pulmonary annulus by a

future balloon dilation was expected. Patients 2 and 3 underwent surgical repair at the age of 5 months. The RVOT was opened and the stents were cut longitudinally with regular scissors. The stents were firmly attached to the outflow tract according to the surgeon, but could be removed completely, followed by infundibular resection and repair with a transannular patch.

DISCUSSION

The management of infants with TOF with pulmonary valve atresia remains challenging. Neonatal intervention at a very early age and/or a low weight is usually unavoidable. In case of severely hypoplastic pulmonary arteries a staged approach is preferred to allow pulmonary arterial growth [2,9]. Prolonged intravenous administration of prostaglandin is not without morbidity. Ductal stenting has become a good alternative for the initial palliation, but unfavorable ductal anatomy (long and tortuous; vertical origin from the inner arch) is rather the rule than the exception in this subgroup of patients, often necessitating unusual arterial access and multiple manipulations, increasing procedural time and complications (ductal spasm, incomplete stenting, and access problems) [11,12]. Percutaneous radiofrequency perforation of the pulmonary valve has been reported, but the risk of perforation is particularly high in case of long segment (muscular) atresia and in very small infants [13]. Conventional palliative treatment consists of the surgical creation of a systemic-to-pulmonary shunt (modified Blalock-Taussig or central shunt) [8–10]. Such surgery in low birth weight infants with diminutive pulmonary arteries can involve major complications such as early or late shunt occlusion, kinking or stenosis, distortion and differential growth of the pulmonary arteries, pulmonary overcirculation, chylothorax, phrenic, and vagal nerve palsy [3,7]. Other surgical options are creating a ventricular-arterial connection using a Sano-shunt or a transannular patch. Both procedures however require cardiopulmonary bypass which is poorly tolerated in the very small and premature infants [1–9,13].

We report on hybrid interventions to get adequate palliation: the surgeon provided access for accurate and safe transventricular puncture of the atretic valve without cardiopulmonary bypass, followed by transluminal stenting of the outflow tract, allowing adequate pulsatile antegrade flow with desaturated blood. This procedure can be considered a combination of an “upgraded” Brock procedure with an intracardiac Sano-type shunt (without cardiopulmonary bypass). A duct-shunted patient is thereby converted into a more “conventional” Fallot with pulmonary stenosis allow-

ing antegrade pulsatile flow of desaturated blood into the pulmonary artery (“the better” shunt) [14,15].

The transluminal stent delineates an end-to-end anastomosis with minimal distortion. Such stent can be dilated to augment pulmonary flow during somatic growth, and provides easy access for transcatheter interventions if indicated.

We applied this technique in three high risk patients (low birth weight, diminutive pulmonary arteries) in whom significant morbidity could be anticipated using conventional strategies. The puncture of the atretic outflow tract from ventricular access is the most critical maneuver of the procedure due to the risk of creating a “fausse route.” In all three patients the pulmonary trunk could easily be entered. If a “fausse route” had been created, the surgeon would probably be able to control any hemorrhage. This would certainly not be the case if the same complication occurred during a transluminal radiofrequency ablation or closed puncture technique.

The sternotomy proved to be a safe and well tolerated maneuver even in premature infants avoiding problems with adequate vascular access (axillary or carotid). A sternotomy is better tolerated than a thoracotomy, as this involves a perioperative collapse of the lung which can be problematic in an already cyanotic patient.

Performing transluminal procedures in a hybrid suite in an open chest creates a new environment with new challenges but also new opportunities. Problems are extreme proximity of the interventionalist’s hands to radiation, less stability of the sheath with a “crowded” operation field, loss of typical radiologic landmarks. Advantages are the much higher limit of sheath size, the possibility to control a perforation or tear of the cardiovascular wall, the possibility to re-crimp a stent if required, the use of vascular clips as landmarks making the procedure safer and faster, and limiting the use of fluoroscopy and contrast.

Deployment of a stent in the right ventricular outflow tract might compress a coronary artery; this is a known complication in older patients during percutaneous stenting [7,16–18]. These two stenting techniques however are distinctively different: stents used in neonates are small and expansion in the surrounding tissues is more symmetrical and therefore minimal in any direction; in contrast, stents used during percutaneous revalvulation are larger and expansion (tear of the graft) typically occurs asymmetrically and excessively in one direction. If coronary compression would happen during the procedure, the interventionalist can re-crimp the stent if necessary. Covered stents were not used as there was tissue continuity from the right ventricle to the pulmonary artery [19].

The chosen stent diameter was 2 mm larger than the pulmonary trunk as the risk of “overstretching” and tearing such neonatal pulmonary artery is small [20].

In all three patients a reconfiguration of the RVOT with progressive subpulmonary stenosis occurred with a wide range of time intervals from 5 days up to 13 months. The trend of the infundibulum to gradually “close off” (fetally and postnatally) in this type of congenital malformation has also been reported by other investigators [7]; it may be part of the natural course, but may also be related to the technique. The need for a second stent to treat the infundibular stenosis might be prevented or postponed by adapting the puncture technique (two motions thereby orientating the stent away from anterior wall), or by using a longer stent initially with maximal protrusion into the RV cavity.

This procedure was in all three patients well tolerated and safe with futile morbidity. We expect this technique to compare very well with more “conventional” shunts, and we now will consider this technique also for larger infants who require a palliative procedure.

CONCLUSION

In this small group of patients, transventricular stenting of the RVOT through medial sternotomy appears to be a safe and well tolerated initial palliation. This technique might in future compare well with conventional strategies as initial palliation in infants with TOF with PA and hypoplastic pulmonary arteries.

REFERENCES

1. Uva MS, Lacour-Gayet F, Komiya T, Serraf A, Bruniaux J, Touchot A, Roux D, Petiti J, Planché C. Surgery for tetralogy of Fallot at less than six months of age. *J Thorac Cardiovasc Surg* 1994;107:1291–1300.
2. Marshall AC, Love BA, Lang P, Jonas RA, del Nido PJ, Mayer JE, Lock JE. Staged repair of tetralogy of Fallot and diminutive pulmonary arteries with a fenestrated septal defect patch. *J Thorac Cardiovasc Surg* 2003;126:1427–1433.
3. Dodge-Khatami A, Tulevski II, Hitchcock JF, de Mol BA, Benink GB. Neonatal complete correction of tetralogy of Fallot versus shunting and deferred repair: Is the future of the right ventriculo-arterial junction at stake, and what of? *Cardiol Young* 2001;11:484–490.
4. Cobanoglu A, Schultz JM. Total correction of tetralogy of Fallot in the first year of life: Late results. *Ann Thorac Surg* 2002;74:133–138.

5. Pagani FD, Cheatham JP, Beekman RH, Lloyd TR, Mosca RS, Bove EL. The management of tetralogy of Fallot with pulmonary atresia and diminutive pulmonary arteries. *J Thorac Cardiovasc Surg* 1995;110:1521–1533.
6. Pigula FA, Khalil PN, Mayer JE, del Nido PJ, Jonas RA. Repair of tetralogy of Fallot in neonates and young infants. *Circulation* 1999;100 (Suppl II):II157–II161.
7. Dohlen G, Chaturvedi RR, Benson LN, Ozawa A, Van Arsdell GS, Fruitman DS, Lee KJ. Stenting of the right ventricular outflow tract in the symptomatic infant with tetralogy of fallot. *Heart* 2009;95:142–147.
8. Van Arsdell GS, Maharaj GS, Tom J, Rao VK, Coles JG, Freedom RM, Williams WG, McCrindle BW. What is the optimal age for repair of tetralogy of Fallot? *Circulation* 2000;102:123–129.
9. Di Donato RM, Jonas RA, Lang P, Rome JJ, Mayer JE Jr, Castaneda AR. Neonatal repair of tetralogy of Fallot with and without pulmonary atresia. *J Thorac Cardiovasc Surg* 1991;101:126–137.
10. Gladman G, McCrindle BW, Williams WG, Freedom RM, Benson LN. The modified Blalock-Taussig shunt: clinical impact and morbidity in Fallot’s tetralogy in the current era. *J Thorac Cardiovasc Surg* 1997;114:25–30.
11. Gibbs JL, Rothman MT, Rees MR, Parsons JM, Blackburn ME, Ruiz CE. Stenting of the arterial duct: A new approach to palliation for pulmonary atresia. *Br Heart J* 1992;67:240–245.
12. Boshoff DE, Michel-Behnke I, Schranz D, Gewillig M. Stenting the neonatal arterial duct. *Expert Rev Cardiovasc Ther* 2007; 5:893–901.
13. Walsh MA, Lee KJ, Chaturvedi R, Van Arsdell GS, Benson LN. Radiofrequency perforation of the right ventricular outflow tract as a palliative strategy for pulmonary atresia with ventricular septal defect. *Catheter Cardiovasc Interv* 2007;69:1015–1020.
14. Fiore AC, Tobin C, Jureidini S, Rahimi M, Kim ES, Schwenengerdt K. A comparison of the Modified Blalock-Taussig shunt with the right ventricle-to-pulmonary artery conduit. *Ann Thorac Surg* 2011;91:1479–1485.
15. Petrucci O, O’Brien S, Jacobs ML, Jacobs JP, Manning PB, Eghtesady P. Risk factors for mortality and morbidity after the neonatal Blalock-Taussig shunt procedure. *Ann Thorac Surg* 2011;92:642–652.
16. Dryzek P, Mazurek-Kula A, Moszura T, Sysa A. Right ventricle outflow tract stenting as a method of palliative treatment of severe tetralogy of Fallot. *Cardiovasc J* 2008;15:376–379.
17. Gibbs JL, Uzun O, Blackburn ME, Parsons JM, Dickinson DF. Right ventricular outflow stent implantation: An alternative to palliative surgical relief of infundibular pulmonary stenosis. *Heart* 1997;77:176–179.
18. Laudito A, Bandisode VM, Lucas JF, Radtke WA, Adamson WT, Bradley SM. Right ventricular outflow tract stent as a bridge to surgery in a premature infant with tetralogy of Fallot. *Ann Thorac Surg* 2006;81:744–746.
19. Butera G, Abella R, Carminati M, Frigiola A. Periventricular implantation of a right ventricular-to-pulmonary artery ‘conduit’. *Eur Heart J* 2009;30:2078.
20. Brown SC, Boshoff DE, Meyns B, Gewillig M. Sutureless rescue of a severely hypoplastic pulmonary artery. *Eur J Cardiothorac Surg* 2010;37:741–743.