




ELSEVIER

Contents lists available at ScienceDirect

Injury

journal homepage: www.elsevier.com/locate/injury



Review

Definition of infection after fracture fixation: A systematic review of randomized controlled trials to evaluate current practice

W.J. Metsemakers^{a,*}, K. Kortram^b, M. Morgenstern^c, T.F. Moriarty^d, I. Meex^a, R. Kuehl^e, S. Nijs^a, R.G. Richards^d, M. Raschke^f, O. Borens^g, S.L. Kates^h, C. Zalavrasⁱ, P.V. Giannoudis^j, M.H.J. Verhofstad^b

^a Department of Trauma Surgery, University Hospitals Leuven, Belgium

^b Department of Trauma Surgery, Erasmus University Medical Centre, Rotterdam, The Netherlands

^c Department of Orthopaedic and Trauma Surgery, University Hospital of Basel, Switzerland

^d AO Research Institute Davos, Switzerland

^e Division of Infectious Diseases and Hospital Epidemiology, University Hospital of Basel, Switzerland

^f Department of Orthopaedic and Trauma Surgery, University Hospital of Münster, Germany

^g Orthopedic Septic Surgical Unit, Department of the Locomotor Apparatus and Department of Surgery and Anaesthesiology, Lausanne University Hospital, Lausanne, Switzerland

^h Department of Orthopaedic Surgery, Virginia Commonwealth University, USA

ⁱ Department of Orthopaedic Surgery, Keck School of Medicine, University of Southern California, Los Angeles, USA

^j Department of Trauma and Orthopaedic Surgery, University Hospital of Leeds, United Kingdom and NIHR Leeds Biomedical Research Unit, Chapel Allerton Hospital, Leeds, UK

ARTICLE INFO

Keywords:

Definition of infection after fracture fixation
Infectious complications
Internal fracture fixation
Definition
Infection after fracture fixation

ABSTRACT

Introduction: One of the most challenging musculoskeletal complications in modern trauma surgery is infection after fracture fixation (IAFF). Although infections are clinically obvious in many cases, a clear definition of the term IAFF is crucial, not only for the evaluation of published research data but also for the establishment of uniform treatment concepts. The aim of this systematic review was to identify the definitions used in the scientific literature to describe infectious complications after internal fixation of fractures. The hypothesis of this study was that the majority of fracture-related literature do not define IAFF.

Material and methods: A comprehensive search was performed in Embase, Cochrane, Google Scholar, Medline (OvidSP), PubMed publisher and Web-of-Science for randomized controlled trials (RCTs) on fracture fixation. Data were collected on the definition of infectious complications after fracture fixation used in each study. Study selection was accomplished through two phases. During the first phase, titles and abstracts were reviewed for relevance, and the full texts of relevant articles were obtained. During the second phase, full-text articles were reviewed. All definitions were literally extracted and collected in a database. Then, a classification was designed to rate the quality of the description of IAFF.

Results: A total of 100 RCT's were identified in the search. Of 100 studies, only two (2%) cited a validated definition to describe IAFF. In 28 (28%) RCTs, the authors used a self-designed definition. In the other 70 RCTs, (70%) there was no description of a definition in the Methods section, although all of the articles described infections as an outcome parameter in the Results section.

Conclusion: This systematic review shows that IAFF is not defined in a large majority of the fracture-related literature. To our knowledge, this is the first study conducted with the objective to explore this important issue. The lack of a consensus definition remains a problem in current orthopedic trauma research and treatment and this void should be addressed in the near future.

© 2017 Elsevier Ltd. All rights reserved.

* Corresponding author.

E-mail address: willem-jan.metsemakers@uzleuven.be (W. Metsemakers).

Contents

Introduction 00
 Methods 00
 Literature search strategy 00
 Data extraction and critical appraisal 00
 Results 00
 Discussion 00
 Conflict of interest 00
 Acknowledgements 00
 References 00

Introduction

One of the most challenging musculoskeletal complications in orthopaedic trauma surgery is infection after fracture fixation (IAFF). This complication may result in permanent functional loss or even amputation of the affected limb in patients who may otherwise be expected to achieve uneventful healing. Accurately estimating the impact of this fracture related complication has been hampered by the lack of a clear definition [1–3].

In contrast to the situation for periprosthetic joint infection (PJI) [4,5], there is currently no consensus definition for IAFF [6]. Many of the surgical and medical treatment concepts applied to IAFF have been adopted from PJI treatment algorithms. Specific concepts tailored towards the musculoskeletal trauma patient are comparatively scarce. Although, IAFF and PJI do indeed have similar clinical properties, there are important distinctions between the elective arthroplasty patient and the trauma patient in terms of infection susceptibility, diagnostic modalities and treatment options. The Centers for Disease Control (CDC) has published guidelines for surgical site infection (SSI), which distinguish between superficial incisional, deep incisional and organ/space infections [7–9]. However, neither the PJI nor the CDC-guidelines were specifically developed for fracture patients and critical parameters, including presence of the fracture and soft tissue damage, are not covered by these definitions. Probably for the above mentioned reasons, authors of IAFF publications have difficulties defining infection [3]. A definition of IAFF is urgently required to aid evaluation of routine clinical data, as well as aid in the evaluation of published novel research data and to establish uniform treatment concepts.

The aim of this systematic review was to identify the different definitions used to describe infectious complications after fracture fixation in randomized controlled trials (RCTs). The hypothesis was that the majority of fracture-related literature do not define IAFF. Furthermore, we searched for different parameters that were used to diagnose IAFF and could be useful for a possible future consensus definition.

Methods

All relevant aspects of the Cochrane Handbook for Interventional Systematic Reviews were followed and the study was written according to the Preferred Reporting Items for Systematic Reviews and Meta-Analyses (PRISMA) statement [10].

Literature search strategy

A comprehensive search was performed with the help of a biomedical information specialist on January 21st 2016 in Embase, Cochrane, Google Scholar, Medline (OvidSP), PubMed publisher and Web-of-Science. Search strings for each database are provided in Appendix 1. All references were screened by two reviewers (WJM and KK). In case of disagreement, a third reviewer (MV)

would have been consulted, but consensus was reached for every case. Study selection was accomplished through two phases (Fig. 1). During the first phase, titles and abstracts were reviewed for relevance and relevant articles were obtained. Published meeting abstracts for which a full text was not yet published, were excluded in order to prevent bias. During the second phase, full-text articles were reviewed. Table 1 provides an overview of the inclusion and exclusion criteria.

Data extraction and critical appraisal

Data were collected on the definition of infectious complications used in the articles. This was again performed by two reviewers (WJM and KK). First, all definitions were literally extracted and collected in a database. Subsequently, the quality of the description/definition was classified according to:

- a) The authors used a validated definition for IAFF (Table 2)
- b) The authors used a self-designed definition for IAFF
- c) No description of any definition for IAFF was given by the authors

Table 2 shows the definitions that were considered to be validated definitions. The PJI related definitions were not developed for patients with the diagnosis of IAFF. Although, we are aware of the fact that diagnostic criteria for PJI are not optimal for diagnosis of IAFF because of important differences that exist between these two types of infectious complications, our hypothesis was that due to the lack of definitions for IAFF, authors would include PJI related definitions in their publications. Definitions regarding pin track infections were not included.

Results

A total of 100 RCTs were identified in the search (Fig. 1). Of these studies, only two (2%) cited a validated definition for IAFF (as listed in Table 2). Both of these studies described the CDC-guidelines in the Methods section of their paper [11,12]. In 28 (28%) RCTs, the authors used a self-designed definition [13–39]. Table 3 describes different signs and parameters that the authors used in these self-designed definitions of IAFF. In Table 4 the different definitions are cited per author.

In the other 70 RCTs (70%) there was no description of a definition in the Methods section, although all of the articles described infections as an outcome parameter in the Results section [40–109].

When evaluating these papers it was noted that 30 RCTs (43%) used terms such as “superficial skin infection”, “superficial wound infection”, “infection in surgical margins” and “deep infection” [64–76,78,80,82,84–93,102,105–107]. Such terms may be suggestive of the CDC-guidelines, although this could not be confirmed in the text. It has to be stated that terms like superficial and deep infection already existed in the literature prior to the introduction

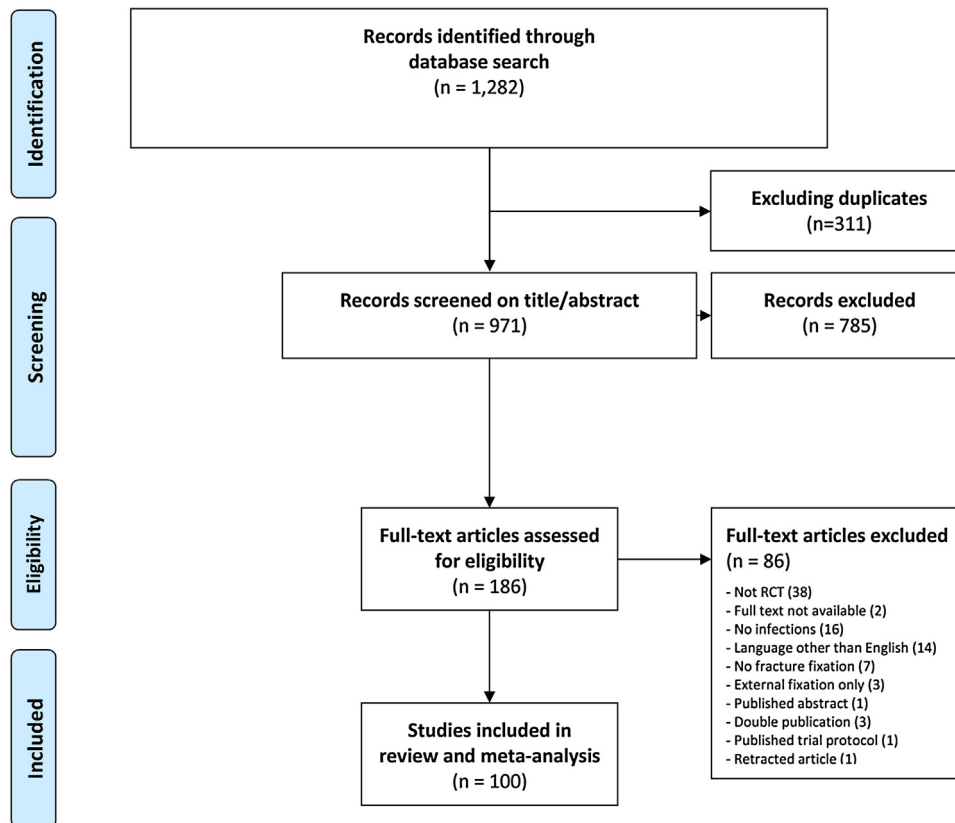


Fig. 1. Outline of the search and selection process including exclusions and final count of acceptable manuscripts. RCT: Randomized Controlled Trial.

by the CDC, proven by two articles included in this group [72,80]. So overall the authors of 28 studies were contacted by email with a request for additional information regarding the exact definition of infection, and their perception of superficial infection, deep infection and other terms described in their papers. More specifically, they asked whether these definitions were based on the CDC-guidelines. The response rate was 25% (7/28). Only one of the authors stated that they used the CDC-guidelines, the others stated that they did not use any specific guideline to describe IAFF.

Discussion

Development of IAFF is one of the most serious complications in musculoskeletal trauma surgery. The consequences for patients

and healthcare systems are severe [2,110]. Accurately estimating the incidence and impact of this complication has been hampered by the lack of a clear definition. In 1996, Arens et al. [3], stated: “It is astonishing that in all papers in which infection is mentioned, the term ‘infection’ is not defined”. The problem becomes clear when reviewing the clinical literature as presented here.

The goal of this systematic review was to perform an exploratory analysis regarding the use of definitions for IAFF in RCTs. The hypothesis was that the majority of included fracture-related RCTs do not clearly define IAFF. We believed that it was not realistic to include every publication regarding fracture care. Consequently, we aimed at high quality publications with an optimal study design, i.e. RCTs. We believed that if these studies did not use a definition, others (i.e. retrospective, etc.) would be even less likely to do so. To our

Table 1

Inclusion and exclusion criteria used during study selection.

Inclusion Criteria	Exclusion Criteria
<ul style="list-style-type: none"> • RCT • Fracture fixation <ul style="list-style-type: none"> -Internal fixation versus external fixation -Internal fixation versus other internal fixation -Internal fixation versus non-operative management • Infections/Infectious complications • Full text written in English • Published between January 1st 1985 and December 31st 2015 	<ul style="list-style-type: none"> • Study design other than RCT • External fixation only • Infections not mentioned as outcome measure or as a detected complication

RCT: Randomized Controlled Trial.

Table 2

List of definitions considered as “validated”.

- CDC-guidelines (superficial incisional, deep incisional and organ/space surgical site infection) [7–9]
- IDSA-guidelines for PJI [5]
- New Definition for PJI: From the Workgroup of the Musculoskeletal Infection Society [4]

CDC: Centers for Disease Control; IDSA Infectious Disease Society of America; PJI: Prosthetic Joint Infection.

Table 3

Parameters used to diagnose and/or define IAFF.

Parameters associated with IAFF	N	Refs.
• Positive cultures	15	[13,15,17–23,27,30,31,33,37,38]
• Clinical signs unspecified	4	[18,25,30,34]
• Purulent drainage (or discharge)	16	[13–17,19,20,22,23,25,27,30,33,34,37,38]
• Fever	3	[17,22,38]
• Rubor (redness)	5	[15,16,37–39]
• Calor (warmth)	4	[15,16,38,39]
• Tumor (swelling)	4	[15,16,33,39]
• Dolor (pain)	2	[16,39]
• Wound dehiscence/breakdown	5	[13,14,27,32,37]
• Need for surgical debridement	5	[23,29,31,32,39]
• Treatment with oral antibiotics	6	[13,24,26,29,32,33]
• Need for implant removal	4	[22,26,28,39]
• Radiological (X-ray) evidence	2	[34,38]
• CRP	1	[18]

CRP: C-reactive protein.

surprise, only 2% of the included RCTs used a validated definition, which in both cases were the CDC-guidelines.

As already mentioned, the CDC-guidelines [9] are currently the only standard definition available for musculoskeletal trauma surgeons [6]. The fact that they are not used routinely in fracture-related studies suggests that they are probably not very suitable in these cases. The CDC divides SSIs into superficial incisional, deep incisional and organ/space infections.

Different objections to the use of the CDC-guidelines in IAFF are offered. First, the CDC defines time-limits for the diagnosis of SSIs: within 30 days after the operation if there is no implant, and within 1 year if there is an implant in place, according to the 1992 guidelines [7]. The recently updated CDC-guidelines define a deep incisional or organ/space SSI after fracture fixation as one occurring within 90 days after the operation [9]. The CDC definitions are used for surveillance and, for practical purposes, limit diagnosis of infection to specific time frames to avoid the burden of additional data collection with potentially low yield. However, in IAFF, some infections will occur outside these time frames (i.e. late-onset infections) [111]; as such the CDC-guidelines do not cover these infections. In general the presence of time frames pose a serious problem from a definition point of view.

A second challenge in IAFF when following the CDC-guidelines emerges in the case of superficial incisional infection. Bonneville et al. already stated that the term ‘superficial infection’ is at best

arbitrary [2]. The depth of bacterial colonization can only be assessed by tissue samples taken under the subcutaneous tissue layer, which means that every wound must be opened because superficial swabs are no longer acceptable for diagnosis [2]. An illustration of this problem is an IAFF of the ankle, where there is minimal subcutaneous tissue. Superficial cultures would require the surgeon to open the surgical wound and both the implant and the fracture site would become visible; this defines a deep infection. Therefore, is it actually possible in all clinical settings to differentiate between these three types of infection (superficial, deep and organ space) and does this change or even influence the clinical treatment algorithm for a patient with IAFF?

In this systematic review none of the included RCTs used the standard definitions for PJI [4,5]. As already mentioned, there are important differences between PJI and IAFF. A first difference is the initial damage to soft tissues overlying the surgical site. An open fracture may for example lead to wound contamination and massive crush injuries can cause a disturbed vascularization with concomitant skin necrosis, both will therefore have an increased susceptibility for infection. A second difference is the presence of a fracture and the need for biomechanical stability in order to heal both – the fracture and the soft tissue. Clinical guidelines highlight the fact that bone and soft tissue stability are important not only for prevention, but also for treatment of IAFF [111–113]. These are both examples of why the use of PJI definitions does not directly

Table 4
Definition for IAFF cited per author.

Self-designed definitions for infection after fracture fixation	Refs.
"Wound infection was defined as spontaneous drainage of pus after suture removal or in association with overt wound dehiscence. If a wound infection was identified in the postoperative period, a swab specimen of the exudate was sent for microscopy, culture, and sensitivity testing to guide subsequent antibiotic therapy."	[13]
"Wound infection was defined as spontaneous drainage of pus after suture removal or in association with overt wound dehiscence."	[14]
"The infections were graded as local or systemic, according to specific criteria. Purulent drainage at the operative site, with positive cultures, represented major infection. Erythema with edema and warmth adjacent to the incision indicated the presence of minor infection."	[15]
"Wound infection was defined as one or more of the classic signs and symptoms of inflammation (rubor, calor, tumor, dolor) together with pus at the operation site. Wound infections were classified as superficial or deep. Infections of the skin and subcutaneous tissue, not communicating with the site of bone operation, were judged as superficial. Deep infections were defined as infections, that by physical examination, reached bone or material inserted for osteosynthesis."	[16]
"Evidence of infection was defined as presence of discharge and constitutional symptoms (fever, malaise and nausea) documented post operatively and confirmed with a wound swab."	[17]
"Clinical signs, CRP, and cultures from the intramedullary canal or tissue adjacent to the bone and deep to the superficial fascia were positive."	[18]
"An infection was considered to be present, whether or not the culture was positive, when pus drained spontaneously from the wound or when the surgeon released purulent material from an inflamed wound."	[19]
"An infection was diagnosed when the wound drained pus spontaneously or was inflamed to the point that it had to be opened by the surgeon and then drained purulent material. A diagnosis of infection was recorded whether or not the culture was positive. A wound with a hematoma or one that drained serous material was considered to be infected only when the culture was positive. In all of the deep infections bone or metal was exposed, and in several a deep tract was demonstrated on a sinogram."	[20]
"Infections were conservatively defined as any suspected or confirmed superficial or deep bone or soft-tissue infection, with or without bacteriological confirmation."	[21]
"Deep infection: Septic fever concomitant to purulent infection affecting the osteosynthesis area eventually necessitating a removal of the foreign material. Superficial infection: purulent discharge with or without a positive culture. Serous discharge with a concomitant positive culture."	[22]
"A soft-tissue infection was defined as the presence of purulent discharge from the wound with positive bacteriological findings. Deep infection was diagnosed if operative exploration with osseous debridement was needed to eradicate the infection."	[23]
"We defined a mild infection as a superficial infection that did not involve the bone, joint or implants, and was successfully treated on an outpatient basis with oral antibiotics."	[24]
"Surgical wound infection was defined as one or more of classic signs and symptoms of inflammation together with pus at the operation site. The classification of surgical wound infections was done as per standard definitions."	[25]
"Deep wound infection (defined as established infection beneath the fascia requiring surgical revision), superficial wound infection (defined as cutaneous/subcutaneous infection requiring antibiotic therapy)."	[26]
"Infection was defined as persistent drainage that was on culture, from an open fracture site or wound that had broken down, regardless of size."	[27]
"Deep infection was defined as infection requiring implant removal."	[28]
"Superficial wound infection requiring only antibiotic therapy was classified as a Grade II complication. Deep infection requiring operative debridement under anesthesia and antibiotic administration was classified as a Grade IIIb complication."	[29]
"Deep infection was defined as purulent drainage or osteomyelitis presenting after definitive wound healing and was diagnosed by the treating surgeon based on clinical suspicion and subsequent cultures."	[30]
"Wound infection was based on positive bacterial organisms obtained from operative debridement of the wound or fracture region."	[31]
"Superficial infection was treated with organism-specific antibiotics. Deep infection was defined as wound breakdown requiring debridement and organism-specific antibiotics."	[32]
"Superficial infection was defined as local erythema or swelling, which resolves with antibiotic therapy. Deep infection was defined as continuing wound drainage of pus or a positive bacteriological culture. Infection was also categorized according to time of occurrence: early surgical infection site, delayed union, non-union and mal-union."	[33]
"Wound infection could be considered when there are signs and symptoms of infection around the wound. The diagnosis of chronic osteomyelitis was based on the presence of chronic drainage from sinuses, fistulas, ulcers, or X-ray evidence."	[34]
"Complications deep into the investing muscular fascia were called deep septic complications, whereas those deep into the dermal or subcutaneous tissues only were called superficial septic complications."	[35]
"Deep infections were defined as those below the deep investing muscular fascia. Superficial infections were clinically confined to the dermal and subcutaneous tissue."	[36]
"Superficial infection: superficial to the deep fascia, discharge, erythema, bacteriological culture, no delay in wound healing. Deep infection: extending to the deep fascia, persistent wound discharge, bacteriological cultures, delay in wound healing."	[37]
"The authors were suspicious of infection when patients were febrile (temperature >37.5 °C); their wounds were erythematous, warm, or draining purulent material; there were radiographic signs of infection; or there was a nonunion. Patients with possible infection were taken to the operating room for debridement or hardware removal. In the operating room, deep culture specimens were obtained. If these specimens grew organisms, these patients were deemed to have infection."	[38]
Wound infection was defined as one or more of the classic signs and symptoms of inflammation (rubor, calor, tumor, dolor) together with pus at the operation site. Wound infections were classified as superficial and deep. Infections of the skin and subcutaneous tissue, not communicating under the fasciae were judged superficial. Deep infections were defined as infections that were located under the fascia and diagnosed by opening of the wound.	[39]

translate to cases of IAFF, and expectedly results in a lack of acceptance of PJI definitions for IAFF.

In 28% of the RCTs, the authors used a self-designed definition. Table 3 shows the different parameters that were included in these definitions. The results are interesting and potentially useful, since a consensus definition should be developed in the future and such parameters are likely highly relevant. Most authors included purulent drainage or discharge and positive cultures as parameters for the diagnosis of IAFF. Furthermore, although describing their own definition, multiple authors included terms as osteomyelitis, superficial septic complications and deep bone infection. If a

consensus definition is desired, a more uniform description of terminology seems critical.

Our study furthermore shows that 70% of the RCTs did not give a definition at all. These are staggering numbers and suggest an urgent need for the introduction of a consensus definition of IAFF [6]. A better understanding and description of the definition of IAFF is a crucial first step towards improving scientific reporting, evaluation of routine clinical data, as well as evaluation of novel prevention and treatment strategies [1].

Conflict of interest

All authors declare no conflict of interest with respect to the preparation and writing of this article.

Acknowledgements

The authors thank Mr. Wichor M. Bramer, biomedical information specialist (Erasmus MC, University Medical Center Rotterdam, Rotterdam, The Netherlands), for his help in conducting the systematic literature search.

Appendix A. Supplementary data

Supplementary data associated with this article can be found in the online version, at <http://dx.doi.org/10.1016/j.injury.2017.02.010>.

References

- Metsemakers WJ. Long Bone Fractures in (Poly)Trauma Patients: Risk Analyses of Musculoskeletal Complications and Strategies to Prevent Them [Thesis]. Leuven: Catholic University Leuven; 2015.
- Bonnevalle P, Bonnomet F, Philippe R, Loubignac F, Rubens-Duval B, Talbi A, et al. Early surgical site infection in adult appendicular skeleton trauma surgery: a multicenter prospective series. *Orthop Traumatol Surg Res* 2012;98:684–9.
- Arens S, Hansis M, Schlegel U, Eijer H, Printzen G, Ziegler WJ, et al. Infection after open reduction and internal fixation with dynamic compression plates—clinical and experimental data. *Injury* 1996;27(Suppl. 3):SC27–33.
- Parvizi J, Zmistowski B, Berbari EF, Bauer TW, Springer BD, Della Valle CJ, et al. New definition for periprosthetic joint infection: from the Workgroup of the Musculoskeletal Infection Society. *Clin Orthop Relat Res* 2011;469:2992–4.
- Osmon DR, Berbari EF, Berendt AR, Lew D, Zimmerli W, Steckelberg JM, et al. Diagnosis and management of prosthetic joint infection: clinical practice guidelines by the Infectious Diseases Society of America. *Clin Infect Dis* 2013;56:e1–e25.
- Metsemakers WJ, Moriarty TF, Morgenstern M, Kuehl R, Borens O, Kates S, et al. Letter to the Editor: new definition for periprosthetic joint infection: from the Workgroup of the Musculoskeletal Infection Society. *Clin Orthop Relat Res* 2016;474:2726–7.
- Horan TC, Gaynes RP, Martone WJ, Jarvis WR, Emori TG. CDC definitions of nosocomial surgical site infections, 1992: a modification of CDC definitions of surgical wound infections. *Infect Control Hosp Epidemiol* 1992;13:606–8.
- Mangram AJ, Horan TC, Pearson ML, Silver LC, Jarvis WR. Guideline for prevention of surgical site infection, 1999. Centers for disease control and prevention (CDC) hospital infection control practices advisory committee. *Am J Infect Control* 1999;27:97–132 quiz 3–4; discussion 96.
- Centers for Disease Control and Prevention. National Healthcare Safety Network (NHSN) Overview. 2016. http://www.cdc.gov/nhsn/pdfs/pscmanual/pscmanual_current.pdf#2016.
- Moher D, Liberati A, Tetzlaff J, Altman DG, Group P. Preferred reporting items for systematic reviews and meta-analyses: the PRISMA statement. *Ann Intern Med* 2009;151:264–9 W64.
- Study to Prospectively Evaluate Reamed Intramedullary Nails in Patients with Tibial Fractures I, Bhandari M, Guyatt G, Tornetta P, 3rd, Schemitsch EH, Swiontkowski M, et al. Randomized trial of reamed and unreamed intramedullary nailing of tibial shaft fractures. *J Bone Joint Surg Am*. 2008;90:2567–78.
- Saveli CC, Morgan SJ, Belknap RW, Ross E, Stahel PF, Chaus GW, et al. Prophylactic antibiotics in open fractures: a pilot randomized clinical safety study. *J Orthop Trauma* 2013;27:552–7.
- Akinyoola AL, Adegbehingbe OO, Odunsi A. Timing of antibiotic prophylaxis in tourniquet surgery. *J Foot Ankle Surg* 2011;50:374–6.
- Akinyoola AL, Odunsi A, Yusu MB. Use of wound drains following open reduction and internal fixation of femoral shaft fractures. *J Wound Care* 2012;21:279–80 82–4.
- Bodoky A, Neff U, Heberer M, Harder F. Antibiotic prophylaxis with two doses of cephalosporin in patients managed with internal fixation for a fracture of the hip. *J Bone Jt Surg Am* 1993;75:61–5.
- Boxma H, Broekhuizen T, Patka P, Oosting H. Randomised controlled trial of single-dose antibiotic prophylaxis in surgical treatment of closed fractures: the Dutch Trauma Trial. *Lancet* 1996;347:1133–7.
- Esan O, Ikem IC, Oginni LM, Esan OT. Comparison of unreamed interlocking nail and external fixation in open tibia shaft fracture management. *West Afr J Med* 2014;33:16–20.
- Gaebler C, McQueen MM, Vecsei V, Court-Brown CM. Reamed versus minimally reamed nailing: a prospectively randomised study of 100 patients with closed fractures of the tibia. *Injury* 2011;42(Suppl. 4):S17–21.
- Garcia S, Lozano ML, Gatell JM, Soriano E, Ramon R, Sanmiguel JG. Prophylaxis against infection: single-dose cefonicid compared with multiple-dose cefamandole. *J Bone Jt Surg Am* 1991;73:1044–8.
- Gatell JM, Garcia S, Lozano L, Soriano E, Ramon R, SanMiguel JG. Perioperative cefamandole prophylaxis against infections. *J Bone Jt Surg Am* 1987;69:1189–93.
- Govender S, Csimma C, Genant HK, Valentin-Opran A, Amit Y, Arbel R, et al. Recombinant human bone morphogenetic protein-2 for treatment of open tibial fractures: a prospective, controlled, randomized study of four hundred and fifty patients. *J Bone Jt Surg Am* 2002;84:2123–34 84–A.
- Hedstrom SA, Lidgren L, Sernbo I, Torholm C, Onnerfalt R. Cefuroxime prophylaxis in trochanteric hip fracture operations. *Acta Orthop Scand* 1987;58:361–4.
- Keating JF, O'Brien PJ, Blachut PA, Meek RN, Broekhuysen HM. Locking intramedullary nailing with and without reaming for open fractures of the tibial shaft A prospective, randomized study. *J Bone Jt Surg Am* 1997;79:334–41.
- Lin T, Liu J, Xiao B, Fu D, Yang S. Comparison of the outcomes of cannulated screws vs. modified tension band wiring fixation techniques in the management of mildly displaced patellar fractures. *BMC Musculoskelet Disord* 2015;16:282.
- Mathur P, Tripathi V, Farooque K, Sharma V, Jain N, Bhardwaj N, et al. Implementation of a short course of prophylactic antibiotic treatment for prevention of postoperative infections in clean orthopaedic surgeries. *Indian J. Med. Res.* 2013;137:111–6.
- Miedel R, Ponzer S, Tornkvist H, Soderqvist A, Tidermark J. The standard Gamma nail or the Medoff sliding plate for unstable trochanteric and subtrocchanteric fractures A randomised, controlled trial. *J Bone Jt Surg Br* 2005;87:68–75.
- Moehring HD, Gravel C, Chapman MW, Olson SA. Comparison of antibiotic beads and intravenous antibiotics in open fractures. *Clin Orthop Relat Res* 2000;25:4–61.
- Narsaria N, Singh AK, Arun GR, Seth RRS. Surgical fixation of displaced midshaft clavicle fractures: elastic intramedullary nailing versus precontoured plating. *J Orthop Traumatol Off J Ital Soc Orthop Traumatol* 2014;15:165–71.
- Okcu G, Ozkayin N, Okta C, Topcu I, Aktuglu K. Which implant is better for treating reverse obliquity fractures of the proximal femur: a standard or long nail. *Clin Orthop Relat Res* 2013;471:2768–75.
- Ramos T, Eriksson BI, Karlsson J, Nistor L, Ilizarov external fixation or locked intramedullary nailing in diaphyseal tibial fractures: a randomized, prospective study of 58 consecutive patients. *Arch Orthop Trauma Surg* 2014;134:793–802.
- Richards JE, Magill M, Tressler MA, Shuler FD, Kregor PJ, Obremskey WT, et al. External fixation versus ORIF for distal intra-articular tibia fractures. *Orthopedics* 2012;35:e862–7.
- Robinson CM, Goudie EB, Murray IR, Jenkins PJ, Ahkhtar MA, Read EO, et al. Open reduction and plate fixation versus nonoperative treatment for displaced midshaft clavicular fractures: a multicenter, randomized, controlled trial. *J Bone Jt Surg Am Vol* 2013;95:1576–84.
- Soleimanpour J, Feizi HH, Mohseni MA, Moradi A, Arzromchilar A. Comparison between ender and unreamed interlocking nails in tibial shaft fractures. *Saudi Med J* 2008;29:1458–62.
- Wang C, Li Y, Huang L, Wang M. Comparison of two-staged ORIF and limited internal fixation with external fixator for closed tibial plafond fractures. *Arch Orthop Trauma Surg* 2010;130:1289–97.
- Zou J, Shi Z-M, Zhang W, Zhang C-Q. Open reduction and internal fixation better than percutaneous plate osteosynthesis in distal tibial fractures. *J Investig Surg Off J Acad Surg Res* 2012;25:326–9.
- Zou J, Zhang W, Zhang CQ. Comparison of minimally invasive percutaneous plate osteosynthesis with open reduction and internal fixation for treatment of extra-articular distal tibia fractures. *Injury* 2013;44:1102–6.
- Hughes SP, Miles RS, Littlejohn M, Brown E. Is antibiotic prophylaxis necessary for internal fixation of low-energy fractures. *Injury* 1991;22:111–3.
- Sorger JJ, Kirk PG, Ruhnke CJ, Bjornson SH, Levy MS, Cockrin J, et al. Once daily, high dose versus divided, low dose gentamicin for open fractures. *Clin Orthop Relat Res* 1999;19:7–204.
- Luthje P, Nurmi I, Aho H, Honkanen P, Jokipii P, Kataja M, et al. Single-dose antibiotic prophylaxis in osteosynthesis for hip fractures: a clinical multicentre study in Finland. *Ann Chir Gynaecol* 2000;89:125–30.
- Arens D, Wilke M, Calabro L, Hackl S, Zeiter S, Zderic I, et al. A rabbit humerus model of plating and nailing osteosynthesis with and without *Staphylococcus aureus* osteomyelitis. *Eur Cell Mater* 2015;30:148–61.
- Aro HT, Govender S, Patel AD, Hernigou P, Perera de Gregorio A, Popescu GI, et al. Recombinant human bone morphogenetic protein-2: a randomized trial in open tibial fractures treated with reamed nail fixation. *J Bone Jt Surg Am* 2011;93:801–8.
- Assobhi JE. Reconstruction plate versus minimal invasive retrograde titanium elastic nail fixation for displaced midclavicular fractures. *J Orthop Traumatol* 2011;12:185–92.
- Bach AW, Hansen Jr. ST. Plates versus external fixation in severe open tibial shaft fractures. A randomized trial. *Clin Orthop Relat Res* 1989;89–94.
- Bar-On E, Sagiv S, Porat S. External fixation or flexible intramedullary nailing for femoral shaft fractures in children A prospective, randomised study. *J Bone Jt Surg Br* 1997;79:975–8.
- Blachut PA, O'Brien PJ, Meek RN, Broekhuysen HM. Interlocking intramedullary nailing with and without reaming for the treatment of

- closed fractures of the tibial shaft A prospective, randomized study. *J Bone Jt Surg Am* 1997;79:640–6.
- [46] Cassidy C, Jupiter JB, Cohen M, Delli-Santi M, Fennell C, Leinberry C, et al. Norian SRS cement compared with conventional fixation in distal radial fractures: a randomized study. *J Bone Jt Surg Am* 2003;8:2127–37 85–A.
- [47] Hanschen M, Aschenbrenner IM, Fehske K, Kirchhoff S, Keil L, Holzapfel BM, et al. Mono- versus polyaxial locking plates in distal femur fractures: a prospective randomized multicentre clinical trial. *Int Orthop* 2014;38:857–63.
- [48] Kortekangas T, Savola O, Flinckila T, Lepojarvi S, Nortunen S, Ohtonen P, et al. A prospective randomised study comparing TightRope and syndesmotic screw fixation for accuracy and maintenance of syndesmotic reduction assessed with bilateral computed tomography. *Injury* 2015;46:1119–26.
- [49] Liu QH, Fu ZG, Zhou JL, Lu T, Liu T, Shan L, et al. Randomized prospective study of olecranon fracture fixation: cable pin system versus tension band wiring. *J Int Med Res* 2012;40:1055–66.
- [50] Luna-Pizarro D, Amato D, Arellano F, Hernandez A, Lopez-Rojas P. Comparison of a technique using a new percutaneous osteosynthesis device with conventional open surgery for displaced patella fractures in a randomized controlled trial. *J Orthop Trauma* 2006;20:529–35.
- [51] McCormack RG, Brien D, Buckley RE, McKee MD, Powell J, Schemitsch EH. Fixation of fractures of the shaft of the humerus by dynamic compression plate or intramedullary nail A prospective, randomised trial. *J Bone Jt Surg Br* 2000;82:336–9.
- [52] Mohseni MA, Soleimanpour J, Mohammadpour H, Shahsavari A. AO tubular external fixation vs: unreamed intramedullary nailing in open grade IIIA–IIIB tibial shaft fractures: a single-center randomized clinical trial. *Pak J Biol Sci* 2011;14:490–5.
- [53] Olerud P, Ahrengart L, Ponzer S, Saving J, Tidermark J. Internal fixation versus nonoperative treatment of displaced 3-part proximal humeral fractures in elderly patients: a randomized controlled trial. *J Shoulder Elbow Surg* 2011;20:747–55.
- [54] Polat A, Kose O, Canbora K, Yanik S, Guler F. Intramedullary nailing versus minimally invasive plate osteosynthesis for distal extra-articular tibial fractures: a prospective randomized clinical trial. *J Orthop Sci Off Jpn Orthop Assoc* 2015;20:695–701.
- [55] Raschke M, Rasmussen MH, Govender S, Segal D, Suntum M, Christiansen JS. Effects of growth hormone in patients with tibial fracture: a randomised, double-blind, placebo-controlled clinical trial. *Eur J Endocrinol* 2007;156:341–51.
- [56] Rodrigues FL, de Abreu LC, Valenti VE, Valente AL, da Costa Pereira Cestari R, Pohl PHI, et al. Bone tissue repair in patients with open diaphyseal tibial fracture treated with biplanar external fixation or reamed locked intramedullary nailing. *Injury* 2014;45(Suppl. 5):S32–5.
- [57] Rodriguez-Merchan EC. Plaster cast versus percutaneous pin fixation for comminuted fractures of the distal radius in patients between 46 and 65 years of age. *J Orthop Trauma* 1997;11:212–7.
- [58] Roh YH, Lee BK, Baek JR, Noh JH, Gong HS, Baek GH. A randomized comparison of volar plate and external fixation for intra-articular distal radius fractures. *J Hand Surg* 2015;40:34–41.
- [59] Saied A, Zyaei A. Tourniquet use during plating of acute extra-articular tibial fractures: effects on final results of the operation. *J Trauma* 2010;69:E94–7.
- [60] Shemshaki HR, Mousavi H, Salehi G, Eshaghi MA. Titanium elastic nailing versus hip spica cast in treatment of femoral-shaft fractures in children. *J Orthop Traumatol* 2011;12:45–8.
- [61] Sloan JP, Dove AF, Maheson M, Cope AN, Welsh KR. Antibiotics in open fractures of the distal phalanx. *J Hand Surg Br* 1987;12:123–4.
- [62] Stall A, Paryavi E, Gupta R, Zadnik M, Hui E, O'Toole RV. Perioperative supplemental oxygen to reduce surgical site infection after open fixation of high-risk fractures: a randomized controlled pilot trial. *J Trauma Acute Care Surg* 2013;75:657–63.
- [63] Zehir S, Zehir R, Sahin E, Calbiyik M. Comparison of novel intramedullary nailing with mini-invasive plating in surgical fixation of displaced midshaft clavicle fractures. *Arch Orthop Trauma Surg* 2015;135:339–44.
- [64] Benegas E, Ferreira Neto AA, Gracitelli MEC, Malavolta EA, Assuncao JH, Prada FDS, et al. Shoulder function after surgical treatment of displaced fractures of the humeral shaft: a randomized trial comparing antegrade intramedullary nailing with minimally invasive plate osteosynthesis. *J Shoulder Elbow Surg Am Shoulder Elbow Surg [et al]* 2014;23:767–74.
- [65] Changulani M, Jain UK, Keswani T. Comparison of the use of the humerus intramedullary nail and dynamic compression plate for the management of diaphyseal fractures of the humerus. A randomised controlled study. *Int Orthop* 2007;31:391–5.
- [66] Chiu KY, Lau SK, Fung B, Ng KH, Chow SP. Plastic adhesive drapes and wound infection after hip fracture surgery. *Aust N Z J Surg* 1993;63:798–801.
- [67] Colaris J, Reijman M, Allema JH, Kraan G, van Winterswijk P, de Vries M, et al. Single-bone intramedullary fixation of unstable both-bone diaphyseal forearm fractures in children leads to increased re-displacement: a multicentre randomised controlled trial. *Arch Orthop Trauma Surg* 2013;133:1079–87.
- [68] Costa ML, Achten J, Plant C, Parsons NR, Rangan A, Tubeuf S, et al. UK DRAFFT: a randomised controlled trial of percutaneous fixation with Kirschner wires versus volar locking-plate fixation in the treatment of adult patients with a dorsally displaced fracture of the distal radius. *Health Technol Assess* 2015;19:1–124 v-vi.
- [69] Fadel M, Ahmed MA, Al-Dars AM, Maabed MA, Shawki H. Ilizarov external fixation versus plate osteosynthesis in the management of extra-articular fractures of the distal tibia. *Int Orthop* 2015;39:513–9.
- [70] Ferran NA, Hodgson P, Vannet N, Williams R, Evans RO. Locked intramedullary fixation vs plating for displaced and shortened mid-shaft clavicle fractures: a randomized clinical trial. *J Shoulder Elbow Surg* 2010;19:783–9.
- [71] Griffin D, Parsons N, Shaw E, Kulikov Y, Hutchinson C, Thorogood M, et al. Operative versus non-operative treatment for closed, displaced, intra-articular fractures of the calcaneus: randomised controlled trial. *BMJ (Clin Res Ed)* 2014;349:g4483.
- [72] Hjortrup A, Sorensen C, Mejdahl S, Horsnaes M, Kjersgaard P. Antibiotic prophylaxis in surgery for hip fractures. *Acta Orthop Scand* 1990;61:152–3.
- [73] Im GI, Tae SK. Distal metaphyseal fractures of tibia: a prospective randomized trial of closed reduction and intramedullary nail versus open reduction and plate and screws fixation. *J Trauma* 2005;59:1219–23 discussion 23.
- [74] Juhn A, Krimerman J, Mendes DG. Intertrochanteric fracture of the hip: comparison of nail-plate fixation and Ender's nailing. *Arch Orthop Trauma Surg* 1988;107:136–9.
- [75] Lee SK, Kim KJ, Lee JW, Choy WS. Plate osteosynthesis versus intramedullary nailing for both forearm bones fractures. *Eur J Orthop Surg Traumatol Orthop Traumatol* 2014;24:769–76.
- [76] Lehtonen H, Jarvinen TL, Honkonen S, Nyman M, Vihtonen K, Jarvinen M. Use of a cast compared with a functional ankle brace after operative treatment of an ankle fracture. A prospective, randomized study. *J Bone Jt Surg Am* 2003;85-A:205–11.
- [77] Canadian Orthopaedic Trauma Society. Are locking constructs in distal femoral fractures always best? a prospective multicenter randomized controlled trial comparing the less invasive stabilization system with the minimally invasive dynamic condylar screw system. *J Orthop Trauma* 2016;30:e1–6.
- [78] Leung F, Chow SP. A prospective, randomized trial comparing the limited contact dynamic compression plate with the point contact fixator for forearm fractures. *J Bone Jt Surg Am* 2003;85-A:2343–8.
- [79] Li Y, Jiang X, Guo Q, Zhu L, Ye T, Chen A. Treatment of distal tibial shaft fractures by three different surgical methods: a randomized, prospective study. *Int Orthop* 2014;38:1261–7.
- [80] Madsen JE, Naess L, Aune AK, Alho A, Ekeland A, Stromsoe K. Dynamic hip screw with trochanteric stabilizing plate in the treatment of unstable proximal femoral fractures: a comparative study with the Gamma nail and compression hip screw. *J Orthop Trauma* 1998;12:241–8.
- [81] Meena RC, Meena UK, Gupta GL, Gahlot N, Gaba S. Intramedullary nailing versus proximal plating in the management of closed extra-articular proximal tibial fracture: a randomized controlled trial. *J Orthop Traumatol* 2015;16:203–8.
- [82] Ozkayin N, Okcu G, Aktuglu K. Intertrochanteric femur fractures in the elderly treated with either proximal femur nailing or hemiarthroplasty: a prospective randomised clinical study. *Injury* 2015;46(Suppl. 2):S3–8.
- [83] Paiement GD, Renaud E, Dagenais G, Gosselin RA. Double-blind randomized prospective study of the efficacy of antibiotic prophylaxis for open reduction and internal fixation of closed ankle fractures. *J Orthop Trauma* 1994;8:64–6.
- [84] Parker MJ, Bowers TR, Pryor GA. Sliding hip screw versus the Targon PF nail in the treatment of trochanteric fractures of the hip: a randomised trial of 600 fractures. *J Bone Jt Surg Br Vol* 2012;94:391–7.
- [85] Canadian Orthopaedic Trauma Society. Nonunion following intramedullary nailing of the femur with and without reaming. Results of a multicenter randomized clinical trial. *J Bone Jt Surg Am* 2003;85-A:2093–6.
- [86] Sanders DW, Tieszer C, Corbett B, Canadian Orthopedic Trauma Society, Sanders D, Tieszer C, et al. Operative versus nonoperative treatment of unstable lateral malleolar fractures: a randomized multicenter trial. *J Orthop Trauma* 2012;26:129–34.
- [87] Tsukada S, Otsuji M, Shiozaki A, Yamamoto A, Komatsu S, Yoshimura H, et al. Locking versus non-locking neutralization plates for treatment of lateral malleolar fractures: a randomized controlled trial. *Int Orthop* 2013;37:2451–6.
- [88] Vallier HA, Cureton BA, Patterson BM. Randomized, prospective comparison of plate versus intramedullary nail fixation for distal tibia shaft fractures. *J Orthop Trauma* 2011;25:736–41.
- [89] Vioreanu M, Dudeney S, Hurson B, Kelly E, O'Rourke K, Quinlan W. Early mobilization in a removable cast compared with immobilization in a cast after operative treatment of ankle fractures: a prospective randomized study. *Foot Ankle Int* 2007;28:13–9.
- [90] Vossinakis IC, Badras LS. The external fixator compared with the sliding hip screw for pertrochanteric fractures of the femur. *J Bone Jt Surg Br* 2002;84:23–9.
- [91] Zhang J, Ebraheim N, Lause GE, Xiao B, Xu R. A comparison of absorbable screws and metallic plates in treating calcaneal fractures: a prospective randomized trial. *J Trauma Acute Care Surg* 2012;72:E106–10.
- [92] Zhang S, Zhang K, Jia Y, Yu B, Feng W. InterTan nail versus Proximal Femoral Nail Antirotaion-Asia in the treatment of unstable trochanteric fractures. *Orthopedics* 2013;36:e288–94.
- [93] Zhang T, Yan Y, Xie X, Mu W. Minimally invasive sinus tarsi approach with cannulated screw fixation combined with vacuum-Assisted closure for treatment of severe open calcaneal fractures with medial wounds. *J Foot Ankle Surg Off Publ Am Coll Foot Ankle Surg* 2016;55:112–6.

- [94] Holbrook JL, Swiontkowski MF, Sanders R. Treatment of open fractures of the tibial shaft: ender nailing versus external fixation. A randomized, prospective comparison. *J Bone Jt Surg Am* 1989;71:1231–8.
- [95] Horton TC, Hatton M, Davis TR. A prospective randomized controlled study of fixation of long oblique and spiral shaft fractures of the proximal phalanx: closed reduction and percutaneous Kirschner wiring versus open reduction and lag screw fixation. *J Hand Surg Br* 2003;28:5–9.
- [96] Karn NK, Singh GK, Kumar P, Shrestha B, Singh MP, Gowda MJ. Comparison between external fixation and sliding hip screw in the management of trochanteric fracture of the femur in Nepal. *J Bone Jt Surg Br* 2006;88:1347–50.
- [97] Hargreaves DG, Drew SJ, Eckersley R. Kirschner wire pin tract infection rates: a randomized controlled trial between percutaneous and buried wires. *J Hand Surg Br* 2004;29:374–6.
- [98] Varley GW, Milner SA. Wound drains in proximal femoral fracture surgery: a randomized prospective trial of 177 patients. *J R Coll Surg Edinb* 1995;40:416–8.
- [99] Sadighi A, Elmi A, Jafari MA, Sadeghifard V, Goldust M. Comparison study of therapeutic results of closed tibial shaft fracture with intramedullary nails inserted with and without reaming. *Pak J Biol Sci* 2011;14:950–3.
- [100] Williams MM, Askins V, Hinkes EW, Zych GA. Primary reamed intramedullary nailing of open femoral shaft fractures. *Clin Orthop Relat Res* 1995;18:2–90.
- [101] Mandal A, Dutta P, Sarkar PS, Bandyopadhyay U, Santra S. Single long midline incision versus two small incision techniques in treatment of Schatzker type V and type VI tibial plateau fractures—a comparative study. *J Indian Med Assoc* 2013;111:804–5.
- [102] Tabatabaei S, Arti H, Mahboobi A. Treatment of open tibial fractures: comparison between unreamed and reamed nailing A prospective randomized trial. *Pak J Med Sci* 2012;28:917–20.
- [103] Rafique A, Ghani S, Sadiq M, Siddiqui IA. Kirschner wire pin tract infection rates between percutaneous and buried wires in treating metacarpal and phalangeal fractures. *J Coll Phys Surg Pak* 2006;16:518–20.
- [104] Karachalios T, Lyritis G, Hatzopoulos E, Sapkas G. Single-dose prophylaxis of ceftriaxone versus standard dosage of cefotaxime in the prophylaxis of bacterial complications in orthopedic surgery. *Chemioterapia* 1987;6:573–5.
- [105] Chen L, Zhang G, Hong J, Lu X, Yuan W. Comparison of percutaneous screw fixation and calcium sulfate cement grafting versus open treatment of displaced intra-articular calcaneal fractures. *Foot Ankle Int* 2011;32:979–85.
- [106] Chen L, Zhang G, Song D, Guo X, Yuan W. A comparison of percutaneous reduction and screw fixation versus open reduction and plate fixation of traumatic symphysis pubis diastasis. *Arch Orthop Trauma Surg* 2012;132:265–70.
- [107] Chen X, Wang SC, Cao LH, Yang GQ, Li M, Su J-C. Comparison between radial head replacement and open reduction and internal fixation in clinical treatment of unstable, multi-fragmented radial head fractures. *Int Orthop* 2011;35:1071–6.
- [108] Tavakoli A, Mousavi Tadi H, Mahmoodian A. A comparison between unreamed locked intramedullary nailing and plate-Screw fixation in the treatment of tibial diaphyseal fractures. *Iran Red Crescent Med J* 2010;12:640–3.
- [109] Kadar A, Eisenberg G, Yahav E, Drexler M, Salai M, Steinberg EL. Surgical site infection in elderly patients with hip fractures, silver-coated versus regular dressings: a randomised prospective trial. *J Wound Care* 2015;24:441–2 4–5.
- [110] Zoubos AB, Galanakos SP, Soucacos PN. Orthopedics and biofilm—what do we know? A review. *Med Sci Monit Int Med J Exp Clin Res* 2012;18:RA89–96.
- [111] Metsemakers W, Kuehl R, Moriarty T, Richards R, Verhofstad M, Borens O, et al. Infection after fracture fixation: current surgical and microbiological concepts. *Injury* 2016.
- [112] Rittmann W, Perren S. Cortical bone healing after internal fixation and infection. Berlin, Heidelberg, New York: Springer; 1974.
- [113] Worlock P, Slack R, Harvey L, Mawhinney R. The prevention of infection in open fractures: an experimental study of the effect of fracture stability. *Injury* 1994;25:31–8.