CBCT versus other imaging modalities to assess peri-implant bone and diagnose complications: a systematic review

Jacobs Reinhilde[1,2], Vranckx Myrthel[1], Vanderstuyft Tony[3], Quirynen Marc[3], Salmon Benjamin[4]

[1]OMFS-IMPATH research group, Department of Imaging and Pathology, Faculty of Medicine, University of Leuven and Department of Oral & Maxillofacial Surgery, University Hospitals Leuven, Leuven, Belgium.

[2]Department of Dental Medicine, Karolinska Institutet, Stockholm, Sweden.

[3]Section of Periodontology, Department of Oral Health Sciences, KU Leuven & Dentistry, University Hospitals, Leuven, Belgium.

[4]Paris Descartes - Sorbonne Paris Cite University, Dental School, EA2496, Montrouge, France and Dental Medicine Department, Bretonneau Hospital, HUPNVS, AP-HP, Paris, France.

Paper presented at FOR Consensus Conference: **Diagnosis, avoidance and management of complications of implant-based treatments,** November 15-17, 2017, Leuven, Belgium.

Correspondence to:
Jacobs Reinhilde
OMFS-IMPATH research group, KU Leuven
Kapucijnenvoer 33
3000 Leuven, Belgium
Tel: +32 16 33 24 52 | +32 16 33 27 48
Fax: +32 16 33 24 10
reinhilde.jacobs@uzleuven.be

Word count text only: 2998
Figures: 3
Tables: 5
Appendices: 1

Abstract

Purpose: The objective of this systematic review was to evaluate the diagnostic value of CBCT compared to 2D imaging and clinical gold standard techniques in peri-implant bone defect detection and measurement.

Materials and methods: Literature search was performed using MEDLINE, Embase and Web of Science databases up to July 2017. Clinical, *ex vivo*, *in vitro* and animal studies that assessed and measured peri-implant bone defects using different imaging modalities were included in this review. Data extraction and qualitative analysis were performed by two reviewers. The methodological quality of each study was reviewed using the QUADAS-2 tool.

Results: The initial search revealed 2849 unique papers. Full-text analysis was performed on 60 articles. For the present review, nine studies were considered eligible to be included for qualitative analysis. CBCT performed similar to intra-oral radiography in mesiodistal defect detection and measurements. Additional buccolingual visualization and volumetric and morphological assessment of peri-implant bone defects are major advantages of three-dimensional visualisation with CBCT. Nevertheless, one must be aware of scattering and beam-hardening artefacts masking osseointegration, shallow bony defects and other peri-implant radiolucencies, thus impeding early diagnosis of intrabony lesions.

Conclusion: The present review did not provide evidence to support the use of CBCT as standard postoperative procedure to evaluate peri-implant bone. Up to date, we are clinically forced to remain with intra-oral radiography, notwithstanding the inherent limitations related to restricted field of view and two-dimensional overlap. A three-dimensional imaging approach for postoperative implant evaluation is crucial, making further development of an optimized and artefact-free CBCT protocol indispensable.

Conflict of interest statement: The authors declare no conflicts of interest.

Introduction

For several decades, implants are widely used to replace missing teeth and restore impaired oral situations. Despite the remarkably high implant survival rates (ranging from 95% to 98%) reported in literature over the past decades[1], recent epidemiological meta-analyses state that in the last decade prevalence of peri-implant diseases could raise to over 20%[2–4]. This rather new pathological entity yields to a collective awareness regarding the significant risk factors of oral implant placement and the appropriate diagnostic and therapeutic approaches. The inflammatory conditions, affecting both soft and hard tissues around the intra-oral implants, may in the long run cause implant failure with consequent loss of the implant and the surrounding bone. In the current context of heterogeneity of definition[5], and considering the lack of consensus regarding the nonsurgical versus surgical approach of the so-called peri-implantitis[6,7], imaging of the bone surrounding the compromised implant is of paramount importance to further develop diagnostic and therapeutic strategies for peri-implant structures. Routinely taken radiographs offer a non-invasive technique for longitudinal follow-up of the peri-implant status. However, when diagnosis occurs too late and marginal bone loss is advanced, treatment options become scarce, often resulting in explantation, meanwhile compromising bone quality and quantity and eventual oral rehabilitation. Nearly every consensus report states that intra-oral radiography (IO) remains the ultimate diagnostic tool for follow-up of peri-implant conditions[8–10]. Intra-oral radiography units are widely accessible in private dental practices. Somewhat less present is panoramic radiography (PR), while cone beam computed tomography (CBCT) and multi-slice computed tomography (MSCT) imaging techniques remain mostly restricted to secondary care. Despite the variant techniques and methods for reproducible and standardized IO images, inter- and intra-observer reliability of measurements on IO images vary significantly and superimposition of anatomical structures can lead to underestimation of the actual bone defect dimensions[11,12]. Moreover, minor variations in X-ray beam orientation compromise the proper follow-up possibilities and the accuracy of the measurements of the peri-implant bone levels[13].

Besides X-ray imaging modalities, ultrasonography is showing promising results in two-dimensional (2D) defect detection, excluding the hazards of electromagnetic radiation[14,15]. However, ultrasound peri-implant bone defect diagnosis, and certainly measurements of defects, needs further refinement before entering daily clinical practice[16].

Since two-dimensional imaging techniques offer merely mesiodistal and vertical detection of bone defects, three-dimensional (3D) imaging techniques can enhance the diagnosis with valuable additional spatial information. As clinicians are more and more focused on esthetics, depending on the preservation of the vestibular tissues, 3D CBCT imaging offers complementary buccolingual visualization of the peri-implant bone[17,18]. Accurate evaluation of the full dimensions and morphology of the peri-implant bone defects benefits treatment decision-making and the patient's rehabilitation outcomes. Nonetheless, 3D imaging techniques are less cost-efficient, increase the radiation exposure and struggle with imaging artefacts around metal objects[11,19].

With regard to proper visualization of peri-implant bone structure and osseointegration, micro-computed tomography (μCT) offers great 3D reconstruction of the implant and surrounding bone morphology, allowing analysis of cortical and trabecular bone structures, without the need for histological sections[20,21]. Nevertheless, this imaging technique is only available for pre-clinical studies and not applicable in daily clinical practice.

Furthermore, researchers are experimenting with non-ionizing imaging such as magnetic resonance imaging (MRI) and optical coherence tomography (OCT), yet a clinical and realistic feasibility of such applications remains questionnable[22,23].

The purpose of this systematic review was to evaluate the diagnostic value of the above-mentioned 2D and 3D imaging techniques in peri-implant bone defect detection and measurement.

Materials & methods

Protocol and registration

This review was conducted following the PRISMA (Preferred Reporting Items for Systematic reviews and Meta-Analyses) guidelines to ensure comprehensiveness[24]. Methods of analysis and inclusion criteria were specified in advance and registered at PROSPERO (Prospective Register of Systematic Reviews) with protocol number ……..

Objective and PICO question

To evaluate the diagnostic (and predictive) value of different 2D and 3D imaging techniques in detection and measurements of peri-implant bone level changes and defects. The PICO question consisted of following components: (P) implant fixtures with peri-implant bone defects, (I) CBCT imaging, (C) other imaging modalities or clinical gold standards, (O) assessment and measurement of peri-implant bone loss and bone defects.

Information sources and search strategy

The search strategy was developed for MEDLINE and adapted for Embase and Web of Science. The electronic databases were searched in July 2017. The search strategy consisted of a combination of controlled terms (MeSH and EMTREE terms, respectively) and keywords. The full search strategy can be consulted in Appendix 1. No language restrictions were applied when searching the electronic databases. Moreover, reference lists of relevant articles and former systematic reviews in the field were manually screened for additional relevant publications. Duplicated hits were manually checked and removed.

Eligibility criteria

Clinical, *ex vivo*, *in vitro* and animal studies that assessed and measured peri-implant bone defects by use of different imaging modalities were included in this review. Exclusion criteria consisted of reviews, letters to the editor, guideline reports, case reports, clinical follow-up studies, case-control studies, studies that did not evaluate imaging techniques and studies comparing clinical diagnostic parameters or different treatment options.

Study selection

Two reviewers (MV and TV) independently reviewed the titles and abstracts of all records. Subsequently, all full-text papers of the studies deemed eligible for inclusion were obtained and full-text reading analysis was performed. In both title/abstract reading phase and full-text reading phase, disagreements were resolved by discussion between the two reviewers. When consensus could not be reached, an experienced third author (RJ) was consulted.

Data extraction

Data were extracted by both reviewers (MV and TV) and discussed mutually. Data recorded for qualitative analysis were:

- Study characteristics: authors, year of publication, level of evidence;
- Methods: study design (clinical, *ex vivo*, *in vitro*, animal), number of samples, number of implants;

- Intervention characteristics: induction of bone defect, directions of detection, imaging modality, reference technique, number of observers;
- Outcomes: type of measurements, intra- and interrater reliability, clinical applicability, results and conclusion.

Risk of bias assessment

The methodological quality of each study was critically reviewed using the QUADAS-2 tool (Quality Assessment of Diagnostic Accuracy Studies 2)[25]. This tool evaluates the risk of bias in four domains: patient selection, index test, reference standard and flow and timing. Moreover, the clinical applicability of the patient selection, index test and reference standard was assessed. The qualitative evaluation of the methodology was done by one reviewer (MV) in duplicate. Discrepancies were resolved by discussion with a second reviewer (RJ).

Results

Search results

A total of 1199, 575 and 2071 records were identified by searching the MEDLINE, Embase and Web of Science databases, respectively. Additionally, 27 articles were identified through handsearching and screening of reference lists. Duplicates were manually removed, resulting in 2849 unique papers. Publication dates of these articles ranged from 1975 to 2017. Figure 1 shows the PRISMA flow diagram describing the selection process. According to the title screening of all 2849 records, 104 papers were deemed eligible for inclusion in the review. Based on the abstract reading, another 18 records were excluded. Finally, 86 articles were selected for full text reading. 26 articles turned out to not meet the strict inclusion criteria and were subsequently excluded for further analysis. Reasons for exclusion are listed in Table 1. From the remaining 60 articles, 43 articles described the detection and measurements of peri-implant bone levels and defects with the use of different 2D and 3D imaging modalities (Table 2 and Figure 2). Additionally, 17 records presented a technique to create reproducible IO radiographs to ensure proper follow-up evaluation of the peri-implant hard tissues and allow comparison of serial radiographs (Table 3). Finally, 9 studies were considered eligible to include in the qualitative analysis of this review, as they reported the use of CBCT versus other imaging modalities or gold standard clinical techniques for the assessment of peri-implant bone loss (Table 4).

Study characteristics

Forty-three papers compared bone defect detection and/or measurements on different kinds of radiographic images with a reference measurement technique. Only 14 authors used a clinical sample of patients presenting with peri-implant bone loss[12,14,26–36]. The majority of studies was conducted with the use of animal bone specimens[18,37–52] or human cadavers[13,53–61]. One study used acrylic blocks simulating alveolar ridges[62]. Above all, IO radiography is the most studied diagnostic imaging technique for intra-oral implant follow-up. Four papers added PR to the methodology[31–34], and another four papers tested the detection capability of 2D tomography[35,36,56,60]. One paper explored the possibilities of ultrasonography, which is not widely used in implant dentistry[14]. The diagnostic potential of CBCT, whether or not compared with conventional MSCT and/or 2D techniques, was investigated sixteen times[18,38,40,41,43–50,57–59,63].

As displayed in Table 2, nineteen papers assessed the presence or absence of a peri-implant radiolucent space[26–28,36,38,40,41,43–46,53–57,59,60], whereof only one measured the volume of the detected defect[58]. Twenty-one papers described linear measurements executed in mesial, distal and/or buccal and lingual directions from the implant's vertical axis[12–14,18,29–31,33,34,37,39,42,47–51,61–64]. The number of threads to determine bone level was used in two papers[32,35]. Becker et al (2017) reported a promising volumetric dehiscence profile through microCT scanning of the implant and surrounding bone[52]. However, this technique, as well as aforementioned ultrasonography measurements, are not yet clinically applicable.

Since IO radiography remains the imaging technique of choice in daily clinical practice, seventeen papers covered the widely clinically used paralleling technique to take reproducible IO radiographs and additional methods to evaluate serial images over time[17,65–80]. Both changes in bone level and bone density are important to assess in follow-up evaluations. Therefore, Table 3 differentiates authors describing a digital subtraction technique using a reference

stepwedge and/or occlusal key, and authors describing methods for consecutive bone level measurements, whether or not with the use of semi-automated digital measurements.

Qualitative analysis of the methodology

The methodological quality analysis included nine papers comparing CBCT to other diagnostic techniques[18,40,46–50,57,58]. The publication dates of these papers ranged from 2011 to 2016, confirming the relatively recent nature of CBCT as a diagnostic tool for peri-implant complications. One study was performed in Belgium, one in the United Kingdom, three in Germany, two in Turkey and one in Switzerland. None of the papers in the qualitative analysis studied a clinical sample of patients presenting with peri-implantitis (Table 4). Animal or cadaver bone specimens were the samples of choice. Bender et al[63] did investigate a clinical sample of patients with CBCT, however, the authors did not compare CBCT with a 2D imaging technique or clinical gold standard, so the study was not included in Table 4. Mean number of implants used in the selected papers was 49 (± 29). Mechanical induction of the defects was performed in 7 out of 9 studies. The number of observers diverged from one to nine, with varying intra- and interrater reliability values, as shown in Table 4.

Taking all findings into account, CBCT performed similar to IO and gold standard techniques in mesiodistal detection and measurement of defects[40,46,48,49,58,81]. Additional buccolingual visualization of the defects is the main added value in the diagnosis of peri-implant bone defects with CBCT. Nevertheless, one must be aware of the occurrence of artefacts and the limited feasibility of CBCT to evaluate bone density, as shown by Corpas et al[48].

Risk of bias within studies

All studies in the qualitative analysis were considered low level of evidence in evidence-based medicine (EBM), since they were conducted using animal or cadaver specimens. The methodological quality of the included papers was assessed using the QUADAS-2 tool and corresponding signalling questions[25]. Table 5 and Figure 3 show the overview of outcomes and summarizing plots of the risk of bias assessment and applicability concerns. The variety of specimens (nonrandomized) and sample preparation techniques, as well as the different imaging machines and settings can have introduced bias. In three papers, concerns arose with regard to flow and timing, as the authors did not clarify the process of detection of defects with the index test and the reference standard[49,58], and the uniformity of the reference standards used[48].

In general, applicability concerns among the analysed papers was low, except for patient selection. This originates from discrepancies in the severity of the target condition. The mechanical induction of peri-implant defects in the study populations hampered evaluation of the clinical relevance of CBCT in detection of the actual pathogenesis of peri-implant marginal bone loss, whilst this is the aim of this review.

Discussion

As displayed in Table 4, CBCT shows promising results in peri-implant bone defect detection and allows measurements in three planes. In six out of nine studies, CBCT equated IO and gold standard clinical techniques in the detection of advanced bone loss defects[46–49,58]. However, CBCT images, and the associated scattering and beam-hardening artefacts, can hide narrow peri-implant radiolucencies and impede the early diagnosis of these starting intrabony lesions[11,18,40,50,57,82]. Clinicians should be aware of image distortions due to high-density materials, for example blooming artefacts associated with implants, and take them into account when diagnosing their patients[19]. Unfortunately, metal artefact reduction algorithms are inefficient to significantly correct the images[43,59] and motion artefacts due to patient movement during the scanning process can reduce the diagnostic image quality even more. MSCT is even worse in artefact expression as compared to CBCT, making assessment of peri-implant bone levels and trabecular bone structure almost impossible. Moreover, as MSCT yields higher dose levels, more costs, and reduced accessibility, it is not advocated when it comes to surgical follow-up of implant placement.

Very accurate and detailed imaging of the peri-implant bone without scattering or blooming caused by the implant would obviously be the desired diagnostic technique. The volumetric dehiscence profile, shown by Becker et al, used microCT to approach this goal[52]. They placed implants in foxhound jaws and after sacrificing the animals, performed microCT and histomorphometric analysis of the specimens. This microCT technique allows to evaluate differences in bone level changes as a function of insertion depth and abutment type, yielding complementary three-dimensional information, which is not possible with histology alone[52]. By cancelling out the scattering and blooming, they managed to visualize the peri-implant bone on a plot, showing it as a 360° view around the implant. In this way, very detailed information on peri-implant bone can be obtained, opening many future diagnostic possibilities. Nevertheless, in order to achieve comparable 360° volumetric outcomes with CBCT, the imaging technique still has to be improved in terms of accuracy and rule out artefacts.

As long as imaging techniques do not offer a 100% accurate reflection of the actual peri-implant bone conditions, the obtained radiographic images should always be combined with clinical information. Probing depth, bleeding on probing and suppuration, together with radiographic data, increase the odds of early detection of peri-implant disease, offering the possibility to adequately intervene, treat and prevent further complications[83]. In this context, the volumetric and morphological characterization of the three-dimensional bone defect may be far more relevant as a diagnostic staging tool for early clinical management, yet further development of optimized, low dose and artefact-free CBCT imaging protocols are required to reach this goal.

Considering the above and in line with basic ALARA-principle (As Low As Reasonably Achievable) and the more clinically applicable ALADIP principle, CBCT imaging devices and protocols should strive to develop as low as diagnostically acceptable CBCT protocols, being indication-oriented and patient-specific[84]. Until further advances occur, CBCT imaging should rather be considered for specific indications in complex clinical cases. Meanwhile, IO radiography will remain the standard imaging technique for long-term follow-up of peri-implant conditions[9,57]. Yet and when doing so, one should realise that superimposition of implant and bone, creates a lack of information of true

buccal and lingual bone levels, obstructing a realistic visualization of the potential defect, hampering detailed diagnosis such as in the esthetic zone[17]. In the same light, this review revealed the lack of clinical samples involving CBCT assessments. Only Bender et al studied a limited cohort of patients affected by peri-implantitis[63]. Meanwhile, the *in vitro* nature of the included studies and the (mechanical) induction of peri-implant defects impedes evaluation of the detection capacity of CBCT for the actual clinical pathogenesis of peri-implant marginal bone loss.

Recently, Bohner et al conducted a meta-analysis of IO and CBCT imaging for diagnosis of peri-implant bone loss[85]. The authors screened literature from 1991 to 2016 and concluded that both techniques showed similar sensitivity, specificity and AUC values. However, they state that voxel size, field of view and image detection system plays a major role in image efficacy of CBCT, thus influencing the detection threshold. The use of filters can improve the visualization of peri-implant radiolucencies, enhancing the detection of true-positive and true-negative cases[41]. Furthermore, peri-implant defect size plays a significant role in the accurate detection of the bone loss. Similar to our findings in the qualitative analysis, Pinheiro et al showed that smaller peri-implant bone defects are identified less often with CBCT compared to larger defects[44]. Overall, heterogeneity of CBCT protocols induces drastic differences in terms of image quality, thus leading to important variation of diagnostic performances[41,44,45,58].

This review was limited to the use of CBCT vs. other imaging modalities in the detection and measurement of peri-implant bone defects. Bone thickness measurements, bone morphology, bone quality/density and other subjects are therefore not discussed. However, besides linear measurements, Corpas et al[48] demonstrated that CBCT is inferior to IO imaging and histology when it comes to bone density evaluation. In this light, it is crucial to emphasize that CBCT should not be used for this purpose. Pauwels et al[86,87] showed that large errors can occur when using CBCT grey values in a quantitative way. Pseudo-Hounsfield units from CBCTs are not reliable and alternative methods of assessing bone quality and density on CBCT should be further investigated[88].

Conclusion

The present review did not provide evidence to support the use of CBCT as standard procedure to evaluate peri-implant marginal bone. Nevertheless, a 3D imaging approach for postoperative implant diagnosis is crucial, surely when dealing with pathological entities as peri-implantitis. Yet, the currently available methods for 3D imaging assessment suffer from artefacts and inaccuracies in visualisation and quantitative assessment of the peri-implant hard tissues. Therefore, in daily practice, intra-oral radiography remains the most commonly used technique for diagnosis and monitoring. However, when applying this technique for postoperative assessment and bony defect evaluation, we should be well aware that the true dimensions and morphology of the defect remain masked.

Bibliography

1. Thoma DS, Sailer I, Ioannidis A, Zwahlen M, Makarov N, Pjetursson BE. A systematic review of the survival and complication rates of resin-bonded fixed dental prostheses after a mean observation period of at least 5 years. Clin Oral Implants Res. 2017. [Epub ahead of print]
2. Derks J, Tomasi C. Peri-implant health and disease. A systematic review of current epidemiology. J Clin Periodontol. 2015;42 Suppl 1:158–171.
3. Lee C, Huang Y, Zhu L, Weltman R. Prevalences of peri-implantitis and peri-implant mucositis: systematic review and meta-analysis. J Dent. 2017;62:1–12.
4. Atieh MA, Alsabeeha NHM, Faggion CMJ, Duncan WJ. The frequency of peri-implant diseases: a systematic review and meta-analysis. J Periodontol. 2013;84:1586–1598.
5. Ramanauskaite A, Juodzbalys G. Diagnostic Principles of Peri-Implantitis: a Systematic Review and Guidelines for Peri-Implantitis Diagnosis Proposal. J oral Maxillofac Res. 2016;7:e8.
6. Ramanauskaite A, Daugela P, Faria de Almeida R, Saulacic N. Surgical Non-Regenerative Treatments for Peri-Implantitis: a Systematic Review. J oral Maxillofac Res. 2016;7:e14.
7. Daugela P, Cicciu M, Saulacic N. Surgical Regenerative Treatments for Peri-Implantitis: Meta-analysis of Recent Findings in a Systematic Literature Review. J oral Maxillofac Res. 2016;7:e15.
8. Harris D, Buser D, Dula K, Grondahl K, Haris D, Jacobs R, e.a. E.A.O. Guidelines for the use of diagnostic imaging in implant dentistry. A consensus workshop organized by the European Association for Osseointegration in Trinity College Dublin. Clin Oral Implants Res. 2002;13:566–570.
9. Harris D, Horner K, Grondahl K, Jacobs R, Helmrot E, Benic GI, e.a. E.A.O. Guidelines for the use of diagnostic imaging in implant dentistry. A consensus workshop organized by the European Association for Osseointegration at the Medical University of Warsaw. Clin Oral Implants Res. 2012;23:1243–1253.
10. Hämmerle C, Cordaro L, Van Assche N, Benic GI, Bornstein MM, Gamper F, e.a. Digital technologies to support planning, treatment , and fabrication processes and outcome assessments in implant dentistry. Summary and consensus statements. The 4th EAO consensus conference 2015. Clin Oral Implants Res. 2015;26:97–101.
11. Bornstein MM, Horner K, Jacobs R. Use of cone beam computed tomography in implant dentistry: current concepts, indications and limitations for clinical practice and research. Periodontol 2000. 2017;73:51–72.
12. García-García M, Mir-Mari J, Benic GI, Figueiredo R, Valmaseda-Castellon E. Accuracy of intra-oral radiography in assessing bone level in implants affected by peri-implantitis: a cross-sectional study. J Clin Periodontol. 2016;43:85–91.
13. Benn DK. Estimating the validity of radiographic measurements of marginal bone height changes around osseointegrated implants. Implant Dent. 1992;1:79–83.
14. Bertram S, Emshoff R. Sonography of periimplant buccal bone defects in periodontitis patients: A pilot study. Oral Surg Oral Med Oral Pathol Oral Radiol Endod [Internet]. 2008;105:99–103.
15. Choi M, Culjat MO, Singh RS, White SN. Ultrasound imagery for dental implant diagnosis and treatment planning in a porcine model. J Prosthet Dent. 2012;108:344–353.
16. Benic GI, Elmasry M, Hammerle CHF. Novel digital imaging techniques to assess the outcome in oral

rehabilitation with dental implants: a narrative review. Clin Oral Implants Res. 2015;26 Suppl 11:86–96.
17. Meijndert L, Meijer HJA, Raghoebar GM, Vissink A. A technique for standardized evaluation of soft and hard peri-implant tissues in partially edentulous patients. J Periodontol ~~[Internet]~~. 2004;75:646–651.
18. Golubovic V, Mihatovic I, Becker J, Schwarz F. Accuracy of cone-beam computed tomography to assess the configuration and extent of ligature-induced peri-implantitis defects: A pilot study. Oral Maxillofac Surg. 2012;16:349–354.
19. Codari M, Vasconcelos KDF, Neto FH. Quantitative evaluation of metal artifacts using different CBCT devices, high-density materials and field of views. Clin Oral Implants Res. 2017. [Epub ahead of print]
20. Butz F, Ogawa T, Chang T-L, Nishimura I. Three-dimensional bone-implant integration profiling using micro-computed tomography. Int J Oral Maxillofac Implants. 2006;21:687–695.
21. Sennerby L, Wennerberg A, Pasop F. A new microtomographic technique for non-invasive evaluation of the bone structure around implants. Clin Oral Implants Res. 2001;12:91–94.
22. Korn P, Elschner C, Schulz MC, Range U, Mai R, Scheler U. MRI and dental implantology: two which do not exclude each other. Biomaterials. 2015;53:634–645.
23. Sanda M, Shiota M, Imakita C, Sakuyama A, Kasugai S, Sumi Y. The effectiveness of optical coherence tomography for evaluating peri-implant tissue: A pilot study. Imaging Sci Dent. 2016;46:173–178.
24. Liberati A, Altman DG, Tetzlaff J, Mulrow C, Gøtzsche PC, Ioannidis JPA, e.a. The PRISMA statement for reporting systematic reviews and meta-analyses of studies that evaluate health care interventions: explanation and elaboration. J Clin Epidemiol. 2009;62:1–34.
25. Whiting P, Rutjes A, Westwood M, Mallett S, Deeks J, Reitsma J, e.a. QUADAS-2: A Revised Tool for the Quality Assessment of Diagnostic Accuracy Studies. Ann Intern Med. 2011;155:529–536.
26. Gröndahl K, Lekholm U. The predictive value of radiographic diagnosis of implant instability. Int J Oral Maxillofac Implants. 1997;12:59–64.
27. Mörner-Svalling A-C, Tronje G, Andersson LG, Welander U. Comparison of the diagnostic potential of direct digital and conventional intraoral radiography in the evaluation of peri-implant conditions. Clin Oral Implants Res. 2003;14:714–719.
28. Sundén S, Gröndahl K, Grondahl HG. Accuracy and precision in the radiographic diagnosis of clinical instability in Brånemark dental implants. Clin Oral Implants Res. 1995;6:220–226.
29. Serino G, Sato H, Holmes P, Turri A. Intra-surgical vs. radiographic bone level assessments in measuring peri-implant bone loss. Clin Oral Implants Res. 2016. [Epub ahead of print]
30. Wyatt CC, Bryant SR, Avivi-Arber L, Chaytor D V, Zarb GA, C.C. W, e.a. A computer-assisted measurement technique to assess bone proximal to oral implants on intraoral radiographs. Clin Oral Implants Res. 2001;12:225–229.
31. Gutmacher Z, Machtei EE, Hirsh I, Zigdon-Giladi H, Horwitz J. A comparative study on the use of digital panoramic and intra-oral radiographs to assess proximal bone height around dental implants. Quintessence Int (Berl). 2016;47:441–446.
32. Kullman L, Al-Asfour A, Zetterqvist L, Andersson L. Comparison of radiographic bone height assessments in panoramic and intraoral radiographs of implant patients. Int J Oral Maxillofac Implant. 2007;22:96–100.

33. Merheb J, Graham J, Coucke W, Roberts M, Quirynen M, Jacobs R, e.a. Prediction of Implant Loss and Marginal Bone Loss by Analysis of Dental Panoramic Radiographs. Int J Oral Maxillofac Implants. 2015;30:372–377.
34. Zechner W, Watzak G, Gahleitner A, Busenlechner D, Tepper G, Watzek G. Rotational panoramic versus intraoral rectangular radiographs for evaluation of peri-implant bone loss in the anterior atrophic mandible. Int J Oral Maxillofac Implants. 2003;18:873–878.
35. Lofthag-Hansen S, Lindh C, Petersson A. Radiographic assessment of the marginal bone level after implant treatment: a comparison of intra-oral and Scanora detailed narrow beam radiography. Dentomaxillofac Radiol. 2003;32:97–103.
36. Ludlow JB, Nason RHJ, Hutchens LHJ, Moriarty J. Radiographic evaluation of alveolar crest obscured by dental implants. Implant Dent. 1995;4:13–18.
37. Borg E, Gröndahl K, Persson LG, Gröndahl HG. Marginal bone level around implants assessed in digital and film radiographs: in vivo study in the dog. Clin Implant Dent Relat Res. 2000;2:10–17.
38. de-Azevedo-Vaz SL, Vasconcelos K de F, Neves FS, Sousa Melo SL, Flores Campos PS, Haiter-Neto F, e.a. Detection of periimplant fenestration and dehiscence with the use of two scan modes and the smallest voxel sizes of a cone-beam computed tomography device. ORAL Surg ORAL Med ORAL Pathol ORAL Radiol. 2013;115:121–127.
39. Hermann JS, Schoolfield JD, Nummikoski P V, Buser D, Schenk RK, Cochran DL, e.a. Crestal bone changes around titanium implants: a methodologic study comparing linear radiographic with histometric measurements. Int J Oral Maxillofac Implants. 2001;16:475–485.
40. Dave M, Davies J, Wilson R, Palmer R. A comparison of cone beam computed tomography and conventional intra-oral radiography at detecting peri-implant bone defects. Clin Oral Implants Res. 2013;24:671–678.
41. de-Azevedo-Vaz SL, Barbosa Alencar PN, Rovaris K, Flores Campos PS, Haiter-Neto F, Alencar PNB, e.a. Enhancement cone beam computed tomography filters improve in vitro periimplant dehiscence detection. ORAL Surg ORAL Med ORAL Pathol ORAL Radiol. 2013;116:633–639.
42. de-Azevedo-Vaz SL, Neves FS, Fiqueirêdo EP, Haiter-Neto F, Campos PSF. Accuracy of enhancement filters in measuring in vitro peri-implant bone level. Clin Oral Implants Res. 2013;24:1074–1077.
43. de-Azevedo-Vaz SL, Peyneau D, Lins de-Azevedo-Vaz S, Peyneau PD, Ramirez-Sotelo LR, Vasconcelos K de F, e.a. Efficacy of a cone beam computed tomography metal artifact reduction algorithm for the detection of peri-implant fenestrations and dehiscences. ORAL Surg ORAL Med ORAL Pathol ORAL Radiol. 2016;121:550–556.
44. Pinheiro LR, Scarfe WC, Augusto de Oliveira Sales M, Gaia BF, Cortes ARG, Cavalcanti MGP. Effect of Cone-Beam Computed Tomography Field of View and Acquisition Frame on the Detection of Chemically Simulated Peri-Implant. J Periodontol. 2015;86:1159–1165.
45. Pinheiro LR, Scarfe WC, Augusto de Oliveira Sales M, Gaia BF, Cortes ARG, Cavalcanti MGP. Effectiveness of Intra-oral Radiography Versus Cone Beam Computed Tomography with Different Kilovoltage Settings in the Detection of Chemically Created Peri-implant Bone Defects: An In Vitro Study. Int J Oral Maxillofac Implants. 2017;32:741–750.

46. Sirin Y, Horasan S, Yaman D, Basegmez C, Tanyel C, Aral A, e.a. Detection of crestal radiolucencies around dental implants: An in vitro experimental study. J Oral Maxillofac Surg. 2012;70:1540–1550.
47. Mengel R, Kruse B, Flores-de-Jacoby L. Digital volume tomography in the diagnosis of peri-implant defects: an in vitro study on native pig mandibles. J Periodontol. 2006;77:1234–1241.
48. Corpas LDS, Quirynen M, Naert I, Jacobs R, Quirynen M, Huang Y, e.a. Peri-implant bone tissue assessment by comparing the outcome of intra-oral radiograph and cone beam computed tomography analyses to the histological standard. Clin Oral Implants Res. 2010;22:492–499.
49. Ritter L, Elger MC, Rothamel D, Fienitz T, Zinser M, Schwarz F, e.a. Accuracy of peri-implant bone evaluation using cone beam CT, digital intra-oral radiographs and histology. Dentomaxillofac Radiol. 2014;43:20130088.
50. González-Martin O, Oteo C, Ortega R, Alandez J, Sanz M, Veltri M. Evaluation of peri-implant buccal bone by computed tomography: an experimental study. Clin Oral Implants Res. 2016;27:950–955.
51. Schliephake H, Wichmann M, Donnerstag F, Vogt S. Imaging of periimplant bone levels of implants with buccal bone defects. Clin Oral Implants Res. 2003;14:193–200.
52. Becker K, Klitzsch I, Stauber M, Schwarz F. Three-dimensional assessment of crestal bone levels at titanium implants with different abutment microstructures and insertion depths using micro-computed tomography. Clin Oral Implants Res. 2016;28:671–676.
53. Kavadella A, Karayiannis A, Nicopoulou-Karayianni K. Detectability of experimental peri-implant cancellous bone lesions using conventional and direct digital radiography. Aust Dent J. 2006;51:180–186.
54. Matsuda Y, Hanazawa T, Seki K, Sano T, Ozeki M, Okano T. Accuracy of Digora system in detecting artificial peri-implant bone defects. Implant Dent. 2001;10:265–271.
55. Sewerin IP, Gotfredsen K, Stoltze K. Accuracy of radiographic diagnosis of peri-implant radiolucencies--an in vitro experiment. Clin Oral Implants Res. 1997;8:299–304.
56. Webber RL, Horton RA, Underhill TE, Ludlow JB, Tyndall DA. Comparison of film, direct digital, and tuned-aperture computed tomography images to identify the location of crestal defects around endosseous titanium implants. Oral Surg Oral Med Oral Pathol Oral Radiol Endod. 1996;81:480–490.
57. Kühl S, Zurcher S, Zitzmann NU, Filippi A, Payer M, Dagassan-Berndt D, e.a. Detection of peri-implant bone defects with different radiographic techniques: a human cadaver study. Clin Oral Implants Res. 2016;27:529–534.
58. Kamburoğlu K, Murat S, Kilic C, Yuksel S, Avsever H, Farman A, e.a. Accuracy of CBCT images in the assessment of buccal marginal alveolar peri-implant defects: effect of field of view. Dentomaxillofac Radiol. 2014;43:20130332.
59. Kamburoğlu K, Kolsuz E, Murat S, Eren H, Yuksel S, Paksoy CS. Assessment of buccal marginal alveolar peri-implant and periodontal defects using a cone beam CT system with and without the application of metal artefact reduction mode. Dentomaxillofac Radiol. 2013;42:20130176.
60. Ludlow JB, Gates W, Nason RJ. Radiographic evaluation of implant-obscured bone. Comparison of digitally subtracted tomographic and intra-oral techniques. Oral Surg Oral Med Oral Pathol Oral Radiol Endod. 1995;80:351–357.
61. De Smet E, Jacobs R, Gijbels F, Naert I, E. DS, R. J, e.a. The accuracy and reliability of radiographic methods for

the assessment of marginal bone level around oral implants. Dentomaxillofacial Radiol. 2002;31:176–181.
62. Sewerin IP. Errors in radiographic assessment of marginal bone height around osseointegrated implants. Scand J Dent Res. 1990;98:428–433.
63. Bender P, Salvi GE, Buser D, Sculean A, Bornstein MM. Correlation of Three-Dimensional Radiologic Data with Subsequent Treatment Approach in Patients with Peri-implantitis: A Retrospective Analysis. Int J per. 2017;37:481–489.
64. Siddiqui AA, Caudill R, Beatty K. Use of an optical comparator for radiographic measurement of bone loss around endosseous implants: a pilot study. Implant Dent. 1995;4:85–88.
65. Jeffcoat MK. Digital radiology for implant treatment planning and evaluation. Dentomaxillofac Radiol. 1992;21:203–207.
66. Jeffcoat MK, Reddy MS. Digital subtraction radiography for longitudinal assessment of peri-implant bone change: method and validation. Adv Dent Res. 1993;7:196–201.
67. Naser AZ, Etemadi S, Rismanchian M, Sheikhi M, Tavakoli M. Comparison of Conventional and Standardized Bone Densitometry around Implants in Intra-oral Radiographs during a Three Months Period. Dent Res J (Isfahan). 2011;8:33–38.
68. Meijer HJ, Steen WH, Bosman F. Standardized radiographs of the alveolar crest around implants in the mandible. J Prosthet Dent. 1992;68:318–321.
69. Malloy KA, Wadhwani C, McAllister B, Wang M, Katancik JA. Accuracy and Reproducibility of Radiographic Images for Assessing Crestal Bone Height of Implants Using the Precision Implant X-ray Locator (PIXRL) Device. Int J Oral Maxillofac Implants. 2017;32:830–836.
70. Larheim TA, Wie H, Tveito L, Eggen S. Method for radiographic assessment of alveolar bone level at endosseous implants and abutment teeth. Scand J Dent Res. 1979;87:146–154.
71. Larheim TA, Eggen S. Measurements of alveolar bone height at tooth and implant abutments on intraoral radiographs. J Clin Periodontol. 1982;9:184–192.
72. Galasso L. Proposed method for the standardized measurement of marginal bone height on intra-oral radiographs with the Brånemark System. Clin Implant Dent Relat Res. 2000;2:147–151.
73. Nicopoulou-Karayianni K, Brägger U, Lang NP. Subtraction radiography in oral implantology. Int J Periodontics Restorative Dent. 1997;17:221–231.
74. Cunha P, Guevara MA, Messias A, Rocha S, Reis R, Nicolau PMG. A method for segmentation of dental implants and crestal bone. Int J Comput Assist Radiol Surg. 2013;8:711–721.
75. Meijer HJA, Steen WH, Bosman F. A comparison of methods to assess marginal bone height around endosseous implants. J Clin Periodontol. 1993;20:250–253.
76. Wakoh M, Nishikawa K, Otonari T, Yamamoto M, Harada T, Sano T, e.a. Digital subtraction technique for evaluation of peri-implant bone change in digital dental imaging. Bull Tokyo Dent Coll. 2006;47:57–64.
77. Bittar-Cortez JA, Passeri LA, de Almeida SM, Haiter-Neto F, Boscolo FN, Haiter-Neto F, e.a. Comparison of peri-implant bone level assessment in digitized conventional radiographs and digital subtraction images. Dentomaxillofacial Radiol. 2006;35:258–262.
78. Geraets WGM, Verheij HGC, Wismeijer D, van der Stelt PF. Detecting bone loss along dental implants by

subtraction of panoramic radiographs. Clin Oral Implants Res. 2012;23:861–865.

79. Reddy MS, Mayfield-Donahoo TL, Jeffcoat MK. A semi-automated computer-assisted method for measuring bone loss adjacent to dental implants. Clin Oral Implants Res. 1992;3:28–31.
80. Patil PG, Nimbalkar-Patil S. A radiographic measurement technique for crest bone changes related to dental implants. J Prosthet Dent. 2015;113:350–351.
81. Kehl M, Swierkot K, Mengel R. Three-Dimensional Measurement of Bone Loss at Implants in Patients With Periodontal Disease. J Periodontol. 2011;82:689–699.
82. Jacobs R, Esposito M. Editorial: On peri-implant bone level measures: To see or not to see, that is the question. Eur J Oral Implantol. 2016;9 Suppl 1:119–121.
83. Salvi GE, Lang NP. Diagnostic parameters for monitoring peri-implant conditions. Int J Oral Maxillofac Implants. 2004;19 Suppl:116–127.
84. Oenning ACC, Jacobs R, Pauwels R, Stratis A, Hedesiu M, Salmon B. Cone-beam CT in pediatric dentistry: DIMITRA project position statement. Pediatr Radiol. 2017, In press.
85. Bohner LOL, Mukai E, Oderich E, Porporatti AL, Pacheco-Pereira C, Tortamano P, e.a. Comparative analysis of imaging techniques for diagnostic accuracy of peri-implant bone defects : a meta-analysis. ORAL Surg ORAL Med ORAL Pathol ORAL Radiol. 2017. [Epub ahead of print]
86. Pauwels R, Jacobs R, Singer SR, Mupparapu M. CBCT-based bone quality assessment: are Hounsfield units applicable? Dentomaxillofacial Radiol. 2015;44:20140238.
87. Pauwels R, Nackaerts O, Bellaiche N, Stamatakis H, Tsiklakis K, Walker A, e.a. Variability of dental cone beam CT grey values for density estimations. Br J Radiol. 2013;86:20120135.
88. Van Dessel J, Nicolielo LFP, Huang Y, Coudyzer W, Salmon B, Lambrichts I, e.a. Accuracy and reliability of different cone beam computed tomography (CBCT) devices for structural analysis of alveolar bone in comparison with multislice CT and micro-CT. Eur J Oral Implantol. 2017;10:95–105.

Appendix 1

MEDLINE:

((((((((("Dental Implants"[Mesh] OR “dental implantation”[Mesh] OR “peri-implantitis”[Mesh] OR “Dental Implant” [tiab] OR “Dental Implants” [tiab] OR “endosseous implant” [tiab] OR “endosseous implants” [tiab] OR "dental implantation" [tiab] OR "oral implant" [tiab] OR "oral implants" [tiab] OR "oral implantation" [tiab] OR periimplant [tiab] OR peri-implant [tiab] OR peri-implantitis [tiab] OR periimplantitis [tiab] OR “peri-implant conditions” [tiab] OR “periimplant conditions” [tiab]))) AND ("Alveolar Bone Loss"[Mesh] OR approximal bone[tiab] OR "implant complications"[tiab] OR "crestal bone"[tiab] OR "bone change"[tiab] OR "bone defect"[tiab] OR "bone level"[tiab] OR "bone levels" [tiab] OR "bone loss"[tiab] OR "bone contour"[tiab] OR "bone contouring"[tiab] OR "bone-to-implant contact"[tiab] OR "supracrestal bone"[tiab] OR "marginal bone"[tiab] OR "bone measurement"[tiab] OR "bone measurements"[tiab] OR "bone height"[tiab] OR osseointegration[tiab] OR pocket[tiab] OR "pocket depth"[tiab] OR "hard tissue"[tiab] OR "alveolar bone"[tiab] OR "bone evaluation"[tiab])) AND ((“Diagnostic Imaging”[Mesh] OR "Radiography, Dental"[Mesh] OR “Imaging, Three-Dimensional"[Mesh] OR “Cone-Beam Computed Tomography"[Mesh] OR radiography [ti] OR radiographs [ti] OR radiographic [ti] OR radiographic data [ti] OR dental radiography [ti] OR radiologic [ti] OR radiologic data [ti] OR ultrasonography [ti] OR ultrasound [ti] OR two dimensional imaging [ti] OR two-dimensional imaging [ti] OR panoramic radiograph [ti] OR panoramic radiographs [ti] OR pantomography [ti] OR orthopantomography [ti] OR intraoral radiograph [ti] OR intraoral radiographs [ti] OR intra-oral radiograph [ti] OR intra-oral radiographs [ti] OR three dimensional imaging [ti] OR three-dimensional imaging [ti] OR “cone-beam computed tomography” [ti] OR “cone beam computed tomography” [ti] OR “Cone-Beam CT” [ti] OR “Cone Beam CT” [ti] OR “computed tomography” [ti] OR CBCT [ti]))) AND ((Assessment [tiab] OR evaluation [tiab] OR accuracy [tiab] OR prediction [tiab] OR accuracy [tiab] OR detection [tiab] OR monitoring [tiab] OR methodology [tiab] OR methodological [tiab] OR method [tiab] OR “postoperative evaluation” [tiab] OR “golden standard” [tiab] OR evaluation technique [tiab] OR reproducibility [tiab] OR diagnostics [tiab] OR diagnostic [tiab] OR “radiographic techniques” [tiab])))))))

Embase:

('dental implant':ti,ab OR 'dental implants':ti,ab OR 'endosseous implant':ti,ab OR 'endosseous implants':ti,ab OR 'dental implantation':ti,ab OR 'oral implant':ti,ab OR 'oral implants':ti,ab OR 'oral implantation':ti,ab OR 'periimplant':ti,ab OR 'peri-implant':ti,ab OR 'peri-implantitis':ti,ab OR 'periimplantitis':ti,ab OR 'peri-implant conditions':ti,ab OR 'periimplant conditions':ti,ab) AND ('alveolar bone loss':ti,ab OR 'approximal bone':ti,ab OR 'implant complication':ti,ab OR 'crestal bone':ti,ab OR 'bone change':ti,ab OR 'bone defect':ti,ab OR 'bone level':ti,ab OR 'bone levels':ti,ab OR 'bone loss':ti,ab OR 'bone contour':ti,ab OR 'bone contouring':ti,ab OR 'bone-to-implant contact':ti,ab OR 'supracrestal bone':ti,ab OR 'marginal bone':ti,ab OR 'bone measurement':ti,ab OR 'bone measurements':ti,ab OR 'bone height':ti,ab OR 'osseointegration':ti,ab OR 'pocket':ti,ab OR 'pocket depth':ti,ab OR 'hard tissue':ti,ab OR 'alveolar bone':ti,ab OR 'bone evaluation':ti,ab) AND ('assessment':ti,ab OR 'evaluation':ti,ab OR 'prediction':ti,ab OR 'accuracy':ti,ab OR 'detection':ti,ab OR 'monitoring':ti,ab OR 'methodology':ti,ab OR 'methodological':ti,ab OR 'method':ti,ab OR 'postoperative evaluation':ti,ab OR 'golden standard':ti,ab OR 'evaluation

technique':ti,ab OR 'reproducibility':ti,ab OR 'diagnostics':ti,ab OR 'diagnostic':ti,ab OR 'radiographic techniques':ti,ab) AND (radiography OR 'cone beam computed tomography' OR 'diagnostic imaging' OR 'dental radiology' OR 'three dimensional imaging' OR radiodiagnosis OR echography OR 'two-dimensional imaging' OR 'panoramic radiography')

Web of Science:

TS=(Dental Implant OR Dental Implants OR endosseous implant OR endosseous implants OR "dental implantation" OR "oral implant" OR "oral implants" OR "oral implantation" OR periimplant OR peri-implant OR peri-implantitis OR periimplantitis OR peri-implant conditions OR periimplant conditions) AND TS=(approximal bone OR "implant complications" OR "crestal bone" OR "bone change" OR "bone defect" OR "bone level" OR "bone levels" OR "bone loss" OR "bone contour" OR "bone contouring" OR "bone-to-implant contact" OR "supracrestal bone" OR "marginal bone" OR "bone measurement" OR "bone measurements" OR "bone height" OR osseointegration OR pocket OR "pocket depth" OR "hard tissue" OR "alveolar bone" OR "bone evaluation") AND TS=(radiography OR radiographs OR radiographic OR radiographic data OR dental radiography OR radiologic OR radiologic data OR ultrasonography OR ultrasound OR two dimensional imaging OR two-dimensional imaging OR panoramic radiograph OR panoramic radiographs OR pantomography OR orthopantomography OR intraoral radiograph OR intraoral radiographs OR intra-oral radiograph OR intra-oral radiographs OR three dimensional imaging OR three-dimensional imaging OR cone-beam computed tomography OR cone beam computed tomography OR Cone-Beam CT OR Cone Beam CT OR computed tomography OR CBCT) AND TS=(assessment OR evaluation OR accuracy OR prediction OR accuracy OR detection OR monitoring OR methodology OR methodological OR method OR postoperative evaluation OR golden standard OR evaluation technique OR reproducibility OR diagnostics OR diagnostic OR radiographic techniques)

Figure 1. Flow diagram of the selection process (PRISMA 2009 format)[24].

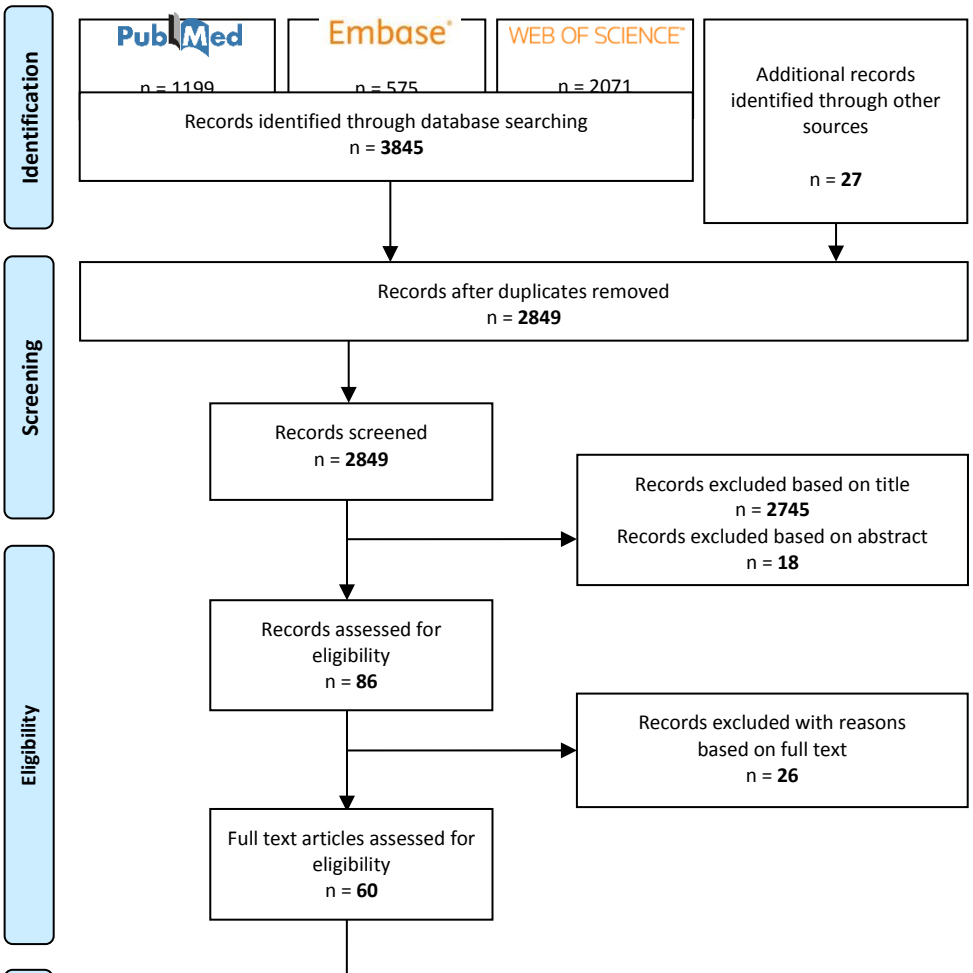

Figure 2. 2D and 3D imaging modalities to assess and measure peri-implant bone changes. Intraoral, tomography, panoramic and CBCT images from own collection; µCT image by courtesy of Huang Yan; ultrasound image from Bertram et al (2008).

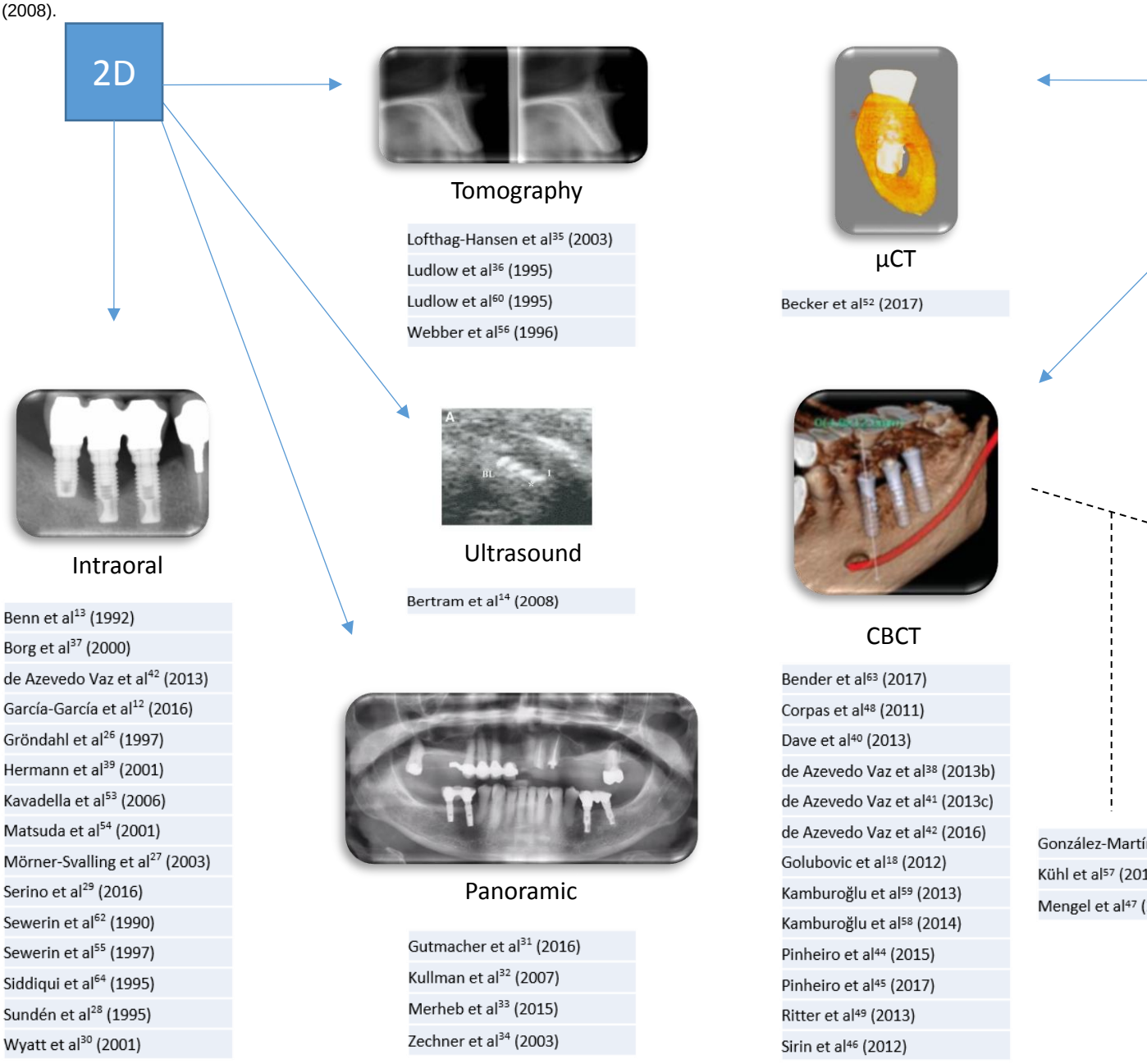

Table 1. Excluded articles with reasons	
Author (year)	**Reason**
Becker et al (2015)	3
Benic et al (2015)	1
Brägger et al (1994)	1
Butz et al (2006)	3
Chan et al (2017)	3
Chopra et al (2016)	3
Daubert et al (2015)	2
De Bruyn et al (2013)	1
Esposito et al (1993)	2
Fienitz et al (2012)	3
Harris et al (2002)	1
Harris et al (2012)	1
Huang et al (2014)	3
Korn et al (2015)	3
Lang et al (2011)	2
Pan et al (2013)	2
Papantonopoulos et al (2017)	3
Raes et al (2013)	2
Salvi et al (2004)	1
Sanda et al (2016)	3
Slagter et al (2015)	3
Truhlar et al (1993)	1
Vera et al (2012)	2
Wang et al (2013a)	3
Wang et al (2013b)	3
Yepes et al (2015)	3

Legend: (1) reviews, letters to the editor, EAO guideline reports; (2) no evaluation of imaging techniques; (3) irrelevant outcome measures for this review (e.g. bone structure analysis, osseointegration, morphology, bone thickness measurements).

Table 2. Measurements of marginal bone levels and peri-implant bone defects with the use of 2D and 3D imaging modalities					
Imaging technique		**Author (year)**		**Type of measurements**	**Measured distances**	**Direc**
2D	periapical radiography	Gröndahl et al[26] (1997)		presence/absence of radiolucency	-	M &
		Kavadella et al[53] (2006)		presence/absence of radiolucency on five-point scale	-	M &
		Matsuda et al[54] (2001)		presence/absence of radiolucency on five-point scale	-	M &
		Mörner-Svalling et al[27] (2003)		presence/absence of radiolucency	-	M &
		Sewerin et al[55] (1997)		presence/absence of radiolucency on five-point scale	-	M &
		Sundén et al[28] (1995)		presence/absence of radiolucency on five-point scale	-	M &

		Borg et al[37] (2000)		linear (mm)	defect height	M &
		De Azevedo Vaz et al[42] (2013)		linear (mm)	defect height	M &
		Hermann et al[39] (2001)		linear (mm)	defect height	M &
		Serino et al[29] (2016)		linear (mm)	defect height	M &
		Wyatt et al[30] (2001)		linear (mm)	defect height	M &
		Siddiqui et al[64] (1995)		linear (mm)	defect width	M &
		Benn et al[13] (1992)		linear (mm)	inter-thread distance	M &
		Sewerin et al[62] (1990)		linear (mm)	inter-thread distance	M &
		García-García et al[12] (2016)		linear (mm)	intrabony height supracrestal part defect width	M &
	panoramic radiography	Gutmacher et al[31] (2016)		linear (mm)	supracrestal part	M &
		Merheb et al[33] (2015)		linear (mm)	defect width	M &
		Zechner et al[34] (2003)		linear (mm)	defect height	M &
		Kullman et al[32] (2007)		number of threads	supracrestal part	M &
	tomography	Lofthag-Hansen et al[35] (2003)		number of threads	supracrestal part	M &
		Ludlow et al[36] (1995)		presence/absence of radiolucency on five-point scale	-	B & L
		Ludlow et al[60] (1995)		presence/absence of radiolucency on five-point scale	-	M D
		Webber et al[56] (1996)		presence/absence of radiolucency on five-point scale	-	M D MB M
	ultrasound	Bertram et al[14] (2008)		linear (mm)	defect height	B
3D	CBCT	Dave et al[40] (2013)		presence/absence of radiolucency on five-point scale	-	M &
		De Azevedo Vaz et al[38] (2013)		presence/absence of radiolucency on five-point scale	-	B & L
		De Azevedo Vaz et al[41] (2013)		presence/absence of radiolucency	-	B & L
		De Azevedo Vaz et al[42] (2016)		presence/absence of radiolucency on five-point scale	-	B & L
		Kamburoğlu et al[59] (2013)		presence/absence of radiolucency on five-point scale	-	B & L
		Pinheiro et al[44] (2015)		presence/absence of radiolucency on five-point scale	-	M D MB M
		Pinheiro et al[45] (2017)		presence/absence of radiolucency on five-point scale	-	M D MB M
		Sirin et al[46] (2012)		presence/absence of radiolucency on five-point scale	-	M D
		Kühl et al[57] (2016)		presence/absence and type of defect	(i) no defect visible (ii) defect present, but not classifiable (iii) defect C (2-wall) (iv) defect B (3- wall) (v) defect A (4-wall)	M D
		Kamburoğlu et al[58] (2014)		presence/absence of radiolucency, linear (mm) and volumetric measurements	defect height defect width defect volume	M D
		Bender et al[63] (2017)		linear (mm)	defect height intrabony height supracrestal part defect width morphology	M D MB M

		Mengel et al[47] (2006)		linear (mm)	defect height supracrestal part defect width	M D
		Corpas et al[48] (2011)		linear (mm) percentage of bone % density (mmAleq)	intrabony height bone fraction bone structure	M D
		Ritter et al[49] (2013)		linear (mm)	supracrestal part	M D
		González-Martín et al[50] (2016)		linear (mm)	supracrestal part buccal bone thickness	B & L
		Golubovic et al[18] (2012)		linear (mm)	supracrestal part intrabony height	B & L
	MSCT	De Smet et al[61] (2002)		linear (mm)	supracrestal part	M D
		Schliephake et al[51] (2003)		linear (mm)	supracrestal part	M D
	µCT	Becker et al[52] (2017)		volumetric dehiscence profile	defect height	vecto degre arou

Five-point scale for assessment of peri-implant radiolucent space: 1 radiolucency definitely not present, 2 probably not present, 3 uncertain, 4 probably present, 5 definitely present.
Abbreviations: M, mesial; D, distal; B, buccal; L, lingual; IO, intraoral periapical radiography; PR, panoramic radiography; CBCT; cone-beam computed tomography; M microcomputed tomography; GS, gold standard.
Color code study types:

	Clinical sample
	Ex vivo
	In vitro
	Animal bone specimen

Table 3. Reproducibility of intraoral radiography for assessment of peri-implant bone changes					
Technique	**Method**	**Author (year)**		**Assessment of peri-implant bone changes**	**Specification of measuring technique**
Paralleling technique	Stepwedge	Jeffcoat[65] (1992)		Bone density	Digital subtraction
		Jeffcoat et al[66] (1993)		Bone density	Digital subtraction
	Occlusal key	Naser et al[67] (2011)		Bone density	Semi-automated digital measures
		Meijer et al[68] (1992)		Bone level	Linear measures with sliding calliper
		Meijndert et al[17] (2004)		Bone level	Linear measures with sliding calliper
		Malloy et al[69] (2017)		Bone level	Linear measures with digital ruler
		Larheim et al[70] (1979)		Bone level	Measuring grid
		Larheim et al[71] (1982)		Bone level	Measuring grid
		Galasso[72] (2000)		Bone level	Linear measures with sliding calliper
		Nicopoulou-Karayianni et al[73] (1997)		Bone density	Digital subtraction
		Cunha et al[74] (2013)		Bone level	Semi-automated digital measures
		Meijer et al[75] (1993)		Bone level	Semi-automated digital measures
		Wakoh et al[76] (2006)		Bone density	Digital subtraction
	Unstandardized	Bittar-Cortez[77] (2006)		Bone density	Digital subtraction
		Geraets et al[78] (2012)		Bone density	Digital subtraction on panoramic radiograph
		Reddy et al[79] (1992)		Bone level	Semi-automated digital measures
		Patil et al[80] (2015)		Bone level	Semi-automated digital measures

Color code study types same as Table 2.

Table 4. Analysis of studies comparing CBCT with other imaging modalities or clinical gold standard in the measurement of peri-implant bone defects									
Study characteristics	**Sample characteristics**			**Intervention characteristics**					
					Test group	**Reference**			
Author (year)	**Study design**	**Samples (n=)**	**Implants (n=)**	**Induction of defect**	**3D imaging**	**2D imaging**	**Gold standard**	**Observers (n=)**	**Intrarater reliability**
Corpas et al[48] (2011)	minipig	10	80	N	CBCT	IO	histology	?	✗
Dave et al[40] (2013)	bovine	4	15	Y mechanical	2 CBCT machines: 3D Accuitomo 80 i-CAT NG	IO	-	9	IO ✓ CBCT ✗
Golubovic et al[18] (2012)	dog	6	48	Y ligature	CBCT	-	histology	1	✓
González-Martín et al[50] (2016)	bovine	10	60	N	2 CBCT machines: i-CAT NG Newtom VGi MSCT	-	direct measurement (calliper)	2	✗
Kamburoğlu et al[58] (2014)		5	69	Y mechanical	CBCT	-	direct measurement (calliper)	3	✓
Kühl et al[57] (2016)		1	6	Y mechanical	CBCT MSCT	IO PR	direct measurement (calliper)	7	✓
Mengel et al[47] (2006)	pig	19	19-38	Y mechanical	CBCT MSCT	IO PR	direct readings with reflecting stereomicroscope with measuring ocular	1	✗
Ritter et al[49] (2014)	dog	12	26	Y	CBCT	IO	histology	RX 2 histo 1	✓
Sirin et al[46] (2012)	bovine	?	100	Y mechanical	CBCT MSCT	IOPR	clinical picture	7	✓

Abbreviations: Y, yes; N, no; M, mesial; D, distal; B, buccal; L, lingual; CC, craniocaudal; IO, intraoral periapical radiography; PR, panoramic radiog
slice computed tomography; µCT, microcomputed tomography; GS, gold standard; histo, histology.
Color code study types same as Table 2.

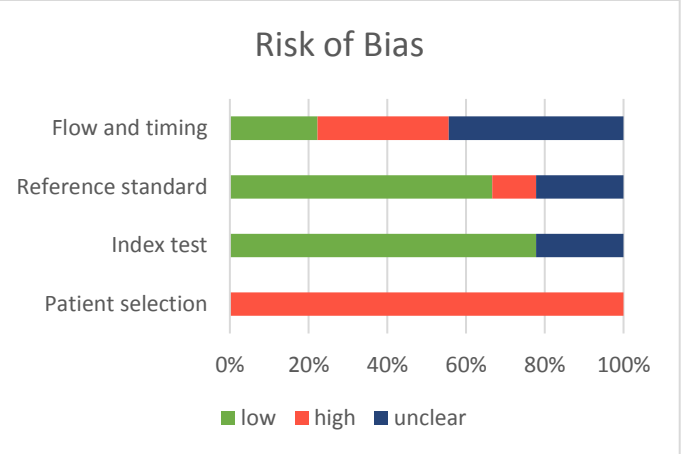

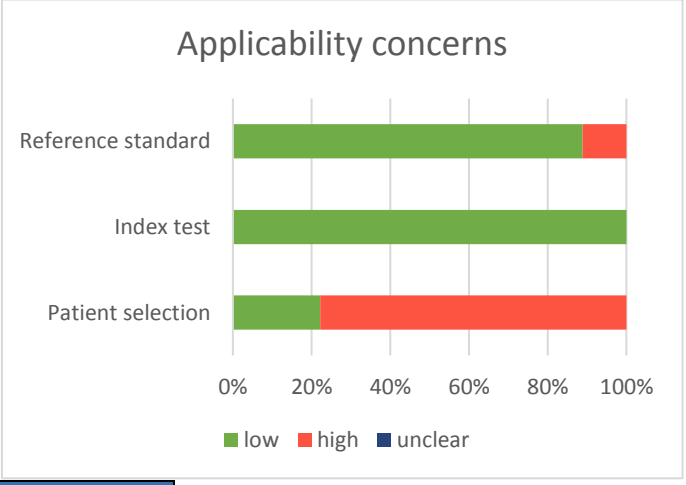

Table 5. Risk of bias assessment using the QUADAS-2 tool

Author (year)	Risk of bias				Applicability concerns		
	Patient selection	Index test	Reference standard	Flow and timing	Patient selection	Index test	Reference standard
Corpas et al[48] (2011)	↑	↓	↓	↑	↓	↓	↓
Dave et al[40] (2013)	↑	↓	↓	↓	↑	↓	↓
Golubovic et al[18] (2012)	↑	?	?	?	↑	↓	↓
González-Martín et al[50] (2016)	↑	↓	↓	?	↓	↓	↓
Kamburoğlu et al[58] (2014)	↑	↓	↑	↑	↑	↓	↑
Kühl et al[57] (2016)	↑	↓	↓	?	↑	↓	↓
Mengel et al[47] (2006)	↑	?	?	?	↑	↓	↓
Ritter et al[49] (2014)	↑	↓	↓	↑	↑	↓	↓
Sirin et al[46] (2012)	↑	↓	↓	↓	↑	↓	↓

Legend: ↓ low risk of bias, ↑ high risk of bias, ? unclear risk of bias

Figure 3. Summary of QUADAS-2 risk of bias assessment and applicability concerns.