Journal Pre-proof



Same-session Double EUS-bypass versus Surgical Gastroenterostomy and Hepaticojejunostomy: An International Multicenter Comparison

Michiel Bronswijk, MD, Giuseppe Vanella, MD, Roy L.J. van Wanrooij, MD PhD, Jayanta Samanta, MD, Jonas Lauwereys, BSc, Enrique Pérez-Cuadrado-Robles, MD PhD, Giuseppe Dell'Anna, MD, Jahnvi Dhar, MD, Vikas Gupta, MS MCh, Hannah van Malenstein, MD PhD, Wim Laleman, MD PhD, Joris Jaekers, MD, Halit Topal, MD, Baki Topal, MD PhD, Stefano Crippa, MD PhD, Massimo Falconi, MD, Marc G. Besselink, MD PhD, Nouredin Messaoudi, MD PhD, Paolo Giorgio Arcidiacono, MD PhD, Rastislav Kunda, MD PhD, Schalk Van der Merwe, MD PhD

PII: S0016-5107(23)00359-0

DOI: https://doi.org/10.1016/j.gie.2023.03.019

Reference: YMGE 13626

To appear in: *Gastrointestinal Endoscopy*

Received Date: 16 November 2022

Revised Date: 16 February 2023

Accepted Date: 9 March 2023

Please cite this article as: Bronswijk M, Vanella G, van Wanrooij RLJ, Samanta J, Lauwereys J, Pérez-Cuadrado-Robles E, Dell'Anna G, Dhar J, Gupta V, van Malenstein H, Laleman W, Jaekers J, Topal H, Topal B, Crippa S, Falconi M, Besselink MG, Messaoudi N, Arcidiacono PG, Kunda R, Van der Merwe S, Same-session Double EUS-bypass versus Surgical Gastroenterostomy and Hepaticojejunostomy: An International Multicenter Comparison, *Gastrointestinal Endoscopy* (2023), doi: https://doi.org/10.1016/j.gie.2023.03.019.

This is a PDF file of an article that has undergone enhancements after acceptance, such as the addition of a cover page and metadata, and formatting for readability, but it is not yet the definitive version of record. This version will undergo additional copyediting, typesetting and review before it is published in its final form, but we are providing this version to give early visibility of the article. Please note that, during the production process, errors may be discovered which could affect the content, and all legal disclaimers that apply to the journal pertain.

Copyright © 2023 by the American Society for Gastrointestinal Endoscopy

Journal Pre-proof

Same-session Double EUS-bypass versus Surgical Gastroenterostomy and Hepaticojejunostomy: An International Multicenter Comparison

Michiel Bronswijk MD[1,2], Giuseppe Vanella MD[3], Roy L.J. van Wanrooij MD PhD[4,5], Jayanta Samanta MD[6], Jonas Lauwereys BSc[1,2], Enrique Pérez-Cuadrado-Robles MD PhD[7], Giuseppe Dell'Anna MD[3], Jahnvi Dhar MD[6], Vikas Gupta MS MCh[6], Hannah van Malenstein MD PhD[1], Wim Laleman MD PhD[1], Joris Jaekers MD[8], Halit Topal MD[8], Baki Topal MD PhD[8], Stefano Crippa, MD PhD[9], Massimo Falconi MD[9], Marc G. Besselink MD PhD[10,11], Nouredin Messaoudi MD PhD[12], Paolo Giorgio Arcidiacono MD PhD[3], Rastislav Kunda MD PhD[12] and Schalk Van der Merwe MD PhD[1]

Author affiliation:

1. Department of Gastroenterology and Hepatology, University Hospital Gasthuisberg, University of Leuven, Leuven, Belgium.
2. Department of Gastroenterology and Hepatology, Imelda Hospital Bonheiden, Belgium
3. Pancreatobiliary Endoscopy and Endosonography Division, Pancreas Translational and Clinical Research Center, IRCCS San Raffaele Scientific Institute and University, Milan, Italy
4. Amsterdam UMC, location Vrije Universiteit Amsterdam, Department of Gastroenterology and Hepatology, Amsterdam, The Netherlands
5. Amsterdam Gastroenterology Endocrinology Metabolism, Amsterdam
6. Departments of Gastroenterology and GI Surgery, Postgraduate Institute of Medical Education and Research (PGIMER), Chandigarh, Chandigarh, India.
7. Department of Gastroenterology, Georges-Pompidou European Hospital, APHP.Centre, University of Paris Cité, Paris, France.
8. Department of Visceral Surgery, University Hospitals Gasthuisberg, University of Leuven, Leuven, Belgium.
9. Pancreatic Surgery Unit, Pancreas Translational and Clinical Research Center, IRCCS San Raffaele Scientific Institute and University, Milan, Italy
10. Amsterdam UMC, location University of Amsterdam, Department of Surgery, Amsterdam, The Netherlands.
11. Cancer Center Amsterdam, The Netherlands
12. Department of Surgery, Department of Gastroenterology and Hepatology, Department of Advanced Interventional Endoscopy, Universitair Ziekenhuis Brussel (UZB), Vrije Universiteit Brussel (VUB), Brussels, Belgium

Author statement

MB was responsible for study design, statistical analysis, performing the procedures and drafting of the final manuscript. GV, JS and RvW collected data, performed procedures and aided in drafting of the manuscript. JL collected data, aided in statistical analysis and drafting of the initial versions of the manuscript. GDA, EPCR, SC, MF and JD collected data and critically revised the manuscript. VG, JJ, HT and BT performed the surgical procedures and critically revised the final version. HvM, WL, PGA, RK and SVDM performed the procedures and critically revised the final version of the manuscript. All authors read and approved the final version of the manuscript.

Corresponding authors:

Michiel Bronswijk MD and Schalk W. Van der Merwe MD, PhD

Department of Gastroenterology and Hepatology

University Hospitals Gasthuisberg, Herestraat 49 | B - 3000 Leuven |www.uzleuven.be

michiel.bronswijk@uzleuven.be and schalk.vandermerwe@uzleuven.be

Journal Pre-proof

Same-session Double EUS-bypass versus Surgical Gastroenterostomy and Hepaticojejunostomy: An International Multicenter Comparison

Michiel Bronswijk MD[1,2], Giuseppe Vanella MD[3], Roy L.J. van Wanrooij MD PhD[4,5], Jayanta Samanta MD[6], Jonas Lauwereys BSc[1,2], Enrique Pérez-Cuadrado-Robles MD PhD[7], Giuseppe Dell'Anna MD[3], Jahnvi Dhar MD[6], Vikas Gupta MS MCh[6], Hannah van Malenstein MD PhD[1], Wim Laleman MD PhD[1], Joris Jaekers MD[8], Halit Topal MD[8], Baki Topal MD PhD[8], Stefano Crippa, MD PhD[9], Massimo Falconi MD[9], Marc G. Besselink MD PhD[10,11], Nouredin Messaoudi MD PhD[12], Paolo Giorgio Arcidiacono MD PhD[3], Rastislav Kunda MD PhD[12] and Schalk Van der Merwe MD PhD[1]

Journal Pre-proof

Abstract

Background and Aims:

Gastric outlet and biliary obstruction are common manifestations of gastrointestinal malignancies and some benign diseases, for which a standard treatment would be surgical gastroenterostomy and hepaticojejunostomy (i.e. 'double bypass'). Therapeutic endoscopic ultrasound (EUS) has allowed for the creation of an EUS-guided double bypass. However, same-session double EUS-bypass has only been described in small proof-of-concept series and lack comparison with surgical double bypass.

Methods:

A retrospective multicenter analysis was performed of all consecutive same-session double EUS-bypass procedures performed in 5 academic centers. Surgical comparators were extracted from these centers' databases from the same time interval. Efficacy, safety, hospital stay, nutrition and chemotherapy resumption, long-term patency and survival were compared.

Results:

In total, 154 patients were identified, of which 53 (34.4%) received treatment with EUS and 101 patients with surgery (65.6%). At baseline, patients undergoing EUS exhibited higher ASA scores and a higher median Charlson Comorbidity Index (9.0 [IQR 7.0-10.0] vs. 7.0 [IQR 5.0-9.0], p<0.001).

Technical success (96.2% vs. 100%, p=0.117) and clinical success rates (90.6% vs. 82.2%, p=0.234) were similar when comparing EUS and surgery. Overall (11.3% vs. 34.7%, p=0.002) and severe adverse events (3.8% vs. 19.8%, p=0.007) occurred more frequently in the surgical group. In the EUS group, median time to oral intake (0 [IQR 0-1] vs. 6 [IQR 3-7] day(s), p<0.001) and hospital stay (4.0 [IQR 3-9] vs 13 [IQR 9-22] days, p<0.001) were significantly shorter.

Conclusion:

Despite being used in a patient population with more comorbidities, same-session double EUS-bypass achieved similar technical and clinical success, and was associated with fewer overall and severe adverse events when compared to surgical gastroenterostomy and hepaticojejunostomy.

Journal Pre-proof

Introduction

Biliary and gastric outlet obstruction (GOO) are common manifestations of gastrointestinal malignancies and some benign diseases, such as chronic pancreatitis[1-3]. Whether occurring simultaneously at diagnosis or during the course of the disease, these obstructive manifestations are likely to both require intervention. In the past, GOO was mainly treated with open or laparoscopic gastroenterostomy[4,5]. From the 90's onwards, fueled by the development of self-expandable metal stents (SEMS), a shift occurred towards enteral stenting. In 2012, another revolution in stent design facilitated creation of an endoscopic ultrasound (EUS)-guided gastroenterostomy (EUS-GE)[6]. Since its introduction, EUS-GE has slowly found its way from initial animal studies into clinical practice and society guidelines. It has shown a lower need for re-intervention and superior clinical success when compared to enteral stenting[7-9], as well as equal efficacy, fewer adverse events (AE) and reduced median hospital stay when compared to surgery[10-14]. Whilst randomized confirmation is awaited, these retrospective studies suggest that EUS-GE should be the preferred option in the management of malignant GOO, due to its minimal invasiveness and surgical-range efficacy[15].

Besides GOO, local invasion or extrinsic compression may also lead to biliary obstruction[16]. Whilst ERCP remains the gold standard, GOO may often prevent retrograde biliary interventions. Endoscopic alternatives in the past mainly consisted of enteral stenting with percutaneous biliary drainage or through-the-mesh stenting. Many patients who suffered both GOO and biliary obstruction were therefore often referred for surgical gastroenterostomy and hepaticojejunostomy (SGJ). EUS-guided biliary drainage (EUS-BD) has proven to be an excellent back-up strategy when ERCP fails or is not feasible, and has been incorporated in various management algorithms[15]. Evidence is much more limited when GOO and biliary obstruction occur simultaneously, with initial data showing that EUS-GE plus EUS-BD (i.e. 'double EUS-bypass') might provide excellent long-term results in this setting and might overcome the intrinsic limitations of surgery, enteral stenting and percutaneous approaches[17-21]. However, in most studies double EUS-bypass has not been performed in the same session or has not been compared to surgical double bypass, which theoretically represents the standard in terms of efficacy and long-term patency.

The aim of this study was therefore to compare the efficacy and safety of same-session EUS-guided versus surgical double bypass.

Journal Pre-proof

Journal Pre-proof

Methods

We performed an observational retrospective multicenter cohort study. All consecutive same session double EUS-bypass procedures were collected from the individual institutional databases between July 2015 and April 2022. Inclusion criteria consisted of: (1) simultaneous presence of symptomatic GOO and biliary obstruction, (2) endoscopic or radiological confirmation of benign or malignant gastro-duodenal and biliary stenosis and (3) treatment with double EUS-bypass (EUS-GE + EUS-BD) performed during the same procedure. Participating centers were also invited to submit surgical cases from the same time frame. Considering surgical cases, both open and laparoscopic surgery with gastroenterostomy and hepaticojejunostomy (with or without cholecystectomy) were eligible for inclusion. No additional techniques or resections were allowed, as to minimize potential confounding by adjunctive procedures. For both approaches, age, sex, underlying disease and disease stage, as well as presence of ascites and peritoneal carcinomatosis were collected.
Each patient gave his or her written consent with regards to the individual procedures. Central Institutional Review Board-approval was obtained from the University Hospitals Leuven (study identifier: s65484) and at each participating center.

Endpoints

The primary endpoint was clinical success. Clinical success was defined as 1) gastric outlet obstruction score system (GOOSS) of ≥2[9,12,14,18,22] (capability to tolerate at least a soft diet) together with 2) post-procedural decrease in bilirubin of >50% at 1-month post-intervention or successful treatment of cholangitis. Bilirubin serum levels at baseline and at 48 hours post-double EUS-bypass were extracted, as well as maximum bilirubin change within 1-month post-intervention. Food intake grade was extracted from the electronic patient file or during subsequent follow-up. Technical and clinical success, as well as bilirubin levels and food intake grading will be described further under the header 'efficacy'. Regarding safety, the ASGE lexicon for adverse events was used to stratify AE in mild, moderate, severe or fatal events[23]. Furthermore, the overall anesthesiology risk and severity of underlying comorbidities were assessed using the American Society of Anesthesiologists-score (ASA) and Charlson Comorbidity Index (CCI)[24-26]. Hospital stay, weight change after 6 months, 'time to oral intake' and 'time to full diet' (GOOSS of 4) were also evaluated.

Follow-up

Gastroenterostomy or biliary dysfunction over time, as well as distal obstruction rates, were also considered. Gastroenterostomy dysfunction was defined as recurrence of obstructive symptoms (GOOSS ≤ 1) after former clinical success, with confirmation of recurrent GOO by endoscopy or imaging studies. Biliary dysfunction was defined as a de novo increase in bilirubin levels or cholangitis after a former clinical success requiring reintervention. Mechanical obstructions during follow-up, located downstream the gastroenterostomy site without signs of EUS-GE or SGJ dysfunction, were recorded as 'distal obstructions'.

Procedure: Double EUS-bypass.

All EUS procedures were performed under either general anesthesia or deep sedation, as well as prophylactic broad-spectrum antibiotics. In all centers procedures were done using the same sequence: EUS-GE was performed first, followed by EUS-BD[20]. For EUS-GE, both the Wireless EUS-gastroenterostomy Simplified Technique (WEST) (**Figure 1**) and endoscopic ultrasonography-guided double-balloon-occluded gastrojejunostomy bypass (EPASS) were used, as previously described[14,27-30]. For EUS-BD, a variety of techniques were allowed: from intrahepatic techniques, such as EUS-guided rendez-vous (EUS-RV), EUS-guided antegrade stenting (EUS-AS) or EUS-guided hepaticogastrostomy (EUS-HG), to extrahepatic techniques, mainly EUS-guided choledocho-duodenostomy (EUS-CD). For the intrahepatic techniques, the peripheral bile duct in segment 2 or 3 was accessed using a 19G or 22G-needle. Following insertion of a guidewire, EUS-RV was performed by advancing the

Journal Pre-proof

guidewire deep into the duodenum and carefully switching to a duodenoscope, provided the gastroduodenal stricture can be crossed, classic ERCP could be performed. However, in the vast majority of patients with GOO, EUS-RV was not feasible. In these cases, EUS-CD, EUS-AS or EUS-HG were considered. After guidewire advancement, a transgastric trajectory was made (with or without electrocautery) and a transpapillary SEMS could be placed in antegrade fashion (uncovered or fully-covered SEMS, 60x10 or 80x10mm, Wallflex, Boston Scientific, Marlborough, MA, USA), draining the bile duct through the classic anatomical route into the duodenum (**Figure 2**)[17]. If the guidewire could not be advanced through the stenosis or in cases where antegrade stenting was undesirable, a partially-covered SEMS was placed (80x8 or 80x10mm, Giobor, Taewoong Medical Co.Ltd, Gyeonggi-do, South-Korea), creating an EUS-HG (**Figure 3**). For extrahepatic biliary drainage of distal biliary strictures, EUS-CD was considered. With this technique, the common bile duct above the stricture was identified from the duodenal bulb and drained into the duodenum using either a step-wise placement of a fully-covered SEMS or free-hand electrocautery-enhanced LAMS insertion (6x8 or 8x8mm, Hot-Axios; Boston Scientific, Marlborough, MA, USA) (**Figure 4**). For each procedure, stent type and size, as well as procedure duration were documented.

Procedure: Surgical gastroenterostomy and hepaticojejunostomy.

All surgical procedures were performed under prophylactic broad spectrum antibiotic therapy, both laparoscopic and open procedures were eligible for inclusion. For laparoscopic procedures, after gaining access to the abdomen, the abdomen was inflated with CO2 to an intra-abdominal pressure of 10 to 15mmHg. The procedure was performed through 3 or 4 laparoscopic ports. For an open procedure an upper midline incision was used. Upon entering the abdomen an exploration was performed. Sequentially followed by dissection of the hepatoduodenal ligament with preparation of the bile duct. The bowel was transected at a short distance from the ligament of Treitz. The proximal jejunal loop was either passed through (transmesocolic) or above the mesocolon transversum (antecolic) to construct an end-to-side or side to side hepaticojejunostomy. Then an antecolic isoperistaltic side-to-side gastroenterostomy and a side-to-side entero-enterostomy anastomosis was performed (Roux-en-Y reconstruction). Besides pre-emptive cholecystectomy, other adjunctive surgical interventions were not allowed, in an effort to prevent potential interference with outcomes. All surgical procedures were performed by surgeons with extensive experience in hepatopancreatobiliary and abdominal surgery, operating in a high-volume academic centers.

Statistical analysis

Categorical variables were reported as frequencies (%) and Fisher's Exact test or Chi-squared test were used to compare these variables. Continuous variables were reported as medians and interquartile range (IQR) or means ± standard deviation (SD). Student's *t* test and Mann-Whitney *U* test were used for comparing normally and non-normally distributed continuous variables. Kaplan-Meier analysis was used for overall post-procedural survival analysis, whereas the log-rank test was used for corresponding comparisons. For clinical success, both an intention-to-treat and per-protocol analysis were provided. A p-value of <0.05 was considered significant. SPSS version 26.0 (IBM, Chicago, IL, USA) was used for the statistical analysis.

Journal Pre-proof

Results

In total, 53(34.4%) were treated with EUS, whereas 101 patients underwent SGJ (65.6%). Inclusion rates per center are shown in **Supplementary Table 1**. Mean age and gender distribution were similar, whereas different patterns of underlying disease were seen (**Table 1**). Pancreatic cancer was the most common primary disease (54.7% vs. 68.3%, p=0.114), followed by ampullary cancer (5.7% vs. 9.9%, p=0.544), cholangiocarcinoma (11.3% vs. 2.0%, p=0.020) and neuroendocrine tumors (7.5% vs. 2.0%, p=0.182). Patients with benign disease were also included, with 1 patient in the EUS group (1.9%), attributed to chronic pancreatitis with secondary biliary obstruction and GOO, and 6 patients in the surgical group (5.9%, p=0.423). Regarding ASA-score distribution, significantly higher scores were seen in the EUS group. More specifically, no ASA-I patients were included in the EUS group, whereas no ASA-IV patients were treated with SGJ. When comparing median Charlson Comorbidity Index (CCI), EUS-treated patients scored significantly higher (9.0 [IQR 7.0-10.0] vs. 7.0 [IQR 5.0-9.0], p<0.001). No major differences were observed regarding disease stage, with local invasion being observed in 19 (35.8%) of double EUS-bypass patients vs. in 40 (39.6%) of surgical patients (p= 0.728). Local invasion with synchronous liver metastases were present in 12 (22.6%) vs. 28 patients (27.7%, p=0.565), whilst diffuse metastatic disease was present in 7 (13.2%) vs. 20 patients (19.8%, p=0.376) respectively. Ascites, a potential sign of advanced oncological disease, was significantly more common amongst EUS patients (11 patients [20.8%]) when compared to surgical patients (1 patient [1.0%], p<0.001).

Efficacy

Clinical success, using intention-to-treat analysis, was achieved in 90.6% and 82.2% respectively (p=0.234). Per-protocol clinical success was significantly higher in the EUS group (94.1% vs. 82.2%, p=0.049), which was mainly attributed to gastroenterostomy failure in the surgical group, due to malignant or post-operative gastroparesis (n=4), need for continued parenteral feeding or nasogastric decompression (n=3) or persistent vomiting (n=2). No differences in clinical success rates were seen when comparing laparoscopic (n=10) with open SGJ (20% vs. 15.6%, p=0.716). Technical success was achieved in 51 out of 53 EUS-treated patients (96.2%) vs. 100% in the SGJ group (p=0.117). Two LAMS maldeployments occurred during EUS-GE, of which one could be salvaged endoscopically by stent-in-stent placement, whereas the other patient required rescue surgery. After a technically successful procedure, median time to oral intake was significantly shorter in the EUS group (0 [IQR 0-1] vs. 6 [IQR 3-7] day(s), p<0.001) (**Table 2**).

Regarding biliary drainage, efficacy was evaluated by biochemical response. At baseline, a trend towards higher median bilirubin levels was identified in the EUS group (3.8 [IQR 2.8-8.9] vs. 2.2 mg/dl [IQR 0.7-6.2], p=0.064). Following biliary drainage, bilirubin decrease of >50% (92.5% vs. 93.1%, p=1.000) was comparable. When focusing on approaches to EUS-BD in particular, EUS-HG (n=16) or EUS-CD (n=29) were used in the majority of procedures, whereas EUS-AS and rendez-vous were only applied in 7 and 1 case(s) respectively (**Table 3**). When compared to EUS-HG, all approaches achieved similar technical and clinical success, with different stents being used for each technique.

Safety

Overall, 41 patients suffered AE (26.6%), with fewer overall AE in the EUS group (6 [11.3%) when compared to patients undergoing SGJ (35 [34.7%], p=0.002). Using the ASGE lexicon for AE, mild AE occurred in similar proportions of patients (3.8% vs. 4.0%, p=1.000). These mild AE mostly consisting of post-procedural pain (n=1) or mild post-interventional cholangitis (n=2), which were treated conservatively with either opioid analgesia or antimicrobial therapy.
For moderate AE, there was a trend towards more AE in the surgical group (3.8% vs. 14.9%, p=0.055), mostly due to post-operative collections or leaks (5.9%) and post-procedural sepsis (4.0%). Two moderate AE occurred in the EUS group, consisting of two bleeding events at the EUS-GE site, for which endoscopic hemostasis was provided in one patient, and a

Journal Pre-proof

conservative approach was taken in the other. Fewer severe AE were seen in the EUS group (2 [3.8%] vs. 20 [19.8%], p=0.007), fueled by a higher incidence of post-interventional infection (0 [0.0%] vs. 10 [9.9%] events, p=0.016) and anastomotic bleeding (0 [0.0% vs. 5 [5.0%] events, p=0.165) following surgery. In the double EUS-bypass group, 1 hepatic pseudoaneurysm occurred following antegrade stenting, for which >1 night ICU stay and angiography-guided embolization was required. The other severe AE consisted of an EUS-GE maldeployment, for which endoscopic salvage failed and rescue surgery was performed (see above). Four fatal AE occurred amongst surgically-treated patients (0.0% vs. 4.0%, p=0.229), which were all related to major bleeding events. Regarding safety for each EUS-BD subtype, only EUS-AS led to significantly more overall AE when compared to EUS-HG (0 [0.0%] vs. 3 [42.9%] events, p=0.020) (**Table 3**).

Secondary outcomes

In the EUS group, median hospital stay was significantly shorter (4.0 [IQR 3-9] vs 13 [IQR 9-22] days, p<0.001). Furthermore, a significantly shorter median procedure duration was seen (51 [IQR 32-77] vs. 198 [IQR 139-263] minutes, p<0.001). When comparing EUS-BD techniques, shorter procedure duration (50 [32-75] vs. 47 [32-73] minutes, p=0.014) and hospital stay were observed (4 [3-9] vs. 4 [3-9] days, p=0.026) in favor of EUS-CD (when compared to EUS-HG). Considering post-procedural survival, no major differences were detected when comparing EUS with surgery (179 [IQR 98-409] vs. 158 [IQR 35-353] days, p=0.101), or amongst EUS-BD techniques (**Table 4**).

Follow-up

Gastroenterostomy dysfunction was only identified following surgery, with 4 events in the surgical group (0 [0.0%] vs. 4 [4.0%], p= 0.299). Conversely, a comparable incidence of distal obstruction (1 [1.9%] vs. 2 [2.0%], p=1.000) and biliary dysfunction was seen in both groups (4 [7.5%] vs. 5 [5.0%] patients, p=0.495). Looking at the EUS group in more detail, biliary dysfunction occurred in both the EUS-HG and EUS-CD groups in 1 patient, whereas 2 patients (28.6%) suffered biliary dysfunction following EUS-AS (p=0.210). No statistically significant differences were seen when comparing post-procedural survival following EUS or surgery (**Supplementary Table 2**).

Journal Pre-proof

Journal Pre-proof

Discussion

In this international multicenter retrospective analysis of patients with both GOO and biliary obstruction, we found that same-session double EUS-bypass was associated with fewer overall and severe AE, whilst achieving similar clinical and technical success when compared to surgical double bypass. Furthermore, a shorter time to oral intake, shorter hospital stay and less weight loss at 2 months were seen in the EUS group. These outcomes were observed notwithstanding more advanced disease and a higher prevalence of comorbidities amongst EUS-treated patients. These promising findings suggest that double EUS-bypass may be preferred over surgery, especially in patients with both GOO and biliary obstruction in the palliative setting.

Surgical gastroenterostomy, either open or laparoscopic, is still regarded as gold standard therapy in the management of GOO. In the last decade, five retrospective studies have compared surgery with EUS-GE, showing similar technical and clinical success[12-14,31,32]. In the last three studies, fewer adverse events and shorter hospital stay were seen in favor of EUS[12-14,31,32]. The current results are in line with these recent studies, showing surgical-range efficacy for EUS with fewer adverse events compared to surgery. Regarding clinical success in particular, we detected a lower per-protocol clinical success for patients who underwent surgery. One could argue that perhaps some clinical failures may have been recorded as such, due to the occurrence of postoperative ileus or because of need for parenteral feeding in the context of malnutrition. However, reasons for clinical failure mainly consisted of lack of clinical response with persistent vomiting (n=7), anastomotic dehiscence or stenosis (n=2), bilirubin decrease <50% (n=2) or early death without attaining clinical success.
The combination of more adverse events following surgery in a patient population prone to complications, has presumably influenced physicians to steer away from surgery for malignant GOO in the non-curative setting [33]. In this specific group of patients, enteral stenting is often preferred despite the fact that this technique is plagued by relatively high rates of stent dysfunction when compared to EUS-GE or surgery[7-9]. This becomes an even bigger issue when GOO and malignant biliary obstruction occur simultaneously, as clinical success of biliary drainage is highly dependent on efficient gastroduodenal transit[34]. Especially for those patients requiring simultaneous (EUS-guided) biliary drainage, EUS-GE may hold significant advantages over enteral stenting.

A recent multicenter analysis compared various endoscopic approaches when treating patients with both biliary and gastric outlet obstruction[21]. This proof-of-concept study found that type III duodenal obstruction and some specific endoscopic combinations (above all enteral stenting in combination with EUS-CD) were independent risk factors for stent dysfunction. It was furthermore shown that EUS-CD was less effective in the context of GOO, whereas no stent dysfunctions occurred when EUS-GE was combined with EUS-HG. In the present study, similar rates of biliary dysfunction were seen amongst the different approaches (EUS-AS=2, EUS-CD=1 and EUS-HG=1). A recent retrospective analysis of 23 same-session procedures using EUS-GE with EUS-HG in all cases, showed high technical success rates and 72.7% of patients experienced >50% bilirubin decrease at one month[19]. Amongst these 23 patients, most of unplanned reinterventions (n=3, 13%) and adverse events (n=5, 22%) were due to hepatobiliary complications. This is confirmed in the present study suggesting that biliary complications are the main drivers of reinterventions when double EUS-bypass is performed. While more prospective data on biliary drainage in patients with GOO are awaited, most published studies support the use of EUS-GE plus EUS-HG. This specific combination might prove most effective, given that bile is diverted away from the tumor obstruction and lower perceived sensitivity to food impaction and cholangitis, together with an acceptable safety profile[35].

It is conceivable that performing double EUS-bypass procedures in a single session might actually increase complications and potentially explain some specific adverse events. However in this study, all adverse events in the EUS group

(misdeployments, bleedings, etc) were complications associated with either EUS-BD or EUS-GE, and were not attributed to the simultaneous execution of both. On the other hand, doing these procedures in a single session may hold several potential advantages, such as reducing interval to oral intake, full diet resumption, hospital discharge, chemotherapy (re-)initiation and halving the anesthetic risk. This question has been evaluated by a 2021 French monocentric study, which compared same-session with separate session approaches, showing a significantly shorter hospital stay (7.5 vs. 12.6 days, p=0.04) with even a trend towards lower adverse events for the same-session procedures (26.7% vs. 56.3, p=0.100)[36].

Another factor that has been associated with adverse events is ascites. Historically, ascites has always been regarded as a strict contraindication for either EUS-GE and EUS-BD[15,28,37,38]. In the current study, little over a fifth of patients undergoing a double EUS-bypass exhibited varying degrees of ascites, without leading to ascites-related complications, confirming results by previous studies[8,14,39]. Although successful double EUS-bypass procedures were performed in patients with ascites, the presence of ascites should prompt a high degree of suspicion towards underlying, potentially obstructive or diffuse peritoneal disease which may be associated with clinical failure, significantly reduced survival and a higher risk of down-stream obstruction over time[12,37,38].

Limitations and strengths:

Limitations to the current study include the retrospective and non-matched design, uneven inclusion rates, as well as lack of information on chemotherapy (re-)initiation and surgical anastomosis site. EUS-treated patients furthermore showed higher frailty, exhibited higher perceived anesthesia risk and potentially had more advanced disease stage and thus, a probable selection bias. Nevertheless, EUS-treated patients showed improved outcomes and similar post-procedural survival, highlighting the safety of double EUS-bypass in achieving excellent outcomes with a reduced invasiveness. Third, all procedures were performed in high-volume academic settings, suggesting generalizability as a potential limitation. And last, inclusion rates differed amongst centers, although we tried to minimize bias by inviting every center to include both same-session double EUS-bypass procedures, as well as surgical cases. The higher number of surgical cases with respect to the EUS group is related to the rigid inclusion criteria of this study, involving only same-session EUS procedures, and therefore excluding 1) double EUS-bypass performed on different time points and 2) cases in which a combined obstruction was solved endoscopically by EUS-GE + ERCP. Conversely, some SGJ were performed after intraoperative exclusion of resectability and might have included “preventive” or ”early” surgical derivations in unresectable malignancies with known GOO and biliary obstruction.

Until recently, few studies were available comparing EUS-GE and surgery in the context of ‘isolated’ GOO. For same-session double EUS-bypass this is even more true[18,19]. By using an international multicenter cohort of consecutive surgical cases, we were able to compare same-procedure double EUS-bypass to SGJ, making the overall sample size and novelty both clear advantages to the current study. Compared to previous work, we also attempted to improve data interpretation, by including more information regarding patient profile, such as ASA score and Charlson Comorbidity Index. And last, one could argue that the current outcomes could depend on selection of the comparator group. We therefore only included consecutive cases from the same exact time frame, included only isolated SGJ (with or without cholecystectomy) and also invited surgeons to participate in the current study.

Journal Pre-proof

Conclusions

Despite being used in a frailer population and potentially more advanced disease stage, same-session double EUS-bypass achieved similar efficacy with lower overall and severe adverse events when compared to surgery. The current study furthermore suggests that EUS-GE and EUS-BD can be performed safely and effectively in a single session. Although future efforts should be directed towards prospectively confirming these results, the current study underlines the usefulness of therapeutic EUS in patients with both GOO and biliary obstruction.

Acknowledgements

None

Conflict of interest:

MB received grants from Boston-Scientific, Ovesco/Fides Medical and has consultancy agreements with Dekra and Taewoong – Prion Medical. RvW holds a consultancy agreement with Boston-Scientific. SVDM holds the Cook chair in Interventional endoscopy and holds consultancy agreements with Cook, Pentax and Olympus. WL co-chairs the Boston-Scientific Chair in Therapeutic Biliopancreatic Endoscopy with SVDM and has consultancy agreements with Boston Scientific and Cook. EPCR, RvW and HvM hold consultancy agreements with Boston-Scientific. Rastislav Kunda is consultant for Boston Scientific, Omega Medical Imaging, Ambu, M.I.Tech, Apollo EndoSurgery, EndiaTx, Medconsgroup, Q3 Medical - AMG International and Tigen Pharma. GV, GDA, JL, JS, JD, VG, JJ, HT, BT, MGB and NM have nothing to declare.

Funding

None

Journal Pre-proof

References

1. Parisi A, Reim D, Borghi F, et al. Minimally invasive surgery for gastric cancer: A comparison between robotic, laparoscopic and open surgery. *World J Gastroenterol*. Apr 7 2017;23(13):2376-2384. doi:10.3748/wjg.v23.i13.2376
2. Shone DN, Nikoomanesh P, Smith-Meek MM, Bender JS. Malignancy is the most common cause of gastric outlet obstruction in the era of H2 blockers. *Am J Gastroenterol*. Oct 1995;90(10):1769-70.
3. Jeong SJ, Lee J. Management of gastric outlet obstruction: Focusing on endoscopic approach. *World J Gastrointest Pharmacol Ther*. Jun 9 2020;11(2):8-16. doi:10.4292/wjgpt.v11.i2.8
4. Ly J, O'Grady G, Mittal A, Plank L, Windsor JA. A systematic review of methods to palliate malignant gastric outlet obstruction. *Surg Endosc*. Feb 2010;24(2):290-7. doi:10.1007/s00464-009-0577-1
5. Rodríguez JI, Kutscher M, Lemus M, Crovari F, Pimentel F, Briceño E. Palliative gastrojejunostomy in unresectable cancer and gastric outlet obstruction: a retrospective cohort study. *Ann R Coll Surg Engl*. Mar 2021;103(3):197-202. doi:10.1308/rcsann.2020.7016
6. Binmoeller KF, Shah JN. Endoscopic ultrasound-guided gastroenterostomy using novel tools designed for transluminal therapy: a porcine study. *Endoscopy*. May 2012;44(5):499-503. doi:10.1055/s-0032-1309382
7. Chen YI, Itoi T, Baron TH, et al. EUS-guided gastroenterostomy is comparable to enteral stenting with fewer re-interventions in malignant gastric outlet obstruction. *Surg Endosc*. Jul 2017;31(7):2946-2952. doi:10.1007/s00464-016-5311-1
8. Ge PS, Young JY, Dong W, Thompson CC. EUS-guided gastroenterostomy versus enteral stent placement for palliation of malignant gastric outlet obstruction. *Surg Endosc*. Oct 2019;33(10):3404-3411. doi:10.1007/s00464-018-06636-3
9. van Wanrooij RLJ, Vanella G, Bronswijk M, et al. Endoscopic ultrasound-guided gastroenterostomy versus duodenal stenting for malignant gastric outlet obstruction: an international, multicenter, propensity score-matched comparison. *Endoscopy*. Mar 24 2022;doi:10.1055/a-1782-7568
10. McCarty TR, Garg R, Thompson CC, Rustagi T. Efficacy and safety of EUS-guided gastroenterostomy for benign and malignant gastric outlet obstruction: a systematic review and meta-analysis. *Endosc Int Open*. Nov 2019;7(11):E1474-E1482. doi:10.1055/a-0996-8178
11. Antonelli G, Kovacevic B, Karstensen JG, et al. Endoscopic ultrasound-guided gastro-enteric anastomosis: A systematic review and meta-analysis. *Dig Liver Dis*. Nov 2020;52(11):1294-1301. doi:10.1016/j.dld.2020.04.021
12. Khashab MA, Bukhari M, Baron TH, et al. International multicenter comparative trial of endoscopic ultrasonography-guided gastroenterostomy versus surgical gastrojejunostomy for the treatment of malignant gastric outlet obstruction. *Endosc Int Open*. Apr 2017;5(4):E275-E281. doi:10.1055/s-0043-101695
13. Perez-Miranda M, Tyberg A, Poletto D, et al. EUS-guided Gastrojejunostomy Versus Laparoscopic Gastrojejunostomy: An International Collaborative Study. *J Clin Gastroenterol*. Nov/Dec 2017;51(10):896-899. doi:10.1097/MCG.0000000000000887
14. Bronswijk M, Vanella G, van Malenstein H, et al. Laparoscopic versus EUS-guided gastroenterostomy for gastric outlet obstruction: an international multicenter propensity score-matched comparison (with video). *Gastrointest Endosc*. Apr 11 2021;doi:10.1016/j.gie.2021.04.006
15. van der Merwe SW, van Wanrooij RLJ, Bronswijk M, et al. Therapeutic endoscopic ultrasound: European Society of Gastrointestinal Endoscopy (ESGE) Guideline. *Endoscopy*. Feb 2022;54(2):185-205. doi:10.1055/a-1717-1391
16. Sugimoto M, Sonntag DP, Flint GS, et al. Biliary Stenosis and Gastric Outlet Obstruction: Late Complications After Acute Pancreatitis With Pancreatic Duct Disruption. *Pancreas*. Jul 2018;47(6):772-777. doi:10.1097/mpa.0000000000001064
17. Vanella G, Bronswijk M, Maleux G, van Malenstein H, Laleman W, Van der Merwe S. EUS-guided intrahepatic biliary drainage: a large retrospective series and subgroup comparison between percutaneous drainage in hilar stenoses or postsurgical anatomy. *Endosc Int Open*. Dec 2020;8(12):E1782-e1794. doi:10.1055/a-1264-7511
18. Brewer Gutierrez OI, Nieto J, Irani S, et al. Double endoscopic bypass for gastric outlet obstruction and biliary obstruction. *Endosc Int Open*. Sep 2017;5(9):E893-e899. doi:10.1055/s-0043-115386
19. Canakis A, Hathorn KE, Irani SS, Baron TH. Single session endoscopic ultrasound-guided double bypass (hepaticogastrostomy and gastrojejunostomy) for concomitant duodenal and biliary obstruction: A case series. *J Hepatobiliary Pancreat Sci*. Oct 7 2021;doi:10.1002/jhbp.1055
20. Bronswijk M, Vanella G, Van der Merwe S. Double EUS bypass: same sequence, different reasons. *VideoGIE*. Jun 2021;6(6):282. doi:10.1016/j.vgie.2021.01.008
21. Vanella G, Bronswijk M, van Wanrooij RLJ, et al. Combined endoscopic mAnagement of BiliaRy and gastrIc OutLET obstruction (CABRIOLET Study): A multicenter retrospective analysis. https://doi.org/10.1002/deo2.132. *DEN Open*. 2023/04/01 2023;3(1):e132. doi:https://doi.org/10.1002/deo2.132
22. Adler DG, Baron TH. Endoscopic palliation of malignant gastric outlet obstruction using self-expanding metal stents: experience in 36 patients. *Am J Gastroenterol*. Jan 2002;97(1):72-8. doi:10.1111/j.1572-0241.2002.05423.x
23. Cotton PB, Eisen GM, Aabakken L, et al. A lexicon for endoscopic adverse events: report of an ASGE workshop. *Gastrointest Endosc*. Mar 2010;71(3):446-54. doi:10.1016/j.gie.2009.10.027
24. Charlson ME, Pompei P, Ales KL, MacKenzie CR. A new method of classifying prognostic comorbidity in longitudinal studies: development and validation. *J Chronic Dis*. 1987;40(5):373-83. doi:10.1016/0021-9681(87)90171-8
25. Laor A, Tal S, Guller V, Zbar AP, Mavor E. The Charlson Comorbidity Index (CCI) as a Mortality Predictor after Surgery in Elderly Patients. *Am Surg*. Jan 2016;82(1):22-7.

Journal Pre-proof

26. Kobayashi K, Cooper GS, Chak A, Sivak MV, Jr., Wong RC. A prospective evaluation of outcome in patients referred for PEG placement. *Gastrointest Endosc*. Apr 2002;55(4):500-6. doi:10.1067/mge.2002.122577
27. Bronswijk M, van Malenstein H, Laleman W, et al. EUS-guided gastroenterostomy: Less is more! The wireless EUS-guided gastroenterostomy simplified technique. *VideoGIE*. Sep 2020;5(9):442. doi:10.1016/j.vgie.2020.06.012
28. van Wanrooij RLJ, Bronswijk M, Kunda R, et al. Therapeutic endoscopic ultrasound: European Society of Gastrointestinal Endoscopy (ESGE) Technical Review. *Endoscopy*. Mar 2022;54(3):310-332. doi:10.1055/a-1738-6780
29. Irani S, Itoi T, Baron TH, Khashab M. EUS-guided gastroenterostomy: techniques from East to West. *VideoGIE*. Feb 2020;5(2):48-50. doi:10.1016/j.vgie.2019.10.007
30. Itoi T, Itokawa F, Uraoka T, et al. Novel EUS-guided gastrojejunostomy technique using a new double-balloon enteric tube and lumen-apposing metal stent (with videos). *Gastrointest Endosc*. Dec 2013;78(6):934-939. doi:10.1016/j.gie.2013.09.025
31. Abbas A, Dolan RD, Bazarbashi AN, Thompson CC. Endoscopic ultrasound-guided gastroenterostomy versus surgical gastrojejunostomy for the palliation of gastric outlet obstruction in patients with peritoneal carcinomatosis. *Endoscopy*. Feb 4 2022;doi:10.1055/a-1708-0037
32. Kouanda A, Binmoeller K, Hamerski C, Nett A, Bernabe J, Watson R. Endoscopic ultrasound-guided gastroenterostomy versus open surgical gastrojejunostomy: clinical outcomes and cost effectiveness analysis. *Surg Endosc*. Jan 21 2021;doi:10.1007/s00464-020-08221-z
33. Jeurnink SM, Steyerberg EW, van Hooft JE, et al. Surgical gastrojejunostomy or endoscopic stent placement for the palliation of malignant gastric outlet obstruction (SUSTENT study): a multicenter randomized trial. *Gastrointest Endosc*. Mar 2010;71(3):490-9. doi:10.1016/j.gie.2009.09.042
34. Nakai Y, Hamada T, Isayama H, Itoi T, Koike K. Endoscopic management of combined malignant biliary and gastric outlet obstruction. *Dig Endosc*. Jan 2017;29(1):16-25. doi:10.1111/den.12729
35. Bronswijk M, Vanella G, van Wanrooij RLJ, Van der Merwe S. EUS-guided choledochoduodenostomy and duodenal stenosis: A marriage doomed to fail? *VideoGIE*. doi:10.1016/j.vgie.2022.08.021
36. Debourdeau A, Caillol F, Zemmour C, et al. Endoscopic management of concomitant biliary and duodenal malignant obstruction: Impact of the timing of drainage for one vs. two procedures and the modalities of biliary drainage. *Endosc Ultrasound*. Mar-Apr 2021;10(2):124-133. doi:10.4103/eus-d-20-00159
37. Basha J, Lakhtakia S, Yarlagadda R, et al. Gastric outlet obstruction with ascites: EUS-guided gastro-enterostomy is feasible. *Endosc Int Open*. //

14.12.2021 2021;09(12):E1918-E1923.
38. Bronswijk M, van Wanrooij RLJ, Vanella G, Van der Merwe S. EUS-guided gastroenterostomy in patients with ascites: What lies beneath? *Endosc Int Open*. //

14.04.2022 2022;10(04):E294-E294.
39. Basha J, Lakhtakia S, Yarlagadda R, et al. Gastric outlet obstruction with ascites: EUS-guided gastro-enterostomy is feasible. *Endosc Int Open*. Dec 2021;9(12):E1918-e1923. doi:10.1055/a-1642-7892

Journal Pre-proof

Journal Pre-proof

Figure legend

Figure 1.

Upper left: Fluoroscopic identification of the nasobiliary catheter.

Upper right: EUS-image, showing the dilated enteric loop with the LAMS-tip coming out of the working channel and the nasobiliary catheter located in the small bowel lumen (arrow).

Lower left: Fluoroscopic image after successful deployment of the electrocautery-tipped LAMS.

Lower right: Endoscopic view through the LAMS, showing the nasobiliary catheter inside the enteric loop in the distance, confirming successful intraluminal deployment.

Figure 2.

Fluoroscopic image, showing successful antegrade stenting through segment 2 using a fully-covered SEMS.

Figure 3.

Fluoroscopic image following successful EUS-GE and EUS-guided hepaticogastrostomy using a partially-covered SEMS in segment 2.

Figure 4.

EUS-guided choledocho-duodenostomy for a malignant distal obstruction using a lumen-apposing metal stent with coaxial double plastic pigtail stent after EUS-GE.

Journal Pre-proof

Table 1.

	EUS (n=53)		Surgery (n=101)		*P* value
Variable					
Age (years), mean ± SD	67,4	12,4	64,9	11,2	0.204
Sex, n (%)					
Female	23	43,4%	54	53,5%	0.309
ASA score					
I, n (%)	0	0,0%	11	10,9%	**0.017**
II, n (%)	13	24,5%	52	51,5%	**0.002**
III, n (%)	35	66,0%	38	37,6%	**0.001**
IV, n (%)	5	9,4%	0	0,0%	**0.004**
Charlson Comorbidity Index, median (IQR)	9,0	(7.0-10)	7	(5.0-9.0)	**<0.001**
Median follow up, days (IQR)	179	(98-409)	158	(35-353)	0.101
Primary disease					
Pancreatic cancer	29	54,7%	69	68,3%	0.114
Benign disease	1	1,9%	6	5,9%	0.423
Breast cancer	0	0,0%	6	5,9%	0.094
Cholangiocarcinoma/gallbladder cancer	6	11,3%	2	2,0%	**0.020**
Gastric cancer	0	0,0%	1	1,0%	1.000
Colorectal cancer	2	3,8%	2	2,0%	0.608
NET	4	7,5%	2	2,0%	0.182
Ampullary cancer	3	5,7%	10	9,9%	0.544
Cervix	1	1,9%	0	0,0%	0.344
Duodenal cancer	4	7,5%	1	1,0%	**0.048**
TCC	2	3,8%	0	0,0%	0.117
RCC	1	1,9%	0	0,0%	0.344
Disease stage					
Local invasion	19	35,8%	40	39,6%	0.728
Local and liver metastases	12	22,6%	28	27,7%	0.565
Diffuse metastatic	7	13,2%	20	19,8%	0.376
Disease manifestations					
Ascites	11	20,8%	1	1,0%	**<0.001**
Peritoneal carcinomatosis	9	17,0%	9	8,9%	0.186

Abbreviations: ASA: American Society of Anaesthesiologists, IQR: interquartile range, NET: neuroendocrine tumor, RCC: renal cell cancer, SD: standard deviation, TCC: transitional cell carcinoma.

Journal Pre-proof

Journal Pre-proof

Table 2

	EUS (n=53)		Surgery (n=101)		*P* value
Efficacy					
Technical success, n (%)	51	96.2%	101	100.0%	0.117
Clinical success*, n (%)	48/53	90.6%	83	82.2%	0.234
Per protocol clinical success, n (%)	48/51	94.1%	83	82.2%	**0.049**
Median time to oral intake, days (IQR)	0	(0-1)	6	(3-7)	**<0.001**
Full diet tolerability, n (%)	50/53	94.3%	22/27	81.5%	0.112
Median time to full diet, days (IQR)	3	(2-4)	9	(6-14)	
Gastroenterostomy dysfunction, n (%)	0	0.0%	4	4.0%	0.299
Median time to dysfunction, days (IQR)	N/A	N/A	130	(57-336)	
Biliary dysfunction, n (%)	4	7.5%	5	5.0%	0.495
Median time to dysfunction, days (IQR)	64	(43-67)	149	(39-265)	
Distal obstruction, n (%)	1	1.9%	2	2.0%	1.000
Median time to distal obstruction, days (IQR)	90	N/A	466	(246-686)	
Baseline bilirubin, median, mg/dl	3,8	(2.8-8.9)	2,2	0.7-6.2	**0.064**
Bilirubin decrease >25%	51	96.2%	98	97.0%	1.000
Bilirubin decrease >50%	49	92.5%	94	93.1%	1.000
Bilirubin decrease >75%	29	54.7%	31	30.7%	**0.005**

Abbreviations: IQR: interquartile rang EUS: endoscopic ultrasound,
N/A: not applicable.
*: intention to treat analysis.

Journal Pre-proof

	EUS (n=53)		Surgery (n=101)		*P* value
Safety					
Overall adverse events, n (%)	6	11.3%	35	34.7%	**0.002**
Mild, n(%)	2	3.8%	4	4.0%	1.000
Pain, n (%)	1	1.9%	0	0.0%	0.344
Post-procedural cholangitis, n (%)	1	1.9%	1	1.0%	1.000
Moderate, n(%)	2	3.8%	15	14.9%	**0.055**
Sepsis, n (%)	0	0.0%	4	4.0%	0.299
Post-interventional bleeding, n (%)	2	3.8%	3	3.0%	1.000
Post-operative collection, n (%)	0	0.0%	6	5.9%	0.094
Need for re-endoscopy, n (%)	1	1.9%	1	1.0%	1.000
Severe, n(%)	2	3.8%	20	19.8%	**0.007**
Hepatic pseudoaneurysm, n (%)	1	1.9%	0	0.0%	0.344
Prolonged anorexia, n (%)	0	0.0%	2	2.0%	0.546
Anastomotic bleeding, n (%)	0	0.0%	5	5.0%	0.165
Post-interventional infection, n (%)	0	0.0%	10	9.9%	**0.016**
Surgical (re-)intervention, n (%)	1	1.9%	2	2.0%	1.000
Fatal, n(%)	0	0.0%	4	4.0%	1.000
Hemorrhagic complications, n (%)	0	0.0%	4	4.0%	0.299

Journal Pre-proof

Secondary outcomes					
Median procedure duration, min (IQR)	51	(32-77)	198	(139-263)	**<0.001**
Median hospital stay, days (IQR)	4	(3-9)	13	(9-22)	**<0.001**
Median weight change after 2 months, kg (IQR)	-0.6	(-2.4-3.5)	-1.9	(-2.0-0.1)	**0.039**
Median post-procedural survival, days (IQR)	179	(98-409)	158	(35-353)	0.101

Journal Pre-proof

Table 3. Comparisons between various EUS-guided biliary drainage techniques.

	EUS-HG (n=16)		**EUS-CD (n=29**		*P* value*	**EUS-AS (n=7)**		*P* value*	**EUS-RV (n=1)**		*P* value*
Efficacy											
Technical success, n (%)	16	100%	27	93,1%	0.531	7	100,0%	1.000	1	100,0%	1.000
Clinical success, n (%)	15	93,8%	27	93,1%	1.000	5	71,4%	0.210	1	100,0%	1.000
Per protocol clinical success, n (%)	15	93,8%	27	100,0%	0.372	5	71,4%	0.210	1	100,0%	1.000
Gastroenterostomy dysfunction, n (%)	0	0,0%	0	0,0%	1.000	0	0,0%	1.000	0	0,0%	1.000
Biliary dysfunction, n (%)	1	6,3%	1	3,4%	1.000	2	28,6%	0.210	0	0,0%	1.000
pc-SEMS	16	100,0%	N/A	N/A	N/A	N/A	N/A	N/A	N/A	N/A	N/A
EC-LAMS	N/A	N/A	26	89,7%	N/A	N/A	N/A	N/A	N/A	N/A	N/A
fc-SEMS	0	0,0%	3	10,3%	0.542	4	57,1%	0.004	1	100,0%	0.058
uc-SEMS	N/A	N/A	N/A	N/A	N/A	3	42,9%	N/A	0	0.0%	1.000
Safety											
Overall adverse events, n (%)	0	0,0%	2	6,9%	0.531	3	42,9%	0.020	1	100,0%	0.058
Mild, n(%)	0	0,0%	0	0,0%	1.000	0	0,0%	1.000	1	100,0%	1.000
Post-ERCP pancreatitis, n (%)	0	0,0%	0	0,0%	1.000	0	0,0%	1.000	1	100,0%	1.000
Moderate, n(%)	0	0,0%	1	3,4%	1.000	2	28,6%	0.083	0	0,0%	1.000
Sepsis, n (%)	0	0,0%	1	3,4%	1.000	1	14,3%	0.304	0	0,0%	1.000
Post-interventional bleeding, n (%)	0	0,0%	0	0,0%	1.000	2	28,6%	0.083	0	0,0%	1.000
Need for re-endoscopy, n (%)	0	0,0%	0	0,0%	1.000	1	14,3%	0.304	0	0,0%	1.000
Severe, n(%)	0	0,0%	1	3,4%	1.000	1	14,3%	0.304	0	0,0%	1.000
EUS-GE LAMS misdeployment, n (%)	0	0,0%	1	3,4%	1.000	0	0,0%	1.000	0	0,0%	1.000
Pseudoaneurysm, n (%)	0	0,0%	0	0,0%	1.000	1	14,3%	0.304	0	0,0%	1.000
Surgical (re-)intervention, n (%)	0	0,0%	1	3,4%	1.000	0	0,0%	1.000	0	0,0%	1.000
Fatal, n(%)	0	0,0%	0	0,0%	1.000	0	0,0%	1.000	0	0,0%	1.000

Abbreviations: EC-LAMS: electrocautery-enhanced lumen apposing metal stent, ERCP: endoscopic retrograde cholangiopancreatography, EUS-AS: EUS-guided antegrade stenting, EUS-CD: EUS-guided choledochoduodenostomy, EUS-GE: EUS-guided gastroenterostomy, EUS-HG: EUS-guided hepaticogastrostomy, EUS-RV: EUS-guided rendez-vous, fc: fully-covered, N/A: not applicable, pc: partially-covered, SEMS: self-expandable metal stent, uc: uncovered.

*: Fisher's exact test, compared with EUS-HG.

Journal Pre-proof

Journal Pre-proof

Table 4. Secondary outcomes EUS-guided biliary drainage.

	EUS-HG (n=16)		**EUS-CD (n=29)**		*P* value*	**EUS-AS (n=7)**		*P* value*	**EUS-RV (n=1)**		*P* value*
Median procedure duration°, min (IQR)	50	(32-75)	47	(32-73)	0.014	81	(60-85)	0.271	106	N/A	N/A
Median hospital stay, days (IQR)	4	(3-9)	4	(3-9)	0.026	11	(7.8-14)	0.741	11	N/A	N/A
Median post-procedural survival, days (IQR)	175	(97-375)	186	(104-409)	0.596	154	(43.5-501)	0.242	348	N/A	N/A

Abbreviations: EUS-AS: EUS-guided antegrade stenting, EUS-CD: EUS-guided choledochoduodenostomy, EUS-GE: EUS-guided gastroenterostomy, EUS-HG: EUS-guided hepaticogastrostomy, EUS-RV: EUS-guided rendez-vous, IQR: interquartile range.

*: Fisher's exact test, compared with EUS-HG. °: consists of duration of both EUS-GE and EUS-BD subtype.

Journal Pre-proof

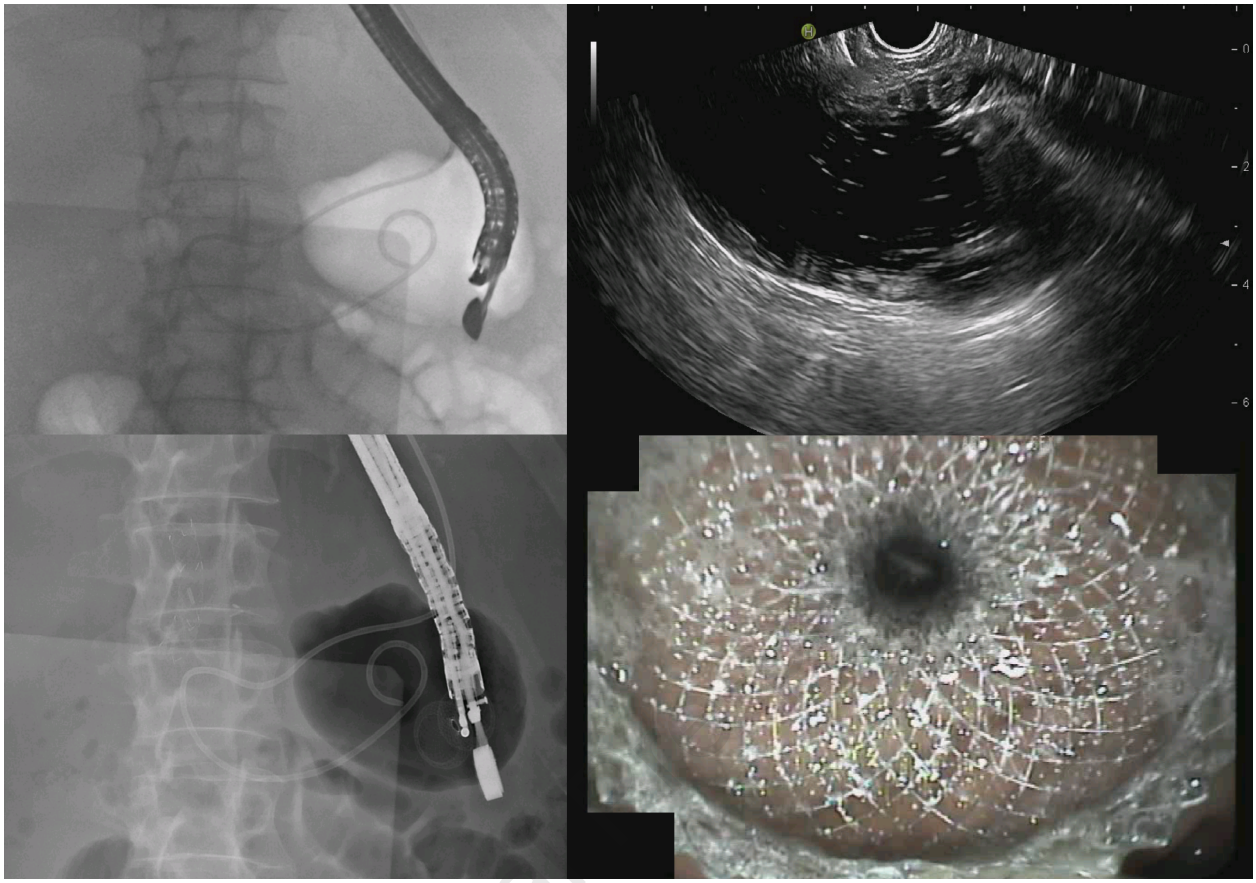

Journal

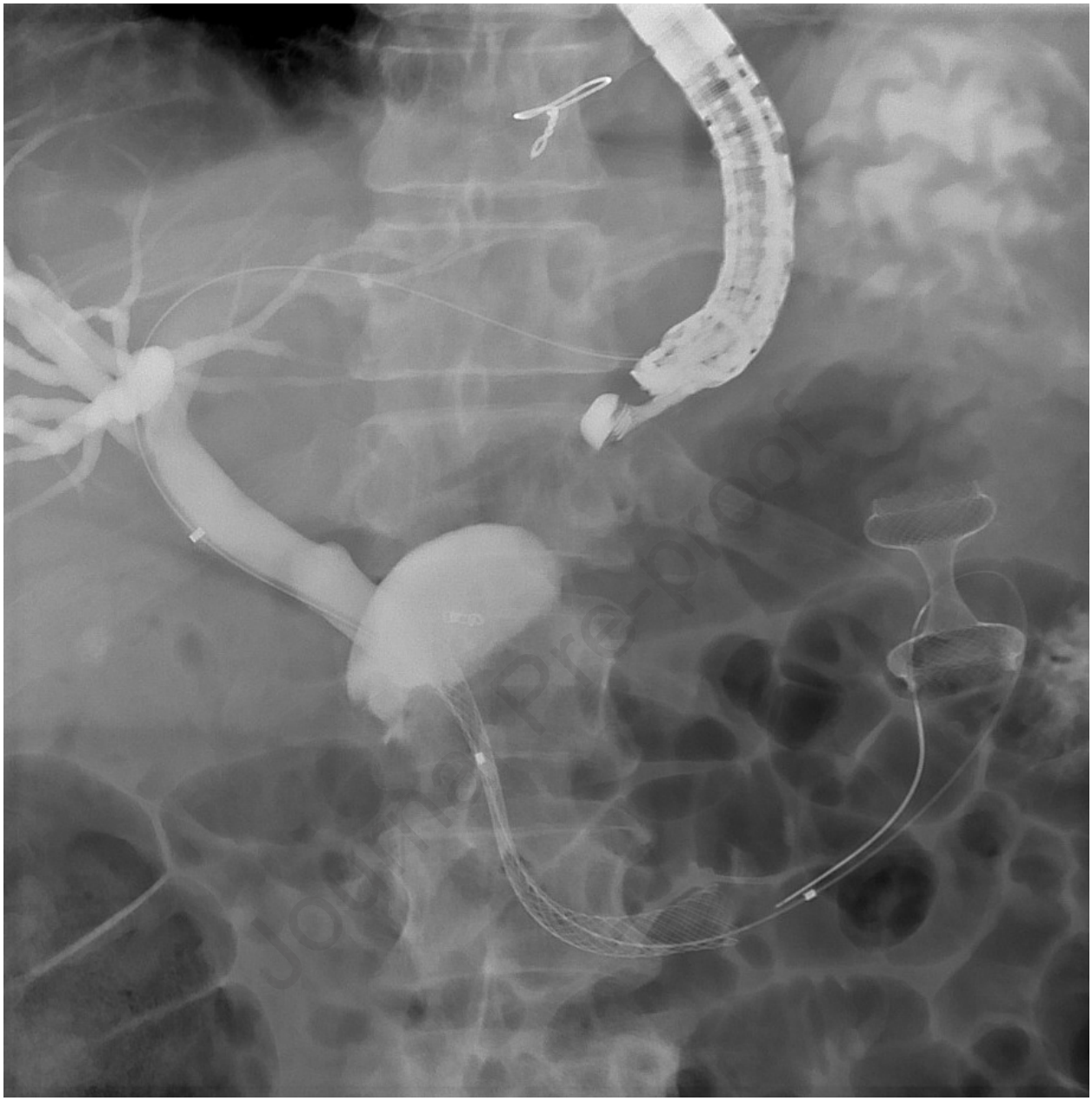

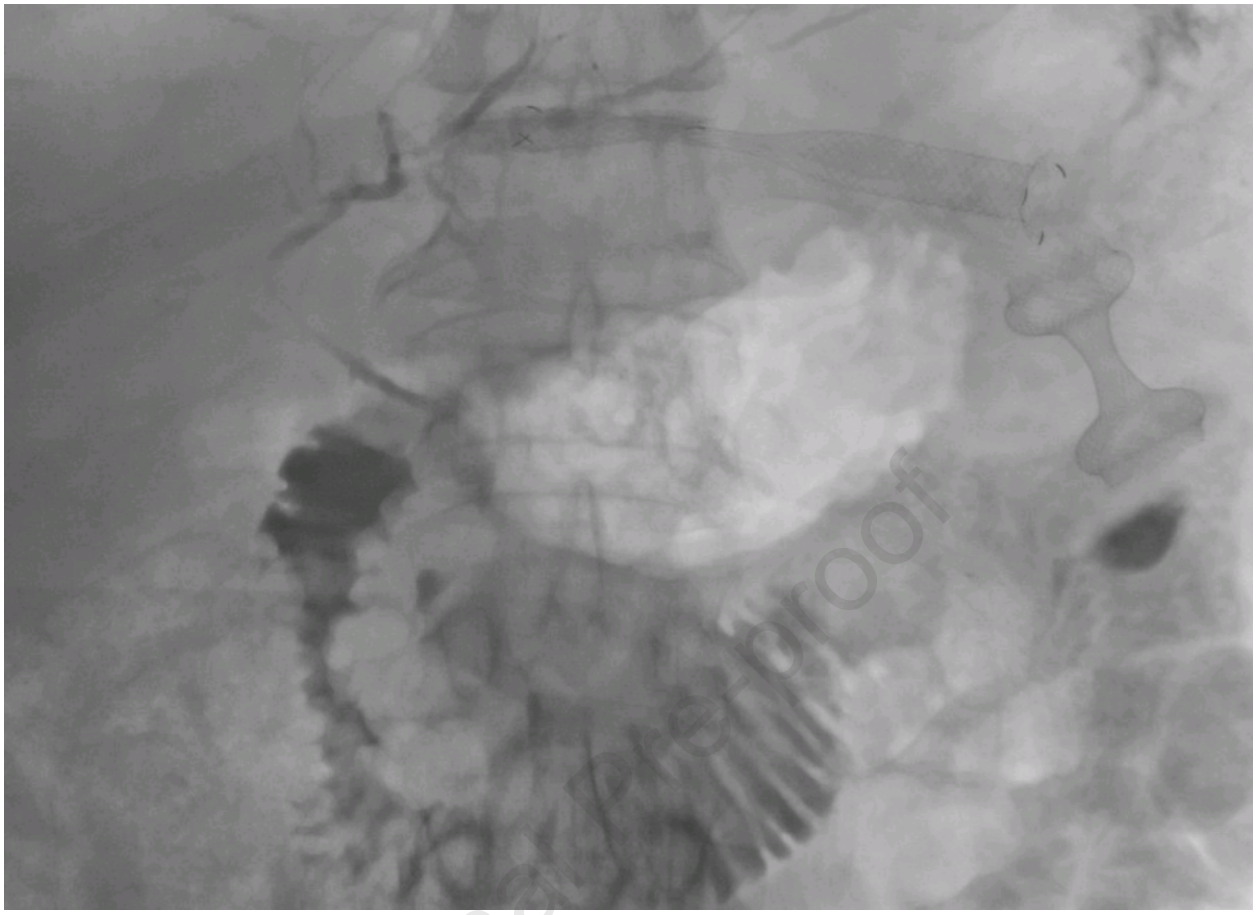

Journal Pre-proof

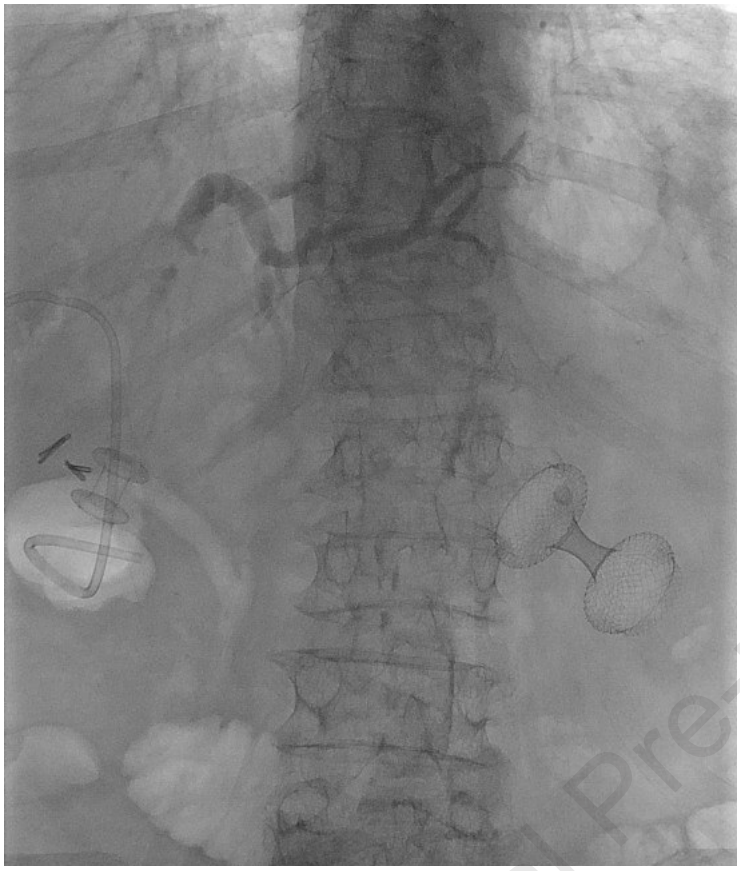

Journal Pre-proof

Journal Pre-proof

Supplementary Table 1. Inclusion rates per center.

	SGJ	Double EUS-bypass
PGIMER, Chandigarh, India	15	7
San Raffaele Scientific Institute, Milan, Italy	56	4
UMC Amsterdam, Netherlands	1	1
UZ Brussels, Belgium	0	26
UZ Leuven, Belgium	29	15

Abbreviations: SGH; surgical gastroenterostomy and hepaticojejunostomy.

Journal Pre-proof

Supplementary Table 2. Postprocedural survival analysis.

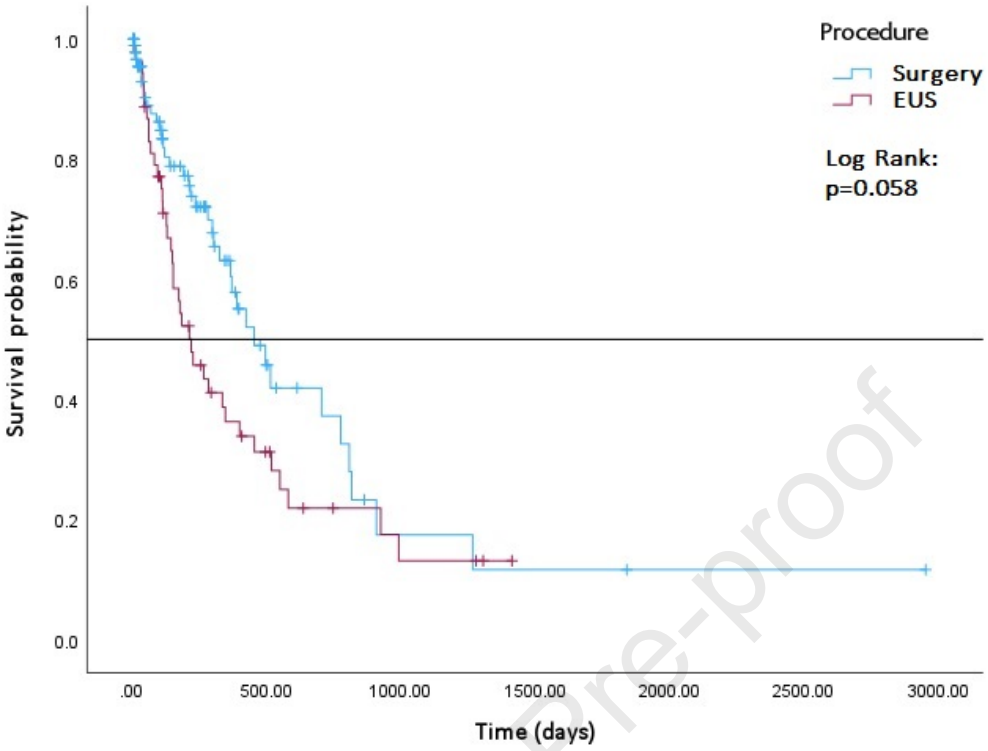

Journal Pre-proof

Journal Pre-proof

Abbreviations

AE: adverse events

ASA: American Society of Anaesthesiologists

CCI: Charlson Comorbidity Index

EUS: endoscopic ultrasound

EUS-AS: EUS-antegrade stenting.

EUS-BD: EUS-guided biliary drainage

EUS-CD: EUS-guided choledocho-duodenostomy

EUS-GE: EUS-guided gastroenterostomy

EUS-HG: EUS-guided hepaticogastrostomy

EUS-RV: EUS-guided rendez-vous

GOO: gastric outlet obstruction

GOOSS: gastric outlet obstruction score system

IQR: interquartile range

LAMS: lumen-apposing metal stent

SD: standard deviation

SEMS: self-expandable metal stent

SGJ: surgical gastroenterostomy and hepaticojejunostomy

WEST: Wireless EUS-gastroenterostomy Simplified Technique

Journal Pre-proof