



Genotype-phenotype correlation in 21 patients with Wolf-Hirschhorn syndrome using high-resolution array CGH

Nicole Maria C. Maas, Griet Van Buggenhout, Femke Hannes, Bernard Thienpont, Damien Sanlaville, Klaas Kok, Alina Midro, Joris Andrieux, Britt-Marie Anderlid, Jacqueline Schoumans, Roel Hordijk, Koenraad Devriendt, Jean-Pierre Fryns and Joris Vermeesch

J. Med. Genet. published online 14 Sep 2007;
doi:10.1136/jmg.2007.052910

Updated information and services can be found at:
<http://jmg.bmj.com/cgi/content/abstract/jmg.2007.052910v1>

- These include:*
- Rapid responses** You can respond to this article at:
<http://jmg.bmj.com/cgi/eletter-submit/jmg.2007.052910v1>
- Email alerting service** Receive free email alerts when new articles cite this article - sign up in the box at the top right corner of the article
-

Notes

Online First contains unedited articles in manuscript form that have been peer reviewed and accepted for publication but have not yet appeared in the paper journal (edited, typeset versions may be posted when available prior to final publication). Online First articles are citable and establish publication priority; they are indexed by PubMed from initial publication. Citations to Online First articles must include the digital object identifier (DOIs) and date of initial publication.

To order reprints of this article go to:
<http://journals.bmj.com/cgi/reprintform>

To subscribe to *Journal of Medical Genetics* go to:
<http://journals.bmj.com/subscriptions/>

Genotype-phenotype correlation in 21 patients with Wolf-Hirschhorn syndrome using high-resolution array CGH

Nicole M.C. Maas, Griet Van Buggenhout, Femke Hannes, Bernard Thienpont, Damien Sanlaville, Klaas Kok, Alina Midro, Joris Andrieux, Britt-Marie Anderlid, Jacqueline Schoumans, Roel Hordijk, Koenraad Devriendt, Jean-Pierre Fryns, Joris R. Vermeesch

Authors' affiliations

NMC Maas, G Van Buggenhout, F Hannes, B Thienpont, K Devriendt, JP Fryns, JR Vermeesch, Center for Human Genetics, University Hospital, Catholic University of Leuven, Leuven, Belgium

D Sanlaville, Department of Genetics, Hôpital Necker-Enfants Malades, Assistance Publique-Hôpitaux de Paris, Paris, France

K Kok, R Hordijk, Department of Medical Genetics, University Medical Center Groningen, Groningen, the Netherlands

A Midro, Department of Clinical Genetics of the Medical University Białystok, Poland

J Andrieux, St Vincent Hospital, Lille, France

B-M Anderlid, J Schoumans, Department of Molecular Medicine, Karolinska Hospital, Stockholm, Sweden

Correspondence to: J.R. Vermeesch, Center for Human Genetics, Herestraat 49, 3000 Leuven, Belgium, Joris.Vermeesch@uz.kuleuven.ac.be

Word count: Abstract: 159
Text: 2921

ABSTRACT

Introduction: The Wolf-Hirschhorn syndrome (WHS) is usually caused by terminal deletions of the short arm of chromosome 4 and is phenotypically defined by growth and mental retardation, seizures, and specific craniofacial manifestations. Large variation is observed in phenotypic expression of these features. In order to compare the phenotype with the genotype, we localized the breakpoints of the 4pter aberrations using a chromosome 4 specific tiling BAC/PAC array.

Methods: In total, DNA from 21 patients was analyzed, of which 8 had a cytogenetic visible and 13 a submicroscopic deletion.

Result and conclusion: In addition to classical terminal deletions sized between 1.9 and 30 Mb, we observed the smallest terminal deletion (1.4 Mb) ever reported in a patient with mild WHS stigmata. In addition, we identified and mapped interstitial deletions in four patients. This study positions the genes causing microcephaly, intrauterine and postnatal growth retardation between 0.3 and 1.4 Mb and further refines the regions causing CHD, CL/P, oligodontia, and hypospadias.

Keywords: tiling array CGH, chromosome 4, deletion, WHS, genotype-phenotype.

INTRODUCTION

Wolf-Hirschhorn syndrome (WHS), first described by Wolf *et al.*[1] and Hirschhorn *et al.*[2] is usually caused by a partial deletion of the short arm of chromosome 4. It is a well known syndrome with growth and mental retardation, microcephaly, seizures, 'Greek helmet' facies, and major malformations such as cleft lip and/or palate (CL/P), coloboma of the eye, congenital heart defects (CHD), and hypospadias. Large variation is observed in phenotypic expression. These features and especially the facial appearance change with ageing.[3-7] The Pitt-Roger-Danks syndrome was described as the milder end of the clinical spectrum of the WHS.[8] Although WHS affects around 1 per 50,000 births, it is suspected that the syndrome is more frequent, because not all patients can be diagnosed with a standard chromosomal investigation.[8] In our experience, the incidence of WHS patients is similar to the incidence of Angelman syndrome patients, hence, about 1 per 20,000 births. In case of a clinical suspicion of WHS in a patient with normal chromosomes, additional fluorescence in situ hybridization (FISH) studies of the subtelomeres and the WHS critical region (WHSCR) are usually performed.

Different genes probably play an important role in the complex phenotype of WHS. One approach to understand the role of different genes is to compare the phenotypes of patients with differently sized deletions and correlating the genotype with the phenotype.[5;9-14] Earlier genotype-phenotype correlation studies identified a WHSCR of approximately 165 kb. This WHSCR covers the entire WHS candidate gene 2 (*WHSC2*), and part of the WHS candidate gene 1 (*WHSC1*).[15;16] In a recent study, this 165 kb WHSCR was not deleted in one patient with a typical WHS face which prompted the investigators to assign a new critical region of WHS, 'WHSCR2'. This region includes the *LETM1* and partially the *WHSC1*, but not the *WHSC2* gene.[11] We reported on five mild WHS patients with small deletions of chromosome 4p covering or flanking the WHSCR which also pinpointed the *WHSC1* as the main candidate for causing the facial WHS appearance.[12]

Genotype-phenotype correlation studies suggest that hemizyosity of genes other than *WHSC1* in the region contribute to some of the phenotypic aspects. An overview of the genes in the region and their potential contribution to the WHS phenotype was described before.[14] CL/P, CHD, renal abnormalities and severe mental retardation are rare in patients with a small terminal microdeletion, but are common in patients with a larger deletion extending to proximal of 4.4 Mb.[10] However, which of these genes is responsible for which phenotype remains unknown, with the exception of *LETM1* which is the most likely candidate gene for epilepsy in WHS patients.[17]

In order to advance phenotype-genotype correlation efforts, we present genotype-phenotype correlations of 8 previously reported and 13 new patients with WHS phenotypic features and characterized the location and size of the deletions by full tiling chromosome 4 BAC array CGH for all 21 patients. Previous genotype-phenotype correlations of this region have been hampered by the presence of other imbalances in part of the WHS patients which likely confused some of the correlations. In this study, only patients with pure 4p deletion were included, which enables us to further refine the 4p phenotypic map.

MATERIALS AND METHODS

Patients

All 21 patients were diagnosed and clinically examined by clinical geneticists of Brussels and Leuven (Belgium), Groningen (The Netherlands), Stockholm (Sweden), and Paris and Lille (France). A personal and family history was obtained from each patient. Most patients were regularly reevaluated during several years and follow up data could be recorded. The summary of the clinical features for each patient is provided in tables 1 and 2. Patient 5, 6, 8-11, 20 and 21 have been described elsewhere.[12;18-22]

Cytogenetic analysis

Karyotyping was performed on metaphase spreads prepared from peripheral blood lymphocytes by routine standard cytogenetic procedures.[23]

Fluorescence in situ hybridization (FISH)

The deletion for all but two patients was confirmed using the commercial LSI WHS region/CEP 4 control (dual color) (Abbott Inc., Downers Grove, IL, USA). The WHSCR probe covering the entire 165 kb WHSCR between loci D4S166 and D4S3327 (Cytocell technologies Ltd., Oxford, UK), was used to analyze the metaphase spreads of patient 2. The metaphase spreads of patient 1 have been tested with probe D4S96 (Oncor, Parsippany, NJ USA) located at ~1.2 Mb from the telomere. Locus specific BAC or PACs were Spectrum Orange labeled as described before.[23]

Array CGH

Genome wide array CGH at 1 Mb resolution was performed as described before.[23] A chromosome 4 tiling BAC array containing 1903 targets was generated as described elsewhere. The DNA from these BAC and PAC targets was obtained from CHORI (Maas et al., submitted).

Cy5 labeled patient DNA was co-hybridized versus Cy3 labeled reference DNA of a healthy individual. The fluorescence intensities measured were first background subtracted. Normalization was performed by dividing each \log_2 transformed intensity ratio by the mean of the \log_2 transformed intensity ratios of all targets derived from the long arm of chromosome 4. In about 1/3 of the hybridizations, an additional 2D normalization was performed using Bioconductor.

(<http://www.bioconductor.org>)[24;25] If successive clones have intensity values below 4x SD of all intensity ratios, the region is considered deleted. Hybridization efficiencies of the chromosome 4 tiling array were around 97%. The average standard deviation of the \log_2 intensity ratio per experiment was 0.08.

RESULTS

Genotype-phenotype correlation

In this study, we aim to correlate the WHS phenotypes with 4p deletion sizes and therefore excluded patients carrying unbalanced translocations or other chromosomal rearrangements which may influence the phenotypic features.[13] About one out of five WHS patients were carrier of a cryptic translocation. The presence of unbalanced translocations was excluded by subtelomeric FISH for patients 5, 6, 10, 11, and 21,[12;20] and both subtelomeric and interstitial chromosomal rearrangements were excluded by 1 Mb array CGH in the other patients. Thus, only those patients with pure 4p deletions were retained in this study. Subsequently, DNA from patients was hybridized on a chromosome 4 tiling array.

Of eight patients with cytogenetically visible terminal 4p deletions, six carried a terminal 4p deletion. Patient 17 carried an interstitial deletion 1 Mb upstream of the WHSCR1 from 2.7 to 14.8 Mb, and patient 15 had an interstitial deletion spanning between 1.8 and 10.1 Mb from the telomere. An overview of the genotypes and phenotypes of the eight patients is shown in table 1 and figure 3A. Hypertelorism, prominent glabella, high forehead, short philtrum, typical down turned or carp shaped mouth, and microcephaly were present in all patients. The typical facial features, intra-uterine growth retardation (IUGR) and seizures were present in all patients except for patient 17 (2.7 to 14.8 Mb interstitial deletion). In two of these eight patients a CL/P was observed (patient 20 and 21), with terminal deletions of respectively 19.5 Mb and 37 Mb. Strabismus was present in five of the seven investigated patients (not in patient 15 (1.8 to 10.1 Mb deletion) and 20 (0 to 19.5 Mb deletion)). Colobomata of the iris were observed in three patients with deletions of at least 10.9 Mb from the telomere. Two patients (patients 18 and 21 with respectively a 14.8 and 37 Mb terminal deletion) were found to have narrow lacrimal ducts. A pre-auricular tag or pit was observed in patients with deletions of 14.8 Mb and larger. All patients had mental, postnatal growth, and psychomotor retardation. Of six patients for which renal ultrasound was performed, a renal defect was only found in one patient (patient 14 with a 8.8 Mb deletion). Fifteen of the seventeen investigated patients had sacral dimples. All three boys with a large deletion presented with genital defects. Patients 16 and 18 had hypospadias (10.9 and 14.8 Mb terminal deletions), and patient 17 had a normal migrated left testis and a non-descended right testis (2.7 to 14.8 Mb interstitial deletion). Hypotonia was present in six of eight individuals except patient 15 and 20 (1.8-10.1 and 0-19.5 Mb deletion).

In 13 patients, a submicroscopic deletion was initially detected by FISH. In 11 of them, the deletion was observed by FISH using the locus specific probe detecting the *WHSC1* deletion. However, in patient 1, the deletion was detected using the Oncor WHS probe located distally from WHSCR1. Subsequently, array CGH was performed to determine the deletion boundaries. This patient had a 1.4 Mb terminal deletion not including the WHSCR1, confirmed by FISH with the flanking clones RP11-1244E8 (1.35 to 1.42 Mb, deleted) and RP11-1398P2 (1.46 to 1.61 Mb, normal) and the deleted telomeric clone CTC-36P21. In patient 2, FISH using the Cytocell WHS probe presented a weak signal in one chromosome 4 and a strong signal in the other chromosome 4 in all metaphases, suggesting a partial deletion. Array CGH pinpointed the breakpoint between RP11-21114 (1.91 to 2.10 Mb, deleted) and RP11-318G6 (2.00 to 2.19 Mb, normal) (Ensembl release 42, Dec 2006). In two patients (patient 6 and 10), small interstitial deletions were observed. An overview of the genotype-phenotype correlation of these 13 patients is shown in table 2 and figure 3B. Patients with deletions of the WHSCR1 all present with the characteristic facial features, except for patient 3. Patient 1 with the 1.4 Mb terminal deletion not involving the WHSCR1 had mild clinical stigmata and no typical WHS face. Patient 10 with the 1.8 to 3.6 Mb interstitial deletion presented with the typical WHS face, but lacked most other WHS stigmata.

DISCUSSION

Genotype-phenotype correlation studies may enable the identification of the role of the different 4p genes in the etiology of WHS. However, several issues remain to be resolved. The number of patients analyzed is still limited and the resolution at which the location of the breakpoints has thus far been analyzed is low. Second, most genotype-phenotype correlation studies are derived from patients with large cytogenetically visible deletions spanning several Mb. Third, since several of the clinical features of this syndrome have considerable variable expressivity or penetrance, the phenotypic characterization of many more WHS patients will be required to pinpoint the genes involved in these more rare aspects of the WHS phenotype. Fourth, the role of position effects due to the relocation of the telomeres is unknown. Finally, since WHS is a contiguous gene syndrome, some of the features seen in WHS could be a result from haploinsufficiency of more than one gene in the region. Unraveling the contribution of each of the genes in the region to these multigenic phenotypes provides a new challenge for geneticists.

This report presents the largest genotype-phenotype correlation analysis of WHS patients thus far. Using a chromosome 4 tiling path array, both interstitial and terminal 4p deletion breakpoints were fine mapped. In addition to the classical terminal deletions, sized between 1.9 and 30 Mb, we identified a 1.4 Mb terminal deletion, the smallest deletion ever to be reported in a patient with WHS phenotypic features. In addition, we identified and mapped four interstitial deletions. Both the patients lacking all classic WHS features and the atypical deletions advanced the dissection of the molecular features leading to the different WHS characteristics.

The main characteristic of WHS is the typical face, usually referred to as a 'Greek warrior helmet face'. Previous studies hypothesized hemizygoty of the *WHSC1* as the most likely cause of the facial phenotype.[10;12;26] This notion was confirmed by the present study. All, except in one patient with a *WHSC1* deletion, did have the typical facial features. The patient with the *WHSC1* deletion but without the typical face is 23 years old. Because of advancing age the facial features could have coarsened over time (patient 3, Figure 1C,D).[7;27] One other patient (patient 7) has partial facial phenotypic features but was not considered to have the "Greek warrior helmet". The two patients in this study without the facial WHS features do not have a deletion of *WHSC1*: one patient had only a 1.4 Mb terminal deletion not covering the *WHSC1* (patient 1, Figure 1A,B), while another patient had a large interstitial deletion upstream of the *WHSC1* (patient 17, Figure 1E,F).

The molecular features of *WHSC1* suggest that the gene might function as a chromatin-remodeling enzyme because SET domains have been shown to function as histone methylases.[28] A deficiency in chromatin remodeling could deregulate the expression of a variety of genes and hence, lead to pleiotropic effects. Recent studies indicated that haploinsufficiency of other chromatin remodeling enzymes cause syndromic phenotypes such as the Chromodomain helicase DNA-binding protein 7 (*CHD7*) gene, causing the CHARGE (Coloboma, Heart anomaly, Choanal atresia, Retardation, Genital and Ear Anomalies) syndrome,[29] the Nipped-B-like (*NIPBL*) gene causing the Cornelia de Lange syndrome[30] and heterozygous mutations in the V-ha-ras Harvey rat sarcoma viral oncogene homolog (*HRAS*) gene causing the Costello syndrome.[31] Because of this possibility, we sequenced the *WHSC1* gene in five WHS patients without 4p deletions (data not shown). Intriguingly, no mutations were detected in this nor in previous studies.[28] Either mutations elsewhere in the genome can cause phenocopies of the WHS or *WHSC1* is the wrong target gene and another gene in the region is key for the phenotype.

Patient 17, a boy with a large interstitial deletion ranging from 2.7 to 14.8 Mb has normal growth parameters, he had no seizures, and mental delay was mild with an IQ of 74. Sitting and walking without support and speech were only mildly delayed compared to the other patients with large deletions. In contrast, all patients with large 4pter deletions, including our 6 patients with large terminal deletions sized between 8.8 and 37 Mb present with pre- and postnatal growth retardation, the typical face, seizures, microcephaly, severe to profound mental and psychomotor retardation and muscular hypotonia (the latter except patient 20). Hence, haploinsufficiency of genes in the 2.7 Mb 4pter region causes these WHS main features.

Not only patient 17 (2.7-14.8 Mb deletion), but also patient 10 with an interstitial deletion (1.8-3.6 Mb deletion) has normal growth parameters. A patient with a normal height and a 191 kb deletion encompassing the *WHSC1* and *WHSC2* genes was described.[16] In contrast, the patient with a 1.4 Mb terminal deletion did present with short stature and IUGR. Therefore, this study locates a short stature candidate region in the terminal 1.4 Mb.

In our previous study, a healthy female with multiple miscarriages carried a 0.3 Mb terminal deletion.[12] Therefore, the 0.3 Mb terminal region is not a candidate region for the genotypic map. Previously, we speculated that the WHS associated microcephaly might be the result of a contiguous

deletion involving at least two genes, one located in a 1.8 Mb terminal region and one between 2.2-2.5 Mb. This hypothesis resulted from patients carrying a 1.9 and 2.2 terminal deletion without microcephaly. This latter observation may also result from incomplete penetrance or genetic modifiers. The microcephaly in the patient with a 1.4 Mb terminal deletion as well as in the other three investigated patients with deletion sizes up to 2.3 Mb is however more consistent with a gene localized in this terminal 1.4 Mb region.

Hemizyosity of *LETM1*, an ubiquitous Ca^{2+} binding protein involved in Ca^{2+} homeostasis, located at 1.8 Mb from the 4p telomere has been suggested to cause seizures.[11;32] However, the patient with an interstitial deletion encompassing *LETM1* (patient 6) did not present with seizures while the patient with the 1.4 Mb terminal deletion did present with seizures. Therefore, another gene in this terminal region may cause the epilepsy.

Besides these main characteristics features, WHS is characterized by several minor features. *Oligodontia* occurred in 6 out of 9 investigated WHS patients in the present study. Nieminen *et al.* showed that a deletion of the msh homeobox 1 gene (*MSX1*), located at 4.9 Mb, might underlie this defect [33]. In contrast to this hypothesis, three patients in this study with deletions in the terminal 2.7 Mb or smaller had oligodontia. Since the carrier of a deletion from 1.1 to 2.5 Mb has oligodontia, the candidate gene has to be sought in this interval. *Cleft lip and palate (CL/P)* has been observed in 9/29 patients described in the literature,[9;10] and a candidate region for CL/P was mapped between 150 kb (D4F26) and 2.3 Mb (D4S43).[34] We observed CL/P in a patient with a terminal microdeletion of 3.7 Mb, and in 2/8 patients with large deletions. We defined the critical region from 0.3 Mb to 3.7 Mb, but after interpretation of the results of Estabrooks *et al.*,[34] this CL/P interval may be refined between 0.3 and 2.3 Mb. *Hypospadias* was detected in all boys but patient 1 (1.4 Mb deletion). Estabrooks *et al.* mapped the critical region for hypospadias between D4S127 (3.0 Mb) and D4S10 (4.0 Mb).[34] Hence our results are concordant with these previous findings. Estabrooks *et al.* mapped the critical region for *congenital heart defect (CHD)* between locus D4S43 and D4S241 proximal from 2.3 Mb.[34] Zollino *et al.*[10] and Wieczorek *et al.*[9] found CHD in only 13/19 patients with large deletions. In the present study, 4 out of 8 patients from both large and small deletions presented with a CHD when having a deletion of 3.7 to 14.8 Mb. We refined the region for heart defect proximal from 3.7 Mb.

In conclusion, the WHS is a syndrome with a spectrum of phenotypic features, from very subtle and mild to a wide range of severe aberrations. The gene(s) causing the IUGR, postnatal growth retardation and microcephaly are localized in the 0.3 to 1.4 Mb 4pter region. It is conceivable that a single gene might cause all these features. Finally, this study refines the candidate regions for CHD, CL/P, oligodontia, and hypospadias. The phenotypic characterization of more WHS patients will be required to delineate regions involved in these more rare aspects of the WHS phenotype.

ACKNOWLEDGEMENTS

We wish to thank the Micro Array Facility, Flanders Interuniversity Institute for Biotechnology (VIB) for their help in the spotting of the arrays and Children's Hospital Oakland Research Institute (CHORI) for the initial clone supply and verification. This work was made possible by grants OT/O2/40, GOA/2006/12 and Centre of Excellence SymbioSys (Research Council K.U.Leuven EF/05/007), Catholic University of Leuven. We wish to thank Mrs. R. Thoelen for her technical support in FISH analyses and Drs. E. Chabchoub for his help in screening patients with the 1 Mb array.

The Corresponding Author has the right to grant on behalf of all authors and does grant on behalf of all authors, an exclusive licence on a worldwide basis to the BMJ Publishing Group Ltd to permit this article (if accepted) to be published in Journal of Medical Genetics and any other BMJPG products and sublicences such use and exploit all subsidiary rights, as set out in our licence.(<http://JMG.bmjournals.com/misc/fora/licenceform.shtml>).

We have written consent from all patients' legal guardians for publication of the images in print and online.

REFERENCES

- 1 Wolf H, Porsch R, Schroeter R, Baitsch H. Defizienz an den kurzen Arm eines Chromosoms nr. 4. *Humangenetik* 1965;**1**:397-413.
- 2 Hirschhorn K, Cooper HL, Firschein IL. Deletion of short arms of chromosome 4-5 in a child with defects of midline fusion. *Humangenetik* 1965;**1**:479-82.
- 3 Battaglia A, Carey JC, Cederholm P, Viskochil D, Brothman A. Natural history experience with 11 cases of Wolf - Hirschhorn syndrome. *Am J Hum Genet* 1996;**95**:A36.
- 4 Battaglia A, Carey JC. Wolf-Hirschhorn syndrome and Pitt-Rogers-Danks syndrome. *Am J Med Genet* 1998;**75**:541.
- 5 Battaglia A, Carey JC, Cederholm P, Viskochil DH, Brothman AR, Galasso C. Natural history of Wolf-Hirschhorn syndrome: experience with 15 cases. *Pediatrics* 1999;**103**:830-6.
- 6 Battaglia A, Carey JC, Viskochil DH, Cederholm P, Opitz JM. Wolf-Hirschhorn syndrome (WHS): a history in pictures. *Clin Dysmorphol* 2000;**9**:25-30.
- 7 Battaglia A, Carey JC, Wright TJ. Wolf-Hirschhorn (4p-) syndrome. *Adv Pediatr* 2001;**48**:75-113.
- 8 Wright TJ, Clemens M, Quarrell O, Altherr MR. Wolf-Hirschhorn and Pitt-Rogers-Danks syndromes caused by overlapping 4p deletions. *Am J Med Genet* 1998;**75**:345-50.
- 9 Wieczorek D, Krause M, Majewski F, Albrecht B, Horn D, Riess O, Gillessen-Kaesbach G. Effect of the size of the deletion and clinical manifestation in Wolf-Hirschhorn syndrome: analysis of 13 patients with a de novo deletion. *Eur J Hum Genet* 2000;**8**:519-26.
- 10 Zollino M, Di Stefano C, Zampino G, Mastroiacovo P, Wright TJ, Sorge G, Selicorni A, Tenconi R, Zappala A, Battaglia A, Di Rocco M, Palka G, Pallotta R, Altherr MR, Neri G. Genotype-phenotype correlations and clinical diagnostic criteria in Wolf-Hirschhorn syndrome. *Am J Med Genet* 2000;**94**:254-61.
- 11 Zollino M, Lecce R, Fischetto R, Murdolo M, Faravelli F, Selicorni A, Butte C, Memo L, Capovilla G, Neri G. Mapping the Wolf-Hirschhorn syndrome phenotype outside the currently accepted WHS critical region and defining a new critical region, WHSCR-2. *Am J Hum Genet* 2003;**72**:590-7.
- 12 Van Buggenhout G, Melotte C, Dutta B, Froyen G, Van Hummelen P, Marynen P, Matthijs G, de Ravel T, Devriendt K, Fryns JP, Vermeesch JR. Mild Wolf-Hirschhorn syndrome: micro-array CGH analysis of atypical 4p16.3 deletions enables refinement of the genotype-phenotype map. *J Med Genet* 2004;**41**:691-8.
- 13 Zollino M, Lecce R, Selicorni A, Murdolo M, Mancuso I, Marangi G, Zampino G, Garavelli L, Ferrarini A, Rocchi M, Opitz JM, Neri G. A double cryptic chromosome imbalance is an important factor to explain phenotypic variability in Wolf-Hirschhorn syndrome. *Eur J Hum Genet* 2004;**12**:797-804.
- 14 Bergemann AD, Cole F, Hirschhorn K. The etiology of Wolf-Hirschhorn syndrome. *Trends Genet* 2005;**21**:188-95.
- 15 Wright TJ, Ricke DO, Denison K, Abmayr S, Cotter PD, Hirschhorn K, Keinanen M, McDonald-McGinn D, Somer M, Spinner N, Yang-Feng T, Zackai E, Altherr MR. A transcript map of the newly defined 165 kb Wolf-Hirschhorn syndrome critical region. *Hum Mol Genet* 1997;**6**:317-24.
- 16 Rauch A, Schellmoser S, Kraus C, Dorr HG, Trautmann U, Altherr MR, Pfeiffer RA, Reis A. First known microdeletion within the Wolf-Hirschhorn syndrome critical region refines genotype-phenotype correlation. *Am J Med Genet* 2001;**99**:338-42.
- 17 Schlickum S, Moghekar A, Simpson JC, Steglich C, O'Brien RJ, Winterpacht A, Endeley SU. LETM1, a gene deleted in Wolf-Hirschhorn syndrome, encodes an evolutionarily conserved mitochondrial protein. *Genomics* 2004;**83**:254-61.
- 18 Fryns JP, de Muelenaere A, Van den Berghe H. The 4p-syndrome in a 24-year-old female. *Ann Genet* 1981;**24**:110-1.
- 19 Fryns JP, Smeets E, Devriendt K, Petit P. Wolf-Hirschhorn syndrome with cryptic 4p16.3 deletion and balanced/unbalanced mosaicism in the mother. *Ann Genet* 1998;**41**:73-6.
- 20 Vermeesch JR, Falzetti D, Van Buggenhout G, Fryns JP, Marynen P. Chromosome healing of constitutional chromosome deletions studied by microdissection. *Cytogenet Cell Genet* 1998;**81**:68-72.
- 21 Manouvrier S, Boute O, Viot G, Delobel B. Deletion of chromosome 4p detected by FISH in a girl with normal high resolution karyotype. *Clin Genet* 1999;**55**:127-9.
- 22 Anderlid BM, Schoumans J, Anneren G, Sahlen S, Kyllerman M, Vujic M, Hagberg B, Blennow E, Nordenskjold M. Subtelomeric rearrangements detected in patients with idiopathic mental retardation. *Am J Med Genet* 2002;**107**:275-84.
- 23 Menten B, Maas N, Thienpont B, Buysse K, Vandesoempele J, Melotte C, de Ravel T, Van Vooren S, Balikova I, Backx L, Janssens S, De Paepe A, De Moor B, Moreau Y, Marynen P, Fryns JP, Mortier G, Devriendt K, Speleman F, Vermeesch JR. Emerging patterns of cryptic chromosomal imbalance in

- patients with idiopathic mental retardation and multiple congenital anomalies: a new series of 140 patients and review of published reports. *J Med Genet* 2006;**43**:625-33.
- 24 Gentleman RC, Carey VJ, Bates DM, Bolstad B, Dettling M, Dudoit S, Ellis B, Gautier L, Ge Y, Gentry J, Hornik K, Hothorn T, Huber W, Iacus S, Irizarry R, Leisch F, Li C, Maechler M, Rossini AJ, Sawitzki G, Smith C, Smyth G, Tierney L, Yang JY, Zhang J. Bioconductor: open software development for computational biology and bioinformatics. *Genome Biol* 2004;**5**:R80.
- 25 Venkatraman ES, Olshen AB. A faster circular binary segmentation algorithm for the analysis of array CGH data. *Bioinformatics* 2007.
- 26 Wright TJ, Costa JL, Naranjo C, Francis-West P, Altherr MR. Comparative analysis of a novel gene from the Wolf-Hirschhorn/Pitt-Rogers-Danks syndrome critical region. *Genomics* 1999;**59**:203-12.
- 27 Marcelis C, Schrandt-Stumpel C, Engelen J, Schoonbrood-Lenssen A, Willemse A, Beemer F, Sigaudy S, Missirian C, Philip N, Fryns JP. Wolf-Hirschhorn (4P-) syndrome in adults. *Genet Couns* 2001;**12**:35-48.
- 28 Stec I, Wright TJ, van Ommen GJ, de Boer PA, van Haeringen A, Moorman AF, Altherr MR, den Dunnen JT. WHSC1, a 90 kb SET domain-containing gene, expressed in early development and homologous to a Drosophila dysmorphia gene maps in the Wolf-Hirschhorn syndrome critical region and is fused to IgH in t(4;14) multiple myeloma. *Hum Mol Genet* 1998;**7**:1071-82.
- 29 Jongmans MC, Admiraal RJ, van der Donk KP, Vissers LE, Baas AF, Kapusta L, van Hagen JM, Donnai D, de Ravel TJ, Veltman JA, Geurts van Kessel A, De Vries BB, Brunner HG, Hoefsloot LH, van Ravenswaaij CM. CHARGE syndrome: the phenotypic spectrum of mutations in the CHD7 gene. *J Med Genet* 2006;**43**:306-14.
- 30 Tonkin ET, Wang TJ, Lisgo S, Bamshad MJ, Strachan T. NIPBL, encoding a homolog of fungal Scc2-type sister chromatid cohesion proteins and fly Nipped-B, is mutated in Cornelia de Lange syndrome. *Nat Genet* 2004;**36**:636-41.
- 31 Aoki Y, Niihori T, Kawame H, Kurosawa K, Ohashi H, Tanaka Y, Filocamo M, Kato K, Suzuki Y, Kure S, Matsubara Y. Germline mutations in HRAS proto-oncogene cause Costello syndrome. *Nat Genet* 2005;**37**:1038-40.
- 32 Endele S, Fuhry M, Pak SJ, Zabel BU, Winterpacht A. LETM1, a novel gene encoding a putative EF-hand Ca(2+)-binding protein, flanks the Wolf-Hirschhorn syndrome (WHS) critical region and is deleted in most WHS patients. *Genomics* 1999;**60**:218-25.
- 33 Nieminen P, Kotilainen J, Aalto Y, Knuutila S, Pirinen S, Thesleff I. MSX1 gene is deleted in Wolf-Hirschhorn syndrome patients with oligodontia. *J Dent Res* 2003;**82**:1013-7.
- 34 Estabrooks LL, Rao KW, Driscoll DA, Crandall BF, Dean JC, Ikonen E, Korf B, Aylsworth AS. Preliminary phenotypic map of chromosome 4p16 based on 4p deletions. *Am J Med Genet* 1995;**57**:581-6.

LEGEND TO THE FIGURES

Figure 1 Facial features of 5 patients with WHS. **A** and **B**: patient 1 from frontal and aside. **C** and **D**: patient 3 from frontal and aside. **E** and **F**: patient 17 from frontal and aside. **G**: patient 15 from frontal.

Figure 2 Results of the array CGH analysis of two patients. The Y axis represents the \log_2 of the intensity ratios of the combined dye swap experiments of patient versus control DNA. In the X axis the spotted clones are ordered from the 4p telomere to the centromere. The distance from the 4p telomere is indicated in Mb. The arrows indicate the location of the breakpoints and the distance from the telomere is indicated. (A) DNA from a patient with a small terminal deletion. (B) DNA from a patient with a cytogenetically visible interstitial deletion.

Figure 3A Results of the detected deletions using the full tiling array CGH of chromosome 4 in 8 WHS patients with microscopically visible deletions. The bars show the sizes of the deletions.

Figure 3B Results of the detected deletions using the full tiling array CGH of chromosome 4 in 13 WHS patients with submicroscopic deletions. The bars show the sizes of the deletions. The thick black bars show the locations of the candidate regions for each phenotypic feature. The red bars show the locations of the critical regions for hypospadias and CL/P defined by Estabrooks *et al.*[34].

We have written consent from all patients' legal guardians for publication of the images in print and online.

Table 1 Clinical findings in 9 WHS patients with *de novo* cytogenetically visible deletions

Case:	14	15	16	17	18	19	20	21	total
Sex (female/male)	f	f	m	m	m	f	f	f	5/3
Facial appearance									
Greek Warrior Helmet facies	+	+	+	-	+	+	+	+	7/8
Hypertelorism	+	+	+	+	+	+	+	+	8/8
Prom glabella	+	+	+	-	+	+	+	+	7/8
High forehead	+	+	+	+	+	+	+	+	8/8
epicanthus	+	+	-	-	+	-	+	+	5/8
Broad nose	-	-	+	+	+	+	+	+	6/8
Beaked nose	-	-	-	-	+	+	+	+	4/8
Short philtrum	+	+	+	+	+	+	+	+	8/8
Oligodontia	n.i.	+	n.i.	-	n.i.	n.i.	too young	too young	1/2
Micrognathia	+	+	+	+	+	+	+	+	8/8
Downturned shape mouth	+	+	+	+	+	+	+	+	8/8
Cleft lip/palate	-/-	-/-	-/-	-/-	-/-	-/-	-/+	-/+	2/8
Colobomata of iris	-	-	+	-	-	-	+	+	3/8
Narrow lacr ducts	n.i.	-	n.i.	-	+	n.i.	n.i.	+	2/4
Strabismus	+	-	+	+	+	+	-	n.i.	5/7
Dysplastic ears	+	-	+	+	+	+	+	+	7/8
Preaur tag/pit	-	-	-	-	+	-	-	+	2/8
Birth									
Gestational weeks at birth (weeks,days)	33	38	38	40,2	38	37	41,5	37,2	Ø 38
Weight (g)	1180 (<P10)	1630 (<P10)	1900 (<P10)	3660 (P75-P90)	1930 (<P10)	1500 (<P10)	2610 (<P10)	1550 (<P10)	Ø 1995
Length in cm	39 (<P10)	42 (<P10)	49 (P50-P75)	52 (P50-P75)	47.5 (P25-P50)	n.i.	48 (P10-P25)	42 (<P10)	Ø 46
IUGR	+	+	+	-	+	+	+	+	7/8
OFC (cm)	27 (<P10)	30.5 (<P10)	30 (<P10)	4 weeks: 36 (P10-P25)	34.5 (P75-P90)	n.i.	n.i.	n.i.	Ø 30.5
microcephaly at birth	+	+	+	-	-	+	n.i.	+	5/7
Postnatal examination									
Age at examination (years,months)	6	12	7	3,6	5	50	1,6	0,2	
height (cm)	89 (<P3)	142 (P10-P25)	<P3	9 (-1SD)	<P3	120 (<P3)	72.5 (<P3)	47.5 (<P3)	
weight (kg)	8.0 (<P3)	30 (P10)	<P3	12.6 (-2SD)	<P3	25 (<P3)	6.9 (<P3)	2.5 (<P3)	
OFC (cm) / microcephaly (+/-)	44.2	48 (<P3)	+	47.5 (-2SD)	43 (<P3)	46 (<P3)	42.2 (<P3)	35 (<P3)	

	(<P3)								
Mental retardation	severe	severe	+	IQ 74	severe	profound	profound	profound	
Sitting without support [y,m]	3,6	1,5	3,6	1,6	-	-	-	-	4/8
Walking without support [y,m]	-	3,5	6	3,6	-	-	-	-	3/8
Speech [y,m]	-	-	7	1,5	-	-	-	-	2/8
hypotonia	+	-	+	+	+	+	-	+	6/8
Seizures	+	+	+	-	+	+	+	+	7/8
Congenital heart defects	+ (ASDII, Pst)	-	-	+ (AVSD)*	+ (ASDII, Pst)	-	-	-	3/8
Clubbing of fingers/toes	-	-	-	-	-	-	-	-	0/8
Scoliosis	-	-	-	-	+	+	-	-	2/8
Club feet	-	-	-	-	-	+	+	-	2/8
Renal anomalies	renal reflux	-	-	-	n.i.	n.i.	-	-	1/6
Genital anomalies	-	n.i	hypospadi s	+*	hypospadi s	-	+	ventrally spaced anus	5/7
Sacral dimple	+	n.i.	n.i.	+	+	+	+	+	6/6
deletion (start-end in Mb)	8.8	1.8-10.1	10.9	2.7-14.8	14.8	16.5	19.5	37	
Diagnosis by	G- banding	1Mb array (Spectral Genomics)	G-banding	G-banding	G-banding	G-banding	G-banding	G-banding	
Subtelomeric screening by	1 Mb array	interstitial deletion	1 Mb array	interstitial deletion	1 Mb array	1 Mb array	FISH subtel	1 Mb array	
Last normal clone (interstitial) (Mb)		RP11-138D6 (1.7-1.9)		RP11-444J4 (2.6-2.7)					
First deleted clone (interstitial) (Mb)		RP11- 1170P16 (1.8-1.9)		RP11-372F2 (2.9-3.1)					
Last deleted clone (Mb)	RP11- 689P11 (8.5-8.7)	RP11- 572M24 (10.1-10.2)	RP11- 518L6 (10.9-11.1)	RP11-804D20 (14.7-14.9)	RP11- 558F7 (14.6-14.8)	RP11- 142E22 (16.5-16.7)	RP11-107E4 (19.4-19.6)	RP11-759E10 (37.3-37.6)	
First normal clone (Mb)	RP11- 637J21 (8.6-8.8)	RP11-61G19 (10.2-10.4)	RP11- 775H15 (11.0-11.2)	RP11-161H8 (14.8-15.0)	RP11- 804D20 (14.7-14.9)	RP11- 714L13 (16.6-16.8)	RP11- 5N10 (19.5-19.7)	RP11-177C12 (37.5-37.7)	
Cytogenetic band	4p16.1	4p16.1p16.3	4p16.1	4p15.33p16.3	4p15.33	4p15.32	4p15.31	4p14	

n.i.: not investigated; n.r.: not reported; f: female; m: male; Ø: average; ASD: atrial septal defect; VSD: ventricular septal defect; Pst: pulmonic stenosis. * see clinical description.

Table 2 Clinical findings in 13 WHS patients with *de novo* microdeletions

Case:	1	2	3	4	5	6	7	8	9	10	11	12	13	
Sex (female/male)	m	m	f	m	f	m	m	f	f	m	f	m	m	5f/8m
Facial appearance														
Greek Warrior Helmet facies	-	+	-	+	+	+	-	+	+	+	+	+	+	10/13
Hypertelorism	-	+	+	n.i.	n.i.	-	+	+	+	+	+	-	+	8/11
Prom glabella	-	+	-	+	n.i.	-	+	+	n.i.	+	+	-	+	7/11
High forehead	-	+	+	n.i.	n.i.	+	+	+	n.i.	+	+	+	+	9/10
epicanthus	n.i.	n.i.	-	-	n.i.	-	-	+	n.i.	-	-	+	-	2/9
Broad nose	-	+	+	n.i.	n.i.	-	+	+	+	+	+	-	-	7/11
Beaked nose	-	+	+	n.i.	n.i.	-	-	-	n.i.	+	+	-	+	5/10
Short philtrum	-	+	+	n.i.	+	-	+	+	n.i.	+	-	+	+	8/11
Oligodontia	n.i.	-	-	n.i.	n.i.	+	+	+	n.i.	n.i.	+	n.i.	+	5/7
Micrognathia	-	+	-	+	+	-	+	-	n.i.	+	-	+	+	7/12
Down mouth	-	+	-	+	n.i.	-	+	+	n.i.	-	+ mild	+	-	6/11
Cleft lip/palate	-/-	-/-	-/-	-/-	n.i.	-/-	-/-	-/-	n.i.	-/-	-/+	-/-	-/-	1/11
Colobomata of iris	-	-	-	-	-	-	-	-	n.i.	-	-	-	-	0/12
Narrow lacr ducts	n.i.	-	-	n.i.	n.i.	-	n.i.	-	n.i.	-	n.i.	n.i.	-	0/6
Strabism	-	+	-	-	-	-	-	+	n.i.	-	-	+	-	3/12
Dysplastic ears	-	+	+	+	+	+	+	+	n.i.	-	+	+	+	10/12
Preaur tag/pit	-	-	-	-	-	-	-	-	n.i.	-	-	-	-	0/12
Birth														
Gestational weeks at birth	40	36	n.i.	39	37	38	32	37	40	42	42	34	40	Ø 38
Weight (g)	2080 (<P3)	1570 (<P3)	2640	2270 (<P3)	2050 (P3-P10)	2330 (P3-P10)	1800 (P50-P75)	2460 (P25)	2010 (<P3)	3250 (P50)	1900 (P3-P10)	2650 (P75-P90)	1900 (<P3)	Ø 2224
Length in cm	47 (P10-P25)	n.i.	n.i.	47.5 (P25)	44 (P10-P25)	44 (<P10)	42 (P50)	46 (P25)	44 (<P10)	50 (P50-P75)	45 (<P10)	49 (P90)	n.i.	Ø 46
IUGR	+	+	+	+	+	+	+	+	+	-	+	-	+	11/13
OFC (cm)	n.i.	n.i.	n.i.	33 (P25-P50)	29 (<P10)	0y1m: 34cm (<P3)	30 (P75-P90)	32 (P25)	31 (<P10)	36,2 (>P90)	30 (<P10)	n.i.	n.i.	Ø 31
Microcephaly at birth	n.i.	n.i.	n.i.	-	+	+	-	-	+	-	+	n.i.	n.i.	4/8
Neonatal feeding difficulties	n.i.	n.i.	n.i.	n.i.	n.i.	n.i.	+	n.i.	n.i.	n.i.	n.i.	n.i.	+	2/2

Postnatal examination														
Age at examination (y,m)	11,8	2,4	23	12	16	13	13	3,6	12	13,6	14	29	5,6	
Length (cm) / short stature (+/-)	+	87 (P10-P25)	n.i.	151 (P50-P75)	+	172 (>P97)	129 (<P3)	+ (-3SD)	128 (<P3)	155 (P25-P50)	149 (<P3)	153 (<P3)	93 (<P3)	
weight (kg) / low weight (+/-)	+	9,2 (<P3)	-	31 (P10-P25)	+	41,3 (P25-P50)	21 (<P3)	-2SD	23 (<P3)	32,1 (P3-P10)	36,7 (<P3)	-	11,5 (<P3)	
OFC (cm) / microcephaly (+/-)	+	46.3 (<P3)	+	n.i.	+	50 (<P3)	48,5 (<P3)	-2SD	49 (<P3)	53.4 (P25)	11y: 47.3 (<P3)	52 (<P3)	44.8 (<P3)	
Mental retardation	moderate	severe	severe	moderate	+	mild / moderate	moderate	severe	severe	mild / moderate	moderate / severe	severe	moderate	
Sitting without support [y,m]	+	-	n.i.	0,1	n.i.	1,2	n.i.	5,0	+	0,9	n.i.	3	+	8/9
Walking without support [y,m]	1,6	-	n.i.	2,1	n.i.	1,6	2,6	-	n.i.	1,3	n.i.	6	1,2	7/9
Speech [y,m]	+	-	-	5,5	n.i.	4	+	-	-	+	4	-	+	7/12
hypotonia	-	-	+	+	+	+	+	+	n.i.	+	n.i.	-	-	7/11
Seizures	+	+	+	+	+	-	+	+	+	-	-	-	-	8/13
Deafness	-	-	-	-	n.i.	-	-	-	+	-	-	-	-	1/12
Congenital heart defects	-	+ small VSD	-	-	-	-	n.i.	-	n.i.	-	+ Pst	-	-	2/11
Clubbing of fingers/toes	-	-	-	-	n.i.	-	-	-	n.i.	n.i.	n.i.	-	-	0/9
Scoliosis/hyperk	-	-	+	n.i.	-	+	+	-	n.i.	+	+	-	-	5/11
Club feet	-	-	+	-	n.i.	-	-	-	n.i.	n.i.	n.i.	-	-	1/9
Renal anomalies	-	Leftsided kidney duplication	-	-	n.i.	n.i.	Vesicourethral reflux	-	n.i.	n.i.	n.i.	n.i.	-	2/7
Genital anomalies	-	hypospadias	-	Hypospadias	n.i.	hypospadias	Hypospadias	-	n.i.	n.i.	clitoromegaly	hypospadias	hypospadias	7/10
Sacral dimple	+	+	+	-	+	+	-	n.i.	n.i.	+	+	+	+	9/11
extra	-	Hip dysplasia, nystagmus	-	Scoliosis	-	-	Kyphosis	-	aphasia hyperactive	Left inguinal hernia	left diaphragmatic hernia	-	-	
Delineation of the deletion														
Deletion (start-end in Mb)	1.4	1.9	2.0	2.2	2.3	1.1-2.5	2.7	2.7	2.7	1.8-3.6	3.7	4.8	5.3	
Diagnosis by means of	FISH Oncor WHS probe	FISH Cytocell WHS probe	FISH Vysis WHS probe	FISH Vysis WHS probe	FISH Vysis WHS probe	FISH Vysis WHS probe	FISH Vysis WHS probe	FISH subtel. Probe Vysis	FISH Vysis WHS probe	FISH Vysis WHS probe	FISH Vysis WHS probe	FISH Vysis WHS probe	FISH Vysis WHS probe	
Subtelomeric	1 Mb array	1 Mb array	1 Mb array	1 Mb array	FISH subtel	FISH subtel	1 Mb array	FISH subtel	1 Mb array	FISH subtel	FISH subtel	1 Mb array	1 Mb array	

screening by														
Last normal clone (interstitial) (Mb)						RP11-20I20 (1.1-1.3)				RP11-1197E19 (1.8-1.9)				
First deleted clone (interstitial) (Mb)						RP11-386I15 (12.-1.4)				RP11-262P20 (1.8-2.1)				
Last deleted clone (Mb)	RP11-386I15 (1.3-1.4)	RP11-21I14 (1.9-2.1)	RP11-318G6 (2.0-2.2)	RP11-440D10 (2.2-2.4)	RP11-478C1 (2.1-2.3)	RP11-478A6 (2.4-2.6)?	RP11-444J4 (2.6-2.7)	RP11-444J4 (2.6-2.7)	RP11-444J4 (2.6-2.7)	RP11-357G3 (3.2-3.4)	RP3-513G18 (3.6-3.7)	RP11-359G4 (4.7-4.9)	CTD-2265H21 (5.3-5.5)	
First normal clone (Mb)	RP11-1398P2 (1.5-1.6)	RP11-318G6 (2.0-2.2)	RP11-478C1 (2.1-2.3)	RP11-678M13 (2.3-2.5)	RP11-503N18 (2.3-2.5)	RP3-474M20 (2.6-2.7)?	RP11-372F2 (2.9-3.1)	RP11-372F2 (2.9-3.1)	RP11-372F2 (2.9-3.1)	RP11-529E10 (3.4-3.6)	RP11-489M13 (4.0-4.2)	RP11-326I19 (4.8-5.0)	RP11-653L17 (5.5-5.7)	
Chr. 4 band	4p16.3	4p16.3	4p16.3	4p16.3	4p16.3	4p16.3p16.3	4p16.3	4p16.3	4p16.3	4p16.3p16.3	4p16.3	4p16.2	4p16.2	

n.i.: not investigated; n.r.: not reported; f: female; m: male; Ø: average; ASD: atrial septal defect; VSD: ventricular septal defect; Pst: pulmonic stenosis.

Figure 1

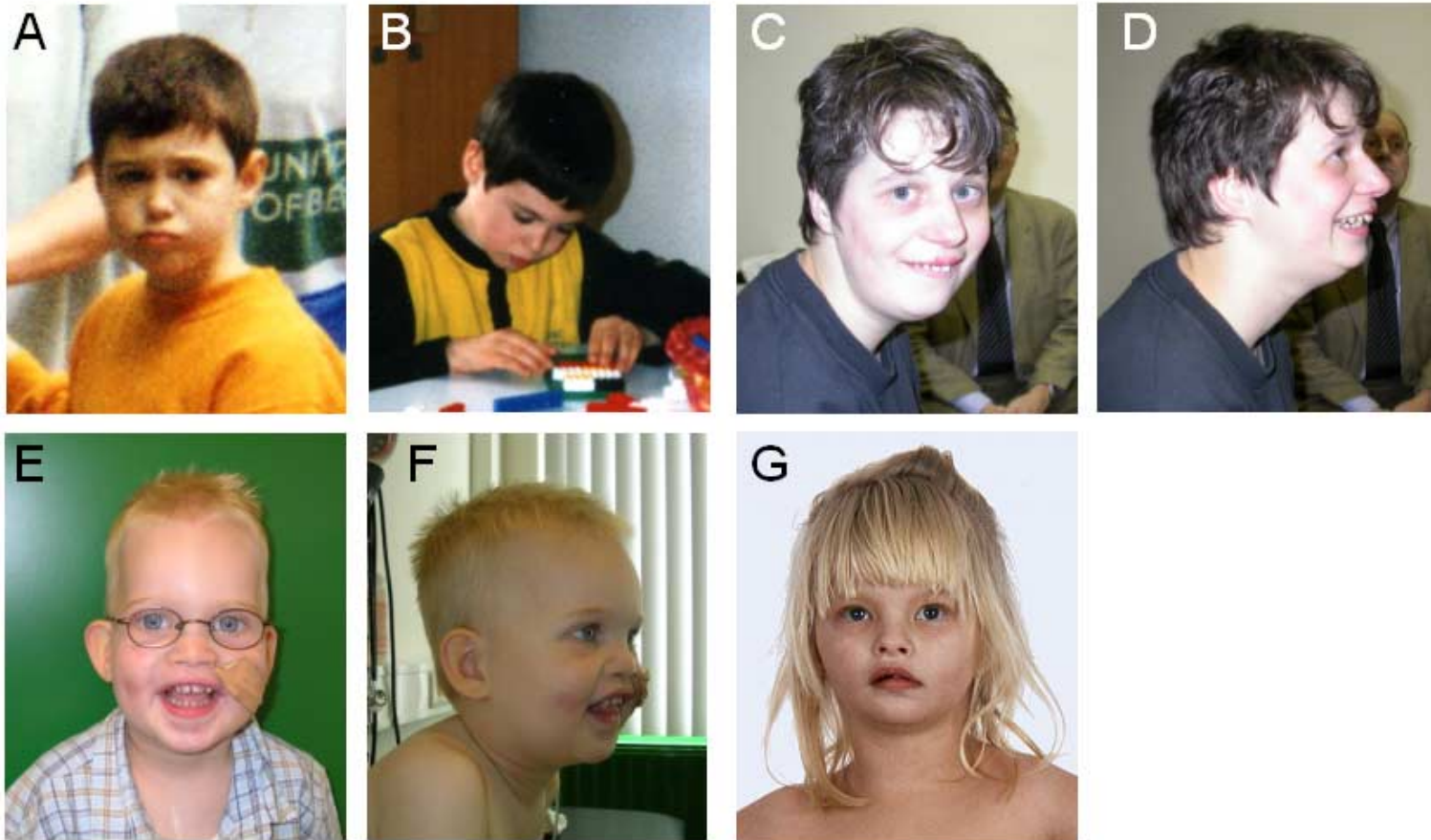


Figure 2

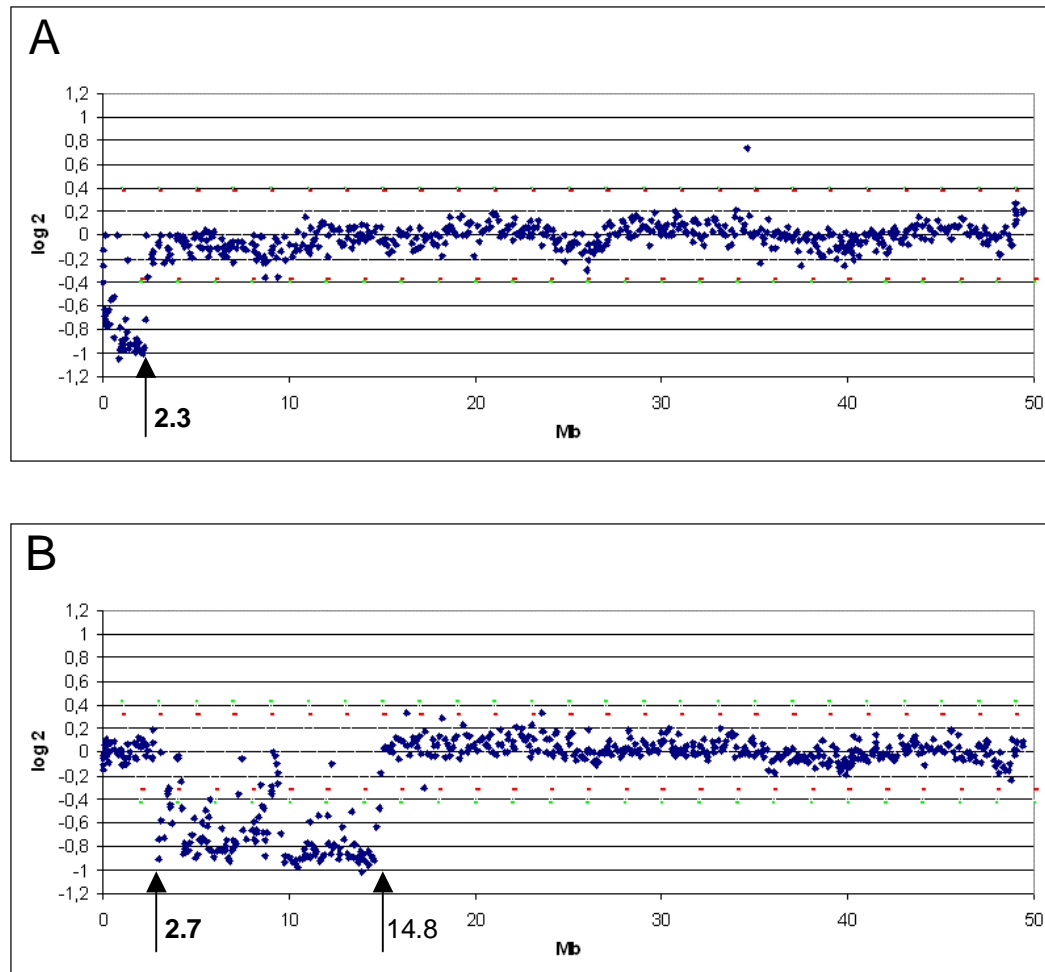


Figure 3A

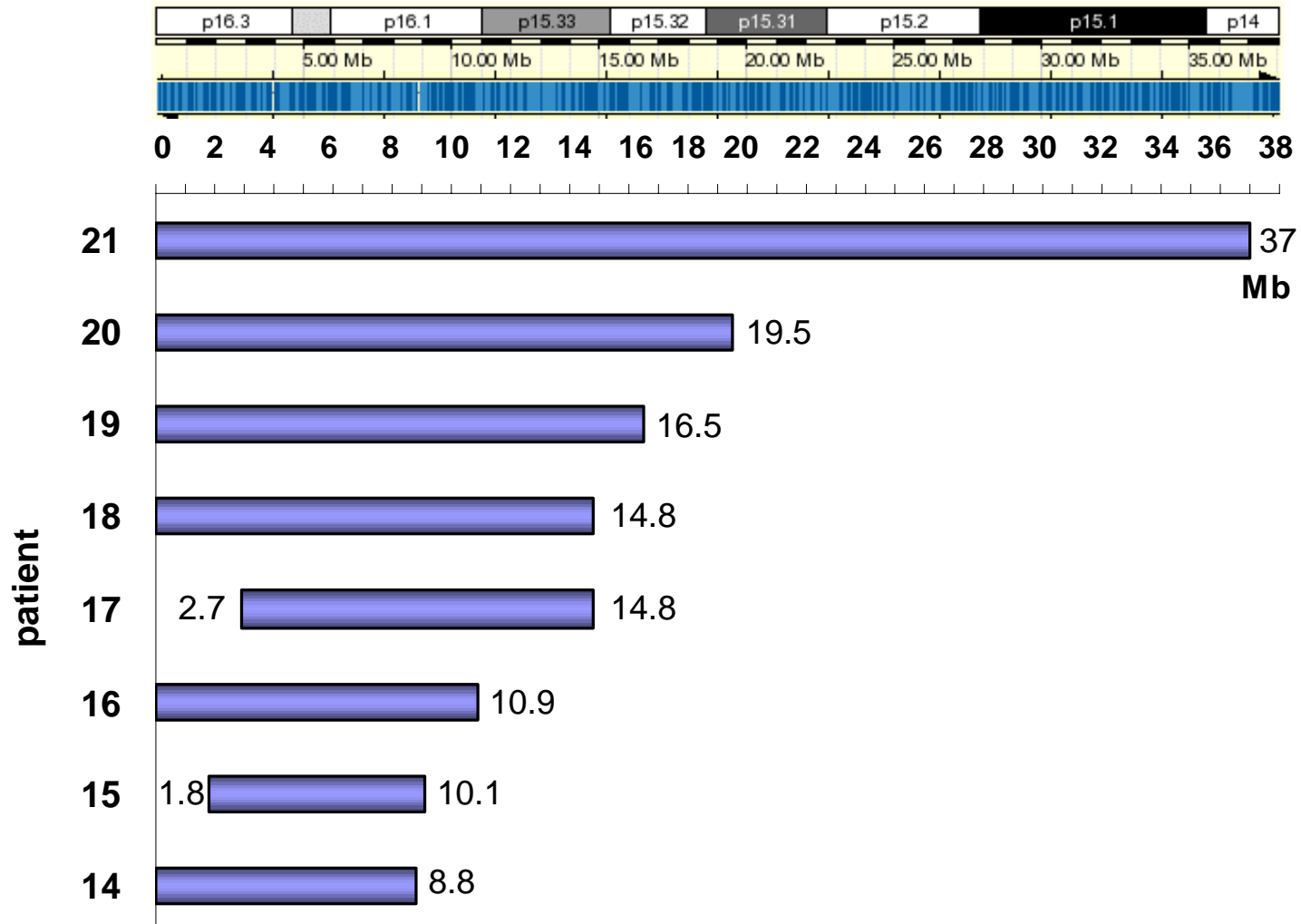


Figure 3B

