

CASE REPORT

Preprocedural imaging for transcatheter mitral valve-in-valve replacement: Planning makes perfect

Alexander Van De Bruaene^{1,2}  | Stijn De Buck¹ | Peter Verbrugge^{1,3} | Christophe Dubois^{1,2}

¹Department of Cardiovascular Sciences, Catholic University of Leuven, Leuven, Belgium

²Department of Cardiovascular Medicine, University Hospital Leuven, Leuven, Belgium

³Department of Cardiac Surgery, University Hospital Leuven, Leuven, Belgium

Correspondence

Alexander Van De Bruaene,
Department of Cardiovascular
Medicine, University Hospitals Leuven,
Leuven, Belgium.
Email: alexander.vandebrauene@
uzleuven.be

Funding information

None

Abstract

Transcatheter mitral valve-in-valve replacement (TMViVR) in degenerated bioprostheses or valvular rings shows promise as an alternative to surgical MVR in selected high-risk patients. However, these procedures are particularly challenging given the complex anatomy of the mitral valve apparatus and the surrounding structures, potentially causing LV outflow tract obstruction (LVOTO). Preprocedural planning with virtual implantation and planimetric estimation of the neo-LVOT at end-systole is crucial for improving procedural results. In this case, we also include a dynamic evaluation of the neo-LVOT and implement virtual reality imaging for immersive assessment of the implanted valve.

KEYWORDS

3D virtual models, preprocedural planning, transcatheter mitral valve replacement, valve-in-valve replacement, virtual reality

1 | INTRODUCTION

Transcatheter mitral valve-in-valve replacement (TMViVR) in degenerated bioprostheses or valvular rings shows promise as an alternative to standard surgical MVR in selected high-risk patients. However, these procedures are particularly challenging given the complex anatomy of the mitral valve apparatus and the surrounding structures, potentially causing LV outflow tract obstruction (LVOTO). Preprocedural planning with virtual implantation and planimetric estimation of the neo-LVOT at end-systole is crucial for improving procedural results. We present a case of a 84-year-old female patient undergoing TMViVR for degeneration of a mitral valve Mosaic bioprosthesis. Preprocedural planimetric assessment of the neo-LVOT using Materialise Mimics Enlight software allowed for accurate post-procedural results. We also incorporated

dynamic assessment of the neo-LVOT during the cardiac cycle and provided immersive visualization using virtual reality imaging.

2 | CASE REPORT

A 84-year-old woman was referred with worsening exercise tolerance and shortness of breath (New York Heart Association [NYHA] class 3–4). In 2011, she underwent surgical mitral and aortic valve replacement (MVR: 29 mm Mosaic [Medtronic]; AVR: 21 mm Mitroflow [Sorin Group Inc.]) for mitral and aortic valve stenosis, followed by dual-chamber pacemaker implantation for postoperative atrioventricular block. In 2017, she underwent transcatheter valve-in-valve aortic valve replacement (TAVR) with an Edwards Sapien XT 20 mm (Edwards Lifesciences)

This is an open access article under the terms of the Creative Commons Attribution-NonCommercial-NoDerivs License, which permits use and distribution in any medium, provided the original work is properly cited, the use is non-commercial and no modifications or adaptations are made.

© 2022 The Authors. *Clinical Case Reports* published by John Wiley & Sons Ltd.

because of degeneration of the Mitroflow bioprosthesis. In 2019, she presented with recurring dyspnea and progressive degeneration of the mitral valve Mosaic bioprosthesis (mean gradient 5 mmHg at a heart rate of 70 bpm, estimated mitral valve area of 1.6 cm² and severe, eccentric, valvular mitral valve regurgitation) (Video S1A).

DICOM data from 4D electrocardiogram-gated computed tomography (CT) were imported in the Materialise Mimics Enlight software (Mitral Planning Wizard, Materialise) for further assessment. First, using the double-oblique technique, aligning cross-hairs with the mitral plane in a sagittal and coronal view, mitral annular dimensions were obtained: perimeter 76 mm, annular area 450 mm²; largest diameter 26 mm, smallest diameter 23 mm. Second, Sapien 3 26 mm and 29 mm valve frames (Edwards Lifesciences) were virtually positioned within the Mosaic 29 mm in different landing zones (20% atrial/80% ventricular up to 50% atrial/50% ventricular). The smallest left ventricular outflow tract (LVOT) area between the anteroseptal wall of the LV and the simulated valve was segmented, showing a neo-LVOT of 117 mm² (worst case: atrial 20%/ventricular 80% for the 29 mm valve) to 275 mm² (best case: atrial 50%/ventricular 50% for the 26 mm valve). Based on preoperative annular sizing and anticipated neo-LVOT, a 26 mm SAPIEN 3 was selected aiming for a position 30% atrial/70% ventricular (neo-LVOT predicted 176 mm²—Figure 1A).

The patient underwent TMViVR using a standard transeptal approach and transesophageal echocardiography (TOE) guidance.¹ The outflow of the Sapien valve was aligned with the sole radiopaque markers on the struts of the Mosaic valve, to obtain a 70% ventricular position

at valve expansion. TOE evaluation immediately post-implantation (Video S1B) showed excellent valve position and function with a mean gradient of 4 mmHg at a heart rate of 80 bpm and absence of mitral regurgitation. A cardiac CT 1 month post-procedure confirmed proper alignment of the Sapien valve with the Mosaic struts, resulting in a neo-LVOT of 171 mm² at end-systole (Figure 1B). Additional measurements at different time points during the cardiac cycle showed a neo-LVOT of 302 mm² at end-diastole and 229 mm² at mid-systole (Figure 1C and Video S2). Using in-house developed software, we were also able to provide an immersive visualization of the neo-LVOT after stent implantation using virtual reality imaging, which can be accessed afterward using a QR code, a smartphone, and a Google Cardboard (Figure S1 and Video S3).

3 | DISCUSSION

Transcatheter mitral valve-in-valve replacement in degenerated bioprostheses or valvular rings shows promise as an alternative to standard surgical MVR in selected high-risk patients. However, these procedures are particularly challenging given the complex anatomy of the mitral valve apparatus and the surrounding structures: transcatheter mitral valve prostheses may protrude in the LV cavity and cause LV outflow tract obstruction (LVOTO).² Therefore, cardiac CT prior to device implantation is performed to accurately size the mitral annulus, calculate working views, assess access points to the heart chambers, and perform TMViVR simulation to assess the risk for LVOTO. During such simulation, a selection of

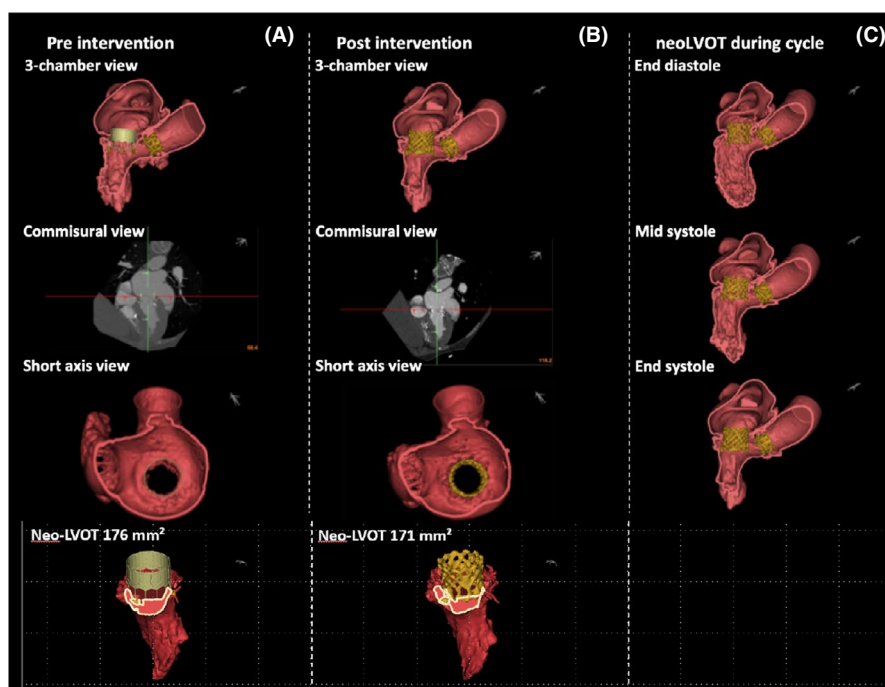


FIGURE 1 (A) Preprocedural virtual implantation (30% atrial/70% ventricular with Sapien 3 26 mm). 2D and segmented view with valve in 3-chamber, commissural and short-axis view at end-systole. (B) Postprocedural result with Sapien 3 26 mm in situ indicating excellent correlation with preprocedural virtual implantation. (C) Postprocedural result at end-diastole, mid-systole, and end-systole with Sapien 3 26 mm in a 3-chamber view with a measured neo-LVOT of 302 mm², 229 mm², and 171 mm², respectively

available valve frames and sizes is virtually positioned at different angles and depths of deployment (usually 20% atrial/80% ventricular to 40% atrial/60% ventricular) during the mid- to late-systolic phase, followed by planimetric assessment of the neo-LVOT and estimation of the risk for obstruction.³ Few studies have evaluated cutoff values for minimal LVOT area that would indicate an increased risk of LVOTO, although Wang et al. found a neo-LVOT area ≤ 189 mm² to have a high sensitivity and specificity for LVOTO post-procedure (defined as an increase in post-transcatheter mitral valve replacement (TMVR) gradient ≥ 10 mmHg).³ There is agreement that patient-specific simulation in TMVR is needed, since LVOTO appears to be the most important predictor of mortality at 30 days.¹ Different preprocedural planning software tools can be used to assess mitral valve anatomy, LV size, interventricular wall thickness, and transcatheter valve size, all of which influence neo-LVOT dimensions.² Crucial is that these tools allow for efficient analysis (i.e., become less time consuming) and accurately predict anatomic outcome. This case highlights that rigorous preprocedural planning is critical for appropriate selection of valve type and size, and determining optimal valve positioning depth (in this case 30% atrial/70% ventricular) and resulting neo-LVOT dimensions, while avoiding LVOTO. We think that evaluating neo-LVOT dimensions during the cardiac cycle may further refine our preprocedural assessment both qualitatively and quantitatively. Since the largest part of LV stroke volume is ejected prior to end-systole, further studies have to clarify at what time point during the cardiac cycle the risk for neo-LVOT obstruction is highest. Future studies may further assess dynamic interactions between the valve and host, resulting in more accurate predictions of LVOTO.⁴

4 | CONCLUSION

Transcatheter mitral valve-in-valve replacement in degenerated bioprostheses or valvular rings shows promise as an alternative to surgical MVR in selected high-risk patients, but preprocedural planning, especially planimetric assessment of the neo-LVOT, is crucial. Dynamic assessment of the neo-LVOT may further refine preprocedural planning, but is feasible using dynamic cardiac CT. Immersive assessment through virtual reality imaging may provide additional information since it provides malleable visualization of internal and external anatomy.

ACKNOWLEDGEMENTS

None.

CONFLICTS OF INTEREST

None.

AUTHOR CONTRIBUTION

Alexander Van De Bruaene wrote the manuscript. Stijn De Buck involved in technical support for 3D analysis and virtual reality imaging, and critical review. Peter Verbrugge involved in critical review. Christophe Dubois wrote the manuscript and involved in critical review.

ETHICAL APPROVAL

Ethics approval was not necessary for this case report. The patient's data and images are de-identified.

CONSENT

Written informed consent was obtained from the patient to publish this report in accordance with the journal's patient consent policy.

DATA AVAILABILITY STATEMENT

The data that support the findings of this study are available on request from the corresponding author. The data are not publicly available due to privacy or ethical restrictions.

ORCID

Alexander Van De Bruaene  <https://orcid.org/0000-0002-0469-8640>

REFERENCES

1. Urena M, Himbert D, Brochet E, et al. Transseptal transcatheter mitral valve replacement using balloon-expandable transcatheter heart valves: a step-by-step approach. *JACC Cardiovasc Interv.* 2017;10:1905-1919.
2. Blanke P, Naoum C, Webb J, et al. Multimodality imaging in the context of transcatheter mitral valve replacement: establishing consensus among modalities and disciplines. *JACC Cardiovasc Imaging.* 2015;8:1191-1208.
3. Wang DD, Eng MH, Greenbaum AB, et al. Validating a prediction modeling tool for left ventricular outflow tract (LVOT) obstruction after transcatheter mitral valve replacement (TMVR). *Catheter Cardiovasc Interv.* 2018;92:379-387.
4. de Jaegere P, Rocatello G, Prendergast BD, de Backer O, Van Mieghem NM, Rajani R. Patient-specific computer simulation for transcatheter cardiac interventions: what a clinician needs to know. *Heart.* 2019;105:s21-s27.

SUPPORTING INFORMATION

Additional supporting information may be found in the online version of the article at the publisher's website.

How to cite this article: Van De Bruaene A, De Buck S, Verbrugge P, Dubois C. Preprocedural imaging for transcatheter mitral valve-in-valve replacement: Planning makes perfect. *Clin Case Rep.* 2022;10:e05392. doi:[10.1002/ccr3.5392](https://doi.org/10.1002/ccr3.5392)