Case report

2 cases presenting with an unilateral adduction deficit associated with human adenosine deaminase 2 deficiency

Eline Veryser, MD, Department of Ophthalmology, University Hospitals, Leuven, Belgium (corresponding author)

Isabelle Meyts, PhD MD, Department of Pediatrics, University Hospitals, Leuven, Belgium

Ingele Casteels, PhD MD, Department of Ophthalmology, University Hospitals, Leuven, Belgium

Philippe Demaerel, PhD MD, Department of Radiology, University Hospitals, Leuven, Belgium

Catherine Cassiman, Phd MD, Department of Ophthalmology, University Hospitals, Leuven, Belgium

Eline Veryser
Oogziekten
Herestraat 49
3000 Leuven
Belgium

Eline.veryser@uzleuven.be

2 cases presenting with an unilateral adduction deficit associated with human adenosine deaminase 2 deficiency

SUMMARY

Deficiency of human adenosine deaminase 2 (DADA2) is an auto-inflammatory inborn error of immunity caused by biallelic deleterious mutations in the gene encoding ADA2. The purpose of this article is to raise awareness among ophthalmologists and pediatricians to consider the diagnosis DADA2 as a possible diagnosis in patients with acute onset of diplopia. In this article we describe two pediatric patients who presented with double vision due to an unilateral adduction deficit. We discuss the importance to recognize this clinically as an ophthalmologist. If a child is presenting with a sudden eye movement abnormality, we must be aware of the possibility of an ischemic insult due to an underlying genetic disorder such as DADA2, especially in patients with a positive familial history or associated clinical signs such as a personal history of characteristic skin lesions or paresis of other cranial nerves. Given the multi-organ involvement in this disorder, a multi-disciplinary approach is crucial to have timely a diagnosis and to treat this rare disorder appropriately.

INTRODUCTION

Deficiency of adenosine deaminase 2 (DADA2) is a rare congenital disorder with variable clinical expression, characterized by intermittent fevers, vasculopathy, bone marrow failure and mild immunodeficiency. Genetic analysis in patients with this syndrome revealed biallelic loss-of-function mutations in the CECR1 gene, now renamed ADA2, encoding the ADA2 protein. (1) (2) The pathogenesis of DADA2 is still controversial, but recent research revealed ADA2 results in a skewed pro-inflammatory M1 macrophage phenotype leading to a subsequent cascade of vasculopathy and inflammation. (3) Furthermore, alterations in B cell differentiation, higher rates of spontaneous cell death, lower concentration of B cells in the

peripheral blood and lower expression of CD27 and immunoglobulin G on B cells after stimulation, have been described. (1) Currently, a multifaceted pathogenesis was proposed by the group of Human et al, in which catalytic dysfunction, growth factor dysfunction and immune dysfunction were combined and attributed to the underlying mechanism of DADA2. (4) In the present report, we describe the presentation, radiological findings and clinical evolution in 2 patients with DADA2 both presenting at the ophthalmology department with an unilateral adduction deficit.

CLINICAL REPORT

The first case is a female infant who was born at term as the second child to nonconsanguineous parents. Family history revealed one 3-year-older sister diagnosed with DADA2 and a father with psoriasis. At the age of 19 months, the girl was admitted because of recurrent, asymptomatic skin sores on the extremities (see Table 1). Histological examination of skin biopsies showed an infiltrate of localized histiocytes, lymphocytes, a few eosinophils and monocytes, inconclusive for a Sweet-like or other inflammatory skin disease. A thorough history revealed intermittent fevers, early-onset vasculitis like lesions and frequent infections. Considering similar clinical features in her older sibling who was diagnosed with DADA2, additional tests for ADA2 deficiency were performed. Blood analysis revealed low plasma ADA2 enzyme activity levels, compatible with ADA2 deficiency. No other signs of associated immunoglobulin deficit were proven. Subsequently a MRI (magnetic resonance imaging) -scan of the brain was performed and showed no cerebral anomalies. A mild global delay in reaching developmental milestones was seen. At that moment a conservative approach with no need to start anti-TNF (tumor necrosis factor) therapy, but with regular follow-up visits was initiated. 9 months after the initial presentation at the dermatology department a decrease in antibodies was seen on laboratory testing. An IgG2, IgM and IgA deficiency was noticed, but there was no need for substitution with immunoglobulins in the absence of infections. Genetic analysis

proved that the patient shared her sister's heterozygous mutation, p.Gly47Val (p.G47V) and p.Arg169Gln (p.R169Q) in the ADA2 gene. At the age of 4 years, she presented at the emergency department because of abnormal quiet behavior since 1 day and ptosis of the left eyelid. Physical examination at admission showed a toddler with normal consciousness and normal pupillary reflexes. A clear adduction deficit of the left eye and an unilateral ptosis was seen. Neurological examination was normal; biochemistry revealed a mild neutropenia, but otherwise normal findings. CT (computed tomography) angiography showed no abnormalities. There was no history of fever or illness in the recent medical history of this girl. A MRI angiography was performed and showed an area suggestive for acute ischemia in the tegmentum of the midbrain at the position of the left oculomotor nucleus (Fig. 1). The girl was hospitalized in our hospital for 3 days. She developed diplopia and an intermittent abduction deficit of the right eye. A quantiferon test and X-ray of the thorax were performed to exclude tuberculosis before starting systemic etanercept, an anti-TNF drug. Treatment once a week with 16 mg (0.8mg/kg) subcutaneous etanercept was initiated. Over the course of several weeks, the clinical symptoms of diplopia and quiet behavior improved. There was a complete resolution of the ptosis of the left eye and a partial resolution of the adduction deficit of the left eye and the intermittent abduction deficit of the right eye. The therapy with etanercept has been continued.

The second case is a male infant who was born as the third child of healthy, nonconsanguineous parents. Family history revealed a immunodeficiency of unknown etiology in the 5-year-old brother of our patient. At the age of 5 months the child was admitted to our hospital with TEC (transient erythroblastopenia of childhood) for which he received two units of packed cells and a high dose of intravenous immunoglobulins, with spontaneous recuperation (see Table 1). He consulted the dermatology department regularly because of repetitive cutaneous impetigo-like lesions. At the age of 2 years he was hospitalized because of a serious bowel inflammation.

Blood tests showed chronic anemia, lymphopenia and hypogammaglobinemia. These triad of blood findings are a hallmark of DADA2. (5) A therapy with subcutaneous injections of immunoglobulins once a week was started for several months. Whole exome sequencing revealed a homozygous mutation, p.Arg169Gln (p.R169Q) in the ADA2 gene. The genetic analysis in this patient that revealed a mutation in the ADA2 gene was performed in January 2014, when DADA2 nor the preferred therapy had been described. At the age of 4 years he presented with a transient ischemic attack characterized by ataxia and recurrent falls. MRI angiography showed no evidence for ischemia nor vasculitis. Subsequently aspirin (3mg/kg/d) was started. 2 months later, he presented again with recurrent falls and unsteadiness. No complete resolution of symptoms was noted within 24 hours after onset, so the diagnosis of a reversible ischemic neurologic deficit was made. MRI angiography was unremarkable. At that time immunosuppressive therapy (sirolimus) was restarted. One year later, he presented with diplopia. Ophthalmological examination revealed an adduction deficit of the left eye. MRI scan of the brain confirmed a stroke situated in the midbrain at the level of the left nucleus of the oculomotor nerve (Fig. 2). In the weeks after the acute onset of diplopia, the complaints stabilized and a Fresnel prism was prescribed with resolution of double vision. At the moment a subarachnoid bleeding occurred at the level of the brain stem, aspirin was promptly stopped. Shortly after, an allogenic stem cell transplantation was planned. Over the next 5 years, the adduction deficit of the left eye gently improved and under therapy and close follow-up at pediatrics, the boy is currently doing well.

DISCUSSION

ADA2 deficiency is a rare congenital disorder with a variability of clinical phenotypes. This syndrome was first identified in 2014. (1-2) Patients present with a multitude of clinical symptoms (vasculopathy ranging from skin to central nervous system manifestations, ischemic or hemorrhagic stroke, immunodeficiency with hypogammaglobulinaemia and a low number

of memory B cells, cytopenia). (6) Genetic analysis confirms the diagnosis of an ADA2 mutation. This results in diminished enzymatic activity of ADA2 proteins. (7-8) Cranial nerve palsy is a well know manifestation in this disease. However, the phenotype is widely variable. The aim of our study is to make ophthalmologists and pediatricians aware of this disease identity.

Nowadays the therapy for DADA2 mainly consists of anti-TNF-agents. As a more definitive treatment, hematopoietic stem cell transplantation (HSCT) has good outcomes. In the second patient aspirin was initially given. Later studies would reveal aspirin use is controversial in DADA2 as hemorrhagic stroke is a potential complication. (6)

Our two patients had a very similar presentation with an adduction deficit of one eye, suggesting a lesion on the course of the oculomotor nerve. In both patients, an MRI scan confirmed the suspected stroke in the midbrain at the level of the oculomotor nucleus. It is important for ophthalmologists to be aware of this particular presentation and to consider an underlying genetic disorder such as ADA2 deficiency, knowing that a delay in diagnosis is disadvantageous for the prognosis. Due to its widely variable presentation, the correct diagnosis is not always easily made. We suggest a flow-chart to use in clinical practice when a child presents with sudden ocular motility abnormalities (Fig. 3). In highly suspicious cases, genetic analysis should be promptly performed to exclude DADA2 as a possible underlying cause.

REFERENCES

1. Zhou Q, Yang D, Ombrello AK, et al. Early-onset stroke and vasculopathy associated with mutations in ADA2. *N Engl J Med.* 2014; 370:911–920. DOI: 10.1056/NEJMoa1307361

2. Navon Elkan P, Pierce SB, Segel R et al. Mutant adenosine deaminase 2 in a polyarteritis nodosa vasculopathy. *N Engl J Med.* 2014; 370(10):921–931. DOI: 10.1056/NEJMoa1307362

3. Giannelou A, Zhou Q, Kastner DL et al. When less is more: primary immunodeficiency with an autoinflammatory kick. *Curr Opin Allergy Clin Immunol*. 2014;14(6):491-500. DOI: 10.1097/ACI.0000000000000117

4. Human A, Pagnoux C. Diagnosis and management of ADA2 deficient polyarteritis nodosa. *Int J Rheum Dis*. 2019; 22(Suppl 1):69–77. DOI: 10.1111/1756-185X.13283

5. Van Eyck L, Hershfield M, Pombal D et al. Hematopoietic stem cell transplantation rescues the immunologic phenotype and prevents vasculopathy in patients with adenosine deaminase 2 deficiency. *J Allergy Clin Immunol.* 2015 Jan;135(1):283-7.e5. DOI 10.1016/j.jaci.2014.10.010

6. Meyts I, Aksentijevich I. Deficiency of adenosine deaminase 2 (DADA2): updates on the phenotype, genetics, pathogenesis, and treatment. *J Clin Immunol*. 2018; 38(5):569–578. DOI: 10.1007/s10875-018-0525-8

7. Caorsi R, Penco F, Grossi A et al. ADA2 deficiency (DADA2) as an unrecognised cause of early onset polyarteritis nodosa and stroke: a multicentre national study. *Ann Rheum Dis*. 2017; 76(10):1648–1656. DOI: 10.1136/annrheumdis-2016-210802

8. Moens L, Hershfield M, Arts K et al. Human adenosine deaminase 2 deficiency: A multi-faceted inborn error of immunity. *Immunol Rev*. 2019; 287(1):62-72. DOI: 10.1111/imr.12722

LEGENDS FOR ILLUSTRATIONS

Fig. 1 Axial FLAIR (a) and sagittal FLAIR (b) MR images of a 4-year-old girl with a presentation of acute ptosis and adduction deficit of the left eye depicting an oval-shaped, high-signal-intensity lesion situated paramedian in the tegmentum of the midbrain at the level of the left oculomotor nucleus.

Fig. 2 MR images of a 5-year-old boy demonstrating an acute infarct in the midbrain. A T2-weighted (a) axial image shows a focus of high signal in the left paramedian midbrain tegmentum. The axial anisotropic diffusion-weighted image (b) and corresponding apparent diffusion coefficient map (c) confirms the presence of cytotoxic edema in acute ischemia.

MR: magnetic resonance; FLAIR: fluid-attenuated inversion recovery; DWI: diffusion-weighted imaging

Fig. 3 Differential diagnoses in children presenting with sudden ocular motility abnormalities.

TABLES

Table 1 Clinical presentation, key points and therapy of ADA2-deficient patients

Table

Case 1	Clinical presentation	Key points	Therapy
Age of 19 months	Skin sores on the extremities	- Biopsy: inflammatory skin disease - Blood test: low plasma ADA2 activity levels - Blood taken for genetic analysis - MRI-scan: normal	Conservative approach with close follow-up
9 months after initial presentation	Routine control showed low levels of immunoglobulins	- Genetic analysis proved mutation in ADA2 gene	No need for substitution with immunoglobulins
Age of 4 years	Quiet behavior and ptosis of left eyelid	- Adduction deficit of left eye was seen - Neurological examination: normal - Blood test: mild neutropenia - CT angiography: normal - MRI-scan: acute ischemia at level of oculomotor nucleus	- Start anti-TNF therapy
Case 2	**Clinical presentation**	**Key points**	**Therapy**
Age of 5 months	- Transient erythroblastopenia of childhood - impetigo-like skin lesions		2 units of packed cells and immunoglobulins
Age of 2 years	Serious bowel infection	Chronic anemia, lymphopenia and hypogammaglobinemia	Therapy with immunoglobulins
January 2014	Routine control	Homozygous mutation in ADA2 gene found	
Age of 4 years	Ataxia and recurrent falls	MRI angiography: no evidence for ischemia nor vasculitis	Aspirin started
	Recurrent falls and unsteadiness	MRI angiography: normal	Sirolimus started
Age of 5 years	Diplopia	- Adduction deficit of left eye - MRI scan: stroke at level of oculomotor nucleus	- Fresnel prism - Immunoglobulins - Allogenic stem cell transplantation
		MRI scan: subarachnoid bleeding	Aspirin stopped

Figure 1

Click here to access/download;Figure;Figure 1.JPG

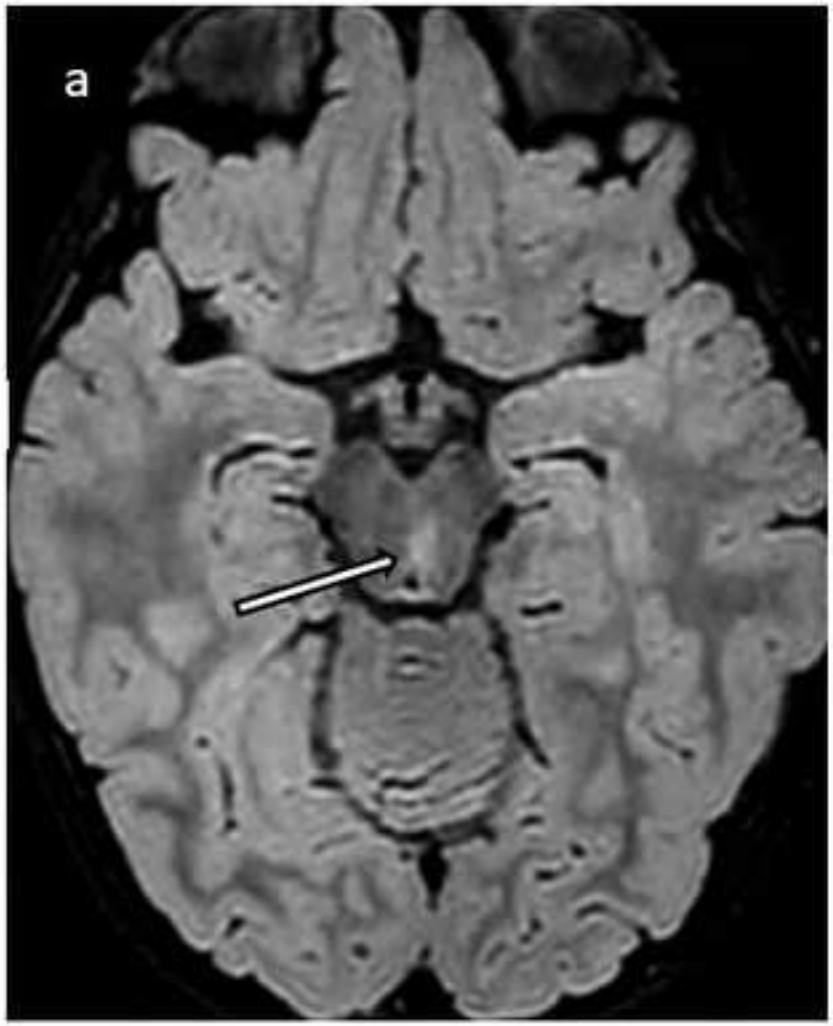

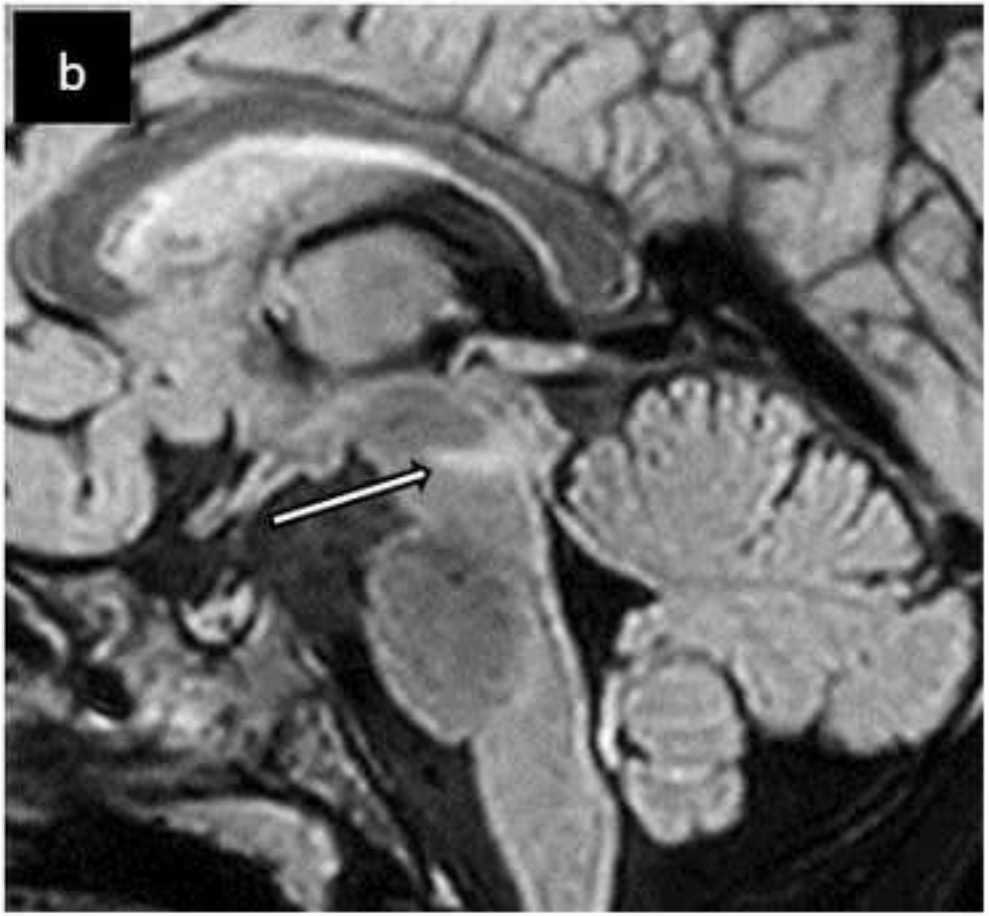

Figure 2

Click here to access/download;Figure;Figure 2.JPG

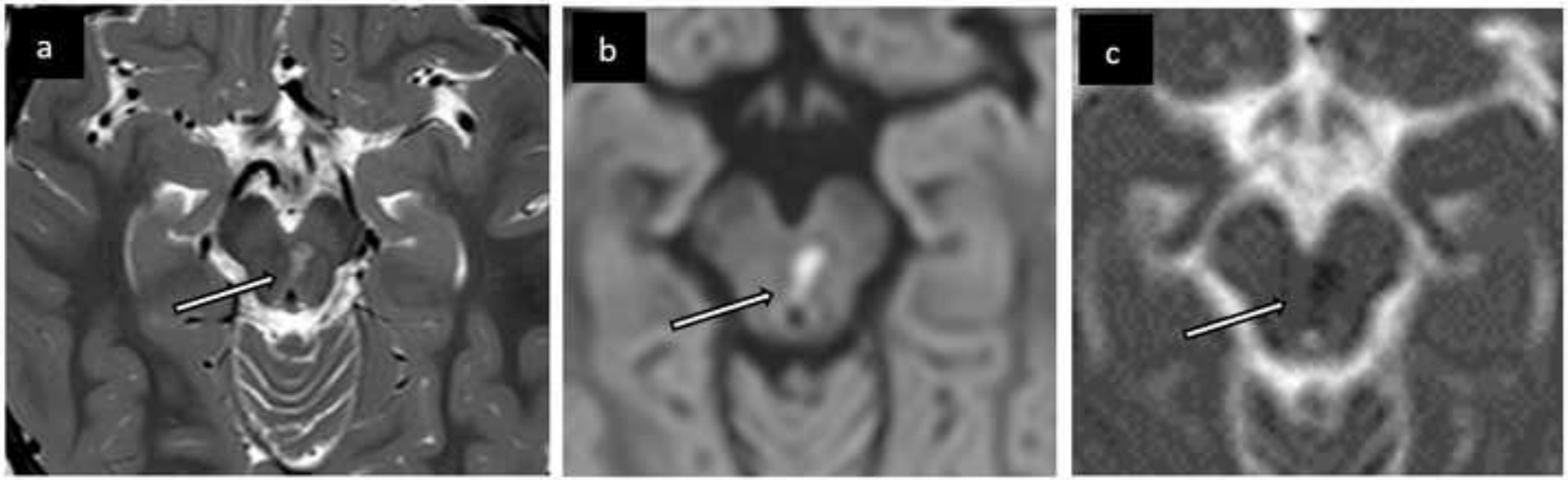

Figure 3

Click here to access/download;Figure;Figure 3.JPG

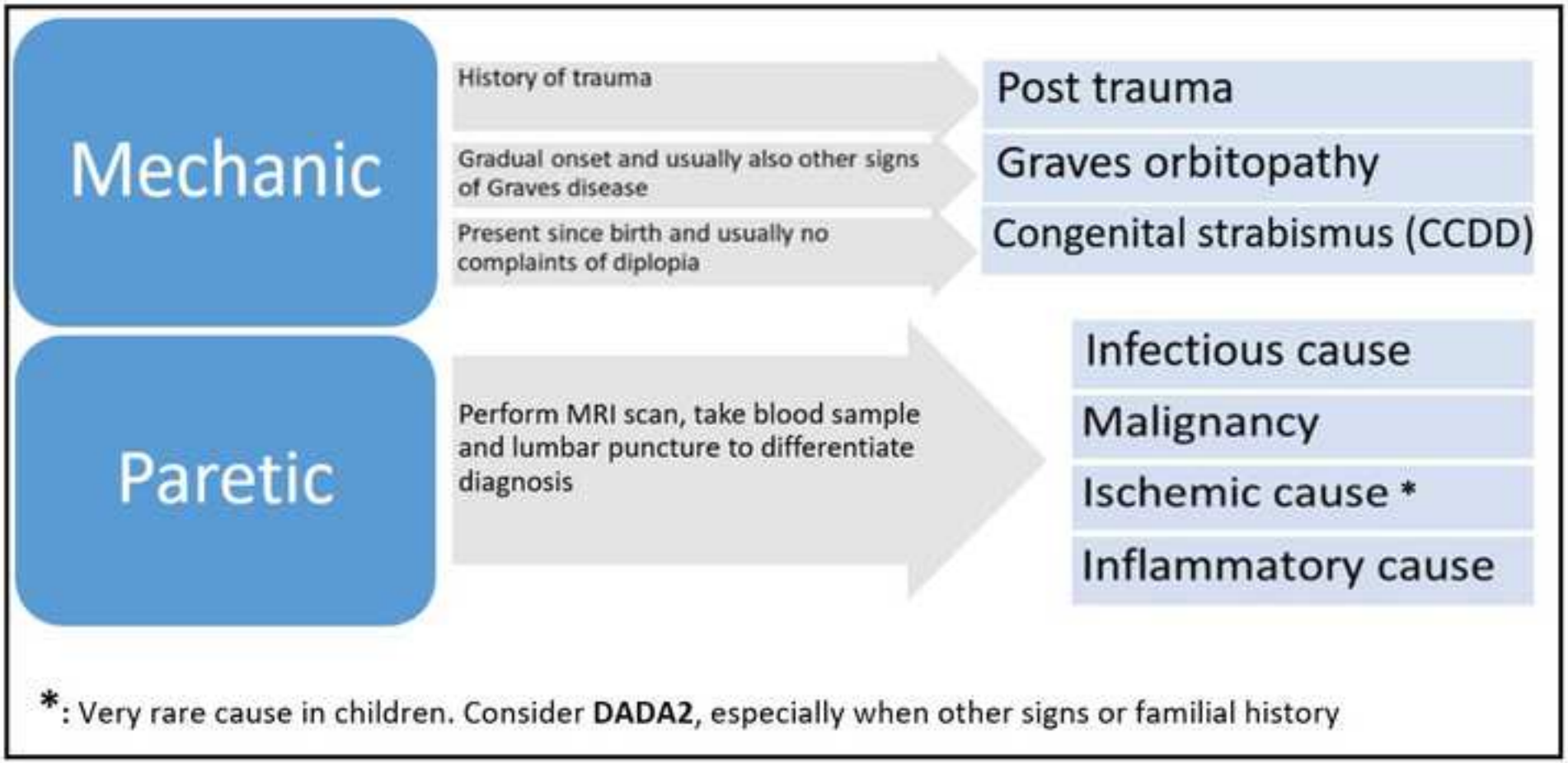

Click here to access/download
Author Statement/ICMJE Form
jpos_author statement_Veryser.pdf

Click here to access/download
Author Statement/ICMJE Form
jpos_author statement_Meyts.pdf

Click here to access/download
Author Statement/ICMJE Form
jpos_author statement_Casteels.pdf

Click here to access/download
Author Statement/ICMJE Form
jpos_author statement_Cassiman.pdf

Click here to access/download
Author Statement/ICMJE Form
jpos_author statement_Demaerel.pdf