

# Impact of Osteoarthritis and Total Joint Arthroplasty on the Kinematics of the Trapeziometacarpal Joint: A Pilot Study

Priscilla D'Agostino, MD, PhD,\*†‡ Benjamin Dourthe, MS,\* Faes Kerkhof, MS,\*  
Evie E. Vereecke, MS, PhD,\* Filip Stockmans, MD, PhD\*§

**Purpose** To quantify the effect of osteoarthritis (OA) and total trapeziometacarpal (TMC) joint replacement on thumb kinematics during the primary physiological motions of the thumb.

**Methods** We included 4 female patients with stage III TMC OA. A computed tomography–based markerless method was used to quantify the 3-dimensional thumb kinematics in patients before and after TMC joint replacement surgery with the Arpe implant.

**Results** Trapeziometacarpal OA led to a marked decrease of internal rotation and abduction of the first metacarpal (MC1) during thumb flexion and a decrease of MC1 adduction during thumb adduction. As a compensatory phenomenon, the trapezium displayed increased abduction. The absence of MC1 translation in the ball-and-socket implant seems to induce a decrease of MC1 adduction as well as a decrease of trapezium adduction during thumb adduction, compared with OA and healthy joints. Implant replacement displayed an unchanged MC1 flexion during thumb flexion and seemed to slightly increase MC1 axial rotation during thumb flexion and adduction. Abduction and adduction of the MC1 are limited and compensated by this somewhat increased axial rotation, allowing more efficient thumb opposition.

**Conclusions** The study highlights that advanced TMC OA mainly restricts the MC1 mobility. We also showed that, whereas total joint arthroplasty is able to restore thumb function, it cannot fully replicate the kinematics of the healthy TMC joint.

**Clinical relevance** The quantification of TMC joint kinematics in OA and implanted patients is essential to improve our understanding of TMC OA as well as to enhance the functionality of implant designs. (*J Hand Surg Am.* 2017; ■(■):1.e1-e10. Copyright © 2017 by the American Society for Surgery of the Hand. All rights reserved.)

**Key words** Implant, medical imaging, OA, thumb, TMC joint.



From the \*Muscles & Movement, Department of Development and Regeneration, Biomedical Sciences Group, Kulak; the †Louise Hand Clinic; the ‡Europe Clinic, St-Elisabeth Clinic, Brussels; the §Handgroep, AZ Groeninge, Kortrijk, Belgium.

Received for publication February 13, 2017; accepted in revised form October 10, 2017.

No benefits in any form have been received or will be received related directly or indirectly to the subject of this article.

**Corresponding author:** Priscilla D'Agostino, MD, PhD, Muscles & Movement, Department of Development and Regeneration, Biomedical Sciences Group, KU Leuven Campus Kulak Kortrijk, Etienne Sabbelaan 53, B-8500 Kortrijk, Belgium; e-mail: [dagostinoprish@gmail.com](mailto:dagostinoprish@gmail.com).

0363-5023/17/ ■ ■ -0001\$36.00/0  
<https://doi.org/10.1016/j.jhsa.2017.10.011>

**T**HE BASAL THUMB JOINT OR trapeziometacarpal (TMC) joint is crucial for the extensive mobility of the thumb. With its unique configuration, this saddle-shaped joint contributes to the dexterity of the human hand by allowing both forceful power and precision gripping as well as fine manipulation.<sup>1</sup>

Available treatment options for symptomatic osteoarthritis (OA) of the TMC joint range from nonsurgical treatments<sup>2</sup> to surgical options such as trapeziectomy, with or without ligament reconstruction and tendon interposition, arthrodesis, and total joint arthroplasty.<sup>3–8</sup> Total joint arthroplasty for patients with TMC OA has been performed for more than 40 years,<sup>9,10</sup> mainly using ball-and-socket implants with a fixed center of rotation, to replace the saddle-shaped TMC joint. Although there are numerous retrospective clinical studies investigating various types of TMC joint implants,<sup>7</sup> little is known about the effect of the implant on the *in vivo* kinematics of the TMC joint. Likewise, the impact of OA on TMC joint kinematics remains unclear; only 3 recent studies have investigated the TMC joint kinematics of healthy and OA subjects using a 3-dimensional motion-capture system.<sup>11,12</sup>

Recent medical imaging–based studies on the native TMC joint have revealed that thumb motions (ie, extension, flexion, abduction, and adduction) are associated with a significant amount of axial rotation of the first metacarpal (MC1)<sup>13–15</sup> and also of the trapezium and scaphoid with lower magnitudes.<sup>14</sup> These *in vivo* kinematic studies have demonstrated that thumb flexion entails flexion, abduction, internal rotation, and translation of the MC1, trapezium, and scaphoid. Likewise, thumb adduction leads to adduction, external rotation, extension, and translation of all 3 bones. Therefore, the full range of motion of the thumb depends on the mobility of each joint in the articular chain.

The central aim of this study was to quantify the effect of OA and total TMC joint replacement on the kinematics of the thumb joints during the primary physiological motions of the thumb (extension-flexion and abduction-adduction). First, we assessed the effect of OA on the thumb kinematics by comparing patients with advanced TMC OA to a group of healthy controls.<sup>14</sup> Next, the kinematics of patients with TMC joint arthroplasty were measured and compared with healthy controls to assess the implant's ability to restore the kinematics of the native TMC joint.<sup>14</sup> Finally, we compared the kinematics of the thumb joints before and after TMC joint replacement surgery. Our hypotheses were (1) OA

affects the kinematics of the MC1 and trapezium and (2) the ball-and-socket implant design cannot fully replicate the native TMC joint kinematics.

## METHODS

### Subject selection

The study protocol, conformed to the ethical guidelines of the 1975 Declaration of Helsinki, and was approved by the Medical Ethical Commission of our university (# B322201420166). After providing informed consents, 4 patients from the patient base of the senior hand surgeon (F.S.) were recruited. Considering the high incidence of TMC OA in postmenopausal women<sup>16</sup> and to avoid an age- or sex-related impact on the results, only women volunteers of 50 years or older were included in this study. Before enrolment, each subject underwent a clinical examination of both hands by a board-certified orthopedic hand surgeon (P.D.A) to rule out other pathological conditions. Each patient was also subjected to a radiological assessment of the affected side to assess the stage of TMC OA according to the Eaton-Littler classification.<sup>17,18</sup> The inclusion criteria were (1) female sex; (2) age older than 50 years; (3) thumb pain (symptomatic); (4) Eaton stage III on x-ray; and (5) eligible for TMC joint arthroplasty with a ball-and-socket implant. The following comorbidities were considered as exclusion criteria: traumatic injury to the thumb, previous thumb surgery, inflammatory arthritis, metabolic bone disease, and any signs of scaphotrapezotrapezoid OA. Each subject completed the Disabilities of the Arm, Shoulder, and Hand (DASH) and the Patient-Rated Wrist Evaluation (PRWE) questionnaires before and after TMC joint implant replacement surgery. The mean age of our series (1 right and 3 left thumbs) was 60.8 years (range, 51–71 years; Table 1).

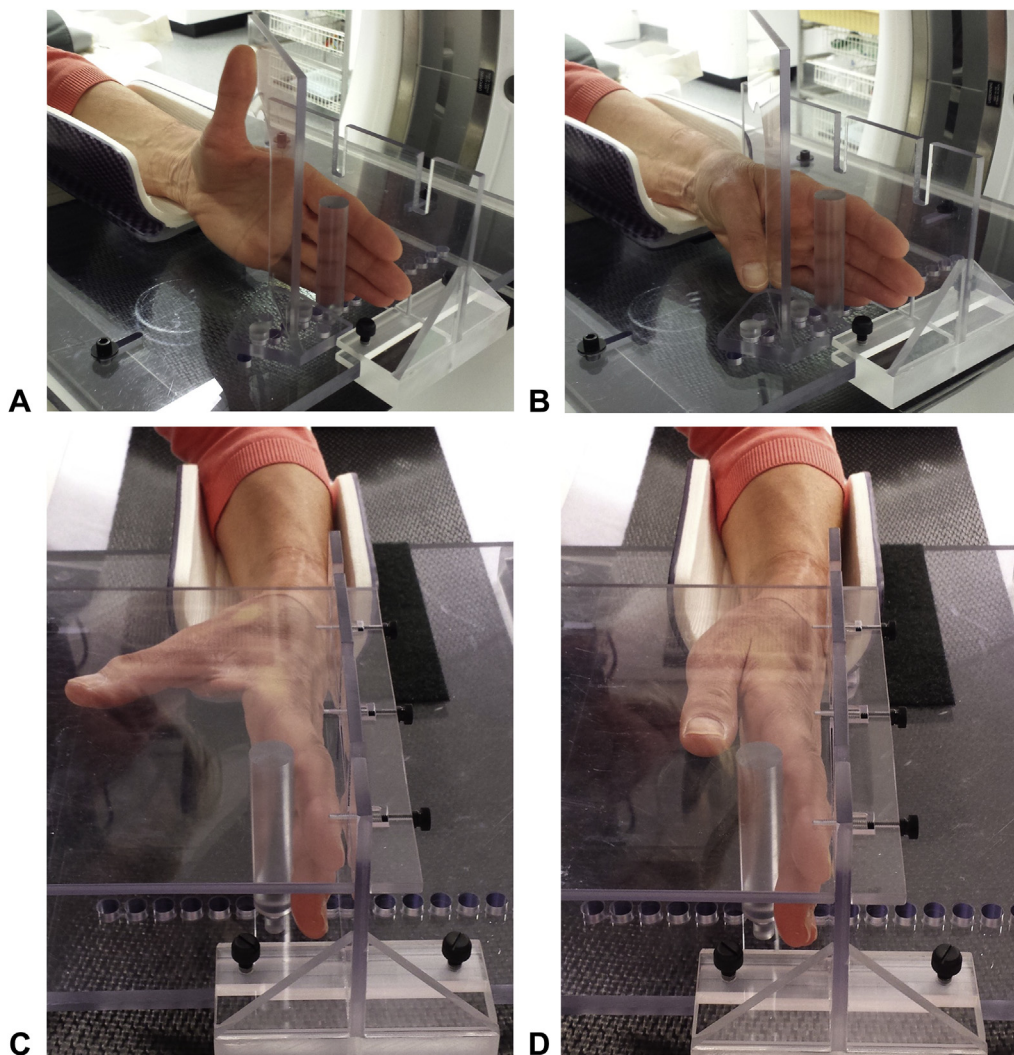
A second cohort of 16 healthy female subjects (mean age, 59.5 years; range, 50–82 years), which were recruited among the university staff and acquaintances, served as a control group. This healthy control group was also used in a previous study on thumb joint kinematics and contact biomechanics.<sup>14,19,20</sup> Subjects in the healthy control group had no clinical or radiological signs of TMC OA and were subjected to the same scanning protocol as the 4 patients.

### Surgical protocol

All patients were treated in the same hospital (AZ Groeninge, Kortrijk, Belgium), by the same hand surgeon (F.S.), using the Arpe ball-and-socket prosthesis (Biomet, France). The lateral (dorsoradial)

**TABLE 1. Age and Duration of the Follow-Up Period of Each Subject**

	Subject 1	Subject 2	Subject 3	Subject 4
Age (y)	51	71	62	59
Follow-up (mo)	11	12	7	6



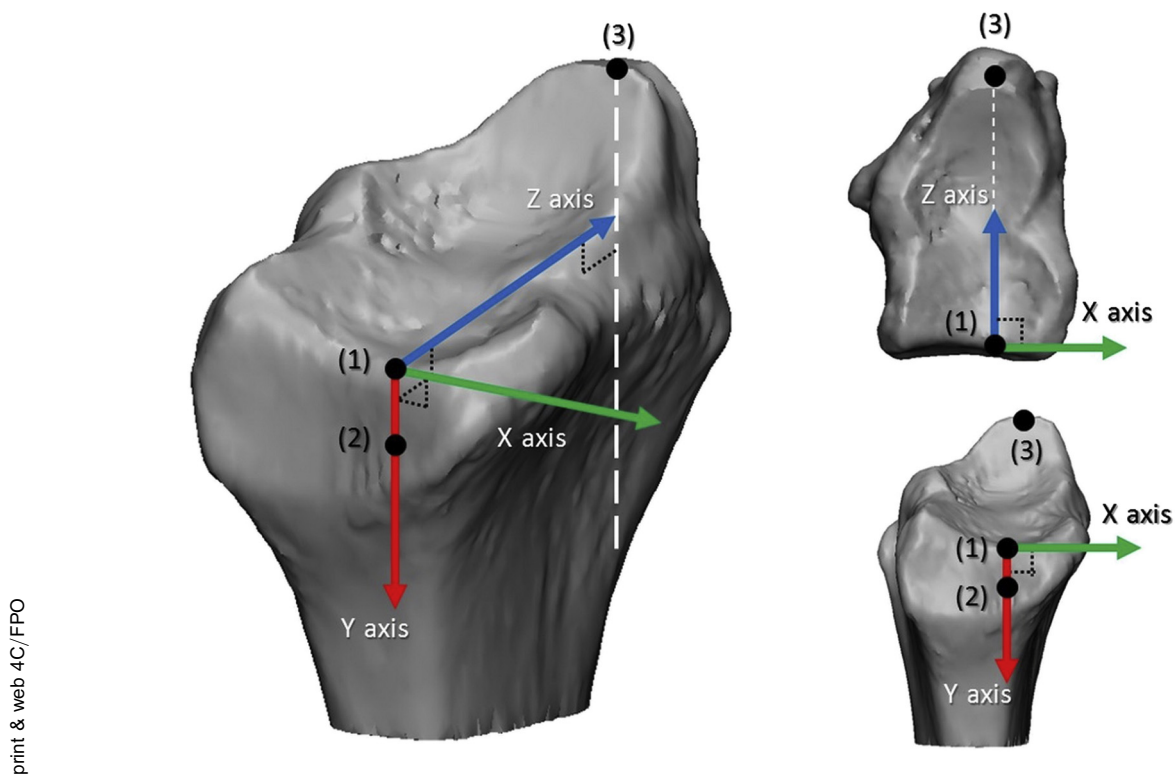
**FIGURE 1:** The custom-designed, radiolucent, polycarbonate rig used to standardize the motion of the thumb during **A** active extension, **B** flexion, **C** abduction, and **D** adduction.

approach to the TMC joint was used. The base of the MC1 was detached from all its ligamentous attachments in a subperiosteal plane (dorsal, volar, and intermetacarpal ligaments) before preparing the bones with the instrumentation. After implanting the trial stem, neck, and cup (diameter of 9 mm, non-retentive), the stability of the prosthesis was assessed in abduction, retropulsion, and opposition. The final implant was then inserted and the subcutaneous soft-tissues and skin were closed after a meticulous dorsal capsulorrhaphy. Thumb immobilization was applied

for 3 weeks following surgery, after which patients were allowed to start self-directed physiotherapy.

#### Computed tomography scanning protocol

The affected side (wrist and thumb) of each subject was scanned, before surgery (OA group) and 6 to 12 months after joint arthroplasty (implant group). Scans were made with a 64-slice Discovery HD 750 computed tomography (CT) scanner (GE Healthcare, Little Chalfont, UK). The scanning parameters were the following: slice thickness, 0.625 mm; pixel size,



**FIGURE 2:** Definition of the radius-based coordinate system with (1) the lowest point on the distal border of the ulnar notch (bordering the lunate fossa), (2) the proximal border of the ulnar notch, and (3) the tip of the radial styloid.

**TABLE 2. Rotation Angles in 3 Directions and the Total Translation of the MC1 During Thumb Flexion and Adduction in the 3 Groups\***

MC1	Control	OA	Implant
<b>Thumb Flexion</b>			
Flexion angle (x axis) (°)	30.7 ± 12.4	29.7 ± 11.2	31.1 ± 7.4
Internal rotation angle (y axis) (°)	13.6 ± 10.2	3.4 ± 2.9	9.4 ± 7.1
Abduction angle (z axis) (°)	30.5 ± 13.1	14.4 ± 12.6	21.5 ± 12.5
Total translation (mm)	4.5 ± 2.5	5.5 ± 1.4	0.8 ± 0.3
<b>Thumb Adduction</b>			
Extension angle (x axis) (°)	5.0 ± 4.5	6.2 ± 2.8	4.2 ± 4.2
External rotation angle (y axis) (°)	13.2 ± 6.4	10.9 ± 5.3	17.6 ± 3.0
Adduction angle (z axis) (°)	33.7 ± 10.4	25.4 ± 12.6	22.0 ± 9.4
Total translation (mm)	9.7 ± 2.2	7.8 ± 2.3	0.6 ± 0.2

\*Values are expressed as mean ± SD.

0.293 mm; field of view, 150 mm; voltage, 100 kV; source current, 156 mA; bone algorithm. Each subject was scanned from the distal part of the radius to the MC1 joint in 4 extreme positions: at maximal active extension, flexion, abduction, and adduction of the thumb (Fig. 1). To avoid interindividual variability and to allow comparison with the kinematics of healthy control subjects, the same setup and protocol were used as in recent publications.<sup>13,14,21</sup> The

radiation dose was estimated to 6.85 mGy (CT dose index volume) for 1 static scan.

#### Image processing

Each scan was reconstructed in a Digital Imaging and Communications in Medicine (DICOM) format and segmented semiautomatically using medical imaging processing software (Mimics Research 18.0 × 64 with CT bone plug-in; Materialise, Leuven, Belgium)



**TABLE 3. Rotation Angles in 3 Directions and the Total Translation of the Trapezium During Thumb Flexion and Adduction in the 3 Groups\***

Trapezium	Control	OA	Implant
<b>Thumb Flexion</b>			
Flexion angle (x axis) (°)	4.4 ± 3.5	5.0 ± 1.5	6.0 ± 2.5
Internal rotation angle (y axis) (°)	3.8 ± 2.9	3.5 ± 1.8	4.3 ± 1.0
Abduction angle (z axis) (°)	5.1 ± 4.3	11.7 ± 4.8	8.5 ± 3.4
Total translation (mm)	1.4 ± 0.9	2.6 ± 1.1	1.6 ± 0.5
<b>Thumb Adduction</b>			
Extension angle (x axis) (°)	3.8 ± 2.4	3.1 ± 2.2	2.4 ± 2.0
External rotation angle (y axis) (°)	2.8 ± 1.6	3.0 ± 2.7	2.6 ± 1.6
Adduction angle (z axis) (°)	5.1 ± 3.4	6.3 ± 2.3	3.4 ± 2.4
Total translation (mm)	1.1 ± 0.4	1.6 ± 0.6	1.2 ± 0.4

\*Values are expressed as mean ± SD.

with constant segmentation parameters (thresholding, minimum of 294 Hounsfield; smoothing, 1 iteration, smooth factor of 0.4). Three-dimensional surface bone models of the radius, scaphoid, trapezium, and MC1 were generated for each configuration.

### Bone kinematics

A custom Matlab code (MathWorks, Natick, MA) based on an iterative closest point algorithm<sup>14</sup> was written to calculate the transformation matrix of each bone between 2 extreme thumb postures (ie, maximal extension vs maximal flexion and maximal abduction vs maximal adduction). A local, radius-based coordinate system was used in agreement with International Society of Biomechanics (ISB) standards,<sup>22</sup> so all rotation angles are expressed relative to the anatomical planes of the forearm (Fig. 2). To better quantify bone motion and facilitate interpretation, 3 rotation angles, representing the amount of rotation occurring in each anatomical plane, were calculated based on each transformation matrix (flexion/extension angle, abduction/adduction angle, internal rotation [pronation]/external rotation [supination]).<sup>14</sup> Translations were also calculated along each direction and the total amount of translation was calculated (ie, norm of the corresponding translation vector, representing the total amount of translation without giving information about the direction of the translation).

## RESULTS

### Functionality scores

Prior to surgery (OA group), the mean DASH and mean PRWE scores were 28.6 (range, 5.0–62.5) and 39.9 (range, 12.0–88.0), respectively. After surgery

(implant group), the mean DASH and mean PRWE scores were 12.3 (range, 0.8–37.5) and 3.6 (range, 0–8.5) respectively.

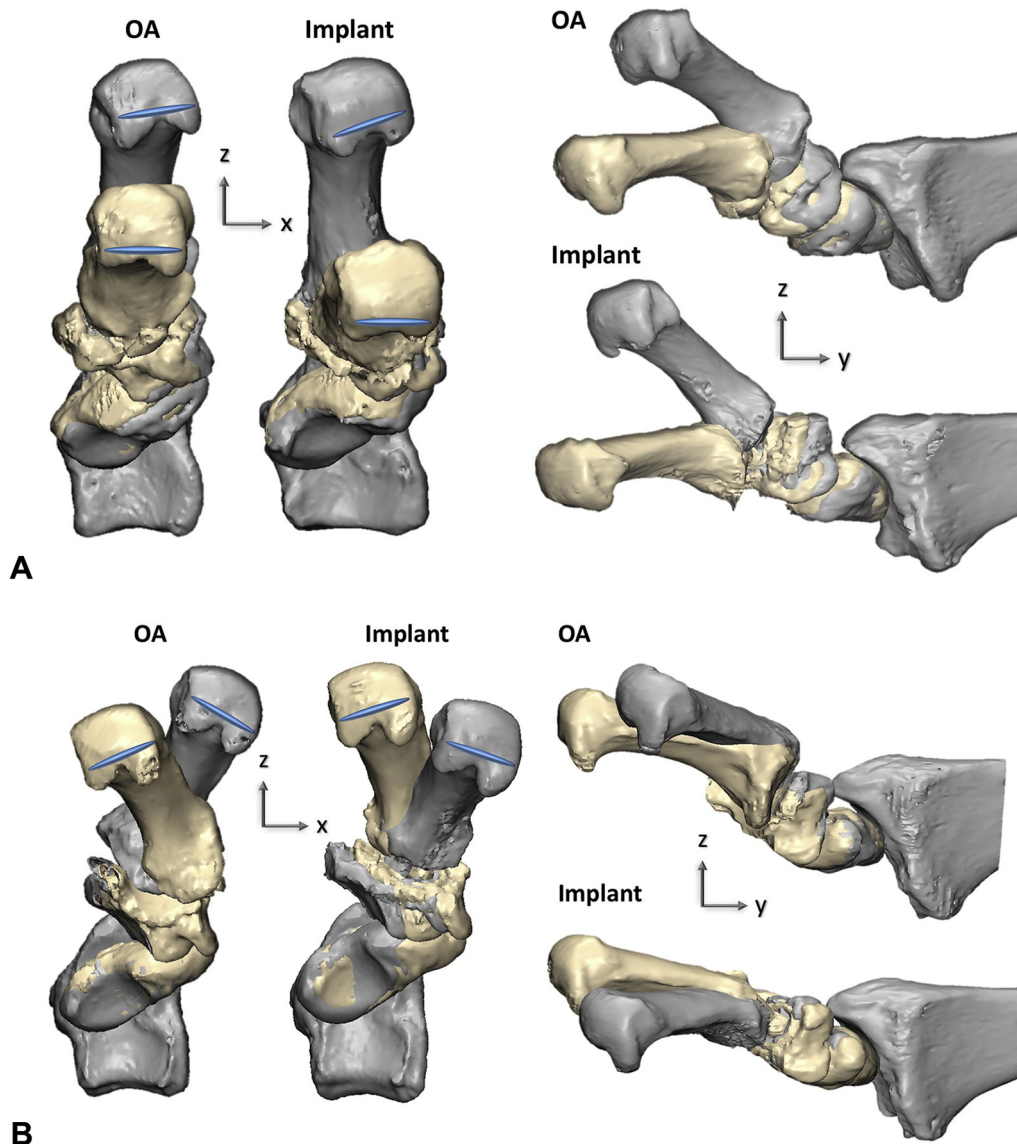
### Osteoarthritis versus control kinematics

Osteoarthritis decreased MC1 adduction during thumb adduction but had no major impact on MC1 flexion during the thumb flexion. Osteoarthritis also decreased the MC1 internal rotation and abduction during thumb flexion. These modified MC1 kinematics during thumb flexion are coupled with an increased abduction angle of the trapezium (Tables 2, 3).

In OA patients and in healthy subjects, we observed a similar amount of translation of the MC1 base during thumb adduction (Table 2). During thumb flexion, the total amount of MC1 translation was also comparable between the healthy and the OA groups (Table 2). The direction of translation of the MC1 during thumb flexion and adduction varied markedly between subjects, in both the healthy and OA groups. No consistent direction of translation could be observed.

### Osteoarthritis versus implant kinematics

In the implant group (n = 4), the internal rotation and abduction of the MC1 seemed to increase during thumb flexion; this trend was also observed for abduction of the scaphoid (Figs. 3A, 4A, B). During thumb adduction, the main effect of implant surgery seemed to be a slight increase in external rotation and decreased adduction of the MC1 and a decreased abduction of the trapezium (Figs. 3B, 4C, D and Tables 2–4).



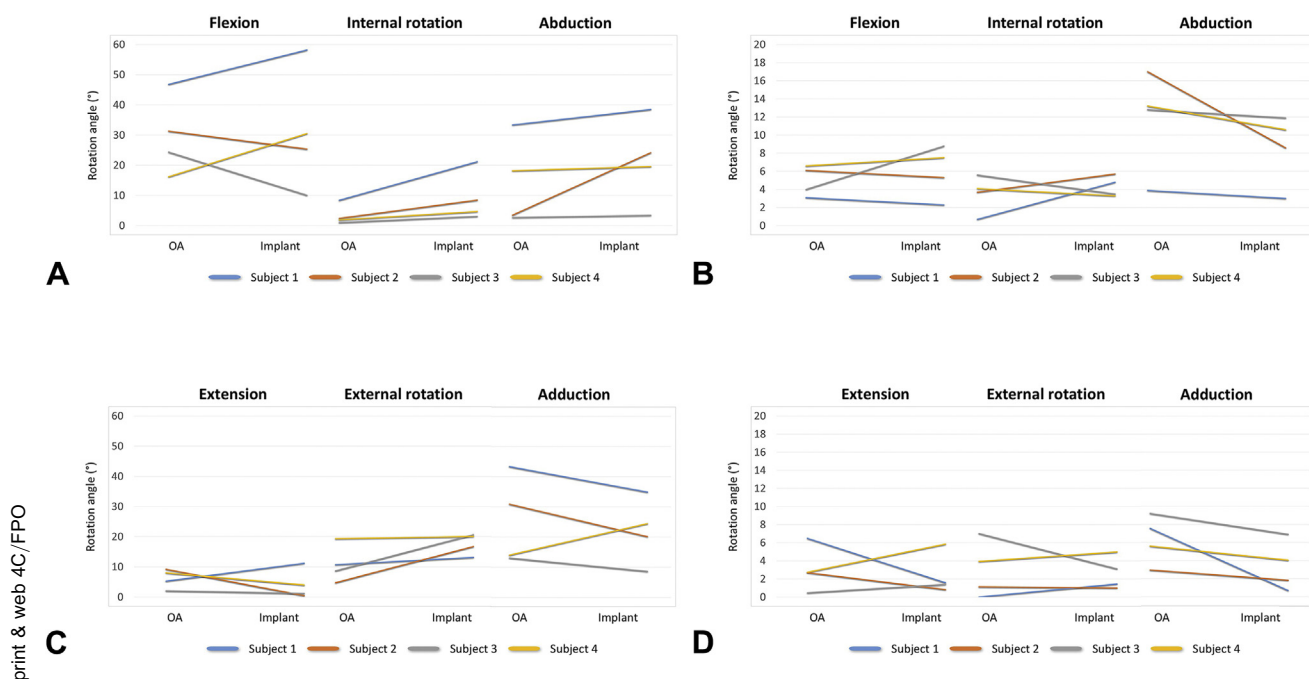
**FIGURE 3:** Planar representation for 1 representative subject of the **A** abduction, flexion, and internal rotation of the MC1, trapezium, and scaphoid observed during flexion of the thumb (gray, extension; yellow, flexion) and the **B** adduction, extension, and external rotation of the MC1 observed during adduction of the thumb (gray, abduction; yellow, adduction).

### Implant versus control kinematics

In postoperative patients with total joint arthroplasty with the Arpe implant, we observed that the implant did not fully restore MC1 adduction during thumb adduction, which remained much lower compared with a healthy joint. During thumb flexion, MC1 flexion was almost completely restored by the implant, but not MC1 abduction. We did, however, see that the implant increased MC1 axial rotation during thumb adduction. Translation of the MC1 during thumb flexion and adduction was almost nonexistent with a ball-and-socket implant (Table 2) and seemed to be associated with decreased adduction of the trapezium during thumb adduction (Table 3).

### DISCUSSION

Compared with healthy controls, our patients with stage III TMC OA demonstrated a marked decrease of internal rotation and abduction of the MC1 during thumb flexion and a decrease of MC1 adduction during thumb adduction. These results do, to some extent, agree with previous studies on the influence of OA on the 3-dimensional kinematics of the TMC joint.<sup>11,12,23,24</sup> These studies all observed a TMC joint motion deficit in patients with TMC OA stage II/III and stage III/IV, but whereas Hamann et al<sup>12</sup> found mainly a restriction of thumb abduction-adduction with preservation of flexion-extension motion and axial rotations of the thumb, a



**FIGURE 4:** Rotation angles of the **A** MC1 and the **B** trapezium in the OA and implant groups during extension-flexion motion of the thumb. Rotation angles of the **C** MC1 and the **D** trapezium in the OA and implant groups during abduction-adduction motion of the thumb.

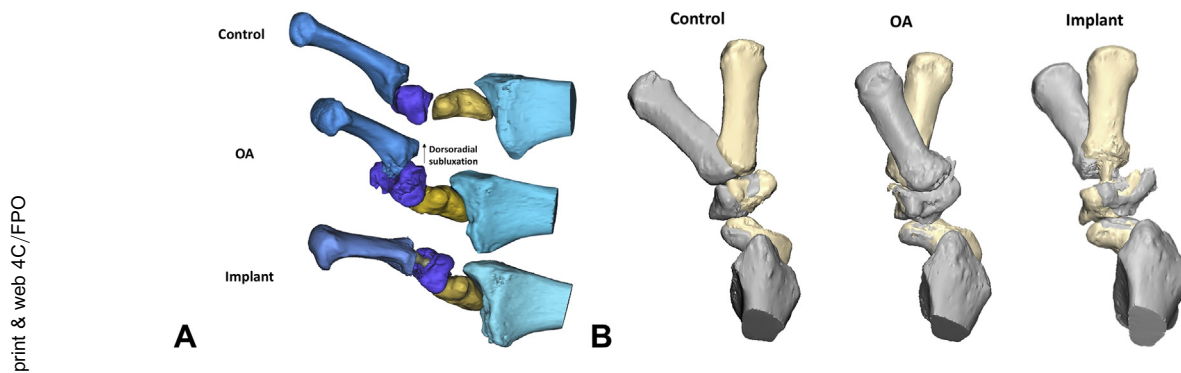
**TABLE 4. Rotation Angles in 3 Directions and the Total Translation of the Scaphoid During Thumb Flexion and Adduction in the 3 Groups\***

Scaphoid	Control	OA	Implant
<b>Thumb Flexion</b>			
Flexion angle (x axis) (°)	2.7 ± 1.8	1.2 ± 0.6	1.6 ± 1.0
Internal rotation angle (y axis) (°)	1.9 ± 1.6	1.5 ± 0.9	0.8 ± 0.9
Abduction angle (z axis) (°)	4.1 ± 3.5	3.9 ± 1.9	8.3 ± 3.0
Total translation (mm)	1.8 ± 0.8	1.2 ± 0.3	2.9 ± 1.0
<b>Thumb Adduction</b>			
Extension angle (x axis) (°)	1.6 ± 1.5	1.2 ± 0.9	2.5 ± 2.4
External rotation angle (y axis) (°)	2.1 ± 1.9	1.3 ± 1.3	2.7 ± 1.6
Adduction angle (z axis) (°)	4.7 ± 3.2	4.0 ± 2.3	3.5 ± 0.5
Total translation (mm)	1.6 ± 0.6	1.2 ± 0.5	1.8 ± 1.4

\*Values are expressed as mean ± SD.

restriction of all motions was described by Miura et al<sup>24</sup> and Gehrman et al.<sup>11</sup> Chèze et al<sup>23</sup> reported a limited range of motion of the TMC joint in 1 male patient with early OA, but only for thumb flexion. The discrepancy with the results of our study could be due to the use of a different motion tracking technique (uniplanar fluoroscopy<sup>24</sup> and surface markers<sup>11,12,23</sup>). In addition, thumb kinematics are described as 3-dimensional motion capabilities of the

TMC joint and expressed as a range of motion of the TMC joint, making the comparison with our results challenging. The kinematic changes we observed in the OA group could be partially explained by bone deformations of the MC1 and trapezium that occur with advanced TMC OA.<sup>20,25</sup> In these patients, the preserved flexion of the MC1 could be linked to the bulging and lengthened articular surface of the MC1, which runs inside the groove-shaped articular surface



**FIGURE 5:** MC1 dorsoradial subluxation reduction with a **A** ball-and-socket Arpe implant and **B** translation of the base in the 3 groups.

of the trapezium.<sup>20</sup> The impaired abduction-adduction and axial rotation of the MC1 in OA patients could be explained by the deepening of the trapezium and the lengthening of its ulnar and radial horns<sup>20,25</sup> and the combined dorsoradial translation of the MC1 base.<sup>17,24,26</sup> This new configuration of the TMC joint, which is no longer saddle-shaped but more condylar with a higher congruency,<sup>20</sup> preserves MC1 flexion but impairs MC1 internal rotation and abduction-adduction. This phenomenon is accompanied with an increased abduction of the trapezium in the OA group (mainly during thumb flexion), which seems to act as a compensatory motion for the ankylosed TMC joint. The reciprocal flexion-adduction of the MC1 shaft to the dorsal subluxation of the MC1 base leads to the adduction deformity of the thumb (concomitant retraction of the first web space) observed in late stage TMC OA.<sup>17,27,28</sup>

Our results for TMC joint replacement indicate that the Arpe implant is not able to fully replicate the motion of the healthy TMC joint. The amount of MC1 adduction during thumb adduction remains much lower compared with the healthy joint and is even somewhat lower than before surgery. This effect can be understood by the inherent absence of translation in the ball-and-socket configuration compared with the healthy saddle joint. Whereas MC1 flexion during thumb flexion remains largely unchanged in patients with an implant, we saw a slight increase in MC1 axial rotation during thumb flexion and adduction in all 4 patients. This slightly increased axial rotation might compensate for the limited range of abduction and adduction of the MC1 in implanted patients and could improve thumb opposition. Translation of the MC1 is nonexistent, which is expected because of the fixed center of rotation of the implant. By centering the MC1 upon the trapezium, the ball-and-socket implant blocks dorsoradial subluxation (Fig. 5A) and suppresses the radial-ulnar

translation of the MC1 (Fig. 5B). As observed for the MC1, the trapezium cup limits adduction of the trapezium during thumb adduction compared with OA and healthy joints. Although the Arpe implant does not fully mimic the native TMC joint kinematics, it is able to restore thumb function by offering a larger amount of axial rotation to the MC1, reducing MC1 dorsal subluxation and improving thumb abduction. Moreover, the ball-and-socket implant works as a spacer with bone anchorage, avoiding collapse of the MC1 base by preserving the height of the resected joint.

In this study, we used a CT-based technique to accurately quantify the 3-dimensional kinematics of the entire articular chain of the thumb in patients before and after implant surgery. This methodology has been used in several recent studies in healthy subjects,<sup>13,14,21,29</sup> but has not yet been used to study the impact of OA and TMC arthroplasty on thumb joint kinematics. Moreover, available studies on total TMC arthroplasties are mostly retrospective clinical studies focusing on postoperative functional outcomes using DASH and/or visual analog scale pain scores, strength assessments, and radiographic outcomes, but not quantifying thumb motion,<sup>7,30–34</sup> except for Chèze et al<sup>23</sup> who quantified *in vivo* TMC joint ranges of motion using an optoelectronic motion analysis system in 2 female subjects with an Arpe implant.

Although our study provides a unique insight in the effect of implant surgery and the effect of OA on the kinematics of the thumb, there are some limitations inherent to using a CT-based technique.<sup>35,36</sup> Most importantly, the segmentation error might be more prominent than in previous CT-based studies due to OA bone deformations.<sup>37</sup> In addition, being a pilot study with a small sample size, the study lacked power to make definitive conclusions on the impact of OA and TMC joint implant on thumb kinematics.



Because we noted a substantial interindividual variation in the amount of MC1 rotation during both thumb flexion and adduction in the OA and implant groups, as well as in the healthy control group,<sup>14</sup> larger series are certainly needed to confirm our preliminary findings of the effect of OA and total TMC joint replacement on the kinematics of the thumb joints and to develop new implant designs that will ensure long-term success.

## ACKNOWLEDGMENTS

This study was partially funded via a research chair to E.E.V. and F.S. donated by the company Materialise (Materialise-Kulak Chair on Hand Surgery).

The investigation was performed at the Department of Development and Regeneration, Biomedical Sciences Group, KU Leuven Campus Kulak, Belgium.

This study has been performed in accordance with the ethical standards of the most recent version of the Declaration of Helsinki. We thank the Bioengineering Laboratory Department of Orthopaedics from Brown University (Providence, RI) for sharing their custom-designed polycarbonate rig.

We are also grateful to Eddy Brugman, MD, and the nursing staff of the Medical Imaging department of AZ Groeninge for their assistance during CT scanning.

## REFERENCES

- Marzke M. Evolutionary development of the human thumb. *Hand Clin.* 1992;8(1):1–8.
- Day CS, Gelberman R, Patel AA, Vogt MT, Ditsios K, Boyer MI. Basal joint osteoarthritis of the thumb: a prospective trial of steroid injection and splinting. *J Hand Surg Am.* 2004;29(2):247–251.
- Matullo KS, Ilyas A, Thoder JJ. CMC arthroplasty of the thumb: a review. *Hand (N Y).* 2007;2(4):232–239.
- Wajon A, Vinycomb T, Carr E, Edmunds I, Ada L. Surgery for thumb (trapeziometacarpal joint) osteoarthritis. *Cochrane Database Syst Rev.* 2009;4:CD004631.
- Vermeulen GM, Slijper H, Feitz R, Hovius SER, Moojen TM, Selles RW. Surgical management of primary thumb carpometacarpal osteoarthritis: a systematic review. *J Hand Surg Am.* 2011;36(1):157–169.
- Avisar E, Elvey M, Wasbrout Z, Aghasi M. Long-term follow-up of trapeziectomy with abductor pollicis longus tendon interposition arthroplasty for osteoarthritis of the thumb carpometacarpal joint. *J Orthop.* 2013;10(2):59–64.
- Huang K, Hollevoet N, Giddins G. Thumb carpometacarpal joint total arthroplasty: a systematic review. *J Hand Surg Eur Vol.* 2015;40(4):338–350.
- Berger AJ, Meals RA. Management of osteoarthrosis of the thumb joints. *J Hand Surg Am.* 2015;40(4):843–850.
- de la Caffinière JY. Total joint arthroplasty of the trapeziometacarpal joint [in French]. *Rev Chir Orth.* 1973;59:299–308.
- de la Caffinière JY, Aucouturier P. Trapezio-metacarpal arthroplasty by total prosthesis. *Hand.* 1979;11(1):41–46.
- Gehrmann SV, Tang J, Li ZM, Goitz RJ, Windolf J, Kaufmann RA. Motion deficit of the thumb in CMC joint arthritis. *J Hand Surg Am.* 2010;35(9):1449–1453.
- Hamann N, Heidemann J, Heinrich K, et al. Effect of carpometacarpal joint osteoarthritis, sex, and handedness on thumb *in vivo* kinematics. *J Hand Surg Am.* 2014;39(11):2161–2167.
- Crisco JJ, Halilaj E, Moore DC, Patel T, Weiss APC, Ladd AL. *In vivo* kinematics of the trapeziometacarpal joint during thumb extension-flexion and abduction-adduction. *J Hand Surg Am.* 2015;40(2):289–296.
- D'Agostino P, Dourthe B, Stockmans F, Kerkhof F, Vereecke EE. *In vivo* kinematics of the thumb during flexion and adduction motion: evidence for a screw-home mechanism. *J Orthop Res.* 2017;35(7):1556–1564.
- Cheze L, Dumas R, Comtet JJ, Rumelhart C, Fayet M. A joint coordinate system proposal for the study of the trapeziometacarpal joint kinematics. *Comput Methods Biomech Biomed Engin.* 2009;12(3):277–282.
- Wilder FV, Barrett JP, Farina EJ. Joint-specific prevalence of osteoarthritis of the hand. *Osteoarthritis Cartilage.* 2006;14(9):953–957.
- Eaton RG, Littler JW. Ligament reconstruction for the painful thumb carpometacarpal joint. *J Bone Joint Surg Am.* 1973;55(8):1655–1666.
- Eaton RG, Glickel SZ. Trapeziometacarpal osteoarthritis. Staging as a rationale for treatment. *Hand Clin.* 1987;3(4):455–471.
- Dourthe B, D'Agostino P, Stockmans F, Kerkhof F, Vereecke E. *In vivo* contact biomechanics in the trapeziometacarpal joint using finite deformation biphasic theory and mathematical modelling. *Med Eng Phys.* 2016;38(2):108–114.
- D'Agostino P, Dourthe B, Kerkhof F, van Lenthe GH, Stockmans F, Vereecke EE. *In vivo* biomechanical behavior of the trapeziometacarpal joint in healthy and osteoarthritic subjects. *Clin Biomech (Bristol, Avon).* 2017;12(49):119–127.
- Crisco JJ, Patel T, Halilaj E, Moore DC. The envelope of physiological motion of the first carpometacarpal joint. *J Biomech Eng.* 2015;137(10):101002.
- Wu G, Van Der Helm FCT, Veeger HEJ, et al. ISB recommendation on definitions of joint coordinate systems of various joints for the reporting of human joint motion—part II: shoulder, elbow, wrist and hand. *J Biomech.* 2005;38(5):981–992.
- Chèze L, Doriot N, Eckert M, Rumelhart C, Comtet JJ. *In vivo* cinematic study of the trapezometacarpal joint [in French]. *Chir Main.* 2001;20(1):23–30.
- Miura T, Ohe T, Masuko T. Comparative *in vivo* kinematic analysis of normal and osteoarthritic trapeziometacarpal joints. *J Hand Surg Am.* 2004;29(2):252–257.
- Van Nortwick S, Berger A, Cheng R, Lee J, Ladd AL. Trapezial topography in thumb carpometacarpal arthritis. *J Wrist Surg.* 2013;2(3):263–270.
- Imaeda T, Niebur G, An K-N, Cooney WP. Kinematics of the trapeziometacarpal joint after sectioning of ligaments. *J Orthop Res.* 1994;12(2):205–210.
- Armbruster EJ, Tan V. Carpometacarpal joint disease: addressing the metacarpophalangeal joint deformity. *Hand Clin.* 2008;24(3):295–299.
- Zancolli ER, Perrotto CJ. New transfer for correction of thumb metacarpophalangeal hyperextension in cases with associated surgery for basal thumb osteoarthritis (transfer of the volar half of the abductor pollicis brevis). *Tech Hand Up Extrem Surg.* 2011;15(2):92–93.
- Halilaj E, Rainbow MJ, Got C, et al. *In vivo* kinematics of the thumb carpometacarpal joint during three isometric functional tasks. *Clin Orthop Relat Res.* 2014;472(4):1114–1122.
- Brutus JP, Kinnen L. Short-term results of the total carpometacarpal joint replacement surgery using the ARPE implant for primary

- osteoarthritis of the thumb [in French]. *Chir Main*. 2004;23(5): 224–228.
31. Jacoulet P. Results of the ARPE trapezometacarpal prosthesis: a retrospective study of 37 cases [in French]. *Chir Main*. 2005;24(1): 24–28.
  32. Aparid T, Saint-Cast Y. Results of a 5 years follow-up of Arpe prosthesis for the basal thumb osteoarthritis. *Chir Main*. 2007;26(2): 88–94.
  33. Eecken S Vander, Vanhove W, Hollevoet N. Trapeziometacarpal joint replacement with the Arpe prosthesis. *Acta Orthop Belg*. 2012;78(6):724–729.
  34. Martin-Ferrero M. Ten-year long-term results of total joint arthroplasties with ARPE implant in the treatment of trapeziometacarpal osteoarthritis. *J Hand Surg Eur Vol*. 2013;39(8):826–832.
  35. Kerkhof FD, Brugman E, D'Agostino P, et al. Quantifying thumb opposition kinematics using dynamic computed tomography. *J Biomech*. 2016;49(9):1994–1999.
  36. Van den Broeck J, Vereecke E, Wirix-Speetjens R, Vander Sloten J. Segmentation accuracy of long bones. *Med Eng Phys*. 2014;36(7): 949–953.
  37. Boas FE, Fleischmann D. CT artifacts: causes and reduction techniques. *Imaging Med*. 2012;4(2):229–240.