

Case Report

MINOCYCLINE INDUCED EOSINOPHILIC PNEUMONIA: CASE REPORT AND REVIEW OF LITERATURE

S. Klerkx, K. Pat, W. Wuyts

Key words: eosinophilic lung disease, minocycline

ABSTRACT

A 51-year-old woman with eosinophilic pneumonia due to minocycline is described and a review of available literature is added. Until now, only 49 cases have been described, mainly in the Japanese population. Minocycline induced eosinophilic pneumonia is probably underreported and even underdiagnosed. This case highlights the importance of careful history taking, especially the use of drugs. Relatively safe drugs (like minocycline) can cause serious adverse events. On presentation, the disease mimics an infectious pneumonia. Peripheral eosinophilia can occur but isn't obligatory. A bronchoalveolar lavage may provide the first (and sometimes only) sign of eosinophilic lung disease. Withdrawal of minocycline is often enough although sometimes corticosteroids are needed. In general, prognosis is good when the diagnosis is made on time.

INTRODUCTION

Minocycline induced eosinophilic pneumonia is a rare disorder but every doctor should be aware of this serious adverse event. Nowadays minocycline is often prescribed for common acne in young people. It is often forgotten in history taking because patients don't consider it as a drug. On presentation, the disease mimics an infectious pneumonia. Peripheral eosinophilia can occur but isn't obligatory. Cessation of minocycline is often enough to cure the patient, in some case corticosteroids are needed.

CASE REPORT

A 51-year-old woman with no significant medical history was admitted to our hospital with a history of dyspnea, dry cough, fever up to 39.9°C, vomiting and myalgia since one day. Six days before admission, she started a treatment with minocycline 50 mg twice a day for common acne.

The physical examination revealed an oxygen saturation on room air of 89% and no fever. Chest auscultation showed bilateral fine crackles.

The white blood cell count was $23.10 \times 9/l$ (normal 4.0-10.0) with 90.6% of neutrophils (normal 38.0-77.0) and no eosinophils. The serum level of C-reactive protein was 340 mg/l (normal <5.0). Liver function tests were normal. On admission blood gas analysis with two liters of oxygen showed a pO₂ of 66 mmHg, a pCO₂ of 35 mmHg and an oxygen saturation of 94%. Chest X-ray showed minimal interstitial changes and chest computed tomography (CT) diffuse ground glass

UZ Leuven,
Department of pneumology,
Herestraat 49, B-3000 Leuven

Address for Correspondence:
Prof. Dr. Wim Wuyts
UZ Leuven
Department of pneumology,
Herestraat 49
B-3000 Leuven
Tel: ++32016346801
Fax: ++2016346803
E-mail: wim.wuyts@uzleuven.be

opacities, thickening of septa and mediastinal and hilar lymphadenopathy (figure 1, 2, 3).

Differential diagnosis on admission was minocycline induced pneumonia or infectious pneumonia. Minocycline was discontinued and antibiotics were added.

A bronchoscopy with bronchoalveolar lavage (BAL) was performed the day after admission. No transbron-

chial biopsies were taken. Differential cell analysis revealed a high total cell count ($246.10 \times 3/\text{ml}$, normal 50-250) and 63.6% macrophages (normal 90.0-100.0), 4.2% lymphocytes (normal <20%), 16% neutrophils (normal <3.0%) and 16% eosinophils (normal <2%). Culture of BAL was negative. Polymerase chain reaction for Chlamydia and Mycoplasma on BAL was negative. Urinary antigen for Legionella pneumonia was also negative.

Because of the clinical presentation, the elevated eosinophilia on BAL and no signs of infection, we concluded that this case was a minocycline induced eosinophilic pneumonia. On the third day of admission she became afebrile, biochemistry on day four showed a significant decline in inflammatory parameters, cough and dyspnea disappeared after one week.

DISCUSSION

Eosinophilic lung diseases

Eosinophilic lung diseases are a diverse group of pulmonary disorders characterized by pulmonary opacities associated with peripheral eosinophilia, tissue eosinophilia confirmed at biopsy or increased eosinophils in BAL (1). They are classified as eosinophilic lung disease of unknown cause, of known cause and eosinophilic vasculitis (table 1).

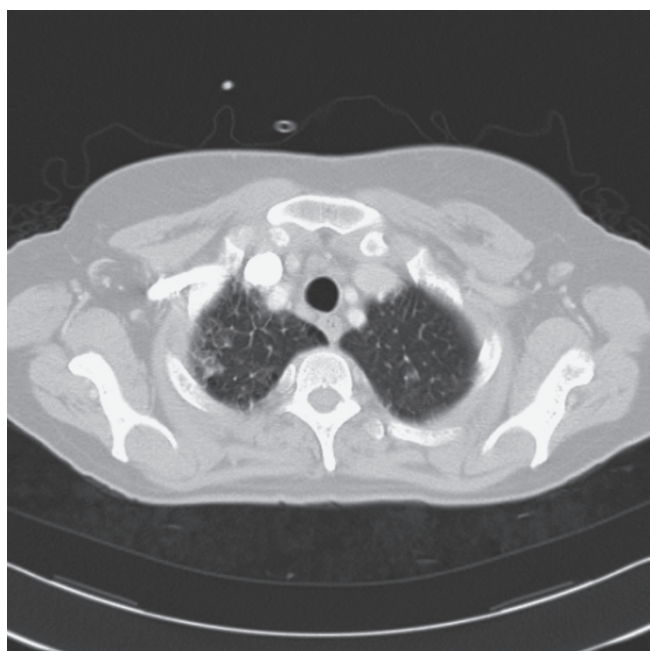


Figure 1: Mediastinal lymphadenopathy

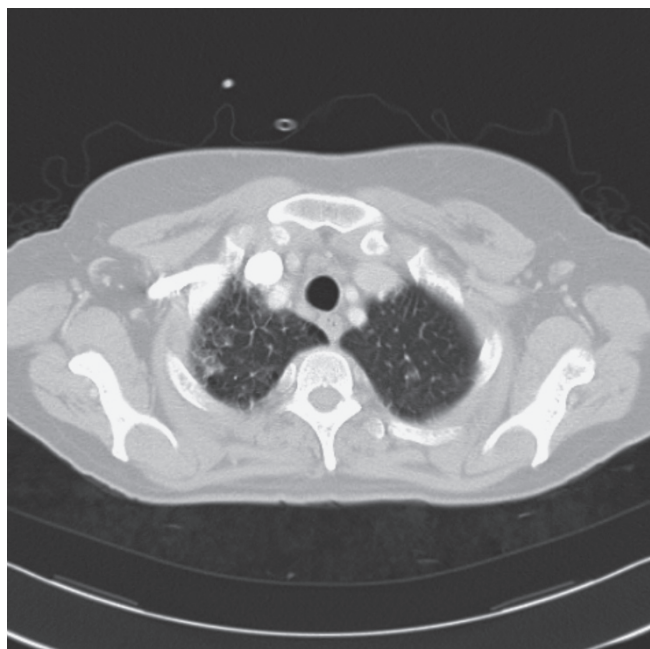


Figure 2: Ground glass opacities and thickening of interlobular septa.

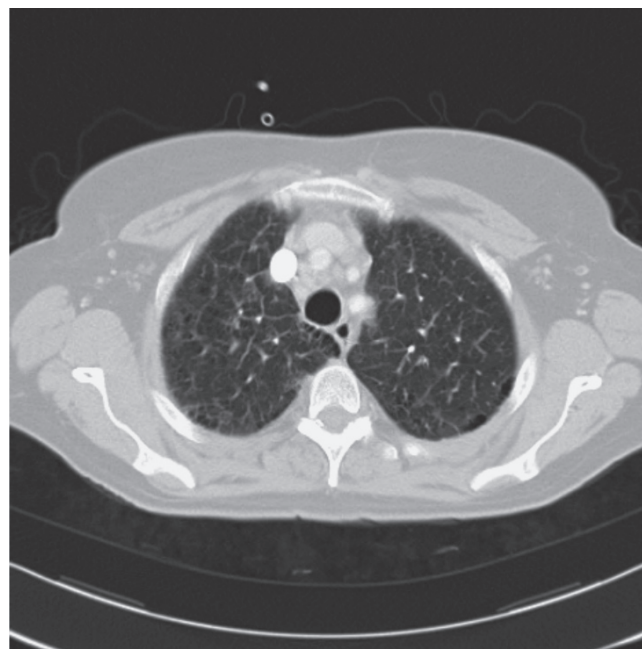


Figure 3: Thickening of interlobular septa

Table 1

Eosinophilic lung disease of unknown cause	Eosinophilic lung disease of known cause	Eosinophilic vasculitis
Simple pulmonary eosinophilia	Allergic bronchopulmonary aspergillosis	Churg-Strauss syndrome
Acute eosinophilic pneumonia	Bronchocentric granulomatosis	
Chronic eosinophilic pneumonia	Parasitic infections	
Idiopathic hypereosinophilic syndrome	Drugs and toxic substance reactions	

History taking is an extremely valuable diagnostic tool, in particular for eosinophilic lung disease of known cause. A history of asthma may raise suspicion of allergic bronchopulmonary aspergillosis, Churg-Strauss syndrome, bronchocentric granulomatosis or

chronic eosinophilic pneumonia. Recent travelling may suggest parasitic infections and an extensive history to rule out the use of drugs is important. A wide variety of drugs and toxic substances may induce eosinophilic disease. In the past two significant outbreaks have been reported. The first is toxic-oil syndrome, affecting > 20000 people in Spain in 1981, associated with the oral ingestion of food-grade rapeseed oil contaminated with aniline derivatives (2, 3). The second was the eosinophilia-myalgia syndrome in 1989, associated with the ingestion of L-tryptophan (4,5). The most common classes of drugs associated with pulmonary eosinophilia are the non-steroidal anti-inflammatory drugs and antimicrobials (nitrofurantoin, minocyclin, sulphonamide, ampicilline). A number of other drugs have been implicated in greater than 20 published case reports, for example methotrexate, amiodarone, anticonvulsants, antidepressants, angiotensin-converting-enzyme-inhibitors and beta-blockers (table 2). A frequently updated website listing drugs that have been

Table 2

Non-steroidal anti-inflammatory drugs		Antimicrobials		Other		Asthma	Peripheral eosinophilia	BAL fluid eosinophilia	Increased IgE level	Extrathoracic manifestations	Pathologic findings	CT findings
nitrofurantoin minocycline sulfonamides ampicilline		anticonvulsants antidepressants ACE inhibitors b-blockers hydrochlorothiazide sulfasalazine radiographic contrast media L-tryptophan methotrexate amiodarone bleomycine propylthiouracil										
SPE	No	Yes	> 20%	Yes	No	Infiltration of eosinophils into the alveolar septa and interstitium	Nodules with a GGO halo, transient and migratory.					
AEP	No	No	> 25%	Some	No	Diffuse alveolar damage with interstitial and alveolar eosinophilia	Bilateral patchy areas of GGO, interlobular septal thickening.					
CEP	Yes (50%)	Yes	> 25%	Yes (67%)	No	Infiltration of eosinophils into the alveoli and interstitium with interstitial fibrosis	Homogeneous peripheral airspace consolidation					
HIS	No	Yes	High (up to 73%)	Yes (50%)	Yes	Eosinophilic infiltration with disruption of architecture	Nodules with a GGO halo					
ABPA	Yes (100%)	Yes	< 20%	Yes	No	Bronchocentric granuloma with eosinophils, fungal hyphae.	Bronchiectasis with or without mucoid impaction involving the central and upper lungs.					
BG	Yes (33%)	Yes	< 20%	Some	No	Granulomatous inflammation of bronchial and bronchiolar epithelium	Nonspecific: focal mass or lobular consolidation with atelectasis					
Parasitic	No	Yes	< 20%	Yes	No	Variable depending on type of parasitic infestation.	Variable depending on type of parasitic infestation.					
Drug	No	Yes	< 20%	Yes	No	Infiltration of eosinophils and macrophages into the alveoli	Nonspecific: peripheral airspace consolidation and GGO					
CSS	Yes (100%)	Yes	> 30%	Yes	Yes	Necrotizing vasculitis, extravascular granulomas, eosinophilic pneumonia.	Subpleural consolidations with a lobular distribution, centrilobular nodules.					

associated with pulmonary infiltrates and eosinophilia is being maintained by 'Les Groupes d'Etudes de la Pathologie Pulmonaire latrogène' (6, www.pneumotox.com).

A white blood cell differential cell count is an essential part in diagnosis although peripheral eosinophilia isn't necessary. BAL may provide the first (and perhaps, the only) indication of an eosinophilic lung disease. Normal BAL fluid consists of less than 1% eosinophils. Eosinophilic lung diseases of unknown cause in general have a higher BAL fluid eosinophil level than eosinophilic lung diseases of known cause (table 3).

Nonspecific findings may be seen at conventional chest radiography. CT chest often shows more characteristic patterns but there is still a considerable overlap among the eosinophilic lung diseases (7, 8, table 3).

Minocycline

Minocycline hydrochloride is a long-acting semi-synthetic tetracycline derivative.

In the past it has been frequently used in the treatment of respiratory and urinary tract infections. Nowadays it's often prescribed by general practitioners and dermatologists for acne vulgaris in young people. Patients themselves do not always consider it as a real drug. Therefore it is often forgotten in history taking.

Minocycline is contra-indicated in pregnant woman because of reported congenital abnormalities (shortening of limbs) and in children under eight year because of the tooth discoloration that can occur during tooth development.

Adverse reactions of tetracyclines are light-headedness, various rashes, headache, nausea and photosensitivity. Specific minocycline associated and often more severe adverse reactions are hyperpigmentation, hypersensitivity reactions (hypersensitivity syndrome reaction (HSR), serumsickness like syndrome (SSLS) and eosinophilic pneumonia) and autoimmune reactions (drug induced lupus, autoimmune hepatitis).

Hyperpigmentation is not only seen on skin but also on oral mucosa, nails, bone, teeth, sclerae, thyroid gland and heart valves. Even black galactorhea is re-

ported. In some cases hyperpigmentation can diminish after cessation of minocycline (9).

Hypersensitivity reactions occur early in treatment, within weeks after starting the treatment. In HSR the patient develops fever and skin abnormalities (erythema, exfoliative dermatitis, exanthema or pustulous dermatitis), followed by internal damage. The liver is often involved, although damage to kidneys, heart and lung is described (9). SSLS is characterised by urticaria, fever, arthralgia and lymphadenopathy, in the absence of circulating antibodies (9). Eosinophilic pneumonia is discussed in the next paragraph.

Autoimmune reactions occur, in contrast to hypersensitivity reactions, after a longer period of treatment. In general, Minocycline induced lupus develops after 2 years of treatment (10,11,12). The symptoms are (poly)arthritis, (poly)arthralgia, morning stiffness, fever and fatigue. A blood exam shows a positive antinuclear antibody titer. Minocycline induced lupus can be accompanied by liver function abnormalities. Autoimmune hepatitis is seen in patients without minocycline induced lupus (13).

In relation to the number of prescriptions the number of serious adverse events of minocycline described is small but every doctor should be aware of them.

Minocycline induced eosinophilic lung disease

Pneumonitis due to minocycline was first reported by Ho et al in 1979 (14). Since then only a further 49 cases of reversible minocycline-related pneumonitis have been described. In only five articles more than one case is described (15, 16, 17, 18, 19). Minocycline-induced eosinophilic pneumonia is probably underreported, and even underdiagnosed.

The pathogenesis is unknown. Guillon et al reported cytotoxic CD8+ T lymphocyte-mediated specific cytotoxicity against minocycline-bearing alveolar macrophages in vitro (20). They hypothesized that T lymphocytes play a central role in the pathogenesis. However, their findings do not explain pulmonary eosinophilia, a characteristic feature of minocycline-induced pneumonitis.

On presentation minocycline induced pneumonia mimics an infectious pneumonia with high fever, dry cough and dyspnea as most frequent symptoms. Chest auscultation often reveals bilateral fine crackles. In 85% of the reported cases the symptoms presented within two weeks after the start of minocycline therapy. In general, biochemistry on admission reveals an elevated CRP, a leucocytosis with neutrophilia and often

Table 3

Note: SPE: simple pulmonary eosinophilia, AEP: acute eosinophilic pneumonia, CEP: chronic eosinophilic pneumonia, IHS: idiopathic hypereosinophilic syndrome, ABPA: allergic bronchopulmonary aspergillosis, BG: bronchocentric granulomatosis, CSS: Churg-Strauss syndrome, GGO: ground glass opacity.

an eosinophilia. Review of available literature showed eosinophilia in 18/26 cases, proving it isn't an obligate sign, as was the case in our patient. Blood gas analysis often reveals severe hypoxemia.

Chest X-ray shows an (often bilateral) infiltrate(s) and sometimes a pleural effusion (21, 22, 23, 24) or mediastinal/hilar lymphadenopathy (23) but can be normal.

Bronchoalveolar lavage is important in diagnosis and most frequently shows an eosinophilic formula (16/20 reported cases) but a neutrophilic/lymphocytic formula can also occur. When transbronchial biopsies are taken or an open lung biopsy is performed, further anatomopathological examination shows elevated eosinophils but there is no pathognomonic pattern. The role of a lymphocyte stimulation test is debated. In literature we only found a positive result in 1/14 cases (25). A Japanese study of seven patients showed a negative result in 6/7 patients (19). For that reason, we did not perform a lymphocyte stimulation test in our patient.

The prognosis after withdrawal of the drug is good. No mortality has been reported. However severe transient respiratory failure necessitating ventilatory support has been described (26, 27) and corticosteroid therapy was required to control symptoms in several cases (13/29 reported cases). There are no guidelines to decide whether corticosteroids should be added or not.

Rechallenge is the ultimate test to proof the relationship between minocycline and the clinical presentation. We didn't perform a rechallenge because of the high risk of recurrence in contrast with the few specific indications for minocycline in treatment of infections.

CONCLUSION

Minocycline-induced eosinophilic pneumonia is a rare disease so it stresses the importance of careful history taking, especially regarding the intake of drugs. In 85% of the reported cases the disease develops within 2 weeks after the start of minocycline therapy. On presentation, it mimics an infectious pneumonia. Peripheral eosinophilia can occur but isn't obligatory. A bronchoalveolar lavage may provide the first (and sometimes only) sign of eosinophilic lung disease. Prognosis is good when the diagnosis is made on time. Cessation of minocycline is often enough, sometimes corticosteroids are needed.

REFERENCES

- Allen JN, Davis WB. Eosinophilic lung diseases. *Am J Respir Crit Care Med* 1994; 150: 1423-1438.
- Kilbourne EM, Rigau-Perez JG, Heath CW Jr, Zack MM, Falk H, Martin-Marcos M, de Carlos A. Clinical epidemiology of toxic-oil syndrome: manifestations of a new illness. *N Eng J Med* 1983; 309: 1408-1414.
- Alonso-Ruiz, A, Calabozo, M, Perez-Ruiz, F, Mancebo, L. Toxic oil syndrome. A long-term follow-up of a cohort of 332 patients. *Medicine (Baltimore)* 1993; 72: 285.
- Silver RM, Heyes MP, Maize JC, Quearry B, Vionnet-Fuasset M, Sternberg EM. Scleroderma, fasciitis, and eosinophilia associated with the ingestion of tryptophan. *N Eng J Med* 1990; 322: 874-881.
- Swygert LA, Maes EF, Sewell et al. Eosinophilia-myalgia syndrome. Results of a national surveillance. *JAMA* 1990; 264: 1698.
- Foucher P, Camus P. Pneumotox online : the drug-induced lung diseases. www.pneumotox.com. Date last accessed : August 14, 2008.
- Johkoh T, Muller NL, Akira M, et al. Eosinophilic lung diseases : diagnostic accuracy of thin-section CT in 111 patients. *Radiology* 2000;216:773-780.
- Jeong YJ, Kim KI, Seo IJ, Lee CH, Lee KN, Kim KN, Kim JS, Kwon WJ. Eosinophilic lung diseases: a clinical, radiologic, and pathologic overview. *Radiographics* 2007; 27: 617-638.
- Hoefnagel JJ, Van Leeuwen RL, Mattie H et al. Bijwerkingen van minocycline in de behandeling van acne vulgaris. *Ned Tijdschr Geneesk* 1997; 141: 1424-1427.
- Christodoulou CS, Emmanuel T, Ray RA, Good RA, Schnapf BM, Cawkwell GD. Respiratory distress due to minocycline-induced pulmonary lupus. *Chest* 1999; 115: 1471-1473.
- Matsuura T, Shimizu Y, Fujimoto H, et al. Minocycline-related lupus. *Lancet* 1992 ; 340 : 1553.
- Masson C, Pascaretti C, Capon F, et al. Mminocycline-related lupus : a review of 23 definite cases (abstract). *Arthritis Rheum* 1996; 39(suppl): 69.
- Rikken NET, Klinkhamer PJJM, Haak HR. Interstitial pneumonia and hepatitis caused by minocycline. *The Netherlands Journal of Medicine* 2004; 62: 62-64.
- Ho D, Tashkin DP, Bein ME, Sharma O. *Chest* 1979; 76(1): 33-36.
- Shintani H, Minami S, Iwabuchi K, Johkaji Y, Hashimoto A, Noumi I, Fujimura M, Matsuda T, Kitagawa M. Three cases of minocycline-induced pneumonitis. *Nihon Kyobu Shikkan Gakkai Zasshi* 1991; 29(6): 718-723.
- Horikx PE, Gooszen HC. Minocycline as a cause of acute eosinophilic pneumonia. *Ned Tijdschr Geneesk* 1992; 136(11): 530-532.
- Sitbon O, Bidel N, Dussopt C, Azarian R, Braud ML, Lebargy F, Fourme T, de Blay F, Piard F, Camus P. Minocycline pneumonitis and eosinophilia. A report on eight patients. *Arch Intern Med* 1994; 154 (14).
- Dykhuisen RS, Zaidi AM, Godden DJ, Jegarajah S, Legge JS. Lesson of the week: minocycline and pulmonary eosinophilia. *BMJ* 1995; 310: 1520-1521.
- Toyoshima M, Sato A, Hayakawa H, Taniguchi M, Imokawa S, Chida K. A clinical study of minocycline-induced pneumonitis. *Int Med* 1996; 35: 176-179.
- Guillon JM, Joly P, Autran B, et al. Minocycline induced cell mediated hypersensitivity pneumonitis. *Ann Intern Med* 117: 476, 1992

21. Osanai S, Fukuzawa J, Akiba Y, Ishida S, Nakano H, Matsumoto H, Onodera S. Minocycline-induced pneumonia and pleurisy—a case report. *Nihon Kyobu Shikkan Gakkai Zasshi* 1992; 30(2): 322-327.
22. Wolthuis A, Nackaerts K, Guffens T, Jousten T, Demedts M. Minocycline-geassocieerde pulmonale infiltraten en eosinofilie. *Acta Clin Belg* 2003 ; 58-1.
23. Bando T, Fujimura M, Noda Y, Hirose J, Ohta G, Matsuda T. Minocycline-induced pneumonitis with bilateral hilar lymphadenopathy and pleural effusion. *Int Med* 1994; 33: 177-179.
24. Arai S, Shinohara Y, Kato Y, Hirano S, Yoshizawa A, Hojyo M, Kobayashi N, Sugiyama H, Kudo K. A case of minocycline-induced pneumonitis with bilateral pleura effusion. *Arerugi* 2007; 56(10): 1293-1297.
25. Nakano K, Gemma H, Ono T, Ito I, Chida K, Nakamura H. A case of minocycline-induced eosinophilic pneumonia presenting with multiple white eosinophilic plaques in the tracheobronchial mucosa. *Nihon Kokyuki Gakkai Zasshi* 2001; 39(1): 24-29.
26. Kondo H, Fujita J, Inoue T, Horiuchi N, Nakao K, Iwata M, Haba R, Ohtsuki Y. Minocycline-induced pneumonitis presenting as multiple ring-shaped opacities on chest CT, pathologically diagnosed bronchiolitis obliterans organizing pneumonia. *Nihon Kokyuki Gakkai Zasshi* 2001; 29(3): 215-219.
27. Oddo M, Liaudet L, Lepori M, Broccard AF, Schaller M. Relapsing acute respiratory failure induced by minocycline. *Chest* 2003; 123: 2146-2148.